

Microneedling: Advances and widening horizons

Aashim Singh, Savita Yadav

Department of
Dermatology and
Venereology, AIIMS,
New Delhi, India

ABSTRACT

Microneedling is a very simple, safe, effective, and minimally invasive therapeutic technique. It was initially introduced for skin rejuvenation, however, now it is being used for a very wide range of indications including acne scar, acne, post-traumatic/burn scar, alopecia, skin rejuvenation, drug delivery, hyperhidrosis, stretch marks, and many more. Moreover, during the last 10 years, many new innovations have been made to the initial instrument, which was used for microneedling. This technique can be combined with other surgical techniques to provide better results. In particular, it is a very safe technique for dark skin types, where risk of postinflammatory pigmentation is very high with other techniques that damage the epidermis. In this review article, we are updating on the different instruments now available for this procedure, and its efficacy when performed alone or in combination with other techniques for various indications.

Key words: Dermaroller, dermatosurgery, microneedling, percutaneous collagen induction

INTRODUCTION

Microneedling is a relatively new minimally invasive procedure involving superficial and controlled puncturing of the skin by rolling with miniature fine needles. Over a short period of time, it has gained mass popularity and acceptance as it is a simple, cheap, safe, and effective technique requiring minimal training. Traditionally used as a collagen induction therapy for facial scars and skin rejuvenation, it is also widely used now as a transdermal delivery system for therapeutic drugs and vaccines. In this review, we highlight the constantly evolving research and developments in microneedling techniques, instruments, and its applications in dermatology.

surgeon Fernandes in 2006 who self-designed a drum-shaped device with multiple fine protruding needles and used it for percutaneous collagen induction.^[3,4]

BASIC INSTRUMENT

The standard medical dermaroller [Figure 1] has a 12 cm long handle with a 2 × 2 cm wide drum-shaped cylinder at one end studded with 8 rows and 24 circular arrays of 192 fine microneedles, usually 0.5–3 mm in length and 0.1–0.25 mm in diameter.^[3] These single use microneedles are synthesized by reactive ion etching techniques on silicon or medical-grade stainless steel. The instrument is presterilized by gamma irradiation. Rolling with a standard dermaroller containing 192 needles of 2 mm length and 0.07 mm diameter over an area of skin for 15 times results in approximately 250

THE INVENTION

The advent of the concept of microneedling dates back to 1995 when Orentreich and Orentreich described dermal needling in the form of subcision for scar treatment and then independently in 1997 by a plastic surgeon Camirand who used tattoo guns without ink to take-off tension from postsurgical scars.^[1,2] Microneedling technique was given further shape by a German inventor Liebl in 2000 and a plastic

This is an open access article distributed under the terms of the Creative Commons Attribution-NonCommercial-ShareAlike 3.0 License, which allows others to remix, tweak, and build upon the work non-commercially, as long as the author is credited and the new creations are licensed under the identical terms.

For reprints contact: reprints@medknow.com

Cite this article as: Singh A, Yadav S. Microneedling: Advances and widening horizons. Indian Dermatol Online J 2016;7:244-54.

Access this article online

Website: www.idoj.in

DOI: 10.4103/2229-5178.185468

Quick Response Code:



Address for correspondence:

Dr. Savita Yadav,
Department of
Dermatology and
Venereology, AIIMS,
New Delhi, India.
E-mail: savita2081@gmail.com

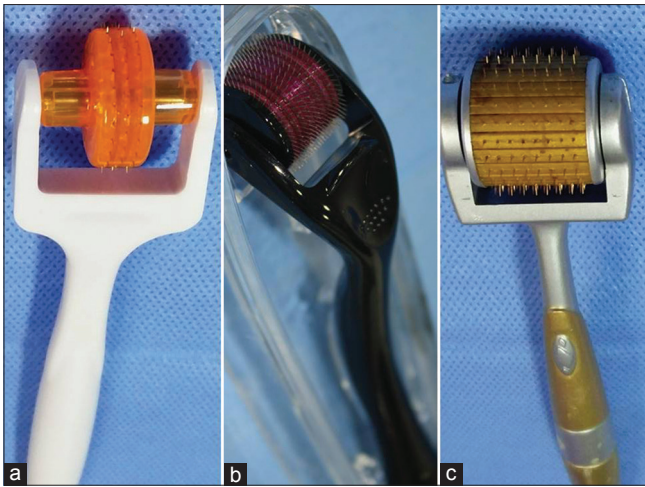


Figure 1: Different variety of Dermarollers: (a) Dermaroller with narrow width of drum meant for smaller areas such as eyelids and nose; (b) Dermaroller with 540 needles; (c) Standard dermaroller with 192 needles

holes per square cm upto the papillary dermis depending on the pressure applied.^[6] Each pass produces 16 micropunctures in the stratum corneum per square cm without damaging the epidermis significantly.^[6]

Principle and mechanism of action

Micropunctures are created using microneedles which produce a controlled skin injury without actually damaging the epidermis. These microinjuries lead to minimal superficial bleeding and set up a wound healing cascade with release of various growth factors such as platelet derived growth factor (PGF), transforming growth factor alpha and beta (TGF- α and TGF- β), connective tissue activating protein, connective tissue growth factor, and fibroblast growth factor (FGF).^[7] The needles also breakdown the old hardened scar strands and allow it to revascularize. Neovascularization and neocollagenesis is initiated by migration and proliferation of fibroblasts and laying down of intercellular matrix.^[8,9] A fibronectin matrix forms after 5 days of injury that determines the deposition of collagen resulting in skin tightening persisting for 5–7 years in the form of collagen III. The depth of neocollagenesis has been found to be 5–600 μm with a 1.5 mm length needle. Histological examination of the skin treated with 4 microneedling sessions 1 month apart shows upto 400% increase in collagen and elastin deposition at 6 months postoperatively, with a thickened stratum spinosum and normal rete ridges at 1 year postoperatively.^[10] Collagen fibre bundles appear to have a normal lattice pattern rather than parallel bundles as in scar tissue.^[6]

Liebl *et al.* have proposed another hypothesis to explain how microneedling works.^[11] Resting electrical membrane potential of cells is approximately -70 mV, and when needles come near the membrane, the inner electrical potential increases quickly to -100 mV. This triggers increased cell activity and

the release of various proteins, potassium, and growth factors from the cells into the exterior leading to the migration of fibroblasts to the site of injury, and hence, collagen induction. Thus, the needles do not create a wound in a real sense, but rather body cells are fooled into believing that the injury has occurred.^[9,11-13]

The expression of matrix metalloproteinases induced by microneedling is speculated in reduction of hyperpigmentation.^[11] In addition, the hyperproliferation of keratinocytes is downregulated by microneedling in acne patients because it overall balances out the cell equilibrium.^[11] However, more research needs to be done to elucidate the chain of events clearly.

Microneedling enhances the delivery of various drugs across the skin barrier as it bypasses the stratum corneum and deposits the drug directly up to the vascularized dermis. It has also been shown to cause significant widening of the follicular infundibulum by 47%, which may partly explain the increased penetration of the medication across the skin barrier. In addition, it removes the scales and sebum residues in the neighbourhood of the infundibulum.^[14]

Hence, this procedure extrapolates the body's own physiology of wound healing and the new collagen deposition results in skin tightening and filling-up of atrophic scars with an overall better aesthetic appeal since overlying epidermis is not ablated.

PROCEDURE

Microneedling is a simple office-based procedure lasting 10 to 20 minutes depending on the area to be treated. The patients must be counselled prior to the procedure explaining the expected outcomes, delayed response, and need for multiple sittings. The skin should preferably be prepared preoperatively for at least a month with vitamin A and C formulations twice a day to maximize dermal collagen formation. Vitamin A influences 400–1000 genes that control proliferation and differentiation of all major cells in epidermis and dermis, and Vitamin C is essential for production of normal collagen.^[10]

The procedure is performed under topical anesthesia containing eutectic mixture of lignocaine and prilocaine/tetracaine for 45 minutes to 1 hour. After preparation of the area with antiseptic and saline, the skin is stretched with one hand, and perpendicularly, rolling is done 5 times each in the horizontal, vertical, and oblique directions with the other hand [Figure 2]. The treatment endpoint is identified as uniform pin-point bleeding which is easily controllable. Post-procedure, the area is made wet with saline, or ice

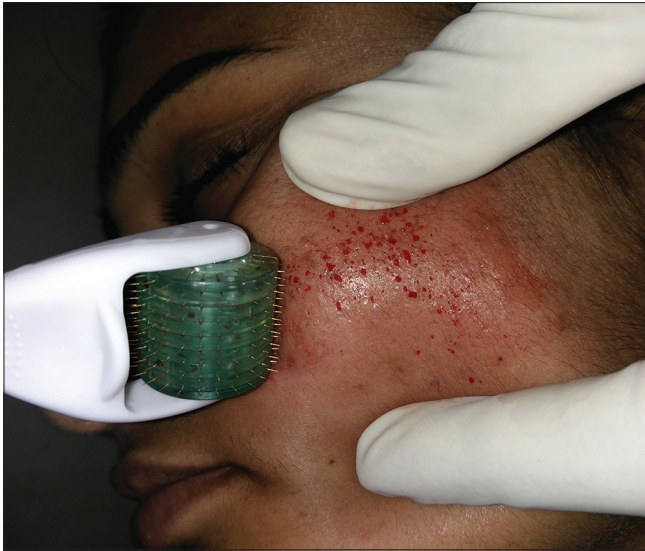

Figure 2: Pin-point bleeding over the cheek following microneedling procedure

packs can be used for comforting the patient. Thereafter, the patient is advised to use sunscreen regularly and follow sun-protective measures. The procedure is well-tolerated by the patients and there are usually no post-treatment sequelae except slight erythema and edema lasting for 2–3 days. There is no downtime and the patient can resume daily work the very next day. Treatments are performed at 3–8 week intervals and multiple sittings are needed to achieve the desired effect on the skin. The final results cannot be viewed immediately because new collagen continues to be laid down for approximately 3–6 months after treatment has ceased.^[10,15]

VARIOUS INSTRUMENTS AND TECHNIQUES

A simple dermaroller has evolved over the past decade through a variety of advancements. The current market is booming with an assortment of devices based on needle length, drum size, and automation [Figure 1].

The most important is the diversity of needle lengths. High ratio of tip length versus diameter of 13:1 is an important property of good needles.^[6] The length of needle selected for an individual patient depends upon the indication for microneedling. For treating acne and other scars as a routine, a needle length of 1.5–2 mm is usually used. When microneedling is used as a procedure to treat ageing skin and wrinkles, the needle length of 0.5 mm or 1.0 mm is usually recommended.^[9] When the needles are only up to 0.5 mm long, the procedure is essentially painless, and the perception of pain increases as the depth of needle penetration increases. It also depends on the thickness of epidermis and dermis of the skin.

The minimum time interval between two sittings of microneedling depends upon the indication for which the procedure is being done as well as the needle length of the dermaroller being used. More is the needle length, greater should be the interval between two sittings of microneedling. When using 1.5 mm dermaroller, at least 3 weeks gap should be there between two procedures.

Five basic types of medical dermarollers, which are registered with the FDA, have been described in the dermaroller series by Konstantinos, and most dermarolling devices are adopted from these elementary types:^[16]

- C-8 (Cosmetic type), is the basic dermaroller as described above with a needle length of only 0.13 mm (130 μ m) used for enhancing penetration of topical agents. It is completely painless.
- C-8HE (Cosmetic type for hair-bearing surfaces, scalp) has a needle length of 0.2 mm (200 μ m). Even this length is below the pain threshold.
- CIT-8 (CIT: Collagen Induction Therapy, Medical type) has a needle length of 0.5 mm (500 μ m) and helps in collagen induction and skin remodelling.
- MF-8 type has a needle length of 1.5 mm (1500 μ m). This creates deeper microchannels on the whole epidermis and dermis and at the same time destroys scar collagen bundles.
- MS-4 is the only dermaroller that has a smaller cylinder, 1 cm length, 2 cm diameter, and subsequently 4 circular arrays of needles (total 96 needles) that have 1.5 mm length. It is used on areas where better precision and deeper penetration is required. It is mostly used on facial acne scars.
- Devices similar to MS-4 are available with needle lengths of 0.5–0.75 mm, which are used for thin-skinned areas such as the periorbital and perioral regions.

Home care dermaroller

Home-care dermarollers (C-8) are used by patients themselves as they are of needle length less than 0.15 mm and are available for reduction of pore size, fine lines, and sebum production, as well as for transdermal delivery of substances such as lipopeptides and other antiageing products. They can be used twice or thrice a week for up to 100 times. After use, the rollers should be cleaned in hot tap water and shaken dry.^[3,17] Beauty Mouse is another approved device intended for home use. It contains a total of 480 needles of approximately 0.2 mm size on 3 separate drums strategically placed inside a computer mouse shaped device. It has been developed to ensure coverage of larger skin surface areas, such as the arms, legs, and buttocks for the treatment of stomach or thigh stretch marks and cellulite.^[18]

Derma-stamp

These are miniature versions of the dermaroller available in different needle lengths (0.2–3 mm) and a diameter of 0.12 mm that are used for localized scars such as varicella scars. Advantage over the dermaroller is that a more focussed treatment of individual scars is possible. It causes vertical penetration to create infusion channels in the skin and is considered ideal for use on isolated scars and wrinkles.^[3,5,17,18]

Dermapen

Dermapen [Figure 3] is an automated microneedling device which looks like a pen. This ergonomic device makes use of disposable needles and guides to adjust needle length for fractional mechanical resurfacing. The tip has 9–12 needles arranged in rows. It makes use of a rechargeable battery to operate in two modes, namely, the high speed mode (700 cycles/min) and the low speed mode (412 cycles/min) in a vibrating stamp-like manner.^[19] It has the advantage of being reusable in different patients as the needles are disposable, safe as the needle tips are hidden inside the guide, and more convenient to treat narrow areas such as the nose, around the eyes and lips without damaging the adjoining skin. It makes the procedure less painful and more economical as there is no need to buy a new instrument every time.^[20] This technology has been designed to overcome the issues of varying pressure application and the subsequent depth of penetration achieved.^[18]

DermaFrac

DermaFrac treatment is a newer modification of microneedling combining microdermabrasion, microneedling, simultaneous deep tissue serum infusion, and light emitting diode (LED) therapy. DermaFrac treatments target aging and sun damaged skin, acne, enlarged pores, uneven skin tone, wrinkles,



Figure 3: Dermapen with battery charger

fine lines, hyperpigmentation, and superficial scars. It takes approximately 45 min to complete full face treatment when all four modalities are used. This noninvasive, cost-effective treatment carries the advantage of having no downtime with individualized selection of serums for infusion.^[20,21]

Microneedle delivery systems

Microneedle delivery systems offer a minimally invasive and painless method of transdermal drug administration, especially useful for vaccines.^[22] The various types of microneedles available for this purpose can be solid, coated, dissolving, hollow, and swellable polymer microneedles synthesized by microfabrication technique.^[18] Silicon, metals such as titanium, natural and synthetic polymers, and polysaccharides are the various materials used to fabricate these microneedles. Solid-coated microneedles are used to pierce the superficial skin followed by topical application and delivery of the drug, whereas dissolvable or biodegradable and hollow needles deliver drugs directly into the dermis.^[22]

Fractional radiofrequency microneedling

The amalgamation of microneedling with radiofrequency has further expanded the prospects of application of this technology. Insulated needles are used to penetrate the skin and release radiofrequency currents from the needle tips producing thermal zones in the dermal structural components and accessory glands without damaging the overlying epidermis.^[23] This triggers long-term dermal remodelling, neocollagenesis, and neocollagenesis. The depth of the needles can be adjusted from 0.5 mm to 3.5 mm allowing us to target different layers of the dermis discretely.^[24] Operating person can exercise a good control over tissue damage by adjusting the power level and duration of energy pulse. The main energy delivery system has a disposable tip with 49 gold plated needles. Microneedling radiofrequency (MNRF) technology does not damage the epidermis, and is therefore, safe in darker skin types. Its indications include scar treatment, hyperhidrosis, skin tightening, rejuvenation, and many more.

Light emitting microneedling device

LED microneedling rollers have been recently launched. These incorporate titanium microneedles and LED light to combat wrinkles and scarring.^[19] These devices have not yet been explored and no published data is available regarding its efficacy.

APPLICATIONS OF MICRONEEDLING IN DERMATOLOGY

Dermarolling has been used for a wide range of indications with many trials supporting evidence for its usefulness.^[5,6,17,23] It has been tried alone as well as in combination with other treatment modalities such as chemical peeling, platelet rich

plasma, radiofrequency, subcision, punch elevation, and lasers. It is often used in conjunction with a topical formulation, and hence, enhances its penetration and action.

Skin rejuvenation

Microneedling leads to reorganization of old collagen fibres and laying down of new collagen, elastin, and capillaries leading to the effect of skin tightening. A significant increase in level of collagen type I, III, and VII, newly synthesized collagen and tropoelastin from baseline was observed after 6 microneedling sessions at 2-week intervals by El-Domyati *et al.*^[25] This percutaneous collagen induction leads to an overall youthful appearance of the skin by reducing fine lines and wrinkles, reducing pore size, more suppleness, and elasticity.

The effects are enhanced when the procedure is combined with topical antiageing vitamin C serum and tretinoin application. Microneedling has also been combined with human embryonic stem cells derived endothelial precursor cell conditioned medium and has shown significant reduction in wrinkles and pigmentation.^[26,29] Fractional microneedling radiofrequency has been studied in a large multicentre trial and has found to be effective in reducing wrinkles [Table 1].^[27]

Scars

Acne scars

The most frequently used indication of microneedling is post-acne facial atrophic scars [Figure 4], and a large number of trials have been conducted to evaluate the same alone as well as in combination with chemical peels, platelet-rich plasma, subcision, cryotherapy, and CROSS technique. Microneedling has been found to be more effective for rolling and boxcar scars, and relatively less effective in ice-pick scars. It is safe for all skin types with minimal downtime. Only the affected area needs to be treated and there is minimal risk of post-inflammatory dyschromia. However, a minimum of 4–6 sessions are required for a significant improvement [Table 2].

Nonacne scars

Post-burn scar, post-traumatic scar, hypertrophic scars, varicella scars [Table 3].

Post-surgical scars were the first to be studied by Camirand^[2] who used tattoo gun needles to reduce the scars. Since then, microneedling has been used for almost all types of surgical scars and are to be found useful. Microneedling has been found to be effective in reducing even burn scars [Figure 5] by up to 80% in a study on 16 patients by Aust *et al.* It was stipulated that there is normalization of collagen-elastin matrix in the dermis at 1 year.^[10,15] Microneedling is also effective for varicella scars [Figure 6] and post-traumatic scars [Figure 7].

Acne vulgaris

The advent of fractional microneedling radiofrequency has expanded the application of microneedling to acne vulgaris as well. It directly targets the sebaceous glands and helps in reducing the sebum production. It is also known to reduce the hyperproliferation of keratinocytes [Table 4].

Androgenic alopecia and alopecia areata

Use of microneedling over scalp for alopecia is one of its recent advances. It has been compared with minoxidil alone and has been found to be better in combination.^[47,48] Home-use dermarollers are prescribed to patients who are using minoxidil, and a better hair growth is observed. However, when topical minoxidil was compared with Platelet Rich Plasma (PRP) and microneedling therapy in a recent study, minoxidil alone continued to remain better.^[49] Microneedling has also been combined with topical triamcinolone acetonide application in alopecia areata and better response has been observed [Table 5].^[50]

Pigmentation—Melasma and periorbital hypermelanosis

The introduction of Dermafrac technique and smaller drums with needles sizes approximately 0.5 mm has made the microneedling to periocular skin amenable. Microneedling

Table 1: Microneedling trials for skin rejuvenation (literature search after year 2010)

Author	Year	No. of patients	Objective	Outcome
Clementoni <i>et al.</i> ^[28]	2010	21	Photodynamic photorejuvenation of the face with a combination of microneedling, 1 hour ALA incubation followed by red light and broadband-pulsed light	90% of patients judged clinical improvement to be greater than 50% at 6 months compared to baseline photography
Calderhead <i>et al.</i> ^[27]	2013	499	Multicentre study to evaluate efficacy of microneedling fractional radiofrequency	80-89% overall improvement, 30-36% decrease in wrinkle size, 25-29% decrease in wrinkle depth after 2-3 sessions
Seo <i>et al.</i> ^[29]	2013	15	Comparison of FMRF with and without stem cell medium	Combination found to be better
Lee <i>et al.</i> ^[26]	2014	25	To study efficacy of microneedling with human stem cell conditioned medium	Combination better than microneedling alone ($P<0.05$)
El-Domyati <i>et al.</i> ^[25]	2015	10	To study objective and histological efficacy of microneedling	Increased collagen I, III, VII, and tropoelastin ($P<0.05$)

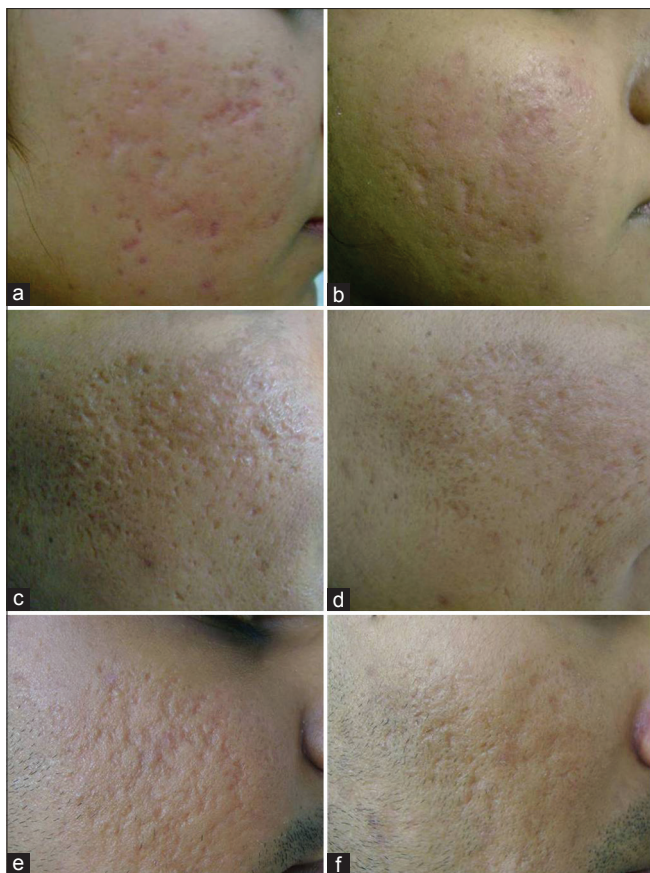

Figure 4: Pre (a, c, e) and post (b, d, f) treatment photographs of post-acne atrophic scar patients after 4 sittings of microneedling done 1 month apart

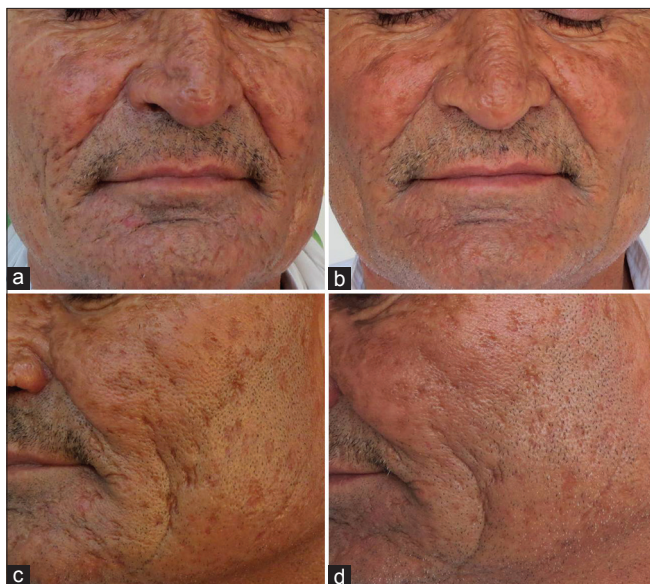


Figure 6: Post-varicella scars (a,c) showing improvement (b,d) after 3 microneedling sittings done 1 month apart

has been combined with various skin lightening agents and chemical peels to reduce melasma as well as periorbital hypermelanosis [Table 6].

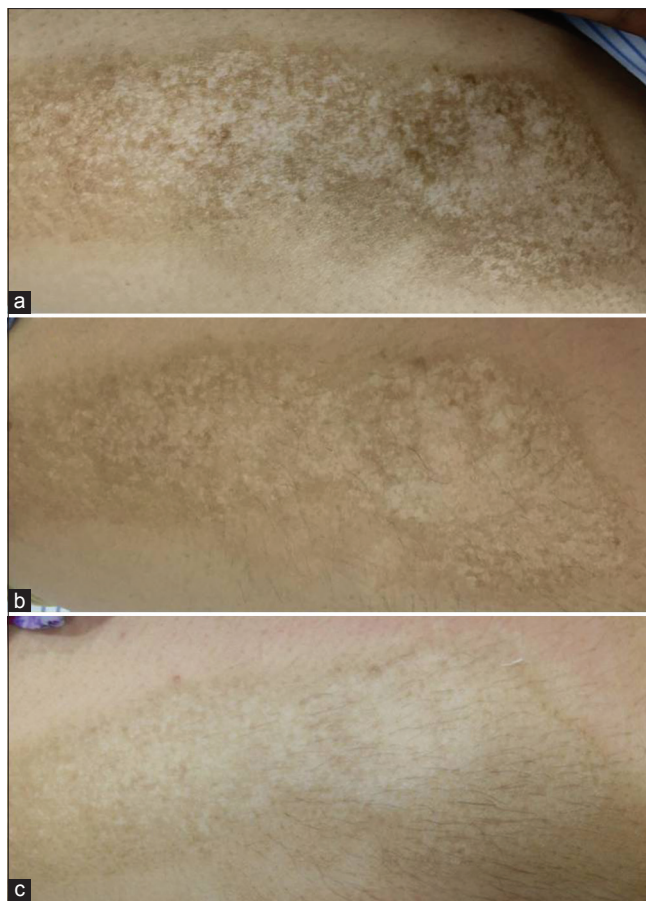

Figure 5: Post-burn scar on the thigh of 1 year duration treated with a combination of microneedling and laser (a) Baseline photograph; (b). Scar showing improvement after 3 fortnightly sessions of microneedling; (c) Further improvement in scar following 1 session of Fraxel laser RE: STORE SR 1500nm (Solta Medical, USA) with following parameters: 70 mj beam energy, 20% density, 8 passes. (Courtesy: Dr Arshdeep, Consultant Dermatologist, Kubba Skin Clinic, New Delhi)

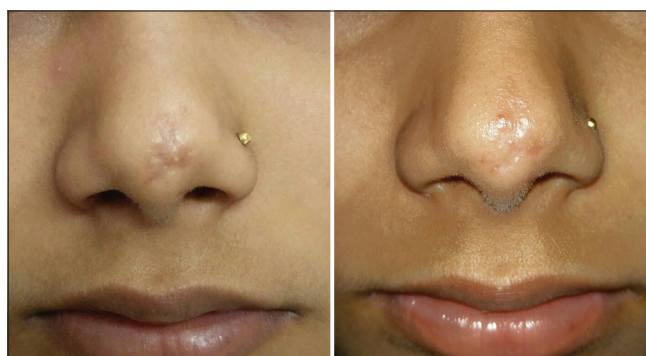

Figure 7: Significant improvement in post-traumatic scar over the nose after 1 sitting of subcision followed by 3 sittings of microneedling done 1 month apart

Miscellaneous conditions

Extended applications of microneedling include stretch marks, axillary hyperhidrosis, and actinic keratosis in photodamaged skin. MNRF has been used even in patients with rosacea and post-acne erythema with favorable results [Table 7].

Table 2: Studies using microneedling for facial post acne atrophic scars (literature search after year 2010)

Author	Year	No. of patients	Objective	Outcome
Sharad ^[30]	2011	60	Comparison of microneedling with and without glycolic acid peels	Combination found to be better
Dogra <i>et al.</i> ^[31]	2014	36	To study efficacy in atrophic facial acne scars	Mean improvement of 50-75% from baseline
Chawla <i>et al.</i> ^[32]	2014	30	Microneedling with PRP vs Microneedling with vitamin C	PRP combination found better ($P=0.01$)
Chandrashekar <i>et al.</i> ^[24]	2014	31	Evaluation of Microneedling Fractional Radiofrequency Device	Improvement-58% moderate and 29% minimal Adverse effects-mild erythema, postinflammatory hyperpigmentation, track marks of the device
Gadkari <i>et al.</i> ^[33]	2014	30	Comparison of subcision with dermaroller vs. subcision with cryoroller	Cryorolling better than microneedling
Fabbrocini <i>et al.</i> ^[34]	2014	60	To analyze efficacy in different skin phototypes	Significant reduction in scars ($P<0.05$) in all phototypes without dyspigmentation in any, 31% reduction in skin irregularity
Hassan ^[35]	2015	70	Comparison of microneedling with and without subcision	100% efficacy with combination, 77% with microneedling alone
El-Domyati <i>et al.</i> ^[36]	2015	10	To assess objective and histological efficacy	Improvement seen, increased collagen ($P<0.05$)
Pandey <i>et al.</i> ^[37]	2015	30	To assess efficacy of microneedling alone	Mean 80% improvement
Puri ^[38]	2015	30	Comparison of microneedling with TCA CROSS	Comparable results
Cachafeiro <i>et al.</i> ^[39]	2016	46	Comparison of Nonablative Fractional Erbium Laser 1340 nm and Microneedling	Comparable results

Table 3: Microneedling for non-acne scar treatment (literature search after year 2010)

Indication	Author	Year	No. of patients	Objective	Outcome
Burn scars	Kim <i>et al.</i> ^[40]	2010	25	To study the effectiveness of Dermastamp	Improvement seen ($P<0.05$)
Burn scars	Aust <i>et al.</i> ^[15]	2010	16	To study efficacy of microneedling in reducing post-burn scars without damaging epidermis	80% improvement in scarring, 45% thickened stratum spinosum, normal rete ridges after 1 year
Burn scars	Sofanov ^[41]	2011	1		Good improvement
Varicella scars	Costa <i>et al.</i> ^[42]	2014	1	Assessment of efficacy	Significant improvement

Table 4: Fractional microneedling radiofrequency trials for acne vulgaris (literature search after year 2010)

Indication	Author	Year	No. of patients	Objective	Outcome
Acne vulgaris	Lee <i>et al.</i> ^[43]	2012	18	To assess the efficacy of FMRF	Reduced number of lesions
Acne vulgaris	Lee <i>et al.</i> ^[44]	2013	20	To assess the efficacy of FMRF	70-80% reduced sebum
Acne vulgaris	Kim <i>et al.</i> ^[45]	2014	25	Treatment of acne vulgaris with FMRF	76% reduction in acne, 37% reduction in sebum ($P<0.05$)
Acne and acne scars	Min <i>et al.</i> ^[46]	2015	20	Comparison of FMRF with bipolar radiofrequency	Superior efficacy of FMRF

Table 5: Microneedling trials for alopecia (literature search after year 2010)

Indication	Author	Year	No. of patients	Objective	Outcome
Androgenic alopecia	Dhurat <i>et al.</i> ^[47]	2013	100	Comparison of topical minoxidil with and without microneedling	Combination better ($P=0.039$)
Alopecia areata	Chandrashekar <i>et al.</i> ^[50]	2014	2	To study the efficacy of microneedling with topical triamcinolone acetonide	Response seen
Androgenic alopecia	Dhurat <i>et al.</i> ^[48]	2015	4	To study efficacy in patients not responding to minoxidil and finasteride	Up to 75% improvement
Patterned hair loss	Farid <i>et al.</i> ^[49]	2016	40	Comparison of PRP microneedling with topical 5% minoxidil	Minoxidil remains better

Table 6: Microneedling trials for pigmentation (melasma and periorbital hypermelanosis) (literature search after year 2010)

Indication	Author	Year	No. of patients	Objective	Outcome
Melasma	Fabbrocini <i>et al.</i> ^[51]	2011	20	Comparison of combined skin needling with depigmenting serum and depigmenting serum alone	Reduction in MASI score more on combination side compared to serum alone ($P<0.001$)
Periorbital hypermelanosis	Sahni <i>et al.</i> ^[20]	2013	1	To study the efficacy of Dermafrac	75-90% improvement
Melasma	Budamakuntla <i>et al.</i> ^[52]	2013	60	Comparison of tranexamic acid microinjections against tranexamic acid with microneedling	44.41% reduction in MASI score in microneedling group compared to 35.72% reduction with microinjections
Melasma	Lima ^[53]	2015	22	To evaluate efficacy in recalcitrant cases	Improvement seen
Periorbital hypermelanosis	Markantoni <i>et al.</i> ^[54]	2015	13	Combination of microneedling and 10% TCA peels	Improvement in 92.3% patients
Periorbital hypermelanosis	Kontochistopoulos <i>et al.</i> ^[55]	2016	13	Combination of microneedling and 10% TCA peels	Improvement seen

Table 7: Microneedling trials for miscellaneous indications (literature search after year 2010)

Indication	Author	Year	No. of patients	Objective	Outcome
Actinic keratosis	Bencini <i>et al.</i> ^[56]	2012	12	To study efficacy of microneedling with topical PDT	83% showed complete response
Acinic keratosis and photodamage	Torezan <i>et al.</i> ^[57]	2013	10	Comparison of PDT with and without microneedling	Combination better ($P=0.004$)
Primary axillary hyperhidrosis	Kim <i>et al.</i> ^[58]	2013	20	To study efficacy of FMRF	Reduced number and size of sweat glands
Striae rubra	Sanad <i>et al.</i> ^[59]	2015	30	Comparison of microneedling with and without trichloroacetic acid peeling	Combination better ($P<0.05$)
Rosacea	Park <i>et al.</i> ^[60]	2015		To study efficacy of microneedling fractional radiofrequency	25-58% improvement
Post-acne erythema	Min <i>et al.</i> ^[61]	2015	25	FMRF in post inflammatory acne erythema	Improvement seen ($P<0.05$)

Skin laxity

- Lax skin on arms, abdomen, neck, thighs, areas between breast and buttocks^[5,6,17]
- To tighten skin after liposuction.

TRANSDERMAL DELIVERY OF DRUGS

The technique of microneedling has been well-exploited to increase penetration of drugs across the skin barrier. This has been proven in *in-vitro* skin models where enhanced absorption of larger molecules such as calcein has been observed.^[62,63] Microneedles cover a range of activity between that of a transdermal patch and a hypodermic needle attempting to gain the advantages of both and eliminate the disadvantages of each one of them. Microneedling has been used for the transdermal delivery of various types of drugs including macromolecular biopharmaceuticals such as insulin, growth hormone, heparin, and albumin; immunobiologicals such as hepatitis B, tetanus toxoid, and influenza vaccines; proteins, peptides and drugs such as aspirin, minoxidil, tretinoin, and L-ascorbic acid.^[21,64,65] Microneedling has also been combined with other advanced techniques such as micropumps, sonophoresis, iontophoresis, and electroporation for better drug penetration.^[21]

With respect to dermatology, microneedling is often combined with topical tretinoin and vitamin C for the treatment of acne scarring and skin rejuvenation, as described above. Penetration enhancement of minoxidil and platelet-rich plasma for androgenic alopecia is another application. Microneedling enhances the effect of 5-aminolevulinic acid for more efficacious photodynamic therapy.^[66] They have been used in combination for the treatment of actinic keratosis^[56] and photoaging.^[28]

CONTRAINDICATIONS^[5,6]

- Active acne
- Herpes labialis or any other local infection such as warts
- Moderate to severe chronic skin disease such as eczema and psoriasis
- Blood dyscrasias, patients on anticoagulant therapy
- Extreme keloidal tendency
- Patient on chemo/radiotherapy.

LIMITATIONS AND ADVERSE EFFECTS

Derma-rolling has its own set of limitations despite its assembly of effective uses and advantages over other procedures. It is

less efficacious in some types of scars such as pitted scars, linear scars, and deep boxcar scars. However, combining other surgical procedures to microneedling can improve its results.

Certain adverse events are also known with the procedure, the common ones being potential erythema and irritation which usually subside within a few hours. Other events noted are post-inflammatory hyperpigmentation, aggravation of acne and reactivation of herpes, systemic hypersensitivity, allergic granulomatous reactions and local infections following the use of a nonsterile instrument.^[6,9,17,22] Allergic contact dermatitis to materials used in the needles has also been observed.^[67] Tram-track effect after two sessions of microneedling has been reported in a patient with acne scars who developed regularly placed linear papular scars over bony prominences of the face.^[68] This can be avoided by using less pressure and smaller needles over these areas.

Microneedling is relatively safe to use in Indian skin because it rarely leads to hyperpigmentation unlike other ablative and resurfacing procedures.^[23] It carries a better safety profile with regards to risk of dyspigmentation in all skin types.^[34]

FUTURE PROSPECTS

Because skin is an easily accessible tissue, has a good regenerative capacity, and is easily scrutinized directly, it serves as a potential organ for the development of therapeutic and prophylactic genetic medicines. It was demonstrated by Chabri *et al.* that microneedling can be used for intradermal delivery of a nonviral vector which can be exploited for localized treatment of genetic diseases such as epidermolysis bullosa.^[69]

Derma-rolling may be useful to dye poorly pigmented hairs and improving laser hair removal because it has been shown that it dilates the follicular infundibulum and increases the transfollicular absorption of melanin.^[14]

CONCLUSION

Microneedling is an effective modality of treatment, especially in patients with Fitzpatrick's IV and V skin types because it overcomes the side effects of scarring and hyperpigmentation resulting from other procedures in which the epidermis is compromised. It certainly promises to be a valuable technique with its numerous applications and its ever-expanding modifications as well as feasibility of home use.

Declaration of patient consent

The authors certify that they have obtained all appropriate patient consent forms. In the form the patient(s) has/have given his/her/their consent for his/her/their images and other clinical information to be reported in the journal. The patients

understand that their names and initials will not be published and due efforts will be made to conceal their identity, but anonymity cannot be guaranteed.

Financial support and sponsorship

Nil.

Conflicts of interest

There are no conflicts of interest.

REFERENCES

- Orentreich DS, Orentreich N. Subcutaneous incisionless (subcision) surgery for the correction of depressed scars and wrinkles. *Dermatol Surg* 1995;21:543-9.
- Camirand A, Doucet J. Needle dermabrasion. *Aesthet Plast Surg* 1997;21:48-51.
- Bahuguna A. Micro needling-Facts and Fictions. *Asian J Med Sci* 2013;4:1-4.
- Fernandes D. Minimally invasive percutaneous collagen induction. *Oral Maxillofac Surg Clin North Am* 2006;17:51-63.
- Bhardwaj D. Collagen induction therapy with dermaroller. *Community Based Med J* 2013;1:35-7.
- Nair PA, Arora TH. Microneedling using dermaroller: A means of collagen induction therapy. *GMJ* 2014;69:24-7.
- Falabella AF, Falanga V. Wound healing. In: Freinkel RK, Woodley DT, editors. *The Biology of the Skin*. New York: Parthenon; 2001. p. 281-99.
- Fabbrocini G, Fardella N, Monfrecola A, Proietti I, Innocenzi D. Acne scarring treatment using skin needling. *Clin Exp Dermatol* 2009;34:874-9.
- Majid I, Sheikh G, September PI. Microneedling and its applications in dermatology. In: *Prime 2014 Sep 15 (Vol. 4, No. 7, pp. 44-49)*. London: Informa Healthcare.
- Aust MC, Fernandes D, Kolokythas P, Kaplan HM, Vogt PM. Percutaneous collagen induction therapy: An alternative treatment for scars, wrinkles, and skin laxity. *Plast Reconstr Surg* 2008;121:1421-9.
- Liebl H, Kloth LC. Skin cell proliferation stimulated by microneedles. *J Am Coll Clin Wound Spec* 2012;4:2-6.
- Jaffe L. Control of development by steady ionic currents. *Fed Proc* 1981;40:125-7.
- Kloth LC. Electrical stimulation for wound healing: A review of evidence from *in vitro* studies, animal experiments, and clinical trials. *Int J Low Extrem Wounds* 2005;4:23-44.
- Serrano G, Almudéver P, Serrano JM, Cortijo J, Faus C, Reyes M, *et al.* Microneedling dilates the follicular infundibulum and increases transfollicular absorption of liposomal sepi melanin. *Clin Cosmet Investig Dermatol* 2015;8:313-8.
- Aust MC1, Knobloch K, Reimers K, Redeker J, Ipaktchi R, Altintas MA, *et al.* Percutaneous collagen induction therapy: An alternative treatment for burn scars. *Burns* 2010;36:836-43.
- Anastassakis K. The Dermaroller Series. http://www.mtoimportadora.com.br/site_novo/wp-content/uploads/2014/04/Dr.-Anastassakis-Kostas.pdf. [Last accessed on 2016 Jun 22].
- Doddaballapur S. Microneedling with dermaroller. *J Cutan Aesthet Surg* 2009;2:110-1.
- McCrudden MT, McAlister E, Courtenay AJ, González-Vázquez P, Singh TR, Donnelly RF. Microneedle applications in improving skin appearance. *Exp Dermatol* 2015;24:561-6.
- Arora S, Gupta BP. Automated microneedling device—A new tool in dermatologist's kit—A review. *J Pak Med Assoc* 2012;22:354-7.

20. Lewis W. Is microneedling really the next big thing? Wendy Lewis explores the buzz surrounding skin needling. *Plast Surg Pract* 2014;7:24-8.
21. Sahni K, Kassir M. Dermafrac™: An innovative new treatment for periorbital melanoses in a dark-skinned male patient. *J Cutan Aesthet Surg* 2013;6:158.
22. Bariya SH, Gohel MC, Mehta TA, Sharma OP. Microneedles: An emerging transdermal drug delivery system. *J Pharm Pharmacol* 2012;64:11-29.
23. Cohen BE, Elbuluk N. Microneedling in skin of color: A review of uses and efficacy. *J Am Acad of Dermatol* 2016;74:348-55.
24. Chandrashekar BS, Sriram R, Mysore R, Bhaskar S, Shetty A. Evaluation of microneedling fractional radiofrequency device for treatment of acne scars. *J Cutan Aesthet Surg* 2014;7:93-7.
25. El-Domyati M, Barakat M, Awad S, Medhat W, El-Fakahany H, Farag H. Multiple microneedling sessions for minimally invasive facial rejuvenation: An objective assessment. *Int J Dermatol* 2015;54:1361-9.
26. Lee HJ, Lee EG, Kang S, Sung JH, Chung HM, Kim DH. Efficacy of Microneedling Plus Human Stem Cell Conditioned Medium for Skin Rejuvenation: A Randomized, Controlled, Blinded Split-Face Study. *Ann Dermatol* 2014;26:584-91.
27. Calderhead RG, Goo BL, Lauro F, Gursoy D, Savant SS, Wronski A. The clinical efficacy and safety of microneedling fractional radiofrequency in the treatment of facial wrinkles: A multicenter study with the Infini System in 499 patients. White paper, Lutronic Corp, Goyang, South Korea.
28. Clementoni MT, B-Roscher M, Munavalli GS. Photodynamic photorejuvenation of the face with a combination of microneedling, red light, and broadband pulsed light. *Lasers Surg Med* 2010;42:150-9.
29. Seo KY, Kim DH, Lee SE, Yoon MS, Lee HJ. Skin rejuvenation by microneedle fractional radiofrequency and a human stem cell conditioned medium in Asian skin: A randomized controlled investigator blinded split-face study. *J Cosmet Laser Ther* 2013;15:25-33.
30. Sharad J. Combination of microneedling and glycolic acid peels for the treatment of acne scars in dark skin. *J Cosmet Dermatol* 2011;10:317-23.
31. Dogra S, Yadav S, Sarangal R. Microneedling for acne scars in Asian skin type: An effective low cost treatment modality. *J Cosmet Dermatol* 2014;13:180-7.
32. Chawla S, Sachidanand S, Leelavathi B. Split Face Comparative Study of Microneedling with PRP Versus Microneedling with Vitamin C in Treating Atrophic Post Acne Scars. *J Cutan Aesthet Surg* 2014;7:209-12.
33. Gadkari R, Nayak C. A split-face comparative study to evaluate efficacy of combined subcision and dermaroller against combined subcision and cryoroller in treatment of acne scars. *J Cosmet Dermatol* 2014;13:38-43.
34. Fabbrocini G, De Vita V, Monfrecola A, De Padova MP, Brazzini B, Teixeira F, *et al.* Percutaneous collagen induction: An effective and safe treatment for post-acne scarring in different skin phototypes. *J Dermatolog Treat* 2014;25:147-52.
35. Hassan R. Comparison of efficacy of micro needling for the treatment of acne scars in Asian skin with and without subcision. *J Turk Acad Dermatol* 2015;9:159-66.
36. El-Domyati M, Barakat M, Awad S, Medhat W, El-Fakahany H, Farag H. Microneedling Therapy for Atrophic Acne Scars: An Objective Evaluation. *J Clin Aesthet Dermatol* 2015;8:36-42.
37. Pandey A, Swain J P, Minj A. Assessment of microneedling therapy in the management of atrophic facial acne scars. *J Evid Based Med Healthcare* 2015;2:8911-13.
38. Puri N. Comparative study of dermaroller therapy versus trichloroacetic acid CROSS for the treatment of atrophic acne scars. *J Pak Assoc Dermatol* 2015;15:114-8.
39. Cachafeiro T, Escobar G, Maldonado G, Cestari T, Corleta O. Comparison of Nonablative Fractional Erbium Laser 1,340 nm and Microneedling for the Treatment of Atrophic Acne Scars: A Randomized Clinical Trial. *Dermatol Surg* 2016;42:232-41.
40. Kim SG, Whang JS, Shim EY, Choi JY, Yoon CJ. Treatment of Sequelae of Burn Injury with Microneedling Procedure (Dermastamp (R)). *J Korean Burn Soc* 2010;13:97-100.
41. Safonov I. Percutaneous collagen induction in correction of post-burn scars. *FACE Mag* 2011;1:34-7.
42. Costa IM, Costa MC. Microneedling for varicella scars in a dark-skinned teenager. *Dermatol Surg* 2014;40:333-4.
43. Lee SJ, Goo JW, Shin J, Chung WS, Kang JM, Kim YK, *et al.* Use of fractionated microneedle radiofrequency for the treatment of inflammatory acne vulgaris in 18 Korean patients. *Dermatol Surg* 2012;38:400-5.
44. Lee KR, Lee EG, Lee HJ, Yoon MS. Assessment of treatment efficacy and sebosuppressive effect of fractional radiofrequency microneedle on acne vulgaris. *Lasers Surg Med* 2013;45:639-47.
45. Kim ST, Lee KH, Sim HJ, Suh KS, Jang MS. Treatment of acne vulgaris with fractional radiofrequency microneedling. *J Dermatol* 2014;41:586-91.
46. Min S, Park SY, Yoon JY, Suh DH. Comparison of fractional microneedling radiofrequency and bipolar radiofrequency on acne and acne scar and investigation of mechanism: Comparative randomized controlled clinical trial. *Arch Dermatol Res* 2015;307:897-904.
47. Dhurat R, Sukesh M, Avhad G, Dandale A, Pal A, Pund P. A randomized evaluator blinded study of effect of microneedling in androgenic alopecia: A pilot study. *Int J Trichol* 2013;5:611.
48. Dhurat R, Mathapati S. Response to microneedling treatment in men with androgenic alopecia who failed to respond to conventional therapy. *Indian J Dermatol* 2015;60:260-3.
49. Farid CI, Abdelmaksoud RA. Platelet-rich plasma microneedling versus 5% topical minoxidil in the treatment of patterned hair loss. *J Egyptian Women's Dermatol Soc* 2016;13:29-36.
50. Chandrashekar B, Yepuri V, Mysore V. Alopecia areata-successful outcome with microneedling and triamcinolone acetonide. *J Cutan Aesthet Surg* 2014;7:63-64.
51. Fabbrocini G, De Vita V, Fardella N, Pastore F, Annunziata MC, Mauriello MC, *et al.* Skin needling to enhance depigmenting serum penetration in the treatment of melasma. *Plast Surg Int* 2011;2011:158241.
52. Budamakuntla L, Loganathan E, Suresh DH, Shanmugam S, Suryanarayan S, Dongare A, *et al.* A Randomised, Open-label, Comparative Study of Tranexamic Acid Microinjections and Tranexamic Acid with Microneedling in Patients with Melasma. *J Cutan Aesthet Surg* 2013;6:139-43.
53. Lima Ede A. Microneedling in facial recalcitrant melasma: Report of a series of 22 cases. *An Bras Dermatol* 2015;90:919-21.
54. Markantoni V, Kouris A, Vavouli C, Armyra K, Plerou N, Antoniou C, Kontochristopoulos G. Combination of microneedling and trichloroacetic acid 10% peels in the management of infraorbital dark circles. *J Am Acad Dermatol* 2015;72:15.
55. Kontochristopoulos G, Kouris A, Platsidaki E, Markantoni V, Gerodimou M, Antoniou C. Combination of microneedling and 10% trichloroacetic acid peels in the management of infraorbital dark circles. *J Cosmet Laser Ther* 2016;15:1-4.
56. Bencini PL, Galimberti MG, Pellacani G, Longo C. Application of photodynamic therapy combined with pre-illumination microneedling in the treatment of actinic keratosis in organ transplant recipients. *Br J Dermatol* 2012;167:1193-4.
57. Torezan L, Chaves Y, Niwa A, Sanches JA, Festa-Neto C, Szeimies RM. A Pilot Split-Face Study Comparing Conventional Methyl Aminolevulinate-Photodynamic Therapy (PDT) With Microneedling-Assisted PDT on Actinically Damaged Skin. *Dermatol Surg* 2013;39:1197-201.
58. Kim M, Shin JY, Lee J, Kim JY, Oh SH. Efficacy of fractional microneedle radiofrequency device in the treatment of primary axillary hyperhidrosis: A pilot study. *Dermatology* 2013;227:243-9.

59. Sanad EM, Aginaa HA, Sorour NE. Microneedling system alone versus microneedling system with trichloroacetic acid in the management of abdominal striae rubra: A clinical and histopathological study. *J Egyptian Women's Dermatol Soc* 2015;12:96-101.
60. Park SY, Min S, Suh DH. P102: Clinical and histological effect of fractional microneedling radiofrequency treatment on rosacea. Program book (formerly proceedings). 2015;67:439-40.
61. Seonguk MI, Park SY, Yoon JY, Kwon HH, Dae Hun SU. Fractional Microneedling Radiofrequency Treatment for Acne-related Post-inflammatory Erythema. *Acta Derm Venereol* 2016;96:87-91.
62. Oh JH, Park HH, Do KY, Han M, Hyun DH, Kim CG, *et al.* Influence of the delivery systems using a microneedle array on the permeation of a hydrophilic molecule, calcein. *Eur J Pharm Biopharm* 2008;69:1040-5.
63. Badran MM, Kuntsche J, Fahr A. Skin penetration enhancement by a microneedle device (Dermaroller®) *in vitro*: Dependency on needle size and applied formulation. *Eur J Pharm Sci* 2009;36:511-23.
64. Kolli CS. Microneedles: Bench to bedside. *Ther Deliv* 2015;6:1081-8.
65. Kim YC, Park JH, Prausnitz MR. Microneedles for drug and vaccine delivery. *Adv Drug Deliv Rev* 2012;64:1547-68.
66. Donnelly RF, Morrow DI, McCarron PA, Woolfson AD, Morrissey A, Juzenas P, *et al.* Microneedle-mediated intradermal delivery of 5-aminolevulinic acid: Potential for enhanced topical photodynamic therapy. *J Control Release* 2008;129:154-62.
67. Yadav S, Dogra S. A Cutaneous Reaction to Microneedling for Postacne Scarring Caused by Nickel Hypersensitivity. *Aesthet Surg J* 2016;36:168-70.
68. Pahwa M, Pahwa P, Zaheer A. "Tram track effect" after treatment of acne scars using a microneedling device. *Dermatol Surg* 2012;38 (7pt1):1107-8.
69. Chabri F, Bouris K, Jones T, Barrow D, Hann A, Allender C, *et al.* Microfabricated silicon microneedles for nonviral cutaneous gene delivery. *Br J Dermatol* 2004;150:869-77.