

# Angiodysplasias of the colon

DERRICK J POUNDER, R ROWLAND, AS PIETERSE, R FREEMAN,\* R HUNTER\*

*From the Institute of Medical and Veterinary Science, Frome Road, Adelaide, South Australia, and the \*Royal Adelaide Hospital, Adelaide, South Australia 5000*

**SUMMARY** We studied 14 large bowel resections from patients with a provisional clinical diagnosis of a bleeding vascular lesion of the colon. For the purpose of this study we developed a barium-gelatine vascular injection technique. Six of the 14 cases were proven to be angiodysplasias with an identifiable mucosal vascular ectasia. The pathological findings in these six cases are described. We conclude that angiodysplasias represent a significant cause of lower gastrointestinal haemorrhage in the elderly. It is our opinion that only the mucosal vascular ectasia seen in these cases is histologically diagnostic and that sub-mucosal venous ectasia, while characteristic of angiodysplasia, is non-specific. The differential diagnostic features which will allow the histological distinction of angiodysplasia from other vascular lesions of the colon are discussed.

Until recently, in the absence of haemorrhoids, severe lower gastrointestinal haemorrhage in the elderly was ascribed usually to diverticulosis. However, the use of selective superior mesenteric angiography has demonstrated that such bleeding in many cases is due to vascular ectasias, particularly involving the right colon. For these lesions the general term angiodysplasia was coined by Galdabini,<sup>1</sup> but the same lesions have been termed angiomias, haemangiomas, arteriovenous malformations and vascular ectasias by others.<sup>2</sup> We report experience of 14 cases who underwent bowel resection for clinically diagnosed bleeding vascular lesions.

## Material and methods

Between 1974 and 1981 14 large bowel resections were submitted to the Institute of Medical and Veterinary Science with a provisional diagnosis of a bleeding vascular lesion. The specimens were studied using a vascular injection technique which we developed for this purpose (see Appendix).

## Results

A summary of the clinical and angiographic findings together with the pathological findings and final diagnoses for the 14 cases studied is set out in Table 1.

Six of the cases were proven to be angiodysplasias

with an identifiable mucosal vascular ectasia. When viewed under the dissecting microscope, the mucosal aspect of the lesion in these cases had a characteristic "coral-reef" like appearance (Fig. 1). In a further two cases the histological findings were suggestive of angiodysplasia but not diagnostic in that ectatic submucosal veins were present but no mucosal lesion was identified. All the angiodysplasias were located in the caecum, their diameter varying from 3 to 10 mm. All were flat and showed varying degrees of attenuation of the mucosa, but none was ulcerated. The angiodysplasias were multiple in three cases.

The dominant histological feature in all six proven cases of angiodysplasia was the presence of dilated thin-walled vascular channels in the lamina propria of the mucosa (Fig. 2). No erosions were observed and there was no significant inflammation or fibrosis. In two cases there was recent intramucosal haemorrhage. No haemosiderin was identified but melanosis coli was present in two cases. Breaching of the muscularis mucosae by dilated venous channels was a prominent feature. In all cases, the submucosal veins appeared dilated and tortuous (Fig. 3). Their vessel walls were thin with a delicate media, and only minimal intimal sclerosis was present in three cases. In three cases clusters of thick-walled arterioles could be seen beneath the muscularis mucosae. Two small atheroemboli with a secondary inflammatory reaction were seen in one case (Fig. 2) and this patient also had aortic stenosis. The associated arteries in all six cases were neither tortuous nor dilated.

Table 1 Summary of findings and diagnoses in 14 cases

Case No	Age (yr)	Sex	Clinical findings	Angiographic diagnosis	Pathological findings	Stopped bleeding
1	69	M	Bleeding per rectum Aortic stenosis	Angiodysplasia	Angiodysplasia 3 lesions	Yes
2	63	M	Bleeding per rectum Aortic stenosis	Angiodysplasia	Angiodysplasia 4 lesions	Yes
3	64	F	Anaemia	Angiodysplasia	Angiodysplasia	Yes
4	69	F	Anaemia Systolic murmur	Angiodysplasia	Angiodysplasia 2 lesions	Yes
5	60	M	Bloody diarrhoea	Angiodysplasia	Angiodysplasia	Yes
6	77	M	Anaemia, Melaena Systolic murmur	Angiodysplasia	Angiodysplasia	Yes
7	68	M	Melaena	Suggestive of angiodysplasia	Dilated submucosal veins	Yes
8	81	F	Anaemia	Suggestive of angiodysplasia	Dilated submucosal veins	Yes
9	57	F	Anaemia	Suggestive of angiodysplasia	Nil (final diagnosis Osler's disease)	No
10	45	F	Bleeding per rectum	Actively bleeding lesion	Diverticulum of right colon	Yes
11	70	F	Bleeding per rectum	Arteriovenous malformation	Arteriovenous malformation	Died
12	78	F	Anaemia	Suspicious of angiodysplasia	Ischaemic colitis	No
13	57	F	Anaemia	Angiodysplasia	Carcinoma of caecum Lymphangiectasia	Yes
14	59	F	Anaemia	Angiodysplasia	Villous adenoma	Yes

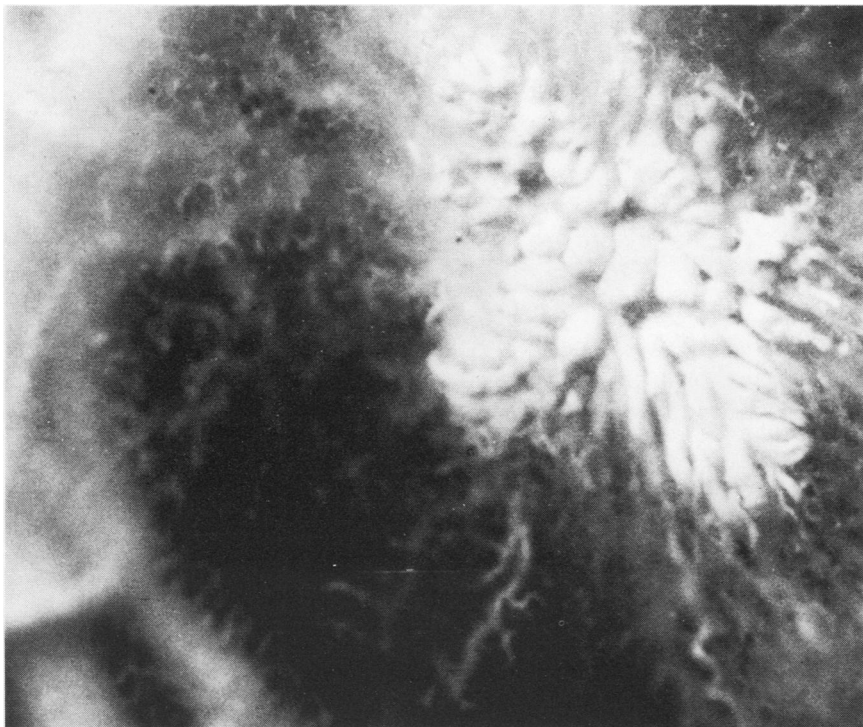
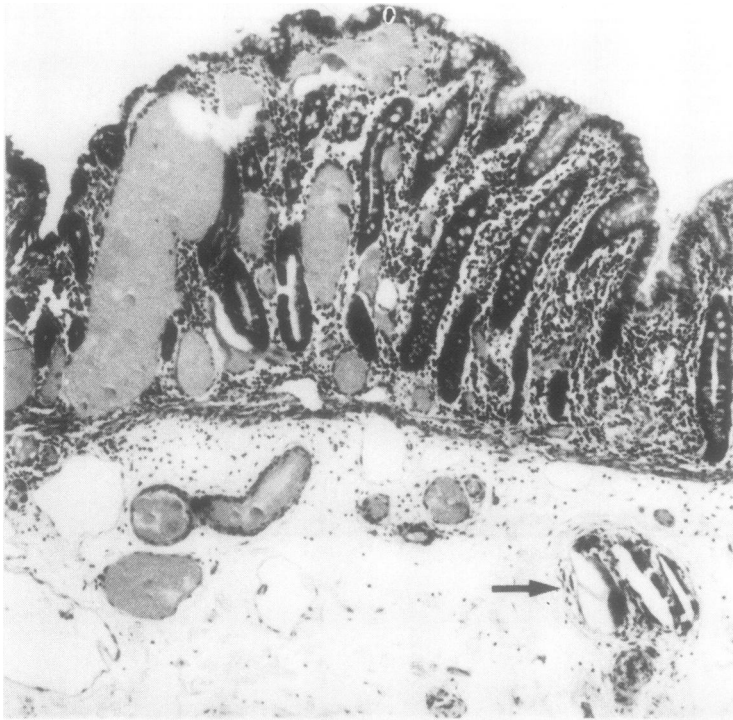
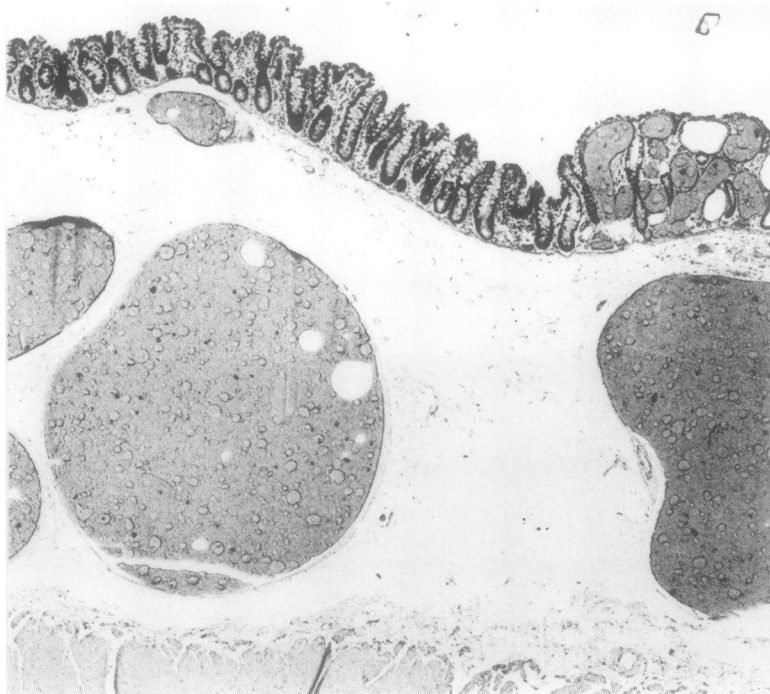

Fig. 1 Typical "coral-reef" appearance of angiodysplasia when a barium-gelatin-injected specimen is viewed under the dissecting microscope. Note the associated artery and ectatic vein on the left hand edge of the photograph  $\times 15$  (approx)



**Fig. 2** Ectatic mucosal blood vessels characteristic of angiodysplasia, filled by barium-gelatin. Note the cluster of associated submucosal arterioles and the lack of surface ulceration, inflammation or fibrosis. Submucosal atheroemboli are present (arrowed)  $\times 60$



**Fig. 3** Markedly ectatic submucosal vein draining an angiodysplasia  $\times 25$

## Discussion

The natural history of angiodysplasias is one of recurrent bleeding. Our cases are typical in their presentation with lower gastrointestinal haemorrhage and/or anaemia for investigation. The average age of the six cases was 67 yr, which is in keeping with a reported median age of 75 yr<sup>3</sup> and the concept that they are degenerative lesions.<sup>1,2</sup> In a review of 28 published cases, all except three were over 50 yr.<sup>4</sup> Only two of our patients were female, which contrasts with the view that there is a slight female preponderance overall.<sup>3</sup> Four of the six patients had cardiac systolic murmurs and two of these were thought to have aortic stenosis. The association of angiodysplasia with aortic stenosis has been previously described.<sup>3,5,6</sup> This association may reflect an increased liability of the angiodysplasias to bleed in patients with aortic stenosis as a result of the low perfusion pressure and consequent ischaemia,<sup>2</sup> and it has been suggested that the bleeding may be relieved by aortic valve replacement.<sup>7</sup>

Angiodysplasias are mucosal and submucosal vascular ectasias and do not involve the muscularis propria or serosa. The dominance of the mucosal component in our cases may reflect the small size of the lesions we have observed, as the submucosal changes are said to overshadow the mucosal changes in larger lesions.<sup>1</sup> We did not observe any mucosal erosions and there was no significant inflammation or fibrosis, an observation in keeping with the view that any fibrosis is secondary to ulceration.<sup>9</sup>

Breaching of the muscularis mucosae by dilated vessels is a feature often seen at the edge of a lesion and should prompt the examination of step sections through the block of tissue. The presence of clusters of thick-walled arterioles seen immediately beneath the muscularis mucosae is a feature said to be present near the centre of the lesion.<sup>1</sup> The association with atheroemboli has been observed by others and is not thought to be causative.<sup>1,3,8</sup> It may be a sequel of angiography since the clinical diagnosis is made typically by selective superior mesenteric angiography.

In keeping with all previously recorded cases, there was no involvement of the muscularis propria or serosa except that a prominent draining vein could sometimes be seen. It would appear that the prominent draining vein may be a non-specific feature since such a vein was also seen related to a villous adenoma in case 14. We did not observe the striking irregular intimal sclerosis of submucosal veins recorded by others.<sup>8</sup> Variations in the histopathological findings in cases of angiodysplasia may reflect stages in the evolution of the lesion,<sup>9</sup> but attempts at histological sub-classification<sup>4</sup> would

seem superfluous.

Although described under a variety of names, angiodysplasias are telangiectasias and consequently the normal honeycomb microvascular pattern of the mucosa is maintained.<sup>11</sup> The differential diagnosis of angiodysplasia includes other varieties of telangiectasias, arteriovenous malformations and haemangiomas. Mucosal lymphangiectasia superficially resembles angiodysplasia but the vessels did not contain blood or barium-gelatin and there is no associated submucosal venous ectasia.

Other causes of colonic telangiectasis include Osler-Weber-Rendu, Sturge-Weber and Bonnet-Dechaume-Blanc syndromes.<sup>12</sup> Of these, Osler-Weber-Rendu syndrome is most frequently associated with telangiectasias of the gastrointestinal tract; its distinction from angiodysplasia relies heavily on the other features of the syndrome, namely a family history, childhood epistaxis and telangiectasias of the oral mucosa and lips. Unlike angiodysplasias, the vascular abnormalities in this syndrome may implicate the muscularis propria and serosa of the bowel.<sup>13</sup> The colonic telangiectasias of Osler-Weber-Rendu syndrome are said to differ histologically from angiodysplasias in having a characteristic sclerotic stromal component.<sup>1</sup> However, stromal sclerosis has been a feature observed in some cases of angiodysplasia. At the present time it must be accepted that distinction of angiodysplasia from other colonic telangiectasias may not be possible on histological grounds alone. In the one case of Osler-Weber-Rendu syndrome in which we had the opportunity to examine the right colon, we were unable to identify a vascular lesion. The diagnosis was made later on clinical grounds, and bowel resection did not halt the gastrointestinal bleeding.

Congenital arteriovenous malformations differ from angiodysplasias in their diffuse infiltrative nature and the presence of abnormal vessels with histological features of both arteries and veins.<sup>4,9</sup>

Apart from their size and tortuosity, the abnormal vessels of angiodysplasias resemble normal veins, venules and capillaries.<sup>14</sup> By contrast, a haemangioma comprises a proliferation of abnormal vascular channels and lacks the organoid appearance of an angiodysplasia. Haemangiomas of the gastrointestinal tract<sup>12</sup> are usually cavernous rather than capillary, single rather than multiple, and most frequently are circumferential segmental lesions<sup>4,10</sup> rather than small focal lesions. They consist of large endothelial-lined and blood-filled sinuses separated by scanty connective tissue. Focal cavernous haemangiomas of the gastrointestinal tract may be associated with raised blue haemangiomas of the skin, the blue rubber-bleb naevus syndrome.<sup>15,16</sup> Bleeding gastrointestinal lesions are common in this

syndrome, and there is frequently a family history. We have not had the opportunity to study a haemangioma of the large bowel.

As might be expected in degenerative lesions associated with ageing, angiodyplasias are frequently multiple. Two or more lesions were found in half our cases, but have been reported in as many as 14 of 19 resections in another series.<sup>8</sup> In fact, colonic angiodyplasias probably are common in the elderly and in one study<sup>2</sup> were demonstrated in 8 of 15 colons resected for carcinoma in patients over 60 years. Consequently, in addition to recognising their importance as a source of lower gastrointestinal bleeding, it is also important to recognise the benign nature of angiodyplasias in the absence of bleeding. In our six proven and two probable cases of angiodyplasia the bleeding stopped after surgery and this was regarded as good corroborative evidence that the angiodyplasias were the source of the bleeding. As angiodyplasia is only a recently recognised entity there is only a short follow-up of patients in our and other series so that the long-term prognosis and incidence of rebleeding is unknown. A variety of surgical procedures have been advocated for angiodyplasia but the usual treatment, and the one used in all our cases, is a right hemicolectomy.

In conclusion, our series of cases demonstrates that angiodyplasias represent a significant cause of lower gastrointestinal haemorrhage in the elderly. The basic histopathological features of angiodyplasia have now been confirmed in several independent series, but the aetiology and pathogenesis of these vascular lesions remain speculative. It is our opinion that only the mucosal vascular ectasia is histologically diagnostic and that the submucosal venous ectasia, whilst characteristic, is non-specific. The differential diagnostic features which will allow the histological distinction of angiodyplasia from other telangiectasias of the gut require further characterisation.

### Acknowledgements

The development of this work resulted from the collaborative effort of the staff of the Royal Adelaide Hospital and the Institute of Medical and Veterinary Science. The staff of the Royal Adelaide Hospital gave permission to review the cases. The authors acknowledge with gratitude the help and encouragement of Professor B Vernon-Roberts.

### Appendix

#### DEMONSTRATION OF VASCULAR LESIONS OF THE BOWEL

This vascular injection method was developed to demonstrate colonic vascular lesions suspected on

clinical or radiological grounds, primarily as an aid to the identification of angiodyplasias. Without the aid of an injection technique, angiodyplasias frequently cannot be identified by the pathologist.

#### VASCULAR INJECTION TECHNIQUE

At operation the affected segment of bowel is resected, leaving it attached by the main vascular pedicle. The artery and vein in this pedicle are separately ligated and cannulated. Cannulae having the largest possible diameter should be used and securely tied in place. The arterial cannula is connected with an intravenous set containing 500 ml of heparinised saline and flushed quickly until the flow from the venous cannula is clear of blood. The saline is then reduced to a slow drip. The ties or clamps at the lines of resection of the specimen are left in place and the specimen is taken directly from the operating theatre to the Radiology Department.

Barium injection of the vessels of the specimen is performed under fluoroscopic control. All x-rays are taken on films large enough to include the whole segment of resected bowel. The bowel is positioned so that lesions identified preoperatively can be viewed to advantage. Using a 50 ml syringe, the artery is injected with the contrast medium. The contrast medium used is 5 g commercial gelatine and 50 g barium sulphate in 100 ml water heated to dissolve the gelatine and maintained at 40°C prior to injection. Firm, steady pressure is necessary but this will not produce artefacts so long as the vein is not occluded.<sup>2</sup> As the hot barium-gelatine mixture cools and sets quickly once it has penetrated the small vessels, the first injection is the most effective in filling these vessels. Having filled the arterial tree to a point where delineation of individual vessels is becoming obscured, the same process is repeated on the venous side. Care should be exercised not to overinject the vessels or create an overflow of contrast medium. Radiographs are taken after both the arterial and venous injections. Any vascular abnormalities identified in the radiographs are marked with tags on the serosal surface.

After injection the bowel lumen is washed out and filled with 10% formol saline solution until it is distended to its normal size. The open ends of the specimen can be conveniently closed with elastic bands. The inflated specimen is pinned to a corkboard and the board floated upside down in a formalin-filled tank overnight. After fixation for 24 h the bowel is opened lengthwise and the mucosal lesions are identified by careful examination with the aid of a hand lens and by checking against the radiographs. Suspicious areas may be examined under a dissecting microscope (Fig. 1). The appropriate areas are photographed and sectioned (Fig. 2).

## Discussion

This injection method for the demonstration of colonic angiodysplasias is reliable, cheap and simple and could be utilised in any routine surgical pathology laboratory. The method of silicone rubber injection previously described<sup>9</sup> is more time-consuming and expensive. It also suffers from the disadvantage that the specimen must be refrigerated at 4–5°C for 24 h to permit polymerisation of the silicone rubber.

Others have met with varying success using a barium-gelatine injection method.<sup>2,6,11,18,10</sup> Some consider it to be of no value in the accurate localisation of lesions for histological examination,<sup>11</sup> or that it reveals only the largest mucosal lesions,<sup>2</sup> whilst others recommended the method.<sup>6,18,10</sup>

These differing views are probably a result of differences in the technique used. Only one group<sup>10</sup> has injected the vessels under fluoroscopic control. By injecting the vessels in the fresh specimen under fluoroscopic control it is possible to take multiple x-rays at a time when any lesions present are optimally visualised. This method provides more information than x-rays taken following fixation of the injected specimen.<sup>6</sup> Prior flushing of the vessel with heparinised saline possibly allows visualisation of smaller lesions than might otherwise be identified. We have been able to demonstrate lesions as small as 3 mm diameter. Releasing the clamps at the lines of resection to wash out the bowel<sup>10</sup> and opening the bowel<sup>18</sup> before injecting the vessels are both likely to reduce the quality of angiograms by allowing free flow of contrast from cut vessels. We have not found it necessary to inflate the bowel with air<sup>6,10</sup> in order to display the angiographic findings to advantage, but we have filled the specimen with formalin after radiological examination as this leads to better fixation for subsequent histology and allows for easier macroscopic examination.

The method we have described allows the best possible combination of radiological demonstration of angiodysplasias, correlation with preoperative angiography, macroscopic visualisation and histological confirmation and would appear to be useful in the demonstration of other vascular lesions of the bowel.

## References

- <sup>1</sup> Athanasoulis CA, Galdabini JJ, Waltman AC, Novelline RA, Greenfield AJ, Ezpleta ML. Angiodysplasia of the colon: a cause of rectal bleeding. *Cardiovasc Radiol* 1978;1:3–13.
- <sup>2</sup> Boley SJ, Sammartano R, Adams A, Di Biase A, Kleinhaus S, Sprayregen S. On the nature and aetiology of vascular ectasias of the colon. Degenerative lesions of aging. *Gastroenterology* 1977;72:650–60.
- <sup>3</sup> Welch CE, Christos A, Athanasoulis CA, Galdabini JJ. Haemorrhage from the large bowel with special reference to angiodysplasia and diverticular disease. *World J Surg* 1978;2:73–83.
- <sup>4</sup> Moore JD, Thompson NW, Appelman HD, Foley D. Arteriovenous malformations of the gastrointestinal tract. *Arch Surg* 1976;111:381–9.
- <sup>5</sup> Baer JW, Ryan S. Analysis of caecal vasculature in the search for vascular malformations. *American Journal of Roentgenology* 1976;126:394–405.
- <sup>6</sup> Galloway SJ, Casarella WJ, Shimkin PM. Vascular malformations of the right colon as a cause of bleeding in patients with aortic stenosis. *Radiology* 1974;113:11–5.
- <sup>7</sup> Love JW, Jahnke EJ, Zacharias D, Davidson WA, Kidder WR, Luan LL. Calcific aortic stenosis and gastrointestinal bleeding. *N Engl J Med* 1980;302:968.
- <sup>8</sup> Mitsudo SM, Boley SJ, Brandt LJ, Montefusco CM, Sammartano RJ. Vascular ectasias of the right colon in the elderly: a distinct pathologic entity. *Hum Pathol* 1979;10:585–600.
- <sup>9</sup> Tarin D, Allison DJ, Modlin IM, Neale G. Diagnosis and management of obscure gastrointestinal bleeding. *Br Med J* 1978;ii:751–4.
- <sup>10</sup> Lewi HJE, Gledhill T, Gilmour HM, Buist TAS. Arteriovenous malformations of the intestine. *Surg Gynecol Obstet* 1979;149:712–6.
- <sup>11</sup> Griffiths JD. Extramural and intramural blood supply of colon. *Br Med J* 1961;i:323–6.
- <sup>12</sup> Abrahamson J, Shandling B. Intestinal haemangiomas in childhood and a syndrome for diagnosis: a collective review. *J Pediatr Surg* 1973;8:487–95.
- <sup>13</sup> Bird RM, Jaques WE. Vascular lesion of hereditary haemorrhagic telangiectasia. *N Engl J Med* 1959;260:597–9.
- <sup>14</sup> Scully RE, McNeely BU. Case records of the Massachusetts General Hospital (case 36—1974). *N Engl J Med* 1974;291:569–75.
- <sup>15</sup> Baker AL, Kahn PC, Binder SC, Patterson JF. Gastrointestinal bleeding due to blue rubber bleb naevus syndrome. A case diagnosed by angiography. *Gastroenterology* 1971;61:530–4.
- <sup>16</sup> Berlyne GM, Berlyne N. Anaemia due to "blue-rubber-bleb" naevus disease. *Lancet* 1960;ii:1275–7.
- <sup>17</sup> Shaff MI, Sacks I, Stein D, Horner J, Louw JH. Caecal angiodysplasia as a cause of chronic iron deficiency anaemia. A case report. *S Afr Med J* 1980;57:17–20.

Requests for reprints to: Dr Derrick J Pounder, Division of Tissue Pathology, Institute of Medical and Veterinary Science, Frome Road, Adelaide, SA 5000, Australia.