

Neutrophil granulocytic cell antigen defined by a monoclonal antibody—its distribution within normal haemic and non-haemic tissue

HW SCHIENLE, H STEIN,* W MÜLLER-RUCHHOLTZ

*From the Department of Immunology, University of Kiel, Brunswiker Str. 2-6, D-2300 Kiel, and the *Institute of Pathology, University of Kiel, Hospitalstr. 42, D-2300 Kiel, West Germany*

SUMMARY Monoclonal antibodies were raised against normal human bone marrow cells. One of the antibodies obtained, monoclonal antibody 3C4 (MA 3C4), the subject of this paper, was characterised by immunofluorescence studies with viable normal peripheral blood and bone marrow cells and by immunoperoxidase studies using paraffin sections. In bone marrow and peripheral blood MA 3C4 reacts selectively with cells of late neutrophilic granulopoiesis (myelocytes, metamyelocytes, and neutrophilic granulocytes). Cells of erythropoiesis, thrombopoiesis and lymphopoiesis are negative. In lymph node and spleen only neutrophils react with MA 3C4. In non-haemic tissue reactivity was seen with epithelial cells of a variety of different gland ducts. Thus the antigen detected by MA 3C4 can serve as a marker for neutrophil differentiation in normal haemopoiesis and as a marker for ductal epithelial cells of a variety of organs within non-haemic tissue. The antigen is formalin-resistant and can be detected in paraffin sections. The antibody thus appears to be a valuable reagent for both haematological research and for routine pathology.

Until recently antigens on granulocytes were described mainly by means of alloantibodies,¹⁻³ autoantibodies,⁴ and xenoantibodies.⁵ Alloantibodies were obtained mostly from multiparous mothers of children with neonatal neutropenia^{1,2} and from patients with chronic benign neutropenia³ (antigens: NA₁, NA₂, NB₁, Vaz, 9a). Autoantibodies were from patients with various diseases, mainly systemic lupus erythematosus.⁴ The autoantibodies recognised an antigen or antigens which were present only on granulocytes in blood-containing tissues. The antigen(s) did not belong to an alloantigenic system and were expressed on the granulocytes of every tested individual. Conventional xenogeneic antibodies⁵ were able to define a similar antigen or antigens. Antigen density increased with maturation within the granulocyte lineage.

An increasing number of antigens on cells are defined nowadays by monoclonal antibodies, though few exist for the myeloid series. Monoclonal antibodies defining granulocytic antigens include the following: MA OKM 1,⁶ which has been described as reacting with granulocytes as well as with mono-

cytes, MA Mo 1,⁷ which reacts with monocytes, granulocytes and null cells, a set of four monoclonal antibodies FMC 10-13,⁸ which are reported to react with neutrophils and eosinophils, a further monoclonal antibody, My 1,⁹ which reacts with peripheral blood granulocytes.

Characterisation of the specificity of monoclonal antibodies directed against blood cell antigens so far has been restricted to the haemopoietic system. In many cases no data are available concerning their reactivity with other, non-haemic tissues. It is important to test reactivity in other tissues because a monoclonal antibody that defines an antigen in haemopoiesis may either react or not react with cells of non-haemic tissues. In the second case the detected antigen could be called a classical differentiation antigen, in the first case the antigen could be called a differentiation antigen only in an operational sense.

Recently we developed monoclonal antibodies (MA) against normal human bone marrow cells. Three of the clones reacted specifically with neutrophil polymorphonuclear leucocytes. The reactivity of one of these monoclonal antibodies, termed MA 3C4, will be reported on here and emphasis will be put on the investigation of haemic and non-haemic

tissues and cells. The term differentiation antigen was found to be applicable to the antigen detected by our monoclonal antibody only in the operational sense described above. In addition to being a marker for late neutrophilic granulopoiesis the detected antigen can serve as a marker for ductal epithelial cells of a variety of organs.

Material and methods

HUMAN PERIPHERAL BLOOD GRANULOCYTES AND MONONUCLEAR CELLS

These were obtained from healthy volunteers by collecting blood into preservative-free heparin (10.0 u/ml) and by sedimenting on discontinuous density gradients (Ficoll-Urographin). A single step method with two different densities (1.076 and 1.096 g/ml) was used.¹⁰ Centrifugation was carried out at 400 g for 40 min. The first layer consisted of mononuclear cells, the second layer of polymorphonuclear cells. After aspiration with Pasteur pipettes the two layers were washed twice in washing medium (RPMI-1640, 10% bovine serum, containing 0.2% azide and 10.0 u/ml preservative-free heparin). These cells were used for indirect immunofluorescence.

NORMAL HUMAN BONE MARROW CELLS

These were prepared from spongiosa of tibial and femoral bone left over after orthopaedic surgery. First the spongiosa pieces were minced mechanically and then the cells were washed out by means of a Pasteur pipette with washing medium. Then suspended cells were separated from the spongiosa by pouring through a nylon mesh and through glass wool. Myelogram counts after May-Grünwald-Giemsa staining of cytocentrifuge smears essentially resembled myelogram counts given in the literature for marrow aspirates. The cell suspension was washed twice with washing medium and then fractionated in the same manner as described above for peripheral blood cells. The two distinct cell layers were washed twice with washing medium at 4°C and then used for indirect fluorescence. In addition the upper cell layer (density 1.076 g/ml) was used for immunising Balb/c mice. Viability of cells was 90%. The upper cell layer lacked erythrocytes and mature granulocytes. All other cellular constituents of normal human bone marrow were present. The lower cell layer (density 1.076–1.096 g/ml) also lacked erythrocytes; polymorphonuclear granulocytes predominated (\approx 30% of cells), while lymphoid cells, myelocytes and blast cells were still present but in smaller numbers and the other cellular constituents—for example, erythroid cells, megakaryocytes, plasma cells, etc., were present.

IMMUNISATION

An 8-week-old female Balb/c mouse was injected intraperitoneally with 2×10^7 viable normal human bone marrow cells suspended in PBS, then boosted 2, 4 and 6 wk later with the same preparation and quantity. Splenectomy was performed three days after the last immunisation.

HYBRIDISATION AND CLONING PROCEDURE

Hybridisation of spleen cells was done with P3X63Ag8-653 myeloma cells.^{11 12} Hybridisation for monoclonal antibody 3C4 was performed on 1 August 1980, cloning was done twice between August and October 1980 by limiting dilution.^{11 12} Clone 3C4 has been propagated since then in culture without change. Samples have been frozen in liquid nitrogen and thawed repeatedly.

ANTIBODY SCREENING

Mass screening was done with viable human bone marrow cells fixed with Poly-L-Lysin (Sigma No P 1886) to Terasaki-HLA-plates and indirect immunofluorescence was performed.

INDIRECT IMMUNOFLUORESCENCE (SLIDE TECHNIQUE)

The fine specificity of MA 3C4 was characterised by indirect immunofluorescence using the slide technique. Viable cells (2×10^6) were incubated with 200 μ l of undiluted supernatant (derived from a dense culture) at room temperature for 30 min. The supernatant contained 0.2% azide. Washing was performed twice with washing medium at 4°C. Centrifugation steps were carried out at 150 g for 3 min. Incubation with the second antibody (FITC-Gt-antimouse-IgG, Tago, California) was performed at 4°C for 30 min. Then the washing procedure was repeated three times. Cells were resuspended at a concentration of 1×10^6 ml in 100% bovine serum containing 10.0 U/ml preservative-free heparin and 0.2% azide. Cytocentrifuge slides were made and fixed with 100% methanol for 5 min and then stored at 4°C until examination. Slides were examined with a Zeiss IM 35 microscope equipped with fluorescence epi-illumination, selective filter combinations, phase-contrast optics and a Contax (Yashica) camera. Cell groups containing positive and negative cells were documented photographically with both FITC and phase-contrast photographs. Then the slides were stained with Giemsa. Cell groups were relocated by means of a Zeiss object finder (Zeiss No 462965). By comparison of corresponding photographs (FITC, phase contrast, and Giemsa stain photograph) fluorescence-positive and negative cells could be determined. An arbitrary scale for intensity of fluorescence was used ranging from

weakly to strongly positive (+, ++, +++, +++++). Negative controls never contained fluorescing cells and no unspecific Fc-binding of FITC-Gt-antimouse-IgG antibody and of monoclonal antibodies occurred. Controls with irrelevant high titred monoclonal antibodies from our laboratory were totally negative.

TISSUE SAMPLES AND IMMUNOSTAINING

Formalin-fixed and paraffin-embedded tissue samples were drawn from the files of the Department of Pathology. Paraffin sections were dewaxed and pretreated with fresh 0.1% trypsin solution.¹³ If necessary the sections were then incubated in methanol containing 1% (vol/vol) H₂O₂ for 30 min to block endogenous peroxidase. The sections were then incubated with 100–200 µl myeloma hybrid tissue culture supernatant. After 30 min at room temperature the slides were washed for 5 min in PBS-albumin (1%) and then incubated with peroxidase-conjugated rabbit anti-mouse IgG (DAKO, Copenhagen, Denmark) (1/10) for 30 min. The conjugate was absorbed with insolubilised human serum until the reactivity against human Ig was removed. After a brief wash in PBS-albumin sites of antibody binding were visualised by incubation in 0.05 M Tris-HCl buffer containing diaminobenzidine (Walter, Kiel, FRG) (0.6 mg/ml) and H₂O₂ (0.01%). After a brief wash in PBS-albumin, slides were counterstained with haemalum, dehydrated and mounted.

Results

Reactivity of MA 3C4 with normal peripheral blood

cells and normal human bone marrow cells as defined by indirect immunofluorescence

As summarised in Table 1 and shown in Figs 1 and 2 in peripheral blood MA 3C4 reacted only with neutrophilic granulocytes. Eosinophils, lymphocytes, monocytes and erythrocytes were negative.

The same was found with bone marrow cells (see Table 1 and Fig 3(a) and (b)). MA 3C4 only reacted with cells of the neutrophil lineage. Of the myelocytes per sample, 10–40% (depending on the sample of bone marrow) stained weakly (+). Maximum reactivity was reached with band and neutrophil polymorphonuclear cells. In this population 95–100% of cells reacted very strongly (++++). All other cells including blast cells, promyelocytes, eosinophils, monocytes, lymphoid cells, erythroid cells and megakaryocytes were negative. Reactivity of basophils could not be determined because too few cells were observed for evaluation.

Reactivity of MA 3C4 with normal haemic and non-haemic tissue as defined by immunoperoxidase staining of paraffin sections

As summarised in Table 2 and shown in Figs 4–10, MA 3C4 reacted with granulocytes present in the tissues tested. In spleen for example myeloid cells located around the Malpighian corpuscles reacted with MA 3C4. Not only the cell surface but also the cytoplasm reacted strongly. One other group of cells present in different organs reacted with MA 3C4: epithelial cells of the crypts of the tubular glands of the colon (apical membrane +) and luminal epithelial cells of the colon (apical membrane +), mucoid cells of the crypts of the gastric glands (intracellularly and at the apical surface membrane +),

Table 1 Reactivity of MA 3C4 with normal peripheral blood cells and normal human bone marrow cells as defined by indirect immunofluorescence

Cell	Reactivity	Remarks
<i>Peripheral blood</i>		
Neutrophilic granulocytes	++++	95–100% of cells per sample
Eosinophilic granulocytes, monocytes, lymphocytes, erythrocytes	–	
Basophilic granulocytes	?	not determined
<i>Bone marrow</i>		
Blasts	–	
Promyelocytes	–	
Neutrophilic myelocytes	+	approx. 10–40% of cells per sample depending on sample obtained
Neutrophilic band cells	+++	95–100% of cells per sample
Neutrophilic polymorphonuclear cells	++++	
Eosinophilic cells	–	
Cells of lymphoid lineage	–	
Cells of erythroid lineage	–	
Megakaryocytes	–	
Basophilic cells	?	not determined
Plasma cells	–	

The degree of fluorescence has been arbitrarily expressed ranging from + to +++++. Microphotograph series from more than 20 different normal bone marrow samples have been used.

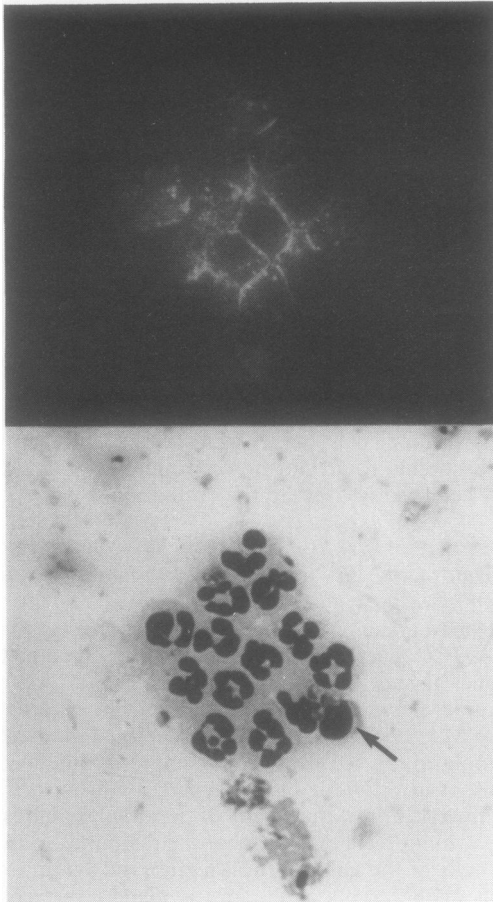


Fig. 1 Granulocyte cell preparation from peripheral blood. All granulocytes are MA 3C4 positive. The contaminating lymphocyte (arrow) is negative. $\times 625$

epithelial cells of the duct systems in the pancreas, parotid and submandibular gland (intracellularly ++), mid-apical portion of prismatic epithelial cells of the bile ducts in the liver (+), epithelial cells of the gall bladder (+), surface layer cells of the transitional epithelium of the renal calyces (++) , epithelial cells of the thin portion of Henle's loop (++) , epithelial cells of the proximal and distal convoluted tubules of the nephron (+), epithelial cells of efferential and epididymal ducts (apical portion ++), and epithelial cells of the ducts of the mammary gland (+). Epithelial cells of hypophyseal and adrenal gland and all placental cells were negative. Connective tissue in every organ was negative.

Discussion

These results show that the antigen reactive with

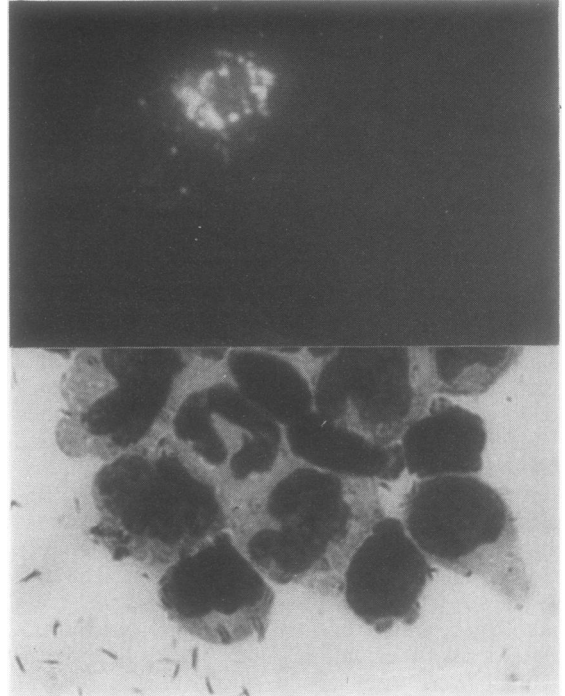


Fig. 2 Mononuclear cell preparation from peripheral blood. Only the contaminating granulocyte is MA 3C4-positive. Lymphocytes and monocytes are negative. $\times 875$

MA 3C4 may be operationally considered to be a differentiation antigen for the neutrophilic series in haemopoiesis. The antigen is present intracellularly in cells of late neutrophilic granulopoiesis as shown by the immunoperoxidase technique, and is membrane-bound extracellularly, as shown best by indirect immunofluorescence using living cells. Our results fit very well with the present knowledge of cellular events in haemopoiesis. According to the literature, granulocyte-monocyte colony-forming-units in culture (GMCFU-c) and eosinophil progenitor cells (EO-CFC) emerge out of a stem cell pool. GMCFU-c give rise to the neutrophil and to the monocyte lineage of cells, and EO-CFC give rise to the eosinophilic lineage of cells.^{14 15} The 3C4 antigen is expressed only by the neutrophil lineage. Interestingly enough, appropriately absorbed rabbit antihuman granulocyte antiserum also reacts with neutrophil granulocytes but excludes eosinophils from its reactivity pattern.⁵ Furthermore, alloantisera from multiparous women in conjunction with neonatal neutropenia are specific for neutrophils and also exclude eosinophils.^{1 2} In view of the opinion that basophil progenitor cells are a separate entity from GMCFU-c and EO-CFC¹⁶ it will be of

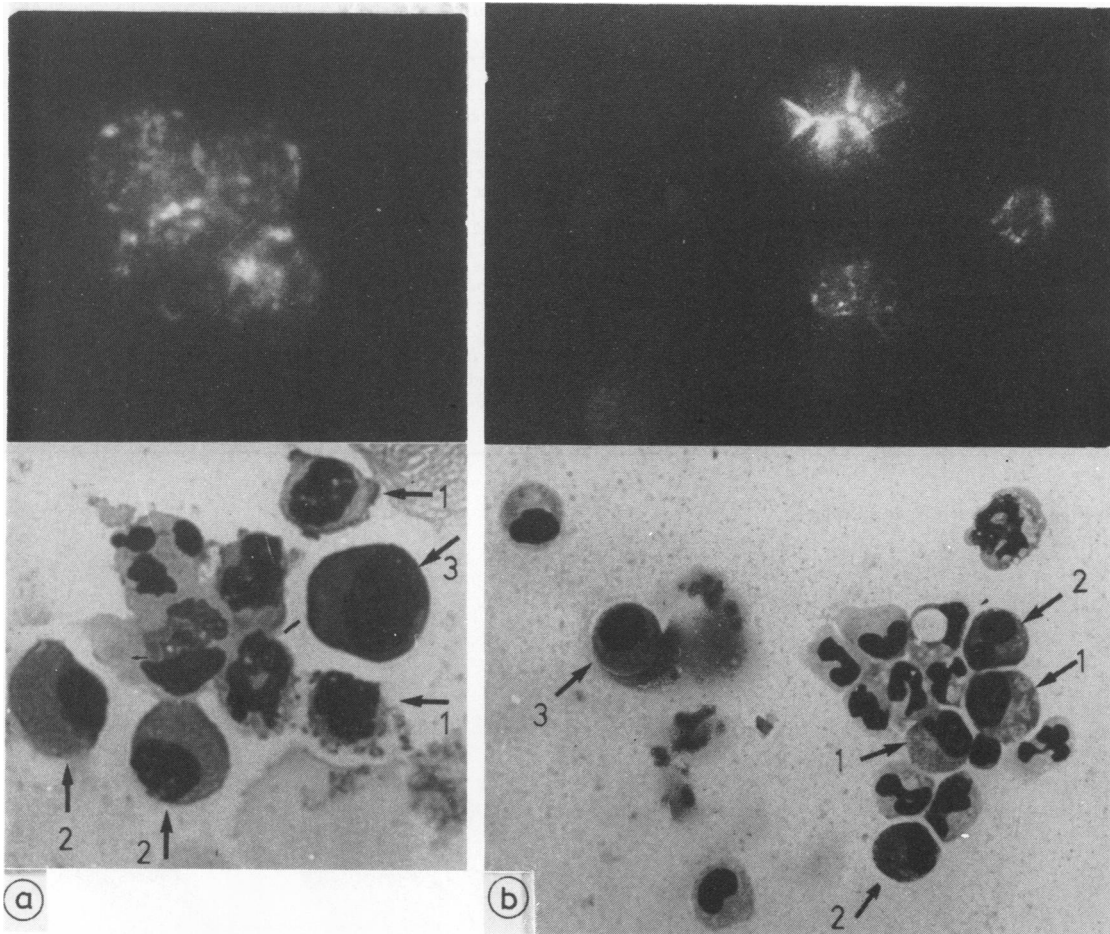


Fig. 3(a) and (b) Normal bone marrow cell preparation (density 1.076–1.096 g/ml, Ficoll-Urographin). Granulocytes are MA 3C4-positive. (a) lymphoid cells (arrow, 1), immature eosinophils (arrow, 2), and erythropoiesis cells (arrow, 3) are negative. $\times 875$. (b) immature myeloid cells (arrow, 1), mature eosinophils (arrow, 2), and erythropoiesis cell (arrow, 3) are negative. $\times 625$

Figs 1–3 Indirect immunofluorescence with MA 3C4. FITC microphotograph and corresponding Giemsa stain microphotograph are combined.

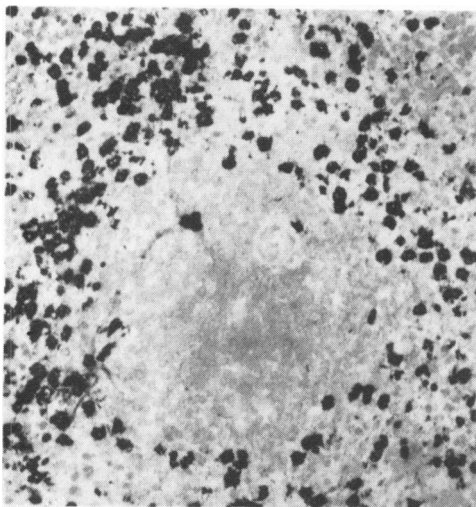


Fig. 4 Spleen: MA 3C4-positive granulocytes are located around the Malpighian corpuscles. $\times 150$

Table 2 Reactivity of MA 3C4 with normal haemic and non-haemic tissue as defined by immunoperoxidase staining of paraffin sections from routine pathology specimens

<i>Tissue</i>	<i>Positive cells</i>
Spleen	Neutrophils located around the Malpighian corpuscles (++)
Lymph nodes	No positive cells except a few neutrophils*
Stomach	Mucoid cells of the crypts of the gastric glands (intracellularly and at the apical surface membrane +)
Colon	Epithelial cells of the crypts of the tubular glands and luminal epithelial cells (apical membrane +)
Pancreas, parotid and submandibular gland	Epithelial cells of the duct systems (intracellularly ++)
Adrenal and hypophyseal gland	No positive cells
Mammary gland	Epithelial cells of the mammary gland ducts (+)
Liver	Globule like distribution of the antigen in the mid-apical region of the epithelial cells of the bile ducts (+)
Gall bladder	Epithelial cells (+)
Kidney	Surface layer cells of the transitional epithelium of the renal calyces (++) Tubular cells of the thin portion of Henle's loop (++) Cells of proximal and distal convoluted tubules of the nephron (+) Epithelial cells of efferential and epididymal ducts (++)
Epididymis	} No positive cells
Lung/skin/placenta	
Connective tissue of all tested organs	

+ = weak staining

++ = strong staining

*Neutrophils were positive in all tissues

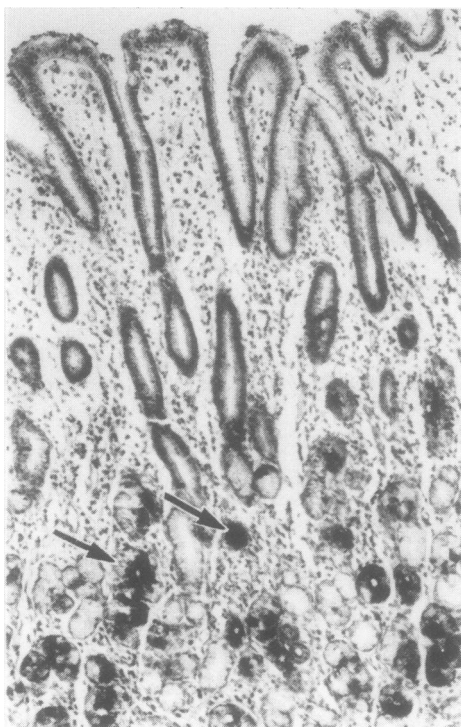


Fig. 5 Stomach: MA 3C4-positive mucoid cells in the crypts of the gastric glands, arrow. $\times 150$

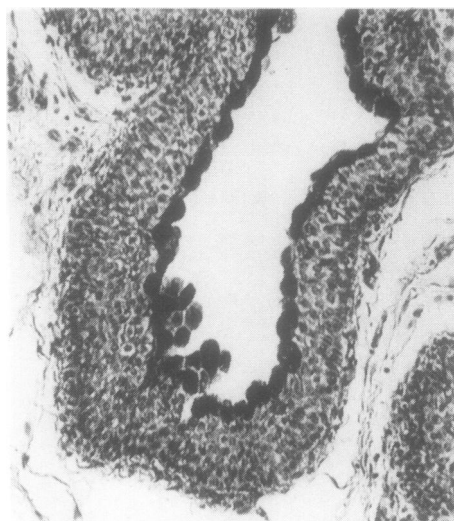


Fig. 6 Kidney: MA 3C4-positive surface layer cells of the transitional epithelium of the renal calyces. $\times 150$

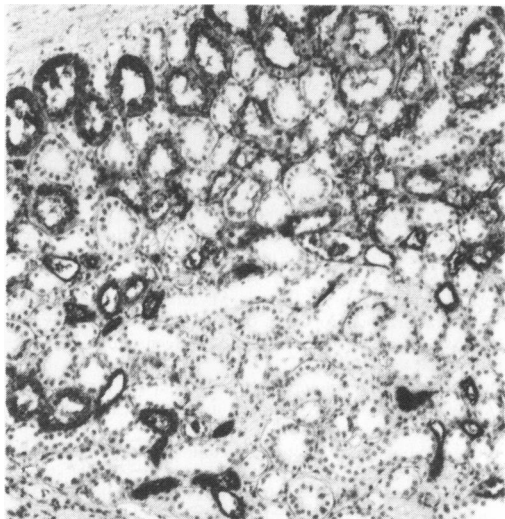


Fig. 7 *Kidney: MA 3C4-positive tubular cells of the thin portion of Henle's loop. × 150*

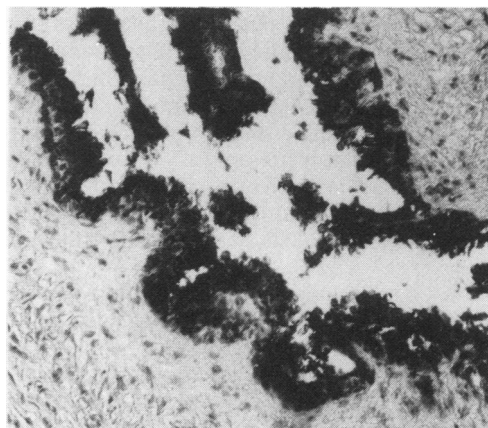

Fig. 8 *Epididymis: MA 3C4-positive epithelial cells of efferential duct. × 150*

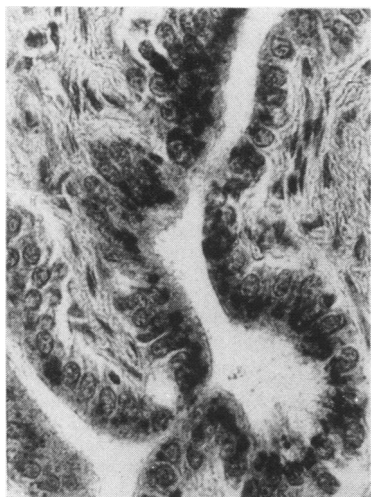

Fig. 9 *Liver: Globule like distribution of antigen reactive with MA 3C4 in the mid-apical portion of the epithelial cells of the bile ducts. × 325*

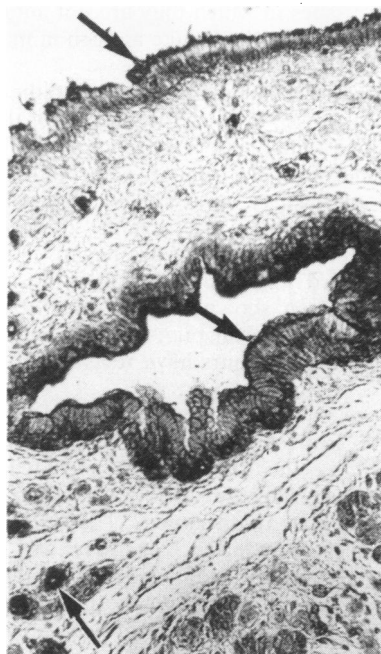


Fig. 10 *Pancreas: MA 3C4-positive epithelial cells in the very small duct radicles as well as in the big excretory ducts (arrows). × 150*

Figs 4-10 *Indirect immunoperoxidase stain with MA 3C4. Haemalum counterstain. Paraffin sections.*

interest to test basophils selectively and see if the specificity for neutrophils still holds true.

To our knowledge tissue distribution studies, as have been done with the Ia-like antigen¹⁷ and HLA-class-1 antigens,¹⁸ have not yet been reported with granulocyte-specific antigens. A look at the distribution of the 3C4 antigen in normal human tissues shows that the antigen is present in the epithel-

ial cells of tubules and ducts of a variety of organs. The quantity of the reaction products after 3C4 incubation and immunoperoxidase staining, however, varies. There are organs where the reaction is as strong in epithelial cells as it is in granulocytes (epithelial cells of renal calyces, Henle's loop, epididymal duct, ducts of pancreas and submandibular and parotid gland). In other epithelial cells

the reaction is distinct but weak (bile ducts of the liver, crypt cells of colonic tubular glands and gastric glands). These findings may indicate either that the same antigen is present in neutrophils and in certain epithelial cells or that a similar epitope belonging to different molecules is present (as observed with one MA directed against glycophorin,¹⁹) or that there is a cross-reaction with antigen(s) of similar antigenicity. Only biochemical studies can answer this question.

It must be concluded that the antigen detected by MA 3C4 can serve as a marker for neutrophil differentiation in haemopoiesis and as a marker for ductal epithelial cells of a variety of organs in non-haemic tissue. The MA 3C4 may indicate a common metabolic property of these different cell types. Similar to the 3C4 antigen many more antigens which were first thought to be haemopoietic differentiation antigens may well be found to be also present in tissues in which they are not anticipated. Good examples are the Ia-like antigen in man^{17 20 21} and the CALL antigen.²²

In spite of its reactivity with ductal epithelial cells MA 3C4 may become a useful reagent for the study of normal and malignant haemopoietic differentiation. Furthermore the role of neutrophils in lymphoid neoplasia may be evaluated, especially since all lymphoid elements, macrophages, interdigitating and dendritic reticulum cells are negative. The MA can be applied in routine pathology because the antigen has been shown to be formalin-resistant, and immunohistological pilot studies with paraffin sections of solid tumours have revealed interesting results.

We thank Professor Dr Blauth, Department of Orthopaedics, University of Kiel, and Dr Lubinus, Surgical Clinic, Kiel, for kindly providing us with human bone marrow specimens. The skilful technical assistance of Marion von Pein and Kirsten Tiemann is gratefully acknowledged. We thank Mrs Katherine Dege for help with the manuscript. The work was supported by Deutsche Forschungsgemeinschaft SFB 111/D8/D12.

References

- ¹ Lalezari P, Radel E. Neutrophil specific antigens: immunology and clinical significance. *Semin Hematol* 1974;11:281-90.
- ² Lalezari P, Thalenfeld B, Weinstein WJ. The third neutrophil antigen. In: Terasaki PI, ed. *Histocompatibility testing* Munksgaard, Copenhagen: 1970, 319-22.
- ³ Claas FHJ, Langerak J, Sabbe LJM, van Rood JJ. NE 1: a new neutrophil specific antigen. *Tissue antigens* 1979;13:129-34.
- ⁴ Drew SI, Terasaki PI. Autoimmune cytotoxic granulocyte antibodies in normal persons and various diseases. *Blood* 1978;52:941-52.
- ⁵ Jäger G, Hoffman-Fezer G, Rodt H, Huhn D, Thiel E, Thierfelder S. Myeloid antigens and antigen densities in mice and men. In: Thierfelder S, Rodt H, Thiel E, eds. *Immunological diagnosis of leukemias and lymphomas*. Berlin, Heidelberg, New York: Springer, 1977, 109-116.
- ⁶ Breard J, Reinherz EL, Kung PC, Goldstein G, Schlossman SF. A monoclonal antibody reactive with human peripheral blood monocytes. *J Immunol* 1980;124:1943-8.
- ⁷ Todd RF, Nadler LM, Schlossman SF. Antigens on human monocytes identified by monoclonal antibodies. *J Immunol* 1981;126:1435-42.
- ⁸ Zola H, McNamara P, Thomas M, Smart IJ, Bradley J. The preparation and properties of monoclonal antibodies against human granulocyte membrane antigens. *Br J Haematol* 1981;48:481-90.
- ⁹ Civin CI, Mirro J, Banquerigo ML. My-1, a new myeloid-specific antigen identified by a mouse monoclonal antibody. *Blood* 1981;57:842-5.
- ¹⁰ Aguado MT, Pujol N, Rubiol E, Tura M, Celada A. Separation of granulocytes from peripheral blood in a single step using discontinuous density gradients of Ficoll-Urographin. A comparative study with separation by dextran. *J Immunol Methods* 1980;32:41-50.
- ¹¹ Köhler G, Milstein C. Continuous cultures of fused cells secreting antibody of predefined specificity. *Nature* 1975;256:495-7.
- ¹² Lemke H, Hämmerling GJ, Höhmann C, Rajewski K. Hybrid cell line secreting monoclonal antibody specific for histocompatibility antigens of the mouse. *Nature* 1978;271:245-50.
- ¹³ Mephram BL, Frater W, Mitchell BS. The use of proteolytic enzymes to improve immunoglobulin staining by the PAP technique. *Histochem J* 1979;11:345-57.
- ¹⁴ Verma DS, Spitzer G, Zander AR, Fisher R, McCredie KB, Dicke KA. The myeloid progenitor cell: a parallel study of subpopulations in human marrow and peripheral blood. *Exp Hematol* 1980;8:32-43.
- ¹⁵ Weller PF, Goetzel EJ. The human eosinophil: roles in host defense and tissue injury. *Am J Pathol* 1980;100:793-820.
- ¹⁶ Zucker-Franklin D. Ultrastructural evidence for the common origin of human mast cells and basophils. *Blood* 1980;56:534-40.
- ¹⁷ Natali PG, DeMartino C, Quaranta V, et al. Expression of Ia-like antigens in normal human nonlymphoid tissues. *Transplantation* 1981;31:75-8.
- ¹⁸ Fleming KA, McMichael A, Morton JA, Woods J, McGee Jo'D. Distribution of HLA class I antigens in normal human tissue and in mammary cancer. *J Clin Pathol* 1981;34:779-84.
- ¹⁹ Edwards PAW. Monoclonal antibodies that bind to the human erythrocyte-membrane glycoproteins glycophorin A and band 3. *Biochem Soc Trans* 1980;8:334-5.
- ²⁰ Lalezari P. Organspecific and systemic alloantigens: interrelationships and biologic implications. *Transplant Proc* 1980;12:12-21.
- ²¹ Winchester RJ, Kunkel HG. The human Ia system. *Adv Immunol* 1979;28:221-92.
- ²² Metzgar RS, Borowitz MJ, Jones NH, Dowell BL. Distribution of common acute lymphoblastic leukemia antigen in nonhemopoietic tissues. *J Exp Med* 1981;154:1249-54.

Requests for reprints to: Professor Dr W Müller-Ruchholtz, Department of Immunology, University of Kiel, Brunswiker Str. 2-6, D-2300 Kiel, FRG.