

## Jejunal crypt cell abnormalities associated with methotrexate treatment in children with acute lymphoblastic leukaemia

CR PINKERTON, CHS CAMERON, JMSLOAN, JFT GLASGOW, NJT GWEVAVA

*From the Departments of Child Health and Pathology, Institute of Clinical Science, Grosvenor Road, Belfast BT12 6BJ*

**SUMMARY** Jejunal mucosal crypts were examined in jejunal biopsies from eight children with acute lymphoblastic leukaemia who had recently received methotrexate treatment. By comparison with biopsies from children under investigation for suspected malabsorption crypt mitosis was significantly reduced and showed a negative correlation with the dose of methotrexate given prior to biopsy. The three major cell types were studied under light and transmission electron microscopy. Gut endocrine cells were unaffected by therapy and immature crypt enterocytes showed only patchy degenerative abnormalities. By contrast a number of Paneth cells showed striking structural alterations with vacuolar dilatation of the cytoplasm. The extent of this correlated with the time since methotrexate treatment rather than its dose and may have been a functional response rather than of a toxic nature.

Methotrexate (MTX) plays an important role in the maintenance of disease remission in children with acute lymphoblastic leukaemia (ALL). The enterotoxic effect of the folate antagonists was recognised in the experimental animal prior to its clinical use<sup>1</sup> and was an important limiting factor in early treatment schedules.<sup>2</sup> In addition to a direct toxic effect upon mature enterocytes,<sup>3,4</sup> MTX may also produce villus abnormalities indirectly by interference with cell generation in the crypts. Blocked mitotic activity was a consistent feature in animal studies<sup>5,6</sup> and has been described in jejunal biopsies after a single intravenous dose of MTX in adults with psoriasis.<sup>3</sup> Apart from these observations the influence of MTX on individual cell populations in the small intestinal crypt has not been previously studied in detail. Jejunal biopsies from children with ALL were examined under light and electron microscopy and the morphological features of the major cell types are described.

### **Patients and methods**

Thirteen jejunal biopsies were studied; eight were from children with ALL receiving MTX treatment, whose ages ranged from 2.6 to 12.5 yr and five were

from patients being investigated for diarrhoea and/or failure to thrive (control group) that were subsequently found to be normal. The children with ALL were receiving treatment according to the Medical Research Council's Working Party on Childhood Leukaemia (UKALL trials). The duration of therapy was 3 to 52 months. At biopsy all were in clinical remission as determined by peripheral blood and bone marrow examination and in a good nutritional state; none had clinical alimentary toxicity nor biochemical evidence of folate deficiency. They had received oral MTX (15 mg/m<sup>2</sup>) but the number of doses and their precise timing in relation to jejunal biopsy varied (Table).

After an overnight fast pentobarbitone was administered and one hour later, in conjunction with bone marrow aspiration, jejunal biopsy was carried out. Biopsy technique was as previously described using a Crosby Kugler Paediatric capsule.<sup>7</sup> The specimen, taken close to the ligament of Treitz, was orientated under a Wild stereomicroscope and divided in two for both light and transmission electron microscopy. Biopsies were taken as part of a study of small intestinal structure and function associated with cytotoxic therapy, in relation to drug malabsorption and its implications in therapeutic response. The protocol was approved by the Ethical Committee of the Faculty of Medicine of this University.

## Incidence of Paneth cell and immature enterocyte abnormalities and crypt mitotic counts in patients treated with MTX and controls

	Patient	MTX doses prior to biopsy (h)				Paneth cells		Immature enterocytes		Mitotic count (per 100 cells)
		72	48	24	3	No	Abnormal %	No	Abnormal %	
ALL	1	*	*	*		29	34	72	10	0
	2	*	*	*	*	34	23	67	0	0
	3	*				27	44	110	22	1.0
	4			*	*	28	11	148	0	0.4
	5			*	*	22	14	73	1	0.4
	6				*	26	4	66	0	0.3
	7				*	42	15	220	1	0.5
	8				*	67	8	353	2	1.9
Controls	1					9	0	40	0	2.5
	2					32	0	127	0	1.3
	3					15	0	54	0	2.0
	4					11	0	230	0	3.4
	5					14	0	135	0	2.0

## HISTOPATHOLOGY

One portion of each specimen was fixed in Susa solution overnight and embedded in paraffin wax. Routine sections were stained by the Feulgen reaction for the purpose of counting mitotic figures. The remainder of the tissue was placed for 4 h in modified Karnovsky's fixative containing 2% paraformaldehyde in 0.1 M phosphate buffer, pH 7.4. After rinsing overnight in buffer, specimens were post fixed in S-collidine buffered osmium tetroxide for 2 h. Following ethanol dehydration the tissue was passed through propylene oxide and embedded in Spur resin. One micron thick sections cut from the blocks were stained with toluidine blue. Ultrathin sections (50–80 nm) were cut from selected areas of the block and mounted on copper grids before staining with uranyl acetate and lead citrate. The sections were examined using an AEI EM 801 transmission electron microscope.

## MITOTIC INDEX

In the Feulgen-stained sections the number of mitotic figures present in vertically sectioned crypts were counted. This was expressed as a percentage of the total number of cells in that particular crypt section.

## CRYPT CELL MORPHOLOGY

In the toluidine blue stained semithin sections cell type and morphology were clearly defined. Only cells of the basal region of the crypts, the "Paneth cell zone", were studied and either vertical or transverse sections in which Paneth cells could be identified were included. The extent of morphological change was expressed as the number of abnormal cells (%) in relation to the total number of that particular cell type present within the zone.

## Results

A reduction in mitotic index was evident within three hours of a single dose of MTX and was most marked in those who had received four doses prior to biopsy (Table & Fig. 1). There was a significant negative correlation between the number of mitotic figures and the cumulative dose of MTX given in the 72 h prior to jejunal biopsy ( $r_s = 0.85$ ,  $p < 0.01$  Spearman rank correlation). The number of crypt mitoses in the

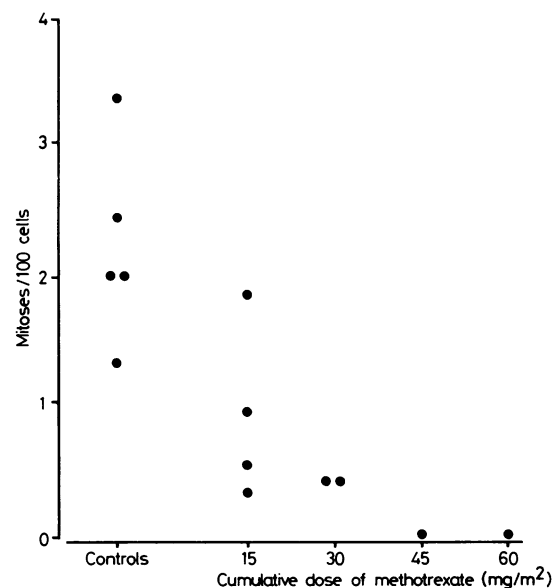


Fig. 1 Jejunal crypt mitotic counts in relation to the cumulative dose of methotrexate given prior to biopsy

treated group was also significantly lower than in the control group. ( $p < 0.001$ , Mann-Whitney U test).

Under light microscopy the three main cell types showed characteristic features. Immature enterocytes were slim and columnar with homogeneous cytoplasm and basal nuclei. Paneth cells were readily identified by their dark blue staining secretory granules and rounded central nuclei. Endocrine cells were elliptical with fine granular cytoplasmic inclusions.

In the MTX-treated cases degenerative changes were evident in a number of immature enterocytes with varying degrees of intracellular vacuolation and in some cases complete degeneration and loss of cytoplasmic structure. These changes were however of patchy distribution and seen in a minority of crypts even after four doses of MTX (Table & Fig. 2). Under electron microscopy the majority appeared normal with maintenance of intercellular junctions and contact with the basement membrane (Fig. 3). Degenerative changes were not present in control biopsies. Endocrine cells appeared to be unaltered in treated cases and did not differ from those in control biopsies. (Fig. 4).

Paneth cells after MTX showed the most marked

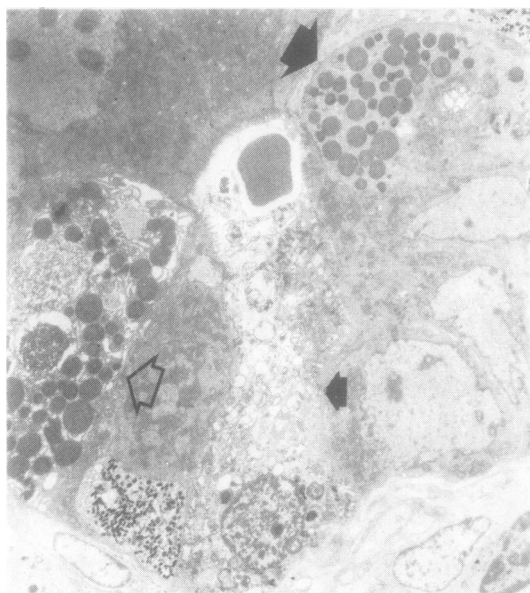


Fig. 2 Patchy crypt cell abnormalities. With the exception of a single necrotic cell (smaller black arrow) immature enterocytes appear to be normal. A normal Paneth cell with homogeneous cytoplasm and distinct secretory granules is present (larger black arrow) by contrast to another with cytoplasmic vacuolation (open arrow). Case 2,  $\times 2500$

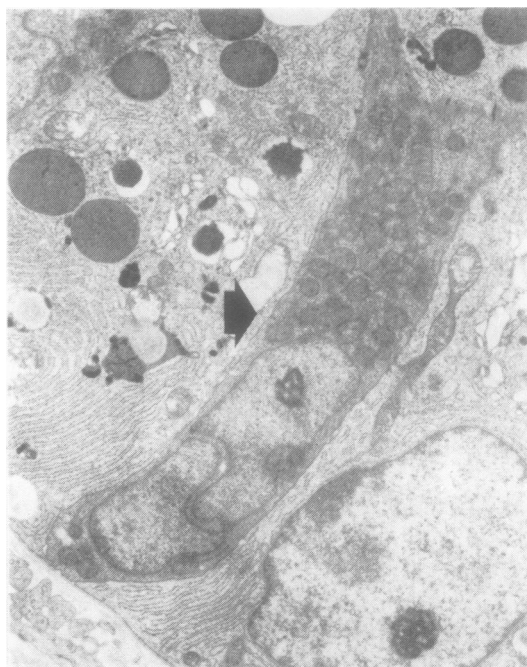
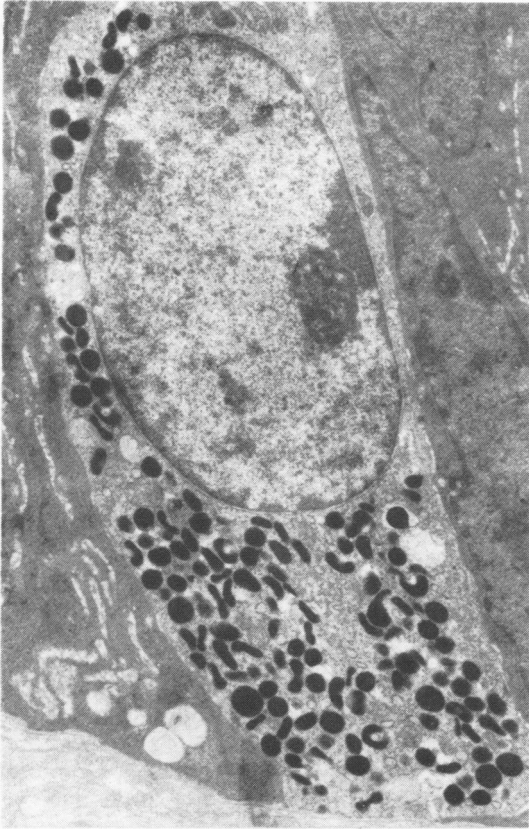


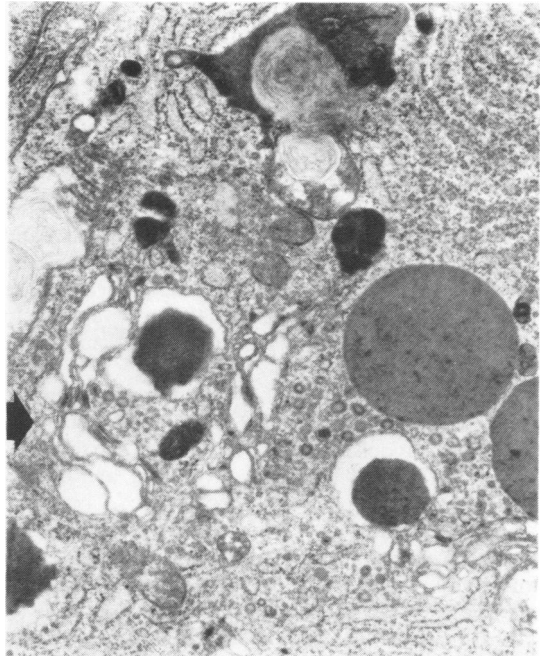
Fig. 3 Immature crypt enterocyte (arrow) unaffected by methotrexate therapy. The characteristic bilobed nucleus is seen and normal intercellular contact is maintained with two adjacent Paneth cells. Case 6,  $\times 5250$

structural alterations by comparison with untreated cases. A varying degree of intracellular vacuolation was evident which in some cases was minimal but in others was marked and almost completely replaced the cytoplasm. Under electron microscopy it appeared that this vacuolation arose in the Golgi and in some cells extended to the endoplasmic reticulum (Fig. 5). Where the changes were not extensive there was preservation of cytoplasmic organelles such as the mitochondria. In cells with marked vacuolation mitochondria were swollen, nuclei indented and only strands of residual endoplasmic reticulum remained (Fig. 6). Although a minor degree of Golgi dilatation was seen in some of the control biopsies in no case were the alterations as extensive as after MTX. Frank necrosis of Paneth cells was not a prominent feature of treated cases. While there was some deformation of secretory granules where vacuolation was marked the homogeneity of these structures was in general well preserved (Fig. 6).

Although the number of crypts studied was small there was a significant correlation between the incidence of Paneth cells with extensive vacuolation and the time since the first dose of MTX ( $r_s = 0.93$   $p < 0.01$  Spearman rank correlation).

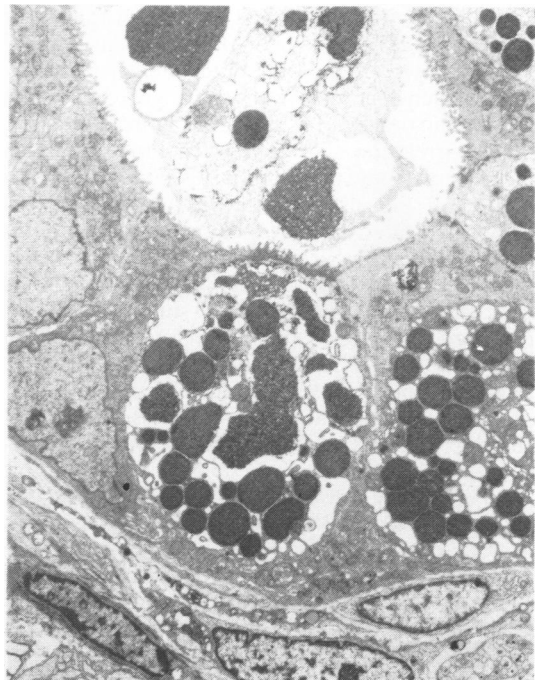

**Fig. 4** Normal gut endocrine cell with homogeneous cytoplasm and fine granular inclusions. Case 3,  $\times 7250$



**Fig. 5** Early dilatation of the Golgi (arrow at far left) three hours after methotrexate therapy. Secretory granules and rough endoplasmic reticulum appear normal. Case 6,  $\times 13250$

**Fig. 6** Marked vacuolation of Paneth cell cytoplasm 72 h after a single dose of methotrexate. Secretory granule structure is well maintained but the nucleus of one cell is shrunken and indented. Normal immature enterocytes and Paneth cells are also seen. Case 3,  $\times 3000$



## Discussion

The patchy distribution of abnormalities produced by MTX in immature enterocytes was similar to that previously reported in mature villus cells<sup>3, 4</sup> and probably reflects differences in the metabolic and kinetic state of cells at the time of drug exposure. The cytotoxic effect of MTX is related to both the intracellular concentration of folic acid and dihydrofolate reductase (DHFR) and the stage of cell division.<sup>9-11</sup> The intracellular drug concentration also influences cytotoxicity<sup>12</sup> and this may vary due to differences in the active transport of MTX across the cell membrane.

The overall incidence of crypt enterocyte damage was surprisingly low considering that the major action of MTX is to block the synthetic phase of cell division. Cells with such a rapid turnover rate are usually thought of as being particularly sensitive.

The interpretation of changes in mitotic index is limited by the static nature of the method and stathmokinetic techniques are required to study crypt cell kinetics in detail. However in view of the S phase action of MTX it is reasonable to assume that any reduction in mitotic index is due to a reduction in cell proliferation rather than a decrease in mitotic duration. Both of these could result in similar numbers of mitotic figures at any particular time of counting. The early reduction in mitotic activity, evident three hours after a single dose was consistent with the threshold serum drug concentration for inhibition of DHFR, estimated to be about  $10^{-7}M$ .<sup>13</sup> In the majority of children on maintenance therapy for ALL such a serum concentration is reached within 20 min of an oral dose of MTX ( $15 \text{ mg/m}^2$ ).<sup>14</sup>

The correlation shown between the decrease in mitotic activity and the cumulative dose of MTX may account for the difference in the incidence of oral toxicity associated with a five-day course of therapy as opposed to a single weekly dose. After a single dose a number of cells remain in mitosis which permits rapid repopulation of epithelial surfaces, whereas prolonged complete inhibition associated with several daily doses results in the failure to replace shed cells and consequent mucosal degeneration. Buccal mucosal ulceration is seen in less than 10% of children receiving weekly MTX compared with as many as 80% on five-day schedules.<sup>15</sup>

Gut endocrine cells appeared to be resistant to the effects of MTX which might have been expected in view of their slow rate of turnover.<sup>16</sup> The abnormalities seen in the Paneth cells, which also have a slow turnover time ( $\approx 2 \text{ wk}$ ),<sup>16</sup> were however quite unexpected. These cells may be influenced by mechanisms other than a blockade of the synthetic phase, although RNA and protein synthesis are

usually only disrupted with higher dose therapy. Paneth cell vacuolation has been described after x irradiation but this was an early effect accompanied by more generalised crypt cell damage.<sup>17, 18</sup> The possibility therefore arises that the cellular alterations were a functional response rather than of a toxic nature.

The role of the Paneth cell has long been an area of debate and functions have been suggested in relation to enzyme secretion<sup>19, 20</sup> local nutrient secretion<sup>21</sup> and the control of crypt cell growth.<sup>22</sup> Although crypt cell damage and reduced cell numbers have been reported in the experimental animal after treatment with a number of cytotoxic agents<sup>23-26</sup> detailed cell morphology has not been considered. In a study of jejunal biopsies after a single intravenous dose of MTX in adults with psoriasis Trier reported generalised patchy necrosis of all cell types.<sup>3</sup> Such abnormalities may have been related to the high peak serum drug concentration associated with this route of administration. Other reports of cytotoxic damage to the human small gut do not specifically describe Paneth cell features.<sup>27, 28</sup>

The possibility that the changes were secondary to a nutritional deficit such as zinc deficiency must be considered. Striking Paneth cell abnormalities have been described in acrodermatitis enteropathica<sup>29</sup> and this condition has been reported in a child receiving cytotoxic therapy.<sup>30</sup> Although serum zinc concentrations were not estimated in this study no case had clinical signs of such a deficiency. The relation between the extent of abnormalities and recent MTX treatment indicates that they represented a short term effect. Furthermore the characteristic features of zinc deficiency—secretory granule degeneration and cytoplasmic inclusions, were not seen.

It could be postulated that the cytoplasmic vacuolation was a response to the inhibition of crypt enterocyte mitosis. It is likely that a feedback mechanism exists between villus enterocytes and crypt cell production which involves one of more trophic agents,<sup>31</sup> although the precise nature of this remains unclear. Could the changes in the Paneth cell cytoplasm be due to increased synthetic activity in an attempt to increase cell turnover in response to reduced villus cell numbers? Some support for this hypothesis comes from the observation that a group of patients with severe villus atrophy unresponsive to gluten withdrawal were deficient in Paneth cells<sup>32</sup>. The jejunal biopsies also showed reduced crypt depth and a uniform decrease in mitotic activity. Although these abnormalities were suggested to be related to a local nutritive activity of Paneth cells,<sup>21</sup> they could also have been due to a defect in the crypt regulatory mechanism.

## References

- <sup>1</sup> Philips FS, Thiersch JB, Ferguson FC. Studies of the action of 4-aminopteroylglutamic acid and its congeners in mammals. *Ann New York Acad Sci* 1950;**52**:1349–59.
- <sup>2</sup> Taylor SG, Hass GM, Crumrine JL, Slaughter DP. Toxic reactions of 4-aminopteroylglutamic acid in patients with far advanced neoplastic disease. *Cancer* 1950;**3**:493–503.
- <sup>3</sup> Trier JS. Morphological alterations induced by methotrexate in the mucosa of human proximal small intestine. 11. Electron microscopic observations. *Gastroenterology* 1962;**43**:407–24.
- <sup>4</sup> Gwevava NJT, Pinkerton CR, Glasgow JFT, Sloan JM, Bridges JM. Small bowed enterocyte abnormalities caused by methotrexate treatment in acute lymphoblastic leukaemia of childhood. *J Clin Pathol* 1981;**34**:790–5.
- <sup>5</sup> Robinson JW, Antonioli JA, Vannotti A. The effect of oral methotrexate on the rat intestine. *Biochem Pharmacol* 1966;**15**:1479–89.
- <sup>6</sup> Baskerville A, Batter-Hatten D. Intestinal lesions induced experimentally by methotrexate. *Br J Exp Pathol* 1977;**58**:663–9.
- <sup>7</sup> Glasgow JFT, Corkey CWB, Molla A. Critical assessment of small bowel biopsy in children. *Arch Dis Child* 1979;**54**:604–8.
- <sup>8</sup> Cheng H, Bjerknes M. The stem cell zone of the mouse small intestinal epithelium. In: Appleton DR, Sunter JP, Watson AJ, eds. *Cell proliferation in the gastrointestinal tract* Tunbridge Wells: Pitman Medical, 1980:155–65.
- <sup>9</sup> Werkheiser WC. The relation of folic acid reductase to aminopterin toxicity. *J Pharmacol Exp Ther* 1962;**137**:167–72.
- <sup>10</sup> Margolis S, Philips FS, Sternberg SS. The cytotoxicity of methotrexate in relation to inhibition of folic acid reductase and of DNA synthesis. *Cancer Res* 1971;**31**:2037–46.
- <sup>11</sup> Skipper HE, Schabel FM, Mellett LB, Montgomery JA, Wilkoff LJ, Lloyd HH, Brockman RW. Implications of biochemical, cytotoxic, pharmacologic and toxicologic relationships in the design of optimal therapeutic schedules. *Cancer Chemother Rep* 1970;**54**:431–50.
- <sup>12</sup> Goldman ID. Analysis of the cytotoxic determinants for methotrexate. *Cancer Chemother Rep* 1975;**6**:51–61.
- <sup>13</sup> Bleyer WA. The clinical pharmacology of methotrexate. *Cancer* 1978;**41**:36–51.
- <sup>14</sup> Pinkerton CR, Welshman SG, Dempsey SI, Bridges JM, Glasgow JFT. Absorption of methotrexate under standardised conditions in children with acute lymphoblastic leukaemia. *Br J Cancer* 1980;**42**:613–5.
- <sup>15</sup> Pinkerton CR. Methotrexate absorption profiles and enterotoxicity in children with acute lymphoblastic leukaemia. MD thesis. The Queen's University of Belfast, 1981.
- <sup>16</sup> Cheng H, Leblond CP. Origin, differentiation and renewal of the four main epithelial cell types in the mouse small intestine. *Am J Anat* 1974;**141**:503–20.
- <sup>17</sup> Trier JS, Browning TH. Morphological response of the mucosa of human small intestine to x ray exposure. *J Clin Invest* 1966;**45**:194–204.
- <sup>18</sup> Torpila SS. Morphological and functional response of the mucosa of human small intestine to ionising radiation. *Scan J Gastroenterol* 1971;**6**:9–52, suppl 12.
- <sup>19</sup> Reiken FO, Pearse AGE. Histochemical study on the Paneth cell in the rat. *Gut* 1966;**7**:86–93.
- <sup>20</sup> Trier JS, Lorenzsonn V, Groehler K. The pattern of secretion of the Paneth cells of the small intestine. *Gastroenterology* 1966;**50**:875.
- <sup>21</sup> Gent AE, Creamer B. Paneth cell secretion. *Digestion* 1972;**7**:1–12.
- <sup>22</sup> Rodning CB, Wilson ID, Erlandsen SL. Immunoglobulins within the human small intestinal Paneth cells. *Lancet* 1976;ii:984–7.
- <sup>23</sup> Hobson RW, Jervis HR, Kingry RL, Wallace JR. Small bowel changes associated with vincristine sulphate treatment: an experimental study in the guinea pig. *Cancer* 1974;**34**:1888–96.
- <sup>24</sup> Jaynes BJ, Altmann GG. Light and scanning electron microscopic observations of the effects of sublethal doses of methotrexate on the rat small intestine. *Anat Rec* 1978;**191**:1–18.
- <sup>25</sup> Woll E, Oleson JJ. The effects of a folic acid antagonist (aminopterin) on albino rats. *Br J Exp Pathol* 1951;**34**:458–61.
- <sup>26</sup> Muggia AL, Wagman E, Milles SS, Spiro HM. Response of the gastro-intestinal tract of the mouse to 5 fluorouracil. *Am J Pathol* 1963;**42**:407–11.
- <sup>27</sup> Slavin RE, Dias MA, Saral R. Cytosine arabinoside induced toxic alterations on sequential chemotherapeutic protocols. *Cancer* 1978;**42**:1747–59.
- <sup>28</sup> Shaw MT, Spector MH, Ladman AJ. Effects of cancer, radiotherapy and cytotoxic drugs on intestinal structure and function. *Cancer Treat Rev* 1979;**6**:141–51.
- <sup>29</sup> Bohane TD, Cutz E, Hamilton JR, Gall DG. Acrodermatitis enteropathica, zinc and the Paneth cell. *Gastroenterology* 1977;**73**:587–92.
- <sup>30</sup> Cutler EA, Palmer J, Kontras SB. Chemotherapy and possible zinc deficiency. *N Engl J Med* 1977;**297**:168–9.
- <sup>31</sup> Galjaard H, Meet-Fieggan W, Gieson J. Feedback control by functional villus cells on cell proliferation and maturation in intestinal epithelium. *Exp Cell Res* 1972;**73**:197–207.
- <sup>32</sup> Creamer B, Pink IJ. Paneth cell deficiency. *Lancet* 1967;i:304–6.

Requests for reprints to: Dr CR Pinkerton, Dept of Child Health, Institute of Child Health, 30 Guilford Street, London WC1, England.