

Fatty tumours of the uterus

DERRICK J POUNDER

From the Division of Tissue Pathology, Institute of Medical and Veterinary Science, Adelaide, South Australia

SUMMARY Uterine fatty tumours (UFT) are uncommon and have received little attention in the English literature. They have aroused interest as a consequence of occasional diagnostic confusion with sarcomas and the continuing unresolved dispute as to their histogenesis. Three cases of UFT are described and the pathological features of note discussed. The viewpoint that these tumours are hamartomas/choristomas is rejected. UFT most probably represent tumour metaplasia within a leiomyoma. There is no uniform accepted nomenclature for such tumours and it is suggested that they be designated “uterine fatty tumours” and subdivided into “lipoma” and “mixed lipoma/leiomyoma” (synonym lipoleiomyoma).

Fatty tumours primary to the uterus are uncommon¹ and are almost invariably benign.² Occasionally the clinical presentation³ or macroscopic appearance² may mimic a sarcoma and create diagnostic confusion. There is no consensus as to the histogenesis or nomenclature of uterine fatty tumours (UFT).^{4,5} Three cases of UFT are presented and discussion centres on these areas of interest and contention.

Material and methods

All uterine fatty tumours (UFT) accessioned on the files of the Institute of Medical and Veterinary Science⁶ over a three-year period, January 1979 to January 1982, were retrieved. Amongst the approximately 54 000 surgical accessions during this period there were three cases of UFT. Nine, two and one paraffin blocks of tumour tissue were available from these three cases for review. Haematoxylin and eosin-stained and, where appropriate, Masson trichrome-stained sections from each paraffin block were studied.

Results

A summary of the relevant clinical history, clinical diagnosis and final diagnosis for the three cases studied is set out in the Table. The pathological diagnosis of a UFT was confirmed in each of the three cases and only the pathological findings relevant to this diagnosis will be described in detail.

CASE 1 (FIGS. 1 AND 2)

The resected specimen comprised a uterus with two

normal Fallopian tubes. There was a very large intramural uterine tumour mass which measured 200 mm in greatest diameter and weighed 2140 g. The tumour, which distorted the uterine cavity into an enlarged slit, was rounded and well circumscribed but not encapsulated. On cut surface the greater part of the tumour appeared yellow, lobulated and fatty. Within the tumour mass and abutting upon one margin was a hard, grey calcified wedge measuring 120 × 80 × 75 mm. Two typical spherical, circumscribed leiomyomas, each approximately 15 mm in diameter, were also identified within the myometrium.

Microscopically, the fatty tumour comprised adult-type adipose tissue divided into lobules by thin connective tissue septae. There was no true tumour capsule but adjacent myometrium was compressed around the tumour to provide a false capsule. Irregularly dispersed amongst the adipocytes were single and small clusters of smooth muscle cells. In some areas of the tumour the smooth muscle component could be identified only after careful searching whilst in other areas groups of smooth muscle cells were readily apparent. Smooth muscle cells were present deep within the tumour as well as at its periphery. Nowhere did the smooth muscle component form the wide interlacing and whorled bands typically seen in a leiomyoma. The hard calcified wedge identified macroscopically comprised degenerate adipose tissue with an extensively hyalinised connective tissue stroma and heavy calcification of adipocytes. Similar smaller foci of hyaline sclerosis and dystrophic calcification of adipocytes were disposed irregularly throughout the tumour. The two small leiomyomas identified macroscopically showed some stromal hyalinisation but did not contain an adipose tissue component.

Clinical details of three cases of uterine fatty tumour

Case	Age (yr)	Clinical history	Clinical diagnosis	Final diagnosis
1	83	Five years increasing weight and abdominal girth; initially refused surgery; oedema of right leg for one week	? Ovarian cyst ? Uterine leiomyoma	Uterine mixed lipoma/leiomyoma, cervical dysplasia (moderate), uterine leiomyomas (2)
2	80	Long-standing uterine prolapse	Uterine prolapse	Uterine prolapse, cervical keratinisation, uterine leiomyoma, uterine mixed lipoma/leiomyoma
3	73	Post-menopausal bleeding, large pelvic mass; curetting-hyperplastic polyps	Ovarian tumour	Mucinous cystadenocarcinoma (right ovary), hyperplastic endometrial polyp, uterine mixed lipoma/leiomyoma

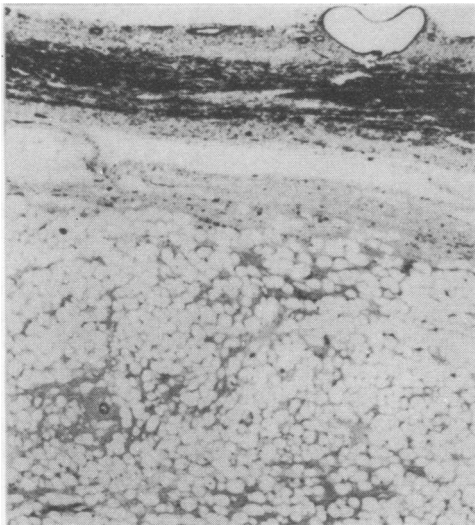


Fig. 1 An intra-mural mixed lipoma/leiomyoma (case 1). The atrophic endometrium is seen at the top of the photomicrograph. Note the lack of broad smooth muscle fascicles within the tumour which is predominantly fatty. Masson's trichrome $\times 20$

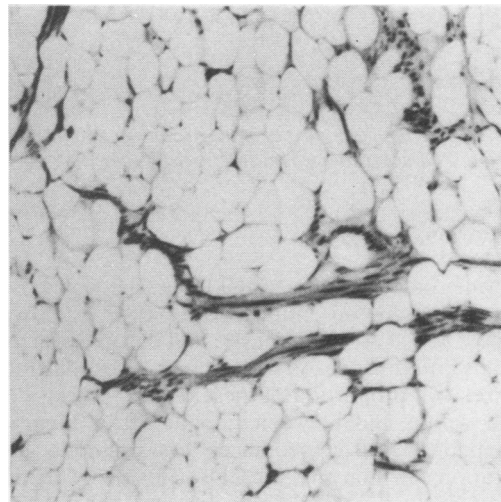


Fig. 2 Clusters of smooth muscle cells are scattered amongst the adipocytes (case 1). Masson's trichrome $\times 60$

CASE 2 (FIG. 3)

The simple hysterectomy specimen comprised a uterus with parous cervix. A spherical, yellow and white, circumscribed nodule 25 mm in diameter was sited intramurally at the fundus. A second circumscribed intramural nodule 8 mm in diameter was present in the lower uterine segment.

Microscopically the larger nodule was circumscribed but not encapsulated and comprised an intimate admixture of adult-type adipose tissue, smooth muscle fascicles and a dense hyalinised stroma. The adipose tissue component was prominent and readily identified. The stromal hyalinisation and the quantity of blood vessels resembled that seen in a typical leiomyoma. The

smaller nodule in the lower uterine segment was a leiomyoma without any adipose tissue component.

CASE 3 (FIG. 4)

The surgical specimen was a total hysterectomy with bilateral salpingo-oophorectomy. At the uterine fundus was a subserosal, circumscribed, yellow and white nodule 20 mm in diameter. Microscopically, this fundal nodule resembled the UFT in case 2 above. The smooth muscle component was more prominent and approximately 10% of the tumour was occupied by broad whorling bands of smooth muscle in a pattern typically seen in uterine leiomyomas. The smooth muscle component was primarily localised to the periphery of the tumour whilst centrally there was extensive hyalinisation. Adipocytes were sparsely scattered amongst the bands of smooth muscle but were very prominent centrally.

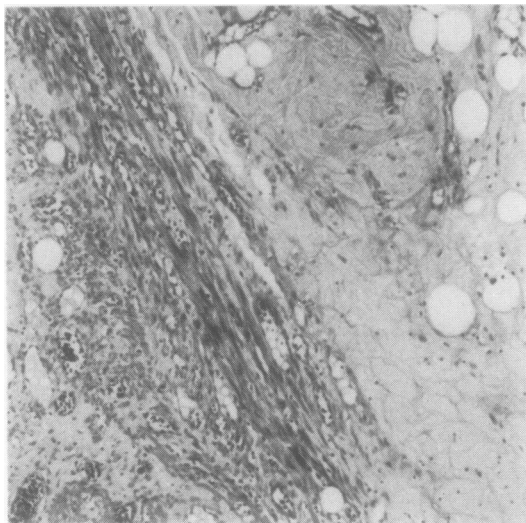


Fig. 3 Scattered adipocytes in the hyalinised stroma and amongst adjacent smooth muscle fascicles (case 2) $\times 60$

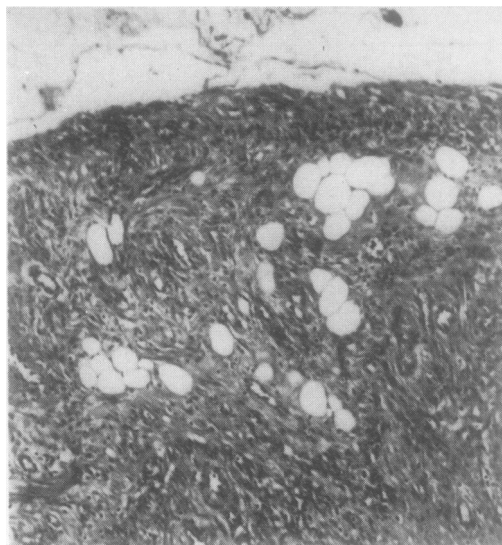


Fig. 4 A few adipocytes are present within an otherwise typical leiomyomatous area (case 3). An artefactual cleft formed between the tumour and its compression capsule is seen at the top of the photomicrograph $\times 60$

Discussion

Uterine fatty tumours (UFT) may be defined as tumours composed entirely or in part of adult-type adipose tissue. Smooth muscle and fibrous tissue are usually intermixed. As the present cases illustrate, the relative proportion of these tissues varies widely both within and between tumours. This range of histopathological appearances has caused a proliferation of synonyms² for UFT. The more common synonyms include lipoleiomyoma, myolipoma, lipofibroma, lipomyoma, fibromyolipoma, mixed lipoma, and lipomatosis of the stroma of a uterine fibroid. There is no common numerical code allocated to UFT in the systematised nomenclature of medicine of the College of American Pathologists.⁷

The average age of the three cases was 79 yr, in keeping with reports that more than 90% of UFT occur in patients over the age of 40 yr.⁵ Only one patient was symptomatic as a consequence of the UFT. The spectrum of clinical presentation of UFT effectively parallels that of uterine leiomyomas.¹⁵ Consequently the correct diagnosis is rarely made preoperatively⁸ unless by x-ray or ultrasound.⁹ Rapid growth of a UFT may suggest a clinical diagnosis of sarcoma.³

All three tumours were located in the uterine corpus which is the typical site. Occasionally UFT arise in the cervix.⁵ Two tumours were intramural and the third was subserosal, a less common location.² The two smaller tumours macroscopically resembled leiomyomas except for their yellow colouration. UFT are variously reported as representing between

0.03% and 0.2%¹ of leiomyomas. Pure leiomyomas are frequently found in association with UFT² and this was so in two cases. UFT may be multiple.¹⁰

Fatty areas within a UFT appear yellow or yellow-grey and feel soft.⁴ As in case 1 the entire tumour may appear distinctly fatty.³ Occasionally a discrete fatty focus may be present within an otherwise typical leiomyoma.⁵ Most commonly the adipose tissue is scattered throughout the tumour (see cases 2 and 3). A UFT which is soft with a homogeneous non-fibrillar cut surface may suggest a diagnosis of leiomyosarcoma.² The differential diagnosis lies between a sarcoma, UFT and leiomyoma with ischaemic degeneration or necrosis. At operation a frozen section should resolve the dilemma.¹⁰ Malignant fatty tumours primary to the uterus are exceptionally rare.²

Microscopically, all UFT contain adult-type fat cells. Most tumours contain easily recognisable areas of smooth muscle either as broad interweaving fascicles or scattered myocytes. The fibrous tissue stroma may be delicate or dense and hyalinised, and the vascular component is said occasionally to be striking.⁴ Scattered mast cells and eosinophils may be found² but were not observed in any of the present cases. These stromal components may also be seen in pure leiomyomas. The overall impression is of a histological spectrum ranging from pure lipoma through mixed lipoma/leiomyoma to pure leiomyoma.

There are no clearly established histopathological criteria for the distinction of a pure lipoma from a

mixed lipoma/leiomyoma of the type illustrated by case 1. The presence of occasional scattered smooth muscle cells is interpreted by some as representing inclusion of myometrium by an expanding lipoma.² I concur with the viewpoint¹ that a diagnosis of pure lipoma of the uterus should only be made when any smooth muscle cells present are confined to the periphery of the tumour. Only then can the myocytes be accepted as having been incorporated by an expanding lipoma.

The term mixed lipoma/leiomyoma is descriptive and serves to emphasise the clinical and macroscopic similarity of these tumours to leiomyomas. These tumours might also be designated as lipoleiomyomas. Division of the mixed lipoma/leiomyoma group into two subgroups,¹² namely circumscribed lipomatosis in a myoma and diffuse lipomatosis in a myoma emphasises differences in the macroscopic appearance (*vide supra*) but seems unnecessarily wieldy. Some⁴ have used the term "benign mixed mesodermal tumours" for these lesions. There does not appear to be a close relationship between UFT and malignant mixed mesodermal tumours.^{11 12}

Theories on histogenesis lay emphasis upon explaining the presence of adipose tissue, an element not usually found in the uterine corpus.^{4 5} Most recently a morphological and histogenetic analogy has been drawn between UFT and renal angiomyolipomas.^{4 10 13} It has been suggested that UFT are hamartomas or, more appropriately, choristomas.¹⁴ Renal angiomyolipomas are considered to be choristomas.¹⁵

Quantitative comparisons between UFT and angiomyolipomas have revealed a similarity in the proportions of adipose and smooth muscle elements.⁴ Abnormal vascular proliferations have also been described in UFT.⁴ However, these comparisons remain unconvincing because there are significant qualitative differences between renal angiomyolipomas and UFT. The smooth muscle in renal angiomyolipomas is often unusual in that the myocytes appear cytologically atypical.¹⁶ Also renal angiomyolipomas have an infiltrating margin. These features are not seen in UFT. To the best of my knowledge histopathologically convincing extra-renal angiomyolipomas have only been described in the liver.¹⁷

The viewpoint that renal angiomyolipomas are choristomas is strengthened by their association with choristomas/hamartomas in other organs.¹⁸ By contrast UFT are associated with uterine leiomyomas.² Furthermore, the entire spectrum of renal smooth muscle and fatty tumours are regarded as choristomas.¹⁵ By contrast uterine leiomyomas are generally regarded as true neoplasms. Thus the analogy between UFT and renal angiomyolipomas is

extremely tenuous.

The adipose tissue within UFT more likely than not represents fatty metaplasia within a leiomyoma.¹⁹ Such "tumour metaplasia" is a well recognised phenomenon.¹⁴ Metaplasia may also occur within the stroma of a tumour—for example, osseous metaplasia in a carcinoid of the lung. The sometimes florid overgrowth of adipose tissue within a UFT as in case 1 suggests that it represents tumour cell metaplasia rather than stromal metaplasia. However, the clarification of the precise histogenesis of UFT must await the complete elucidation of the histogenesis of leiomyomas of the uterus.⁸

References

- Willen R, Gad A, Willen H. Lipomatous lesions of the uterus. *Virchows Arch A Pathol Anat Histol* 1978;377:351–61.
- Jacobs DS, Cohen H, Johnson JS. Lipoleiomyomas of the uterus. *Am J Clin Pathol* 1965;44:45–51.
- Gupta RK, Hunter RE. Lipoma of the uterus: review of literature with views of histogenesis. *Obstet Gynecol* 1964;24:255–7.
- Demopoulos RI, Denarvaez F, Kaji V. Benign mixed mesodermal tumours of the uterus: a histogenetic study. *Am J Clin Pathol* 1973;60:377–83.
- Brandfass RT, Everts-Suarez EA. Lipomatous tumours of the uterus. A review of the world's literature with report of a case of true lipoma. *Am J Obstet Gynecol* 1955;70:359–67.
- Allen PW, Angus BV. Computer-output microfilm in an anatomic pathology laboratory. *Am J Clin Pathol* 1978;69:537–43.
- Cote RA. *Systematised nomenclature of medicine*. Illinois: College of American Pathologists, 1977.
- Honore LH. Uterine fibrolipoleiomyoma: report of a case with discussion of histogenesis. *Am J Obstet Gynecol* 1978;132:635–6.
- Houser LM, Carrasco CH, Sheehan CR. Lipomatous tumour of the uterus: radiographic and ultrasonic appearance. *Br J Radiol* 1979;52:992–3.
- Chachutow D, Brill R, Passaic NJ. Lipomas of the uterus. *Am J Obstet Gynecol* 1957;73:1358–61.
- Norris HJ, Taylor HB. Mesenchymal tumours of the uterus. III A clinical and pathological study of 31 carcinosarcomas. *Cancer* 1966;19:1459–65.
- Kempson RL, Bari W. Uterine sarcomas. Classification, diagnosis and prognosis. *Hum Pathol* 1970;1:331–49.
- McKeithen WS, Shinner JJ, Michelsen J. Hamartoma of the uterus. Report of a case. *Obstet Gynecol* 1964;24:231–4.
- Walter JB, Israel MS. *General pathology*. 5th ed. Edinburgh: Churchill Livingstone, 1979.
- Bennington JL, Beckwith JB. Tumors of the Kidney, Renal Pelvis and Ureter (*Atlas of tumor pathology*, 2nd series fascicle 12). Washington: Armed Forces Institute of Pathology, 1975.
- Allen PW. *Tumors and proliferations of adipose tissue. A clinicopathological approach*. New York: Masson, 1981.
- Ishak KG. Mesenchymal tumours of the liver. In: Okuda K, Peters RL, eds. *Hepatocellular carcinoma*. New York: John Wiley and Sons, 1976:247–305.
- Donegani G, Grattarola FR, Wildi E. Tuberosus sclerosis: Bourneville disease. In: Vinken PJ, Bryan GW, eds. *Handbook of clinical neurology*. Amsterdam: North Holland Publishing Co, 1972;14:340–89.
- Gonzalez-Angulo A, Kaufman RH. Lipomatous tumor of the Uterus. Report of a case. *Obstet Gynecol* 1962;19:494–8.

Requests for reprints to: Dr Derrick J Pounder, Division of Tissue Pathology, Institute of Medical and Veterinary Science, Frome Road, Adelaide S.A. 5000, Australia.