



STONES/ENDOUROLOGY

ORIGINAL ARTICLE

Comparison of ureteric stone size, on bone window versus standard soft-tissue window settings, on multi-detector non-contrast computed tomography



Hussam Uddin Soomro^a, M. Hammad Ather^{a,*}, Basit Salam^b

^a Section of Urology, Department of Surgery, Aga Khan University, Karachi, Pakistan

^b Department of Radiology, Aga Khan University, Karachi, Pakistan

Received 26 April 2016, Received in revised form 14 June 2016, Accepted 25 June 2016

Available online 26 July 2016

KEYWORDS

Urinary calculi;
Computed tomography;
Soft-tissue window setting;
Bone window setting

ABBREVIATIONS

CT KUB, non-contrast enhanced CT of the kidney, ureter and bladder;

Abstract Objective: To compare the difference in mean stone size, as measured on bone window vs standard soft-tissue window setting using multi-detector computed tomography (MDCT) in patients with a solitary ureteric stone.

Patients and methods: In all, 60 patients presenting to the emergency and outpatient departments of a University Hospital from May 2015 to October 2015 and fulfilling the inclusion criteria were included in the study. A 64-slice MDCT was used to assess the locations and size of the ureteric stones. A consultant radiologist independently analysed the MDCT scans of all the patients. The mean difference in stone size was calculated between both window settings in axial and coronal planes.

Results: The mean (SD) age of the patients was 37.13 (11.9) years. Males constituted ~68% of the cohort and 32% were female. In all, 85% of the patients had left ureteric stones and 15% had right ureteric stones. The mean (SD) stone size, as measured on the soft-tissue window setting was 6.68 (2.01) mm, and on the bone window setting was 4.8 (1.9) mm. The mean (SD) difference in stone size between the two

* Corresponding author at: Section of Urology, Department of Surgery, Aga Khan University, P.O. Box 3500, Stadium Road, Karachi 74800, Pakistan. Fax: +92 21 3493 4294.

E-mail address: hammad.ather@aku.edu (M. Hammad Ather).

Peer review under responsibility of Arab Association of Urology.



Production and hosting by Elsevier

MDCT, multi-detector CT;
MET, medical expulsive therapy;
US, ultrasonography

window settings was +1.85 (0.55) mm. The two means were compared using Student's *t*-test, and the difference was found to be statistically significant ($P < 0.05$).

Conclusion: The stone size measured using the soft-tissue window setting on a MDCT is significantly different from the measurement on the bone window setting.

© 2016 Production and hosting by Elsevier B.V. on behalf of Arab Association of Urology. This is an open access article under the CC BY-NC-ND license (<http://creativecommons.org/licenses/by-nc-nd/4.0/>).

Introduction

Acute flank pain due to suspected reno-ureteric stone is a common clinical presentation in the accident and emergency and urology outpatient departments. It is crucial to accurately diagnose the presence of stones and associated complications such as obstruction, infection, and renal failure [1]. Early and accurate diagnosis of urolithiasis is instrumental in preventing obstruction and related complications.

Non-contrast enhanced CT of the kidney, ureter and bladder (CT KUB) is now an established imaging method in the evaluation of suspected acute renal colic [2]. It is well established that CT KUB is a diagnostically superior, safer, quicker, and more cost-effective investigation for acute renal colic. Accurate determination of maximum stone size is crucial in clinical decision-making for intervention or use of medical expulsive therapy (MET) [3].

The pre-set window setting in abdominal CT is soft tissue; however, there is an option of changing it to the bone setting. The drop-down box allows selection of pre-sets for 'Window' and 'Level' to optimise the display of specific tissues or pathologies on CT scans. Currently, the standard is to measure stone size on the soft-tissue window setting on CT KUB. There is still significant controversy in size estimation using soft-tissue and bone windows. Argüelles Salido et al. [4] whilst comparing actual surface size and bone window CT scan size when using the European Association of Urology formula or scanner software did not find a statistically significant difference. They also noted that measurements in the soft-tissue window tended to significantly overestimate the surface size, whilst the plain radiography underestimated it slightly but significantly. Recently, Zorba et al. [5] assessed the role of stone volume in predicting stone clearance. They noted that stone diameter alone lead to heterogeneity within the group and stone volume may be used in addition to size to determine a more definite homogeneous group to predict stone passage more precisely.

Patients presenting with acute ureteric colic secondary to a ureteric stone require a decision on management between MET and interventional treatment. Stone size is the most critical factor in deciding the management option. The current practice to measure stone size on the soft-tissue window setting on CT KUB is variable. We therefore conducted the present study to deter-

mine the difference in the measurement of stone size between soft-tissue and bone window settings on multi-detector CT (MDCT) KUB.

Patients and methods

This cross-sectional study was conducted over a period of 6 months following Ethics Review Committee approval. Adult patients aged >16 years, from both genders presenting to the Emergency Department or Out-patient clinic, undergoing MDCT KUB for ureteric colic/flank pain, and having single ureteric stone, and available for follow-up until stone-free were included in the study. We included 60 patients fulfilling the study criteria. MDCT scans of all those patients whose stones were retrieved completely as a single unit were independently analysed by a consultant radiologist using a picture-archiving computer system (PACS™). The CT scans of these patients were reviewed and measurements recorded on soft-tissue and bone windows. Stone measurements were done on axial and coronal planes, on $\times 4.0$ magnified standard soft-tissue window and $\times 4.0$ magnified bone window settings. All reported results on mean stone size were done on the coronal reconstructed sections. Each stone was measured in two dimensions, along its maximum diameter and the other one perpendicular to it. Then the mean difference in stone size was calculated between both window settings in the axial and coronal planes. All the collected data were entered into a pre-designed proforma.

Data were entered and analysed using SPSS version 19. The mean \pm SD was calculated for age and stone size measured on the soft-tissue and bone window settings. Frequencies and percentages were calculated for gender and side of stone. Student's *t*-test was used to compare the mean difference in stone size and a $P \leq 0.05$ was considered to indicate statistical significance. Effect modifiers were controlled through stratification of age and gender to see the effect of these on outcome variables and a post-stratification *t*-test was used taking $P \leq 0.05$ as significant. The mean difference was calculated by subtracting the mean value of the soft-tissue and bone window settings. Stratification of outcome variables, i.e. mean stone size on soft-tissue window and mean stone size on bone window, was done with age and gender, and none of these were found to have a statistically significant effect.

The sample size calculation was done using open EPI™ info sample size calculator, using a mean (SD) for soft-tissue window of -2.16 (1.29) and for bone window setting of -1.83 (1.02), CI 95%, power of test 80%, then the estimated sample size was at least 60.

Results

In all, 60 patients were included fulfilling the inclusion and exclusion criteria. The mean (SD; range) age of the patients was 37.13 (11.9; 16–70) years (Fig. 1). Males constituted ~68% of the cohort, whilst 32% were females. In all, 85% of the patients had left ureteric stones and 15% had right ureteric stones. The mean (SD; range) stone size, as measured on soft-tissue window setting was 6.68 (2.01; 2.9–10) mm. Similarly, the mean (SD; range) size of stones as measured on the bone window setting was 4.8 (1.9; 1.4–9.8) mm.

The mean (SD) difference in stone size between the soft-tissue window and bone window was +1.85 (0.55) mm. The two means were compared using Student's *t*-test, and the difference was found to be statistically significant ($P < 0.05$).

Discussion

Reno-ureteric colic has an estimated lifetime prevalence of 12% and it is one of the commonest presentations to emergency departments and urology clinics [6]. Most patients either have obstruction with or without a urinary calculus [7]. CT KUB has become the standard of care as the imaging modality of choice in the evaluation of ureteric colic [8], although it has been suggested that use of CT should be rationalised [9]. CT KUB has become the imaging of choice for diagnosis of stones and obstruction even in patients with deranged renal function [10]. CT is also useful in diagnosing alternate causes of flank pain, which could be either genitourinary or extra-urinary tract pathologies [11]. The radiation dose is a concern, but there are low-dose protocols with matching sensitivity [12].

Urolithiasis is a highly recurrent condition with the 10-year recurrence rate exceeding 35% [13]. Ekici and Sinanoglu [14] showed that the combination of plain radiograph KUB and/or ultrasonography (US) in the diagnosis are highly sensitive and specific for nephrolithiasis, but lack sensitivity for ureteric calculi particularly when they are in the middle ureter. However, a recent multicentre, pragmatic, comparative effectiveness trial in randomly assigned patients between US and CT showed that initial US was associated with lower cumulative radiation exposure than initial CT [15]. The authors of the work noted that using an algorithmic approach does not significantly impact the diagnoses with complications, serious adverse events, pain scores, return emergency department visits, or hospitalisations

in high-risk groups. Most uncomplicated ureteric stones are managed expectantly or with MET. Some patients initially managed with MET will require intervention within a few days to weeks of initial diagnosis. Various parameters have been defined in the literature to identify patients who would fail MET and would require intervention. These include stone size (volume) [8], stone location (proximal vs ureterovesical junction), presence of hydronephrosis etc.; however, stone size is the most extensively studied determinant of stone passage without intervention. The advantage of CT in making management decisions is in defining the exact stone size. The current practice is to determine the stone size on the soft-tissue window setting; however, the practice of determining the stone size in the bone window setting is also in practice. The present study was performed to assess the difference in the stone size estimated on bone window vs soft-tissue window settings.

Stone size is a major determinant of stone passage, as almost two-thirds of stones of ≤ 5 mm and half of stones of 5–10 mm pass spontaneously [16].

We conducted the present study on 60 patients with a single unilateral ureteric calculus. In the present study, the ureteric stone size was measured using the soft-tissue window as well as the bone window settings on MDCT scan, the mean stone size calculated on both the window settings was different (6.68 mm on soft-tissue window and 4.84 mm on bone window settings) and the difference was statistically significant ($P > 0.05$).

More than a decade ago, Alobaidi et al. [17], demonstrated the value of bone window settings on MDCT for the diagnosis of appendicoliths in patients with appendicitis. Tanrikut et al. [18], used the bone window setting to distinguish stents or nephrostomy tubes from urinary tract calculi. Later, Eisner et al. [19], compared magnified bone window and standard soft-tissue window settings for accurate measurement of stone size and they found a mean (SD) difference of 0.19 (1.00) mm on magnified bone window settings and a difference of -1.85 (1.42) mm, from the actual size of the stone.

Nadler et al. [20] reported that examining only axial images provides an inaccurate measure of stone size and suggested that coronal images should also be used to measure stone size more accurately, which is critical for clinical decision-making. Similarly, Nazim et al. [3] in their study found that the transverse stone diameter on axial images of non-contrast CT has the potential of underestimating the size of ureteric stones. The authors suggested that coronal, reformatted images be used for size estimation. CT has the potential to identify alternate causes of flank pain. Ather et al. [21] evaluated the role of CT KUB scan in detecting alternate and incidental diagnoses of acute flank pain. They observed a wide spectrum of alternate causes of flank pain and additional diagnoses including abdominal solid organ tumours and other significant abdominal conditions,

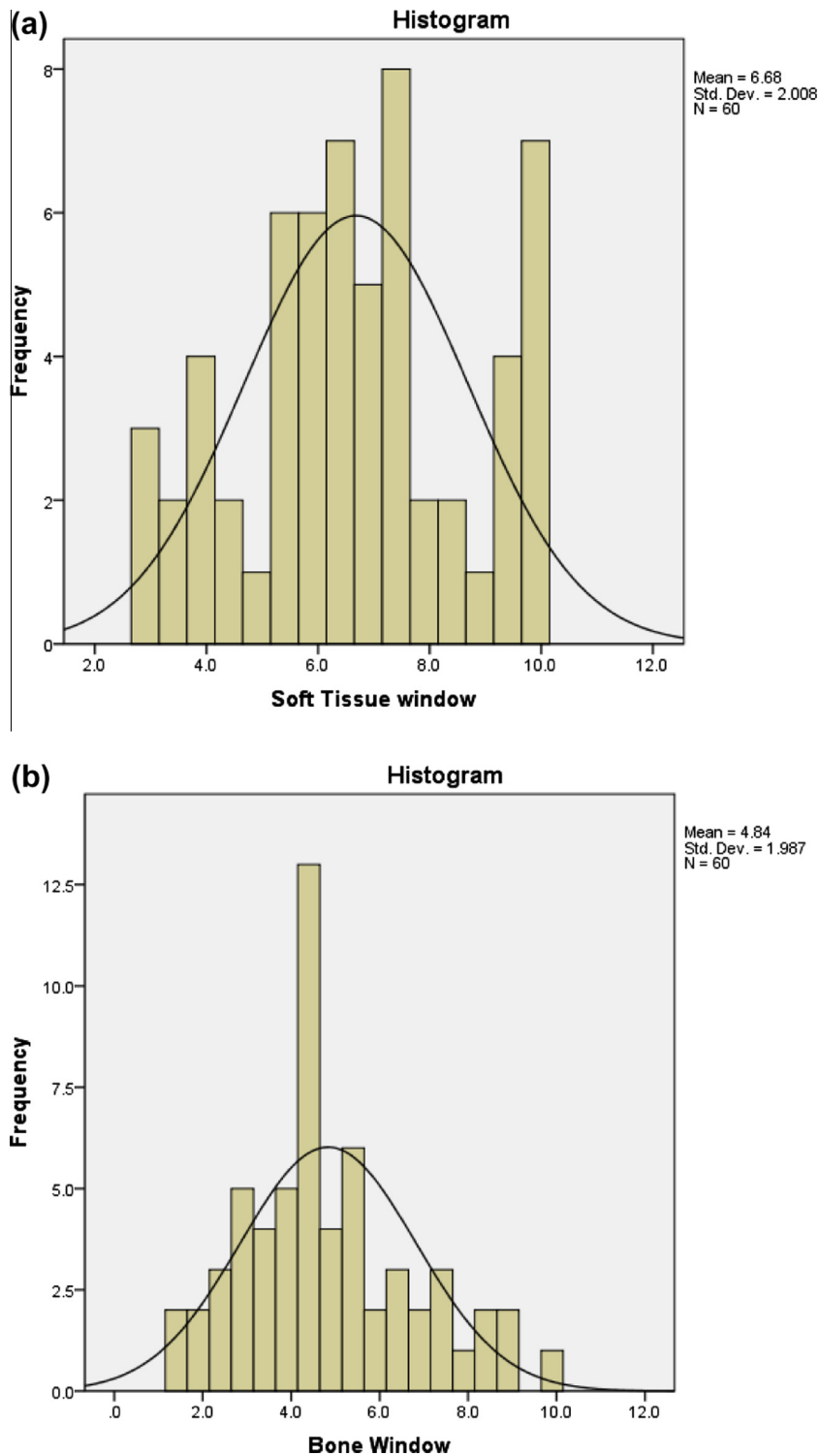


Figure 1 Histogram of stone sizes (a) on soft-tissue window CT KUB and (b) on bone window CT KUB.

such as pancreatitis, can be established or suggested on spiral CT performed for suspected acute urinary colic.

Historically CT performed to evaluate flank pain has been evaluated using soft-tissue windows because they are most useful for viewing the various intraperitoneal and extraperitoneal organs. Similarly, renal and ureteric

calculi have been viewed and measured in soft-tissue windows in most previously published studies [22,23].

Tanrikut et al. [18] in their study used different window settings on the CT scan to differentiate between urinary tract stones and ureteric stents or nephrostomy drainage catheters (stents/tubes). They observed superi-

ority of the bone window setting compared to the abdominal soft-tissue window setting in differentiating between stents and stones. Another advantage of the bone window setting is easier detection of appendicoliths. Alobaidi and Shirkhoda [17] noted that the use of bone window settings is helpful for detecting appendicoliths, when evaluating patients for acute appendicitis, particularly patients in whom evidence of appendicitis is equivocal.

Eisner et al. [19] in their *in vitro* and clinical study compared the magnified bone window and standard soft-tissue window for accurate measurement of ureteric stones and found that measurements performed in the soft-tissue window, with and without magnification, and in the bone window without magnification, were significantly different from hand calliper measurements (mean difference 1.2, 1.9 and 1.4 mm, $P = 0.003$, <0.001 and <0.001 , respectively). Eisner et al. [19] also noted no significant difference in the magnified bone window measurements compared to the digital calliper measurements. It is therefore recommended that magnified bone windows were the most accurate method of stone measurements *in vitro* and *in vivo*. In the bone window setting due to better definition of the stone edges the determined size of the stone is closer to reality. However, this needs to be confirmed in a larger cohort of patients and preferably in comparison with the retrieved stone.

Conclusion

The stone size measured using the soft-tissue window setting on a MDCT scan is significantly different from the measurement using the bone window setting. We recommend that future studies compare the stone size of the actual stone *in vitro* and CT measurements of the stone size on both soft-tissue and bone window settings to assess the difference in size. Determining the predictive value of stone size for the two window settings will help in evaluating the clinical implications.

Conflicts of interest

None declared.

Source of funding

None.

References

- [1] Rafi M, Shetty A, Gunja N. Accuracy of computed tomography of the kidneys, ureters and bladder interpretation by emergency physicians. *Emerg Med Australas* 2013;**25**:422–6.
- [2] Ahmed F, Zafar AM, Khan N, Haider Z, Ather MH. A paradigm shift in imaging for renal colic – Is it time to say good bye to an old trusted friend? *Int J Surg* 2010;**8**:252–6.
- [3] Nazim SM, Ather MH, Khan N. Measurement of ureteric stone diameter in different planes on multidetector computed tomography-impact on the clinical decision making. *Urology* 2014;**83**:288–93.
- [4] Argüelles Salido E, Aguilar García J, Lozano-Blasco JM, Subirá Ríos J, Beardo Villar P, Campoy-Martínez P, et al. Lithiasis size estimation variability depending on image technical methodology. *Urolithiasis* 2013;**41**:517–22.
- [5] Zorba Oü, Ogullar S, Yazar S, Akca G. CT-based determination of ureteral stone volume: a predictor of spontaneous passage. *J Endourol* 2016;**30**:32–6.
- [6] Miller OF, Rineer SK, Reichard SR, Buckley RG, Donovan MS, Graham IR, et al. Prospective comparison of unenhanced spiral computed tomography and intravenous urogram in the evaluation of acute flank pain. *Urology* 1998;**52**:982–7.
- [7] Reddy S. State of the art trends in imaging renal of colic. *Emerg Radiol* 2008;**15**:217–25.
- [8] Ahmad NA, Ather MH, Rees J. Unenhanced helical computed tomography in the evaluation of acute flank pain. *Int J Urol* 2003;**10**:287–92.
- [9] Nadeem M, Ather MH, Jamshaid A, Zaigham S, Mirza R, Salam B. Rationale use of unenhanced multi-detector CT (CT KUB) in evaluation of suspected renal colic. *Int J Surg* 2012;**10**:634–7.
- [10] Ather MH, Faizullah K, Achakzai I, Siwani R, Irani F. Alternate and incidental diagnoses on noncontrast-enhanced spiral computed tomography for acute flank pain. *Urol J* 2009;**6**:14–8.
- [11] Khan N, Ather MH, Ahmed F, Zafar AM, Khan A. Has the significance of incidental findings on unenhanced computed tomography for urolithiasis been overestimated? A retrospective review of over 800 patients. *Arab J Urol* 2012;**10**:149–54.
- [12] Ather MH, Memon WA. Stones: Impact of dose reduction on CT detection of urolithiasis. *Nat Rev Urol* 2009;**6**:526–7.
- [13] Masarani M, Dinneen M. Ureteric colic: new trends in diagnosis and treatment. *Postgrad Med J* 2007;**83**:469–72.
- [14] Ekici S, Sinanoglu O. Comparison of conventional radiography combined with ultrasonography versus nonenhanced helical computed tomography in evaluation of patients with renal colic. *Urol Res* 2012;**40**:543–7.
- [15] Smith-Bindman R, Aubin C, Bailitz J, Bengiamin RN, Camargo Jr CA, Corbo J, et al. Ultrasonography versus computed tomography for suspected nephrolithiasis. *N Engl J Med* 2014;**371**:1100–10.
- [16] Preminger G, Tiselius H, Assimos D. EAU/AUA nephrolithiasis guideline panel. Guidelines on urolithiasis. *J Urol* 2007;**178**:2418–34.
- [17] Alobaidi M, Shirkhoda A. Value of bone window settings on CT for revealing appendicoliths in patients with appendicitis. *Am J Roentgenol* 2003;**180**:201–5.
- [18] Tanrikut C, Sahani D, Dretler SP. Distinguishing stent from stone: use of bone windows. *Urology* 2004;**63**:823–6.
- [19] Eisner BH, Kambadakone A, Monga M, Anderson JK, Thoreson H, Lee H, et al. Computerized tomography magnified bone windows are superior to standard soft tissue windows for accurate measurement of stone size: an *in vitro* and clinical study. *J Urol* 2009;**181**:1710–5.
- [20] Nadler RB, Stern JA, Kimm S, Hoff F, Rademaker AW. Coronal imaging to assess urinary tract stone size. *J Urol* 2004;**172**:962–4.
- [21] Ather MH, Faizullah KF, Achakzai IA, Siwani R, Irani F. Alternate and incidental diagnoses on noncontrast-enhanced spiral computed tomography for acute flank pain. *Urol J* 2009;**6**:14–8.
- [22] Smith RC, Rosenfield AT, Choe KA, Essenmacher KR, Verga M, Glickman MG, et al. Acute flank pain: comparison of non-contrast-enhanced CT and intravenous urography. *Radiology* 1995;**194**:789–94.
- [23] Lin WC, Uppot RN, Li CS, Hahn PF, Sahani DV. Value of automated coronal reformations from 64-section multidetector row computerized tomography in the diagnosis of urinary stone disease. *J Urol* 2007;**178**:907–11.