

Necrotising granulomata in prostatic resection specimens—a sequel to previous operation

GARRY LEE, NEIL SHEPHERD

From the Department of Histopathology, St Bartholomew's Hospital, West Smithfield, London EC1A 7BE

SUMMARY Six cases, in which necrotising granulomata were discovered in transurethral resection specimens of prostate gland, are described. In four of these cases, granulomata of foreign body type were also present. None of the patients had clinical, microbiological or histological evidence of tuberculosis, past or present. All had had at least one previous prostatectomy. The necrotising granulomata had characteristic microscopic appearances. They were almost certainly caused by operative trauma.

When a pathologist sees necrotising granulomata in prostate tissue, he automatically strongly suspects that the patient has tuberculosis. Even when Ziehl-Neelsen and fluorescent stains fail to show tubercle bacilli and there are no other clinical features to suggest tuberculosis, many pathologists will favour a diagnosis of tuberculosis.

The identification of a histologically similar condition caused by operative trauma is obviously important in order to prevent excessive investigation, unnecessary treatment and clinical uncertainty.

Material and methods

Four hundred and sixty prostatectomy specimens were examined in St Bartholomew's Hospital over the past 2 years. Six cases in which necrotising granulomata were identified, were found. A brief summary of the main features is given in the Table. The types of operation which the patients had are listed sequentially. The total number of granulomata in the positive specimens (necrotising and non-necrotising) is shown and beneath that the number of necrotising granulomata.

In every case the indication for the operation which yielded a specimen with granulomata was the recurrence of obstructive symptoms. In case 2 the presence of a false passage between the bladder and the urethra was observed. In case 4 there was a strong clinical suspicion of malignancy (the prostate felt hard and craggy). This was not confirmed by histology. Patient 5 also had haematuria and patient 6 had known adenocarcinoma of prostate. Patient 1

had late onset diabetes mellitus of long standing, essential hypertension and asymptomatic Paget's disease of bone. Patient 3 had had an episode of the nephrotic syndrome 10 years previously. A renal biopsy was not performed. His renal function is now normal but he has recently developed motor neurone disease. Patient 5 had a history of angina pectoris and duodenal ulceration. None of the patients had a history of allergy.

Slides from each positive specimen were stained with haematoxylin and eosin, PAS, Ziehl-Neelsen, elastic van Gieson and Martius scarlet blue, and reticulin preparations were also performed.

MICROSCOPIC FINDINGS

The frequency of granulomata is shown in the Table. The granulomata varied somewhat in appearance but nearly all conformed to one of two basic types.

The first type bore a strong microscopic resemblance to a rheumatoid nodule. It had a marked tendency to be linear in configuration (Fig. 1). It had a coarsely granular or amorphous eosinophilic core surrounded by a thick band of collagen which contained fibroblasts (Fig. 2). In case 6 fibrin was identified in two of the four necrotising granulomata. Elastic was very scanty in the fibrous collars of the lesions. The necrotic cores contained only a few reticulin fibres though the surrounding tissue showed much reticulin (Fig. 3). Scattered chronic inflammatory cells, mainly lymphocytes, were present at the edges of the necrotic zones, and also surrounding the lesions. Eosinophils were present in the surrounding tissue in small to moderate numbers. Scattered epithelioid and giant cells were

Main features of six cases

	Patient					
	1	2	3	4	5	6
Age (yr)	78	63	67	74	70	56
Operation 1	Open	TUR	TUR	TUR	TUR	TUR
2	TUR	TUR	TUR*	TUR*	TUR*	TUR*
3	TUR*	TUR*				
4		TUR*				
No of granulomas	3	3, 4	7	13	5	4
Necrotising granulomas	3	2, 1	5	12	3	4
Weight of positive specimen (g)	14	24, 6	"10 chips"	16	5.5, 6	13.1
Pre-op UTI	No	No	No	No	No	No
Interoperative interval before granuloma found	3¼ years	13 months, 6 months	48 days	132 days	15 months	8 months

TUR = transurethral resection.

TUR* = transurethral resection (granulomata found).

UTI = urinary tract infection.

present in these lesions, and occasional giant cells were seen in the surrounding tissue (Fig. 2).

The second microscopic type of granuloma was of variable size and was composed of aggregates of epithelioid and foreign body-type giant cells with surrounding lymphocytes, plasma cells and occasional eosinophils (Fig. 4). Birefringent material could not be detected in these lesions, however, and *x*-ray microanalysis of paraffin-embedded sections, performed by Mr Peter Crocker of the Mic-

roanalysis Department, failed to show inorganic foreign material.

In the second prostatectomy specimen of case 2 (see Table 1), hyalinised structures resembling the first type of granuloma were evident (Fig. 5). This operation had been performed after a nine-year interval. A single granuloma of the first type with a central aggregate of polymorphs was seen in case 4.

Discussion

The occurrence of necrotising granulomata in second and subsequent transurethral resection specimens was recently described by Hedelin *et al.*¹ They

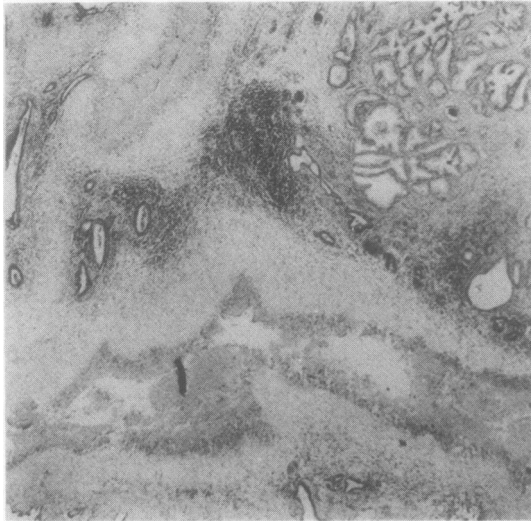


Fig. 1 Case 2, third operation. Linear granuloma with a thick fibrous collar at the bottom. A second granuloma is seen at the top of the picture. Note the collections of lymphocytes between the two lesions. Haematoxylin and eosin $\times 75$.

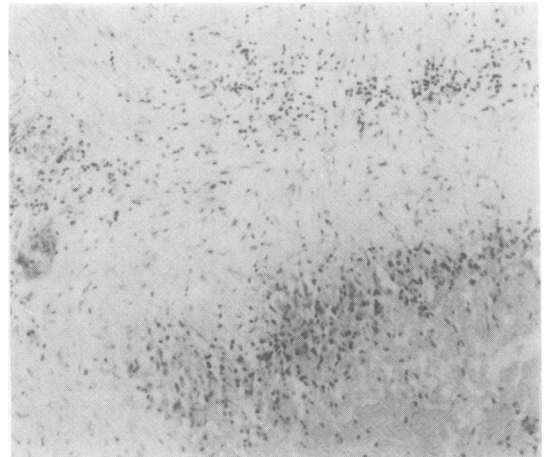


Fig. 2 Case 2, third operation. Edge of the main granuloma seen in Fig. 1. The necrotic core is at the bottom right hand corner. Note the foreign body-type giant cell on the left. Haematoxylin and eosin $\times 300$.

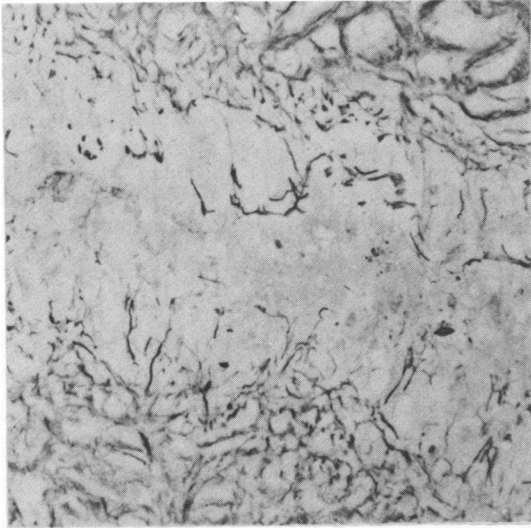


Fig. 3 Scanty reticulin in a linear granuloma. Reticulin $\times 600$.

described six cases and stressed that eosinophils were especially plentiful in the cases with a short interoperative period. However, we found the biggest number in the cases with the longest (3 y 3 months) and shortest (48 days) intervals. Hedelin *et al* did not remark on the peculiar linear configuration of the lesions, nor on the remarkable resemblance they bore to rheumatoid nodules, histologi-

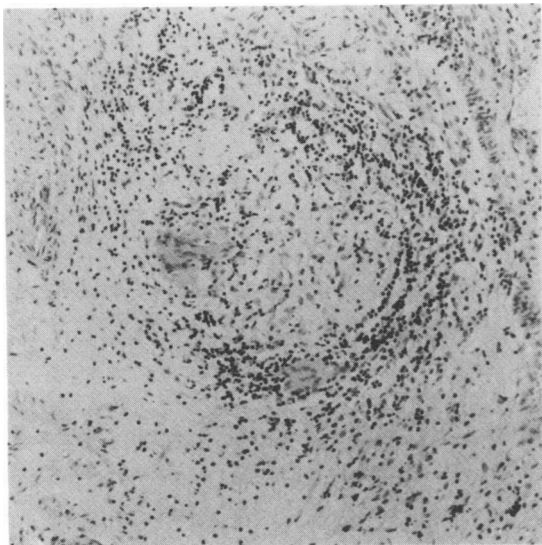


Fig. 4 Case 3. Foreign body-type granuloma. Two giant cells are present. Note the surrounding chronic inflammatory cell infiltrate. Haematoxylin and eosin $\times 300$.

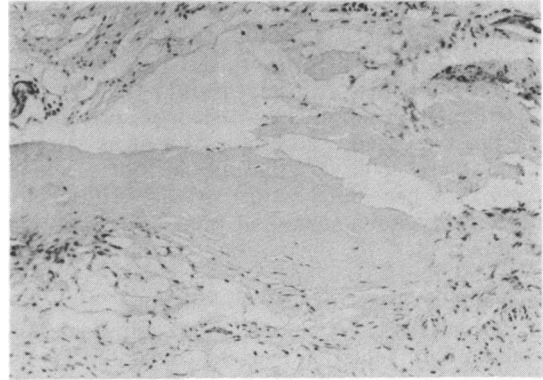


Fig. 5 Case 2, second operation (nine years after the first). Hyalinised linear structure which probably represents an old granuloma. Haematoxylin and eosin $\times 300$.

cally. We found these features with remarkable consistency.

The linearity of these lesions, which are of similar diameter to prostatic ducts raises the possibility that they may be de-epithelialised ducts containing inspissated secretion, which is inciting an inflammatory reaction. However the presence of a little reticulin in the necrotic cores is against this hypothesis. The possibility that they may be thrombosed blood vessels is not supported by the van Gieson stain.

While it is probable that both types of granuloma described represent morphological variants of the same lesion, strong evidence for this is lacking. From the Table it can be seen that both types have been found together in cases with 48 day (shortest) and 13 month (longest) intervals. Also, both granulomata have different shapes, the first being sometimes round, but most often linear, the second always round.

This condition of postoperative granulomata can be distinguished from allergic granulomatous prostatitis² by its focal nature, the history of a previous resection showing no granulomata, and in our patients, the absence of a history of allergy. Non-specific granulomatous prostatitis, first described in 1943³ is discussed by Thybo *et al*⁴ who reported on 19 cases. They found necrotising granulomata in only one case. Also, in this condition, the granulomata are more compact, and are not linear in shape.

The likelihood of a tuberculous aetiology in our lesions is much diminished by the absence of tuberculosis elsewhere in the genitourinary tract (all six patients had normal kidneys on IVP), and the presence of foreign body type granulomata as well as necrotising granulomata. On a purely morphological

basis it would be difficult to exclude tuberculosis as the necrosis in our granulomata looks exactly like caseous necrosis. However, the linearity of the lesions is an almost constant feature.

The relationship of these lesions to infarction of the prostate gland is uncertain. The edges of a prostatic infarct look very like the necrotising granuloma. We have seen a further case with typical necrotising granulomata and frank infarction. It is possible that the necrotising granulomata are microinfarcts. However, we have not seen one with coagulative, as against caseous, necrosis.

It seems likely that initially the necrotising lesions contain fibrin, and that over the course of time this becomes altered until it is hyalinised. However we cannot explain why the Martius scarlet blue stain was only positive in case 6, which was not the earliest lesion. The ideal procedure to investigate these lesions would include serial operations on the same patient, performed at different intervals. This is, of course, out of the question.

The mechanism causing these granulomata remains obscure. None of our cases had preoperative urinary tract infection, and none had anything other than the briefest period of preoperative catheterisation.

Conclusion

When a pathologist discovers necrotising granulomata in prostatic specimens, he should first ascertain whether or not the patient has had a previous prostatectomy, and if so, whether granulomata were present in the original specimen. The peculiar morphology of the lesions we have described should aid in their distinction from prostatic tuberculosis.

References

- ¹ Hedelin H, Johansson S, Nilsson S. Focal prostatic granulomas: a sequel to transurethral resection. *Scand J Urol Nephrol* 1980;**15**:197-200.
- ² Stewart MH, Wray S, Hall M. Allergic prostatitis in asthmatics. *J Pathol Bacteriol* 1954;**67**:423-30.
- ³ Tanner FH, McDonald JR. Granulomatous prostatitis. *Arch Pathol* 1943;**36**:358-70.
- ⁴ Thybo E, Zdravkovic D, Zdravkovic M. Granulomatous prostatitis. *Scand J Urol Nephrol* 1973;**7**:111-4.

Requests for reprints to: Dr G Lee, Department of Histopathology, St Bartholomew's Hospital, West Smithfield, London EC1A 7BE, England.