

## The exanthem of Ross River virus infection: histology, location of virus antigen and nature of inflammatory infiltrate

J ROBERT E FRASER,\* V MALA RATNAMOHAN,\* JOHN PG DOWLING,† GAVIN J BECKER,‡ GEORGE A VARIGOS\*

From the University of Melbourne Department of \*Medicine, and the Departments of †Anatomical Pathology and ‡Nephrology, The Royal Melbourne Hospital, Victoria, Australia

**SUMMARY** The exanthem of epidemic polyarthritides, a disease caused by Ross River (RR) virus, was examined three days after onset of the common erythematous and the rare purpuric forms of the eruption. The dermis showed a light perivascular infiltrate of mononuclear cells in both, with extravasation of erythrocytes in the latter. No immunoglobulins (IgM, IgG, IgA) or complement components (C1q, C3) were detected. Most of the infiltrating cells were T lymphocytes of the T suppressor-cytotoxic class. Their perivascular location, the scarcity of other lymphocytes or phagocytes, and rapid resolution of the rash indicated that the T lymphocytes were responsible for cytotoxic destruction of virus-infected cells. A few monocyte-macrophage cells were identified in the perivascular infiltrate. RR virus antigen was found in the basal epidermal and eccrine duct epithelial cells of both types of lesion and in the perivascular zone of the erythematous lesion, but appeared to have been eliminated from this region in the purpuric lesion. It is suggested that secondary effects of the T-cytotoxic reaction on nearby capillaries are responsible for erythema, oedema and purpura in the exanthem.

Many virus infections merely result in immunity with trivial symptoms or none at all, and the levels of specific circulating antibody often show little relation to the outcome. The nature of the cellular response to virus infection has therefore been closely scrutinised both for its part in elimination of infection and for its possible contribution to the occurrence of disease. Much of this work has of necessity been limited to studies *in vitro* or to experimental animal infections. With the development of monoclonal antibodies and other immunological techniques, the proportions of circulating T and B lymphocytes and T cell subsets have been determined in some human virus diseases.<sup>1-3</sup> The infiltrating cells in tissue lesions have been similarly examined in inflammatory diseases of undetermined nature such as rheumatoid arthritis,<sup>4,5</sup> in skin disease,<sup>6,7</sup> in leprosy<sup>8</sup> and in chronic hepatitis associated with hepatitis B antigenaemia<sup>9</sup> but comparable studies in acute human virus diseases have not been reported at the time of writing.

Epidemic polyarthritides is the major clinical syndrome arising from infection with RR virus, a

mosquito-borne alphavirus. About two-thirds of the patients develop a rash, which is usually maculopapular and resolves in 5-10 days. It sometimes includes purpuric lesions and small vesicles,<sup>10</sup> but these are rarely numerous. The rheumatic manifestations are both articular and extra-articular, and can persist as long as three years. The virus is endemic in Australia and the South Pacific, and is classified with rubella in the *Togaviridae*. Both viruses are of particular interest for their capacity to induce rheumatic disease.

The only cytopathology of the disease reported to date is that of the synovial exudate, which is predominantly mononuclear in both the acute and chronic phases.<sup>11,12</sup> We describe here the pathological features of the rash in its usual form at the height of its development, and in another example notable for the exceptionally high proportion and extent of purpuric lesions.

### Material and methods

#### SOURCES OF TISSUE

##### Case 1

Erythematous papular lesions were obtained from a

man of 39 yr who had worked for ten months in an area of endemic risk for RR virus infection but had been well until the onset of polyarthritis with Achilles tendonitis six days before skin biopsy. An irritable maculopapular rash, which faded on pressure, appeared three days before biopsy and spread to involve the whole of the trunk and limbs, including palms and soles, until it was nearly confluent at the time of examination. Clinical findings were consistent with epidemic polyarthritis. Appropriate tests showed no evidence of heterophile antibodies, recent  $\beta$ -haemolytic streptococcal infection or of renal or hepatic dysfunction. Peripheral blood showed normal haemoglobin, erythrocyte sedimentation rate of 7 mm/h (Westergren), and a leucocyte count of  $4.4 \times 10^9/l$  with some atypical lymphocytes but an otherwise normal pattern. Diagnosis was confirmed by a rise in serum haemagglutination-inhibition (HI) antibody titre to RR virus from 1/20 on the first day of illness to 1/160 two weeks later. The rash resolved within three days. The patient's recovery was complete in two weeks, and he had suffered no relapses when reviewed 8 months later.

#### Case 2

Purpuric papules were excised from a woman of 33 yr who developed rash and polyarthritis with swelling of ankles and digital joints six days after leaving regions of high RR virus prevalence. The rash consisted of red macules and papules scantily distributed on the arms, wrists, palms, fingers, trunk, feet and soles, and much more numerous on the shins and buttocks. Some in the latter site showed small vesicles. The majority did not blanch on pressure, and were 1–2 mm in diameter, with a few to 5 mm. Face and oral mucosa were spared. There were no abdominal symptoms. Urine analysis including cell counts was normal. Peripheral blood showed normal haemoglobin, leucocytes ( $5.2 \times 10^9/l$ ) and platelet count ( $204 \times 10^{12}/l$ ). Erythrocyte sedimentation rate was 41 mm/h (Westergren). Other diagnostic tests cited in the first patient, together with serological tests for hepatitis A and B, IgM rheumatoid factors, tissue antinuclear factor and DNA antibodies were negative. Skin biopsies of lesions identified by the patient as recent were done three days after onset. The last of the purpura had faded in two weeks. Rheumatic symptoms and signs had almost completely subsided three weeks after onset, and the erythrocyte sedimentation rate had returned to normal (9 mm/h). Serum HI antibody titres against RR virus were 1/40 on the third day of illness, and 1/20 after three weeks. These levels are significant but unusually low for the acute phase of the disease, but both samples were however

shown by ELISA to contain specific IgM antibodies (courtesy of Dr J Aaskov).

With local anaesthesia, lesions were removed from the trunk in the first patient and from the palm and fingers in the second, by excision through the deeper layers of the dermis with a trephine of 4 mm diameter and a fine scalpel. Sections were immediately frozen at  $-70^\circ\text{C}$  for immunochemical staining, fixed overnight in buffered formalin for routine histology, and fixed in 2.5% glutaraldehyde in 0.1 M cacodylate buffer, pH 7.3, for electron microscopy. Cultures for virus were prepared from frozen and fresh tissue.

#### HISTOLOGY

Paraffin-embedded sections were stained with haematoxylin and eosin, and with orcein-Giemsa. For electron microscopy, tissue was dehydrated in acetone and embedded in Spurr's resin after post-fixation in 2%  $\text{OsO}_4$  for 1 h. Sections of 800 nm were stained with 2% uranyl nitrate and Reynold's nitrate.

#### ANTISERA

Normal rabbit serum and rabbit antiserum against the prototype strain of RR virus (T48; neutralising titre 1/250) were absorbed in two steps (2 h at  $37^\circ\text{C}$  and 16 h at  $4^\circ\text{C}$ ) with 6 mg of dried defatted human skin powder per ml, and diluted 1/20. Sources and dilutions of fluorescein-conjugated sheep antisera were as follows: antihuman IgM (1/15), IgA (1/15), IgG (1/30), C3 (1/15) Wellcome Aust Ltd, Melbourne and antirabbit IgG (1/20), fibrinogen (1/20) and Clq (1/15), Boehringer-Hoechst, Melbourne.

#### FLUORESCENT STAINING

Frozen sections ( $6 \mu\text{m}$ ) were airdried, incubated with serum diluted in phosphate-buffered saline (pH 7.4) for 30 min at  $37^\circ\text{C}$  and washed for 15 min in three changes of buffer between successive steps and before mounting in buffered glycerol medium (pH 8.6). Positive and negative controls for the specific antisera consisted of RR virus-infected and uninfected human and insect cell cultures, and concurrent biopsy specimens from various skin and renal diseases (non-specific dermatitis, bullous pemphigoid, pemphigus vulgaris, lupus erythematosus, IgA-, membranous and post-infective nephropathies). Preparations were examined with a Zeiss Photomicroscope II fitted with exciter filter BP450–490 and barrier filter LP520.

#### IDENTIFICATION OF CELLULAR INFILTRATES

Frozen sections ( $6 \mu\text{m}$ ) were fixed in paraformaldehyde-lysine-periodate (PLP) and

Table 1 *Immunofluorescent and immunoperoxidase staining in skin*

Antibody	Specificity	Site of positive reaction	Comparative numbers of positive cells*	
			Case 1	Case 2
PHM1	All leucocytes <sup>13</sup>	Dermis: perivascular and scattered	++++	ND
OKT3	T lymphocytes <sup>15</sup>	Dermis: perivascular	+++	0
OKT4	T (inducer/helper) <sup>16</sup>	Dermis: occasional cells in some perivascular zones	+/-	0
OKT8	T (cytotoxic/suppressor) <sup>17</sup>	Dermis: perivascular	+++	+++
FMC32	Monocyte-macrophage <sup>18</sup>	Dermis: perivascular and scattered	+	+/-
RRV†	Ross River virus	Basal epidermal cells	++	++
		Duct epithelial cells	+	+
		Dermis, perivascular	+++	0
		Epidermis only	+	+
OKT6	Langerhans cells	Dermis: probably mast cells	Very few	ND
FMC10	Granulocytes <sup>20</sup>	—	0	ND
OKT10	Natural killer cells <sup>21</sup>	—	0	ND
Various†	IgM, IgG, IgA, C3, C1q, fibrin	—	0	0

\*The degree of cellular infiltration was varied and generally light.

The grades compare the proportions of reactive cells.

The smaller lesion in case 2 provided insufficient material for all reagents; ND = not done.

†Polyclonal antisera.

stained by a four-layer unlabelled peroxidase technique<sup>13,14</sup> comprising sequential incubation with mouse monoclonal antibody, rabbit antimouse antibody, excess sheep antirabbit antibody and preformed rabbit peroxidase-antiperoxidase complexes.

Tissue-bound peroxidase was then detected by incubation with diaminobenzidine (DAB) and H<sub>2</sub>O<sub>2</sub>. Endogenous peroxidase activity was blocked by the addition of NaN<sub>3</sub> (0.3%) to the DAB solution.<sup>13</sup> Monoclonal antibodies employed and their specificities are shown in Table 1.

Macrophages were also identified histochemically by staining for  $\beta$ -glucuronidase.<sup>22</sup>

#### ATTEMPTED GROWTH OF VIRUS

Approximately 6 mm<sup>3</sup> of skin was mechanically homogenised in 1 ml of Eagle's minimum essential medium. Confluent test tube cultures of *Aedes albopictus* cells, C6/36 strain, were inoculated with 0.1 ml of the homogenate and incubated at 30°C in appropriate growth medium. At three-day intervals, replicate cultures were frozen and thawed twice before passage into fresh C6/36 cultures. Supernatant was inoculated into Vero cell monolayers, which were incubated at 37°C and observed for cytopathic effects. Cells from inoculated and control C6/36 cultures were also examined at each passage by the indirect immunofluorescence technique. In the second case, peripheral blood buffy coat cells and culture medium from a primary culture of the skin were also used to inoculate the insect cell cultures. Cultures inoculated with 0.1 ml aliquots of the patient's acute-phase serum, diluted 1/10, were treated similarly.

## Results

#### LIGHT MICROSCOPY

The sole changes were slight perivascular oedema and leucocytic infiltration in the erythematous lesions of case 1 with a light extravasation of erythrocytes in the purpuric lesions of case 2 (Fig. 1). The intensity of the infiltrates varied in different regions of the specimens, but the cells were consistently mononuclear. The epidermis was normal except for "clear" cells in the lower prickle cell layer, attributed to the anaesthetic. No platelet aggregation, thrombosis, fibrin deposition, or conspicuous endothelial damage was seen.

#### IMMUNOFLUORESCENT STAINING

Minimal random punctate staining occurred with anti-albumin antiserum. No staining was seen with antisera against IgM, IgG, IgA, fibrinogen, C3 or C1q. Specific staining for RR virus antigen (Fig. 2) was detected in the basal epidermal layer and in eccrine duct epithelial cells of both cases. Antigen was also prominent in the perivascular regions in the erythematous but not in the purpuric lesion although the OKT8<sup>+</sup> lymphocytes were most numerous in this region of both types of lesion.

#### ELECTRON MICROSCOPY

In case 1, the perivascular infiltrate included typical lymphocytes, moderately vacuolated cells of histiocyte-macrophage type and slightly more cells of indeterminate class with short filipodia, and a little vacuolation (Fig. 3). The endothelial cells were normal. In case 2, the infiltrating cells were mainly lymphocytes. Small vessels showed swelling of

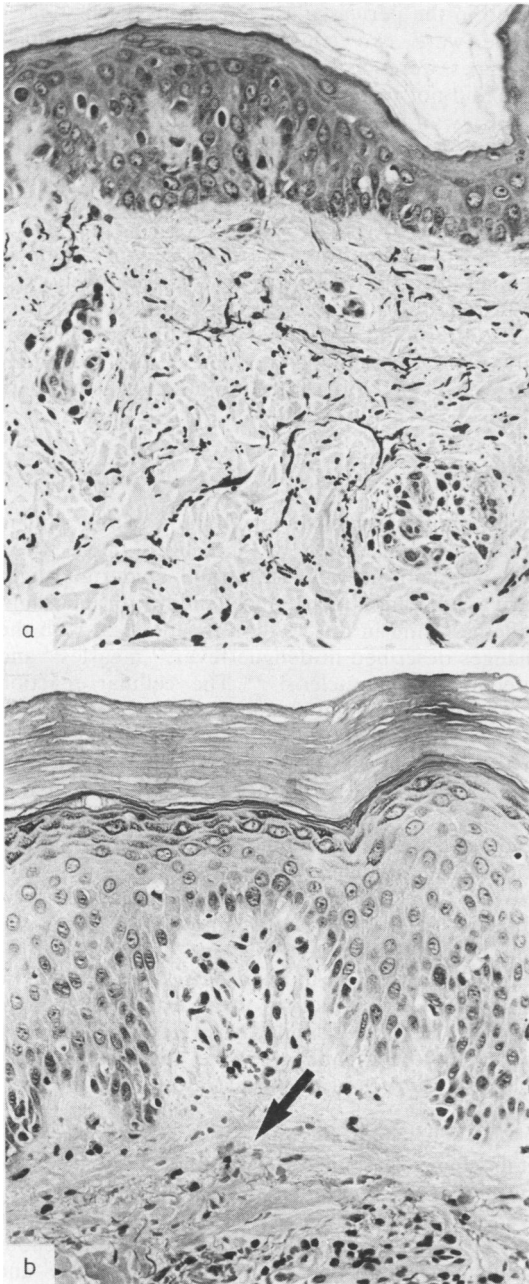


Fig. 1 (a) Case 1. Light perivascular collections of mononuclear cells in superficial dermis. Elastin fibres stained black. Orcein-Giemsa stain. Original magnification  $\times 160$ . (b) Case 2. Similar perivascular pattern of mononuclear cells, with extravasation of erythrocytes (arrow) into oedematous dermis. Haematoxylin and eosin stain. Original magnification  $\times 160$ .

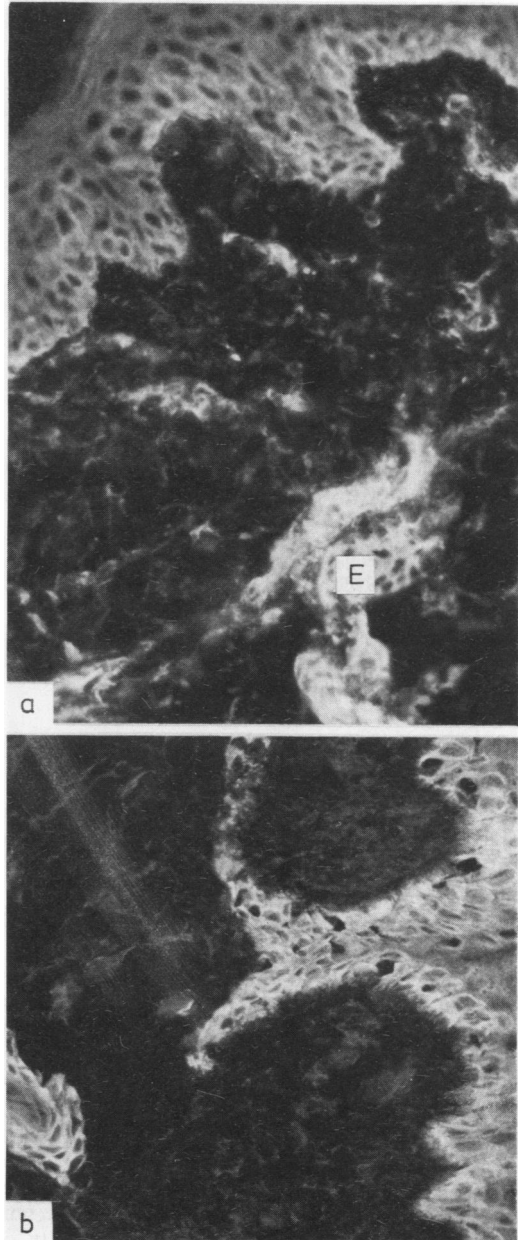


Fig. 2 Location of virus antigen by indirect immunofluorescence. (a) Case 1. Antigen was detected in cellular connective tissue surrounding superficial dermal vessels, within the basal layers of the epidermis and eccrine duct epithelium (E). Magnification  $\times 250$ . (b) Case 2. Antigen was detected in the basal layers of the epidermis and in eccrine duct-epithelium, but not in the perivascular tissue. Magnification  $\times 250$ .

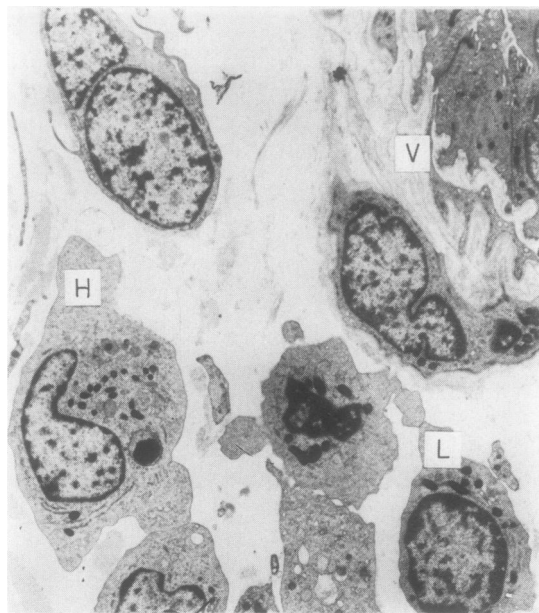


Fig. 3 Mixed collection of lymphocytes (L) and histiocytes (H) adjacent to vessel wall (V). Case 1. Electron microscopy. Magnification  $\times 3600$ .

endothelial cytoplasm and thickening of the basement membrane, but no deposition of fibrin. No virus particles were found in either. Typical Langerhans cells with Birbeck granules were identified in both cases, but only in the epidermis.

#### IDENTIFICATION OF CELLS WITH MONOCLONAL REAGENTS

In the erythematous lesion (*case 1*), most of the infiltrating cells reacted with the pan-T lymphocyte antibody, OKT3, and with the reagent for common leucocyte antigen, PHM1. In the perivascular infiltrates, small numbers of cells reacted with the monocyte-macrophage reagent, FMC32. The distribution of  $\beta$ -glucuronidase activity was similar. The most numerous cells in this region were OKT8-positive. Very few were OKT4-positive (Fig. 4). Only two granulocytes were identified in one section with FMC10 antibody. A normal density of Langerhans cells was found in the lower and mid-spinous layers of epidermis with OKT6, but none was detected in the dermis. No cells reacted with OKT10. Single dermal cells which stained with PHM1 and FMC32 outside the perivascular region were considered to be normal tissue histiocytes.

Examination of the smaller purpuric lesion was limited to selected reagents. The cellular infiltrates were almost entirely OKT8-positive, and concen-

trated in the perivascular zones as in the first case. There were two conspicuous differences: macrophages were distinctly scarce, and the lymphocytes did not react with OKT3.

In view of the irregular cell distribution and clear distinctions observed, the results are summarised in grades rather than proportional counts (Table 1).

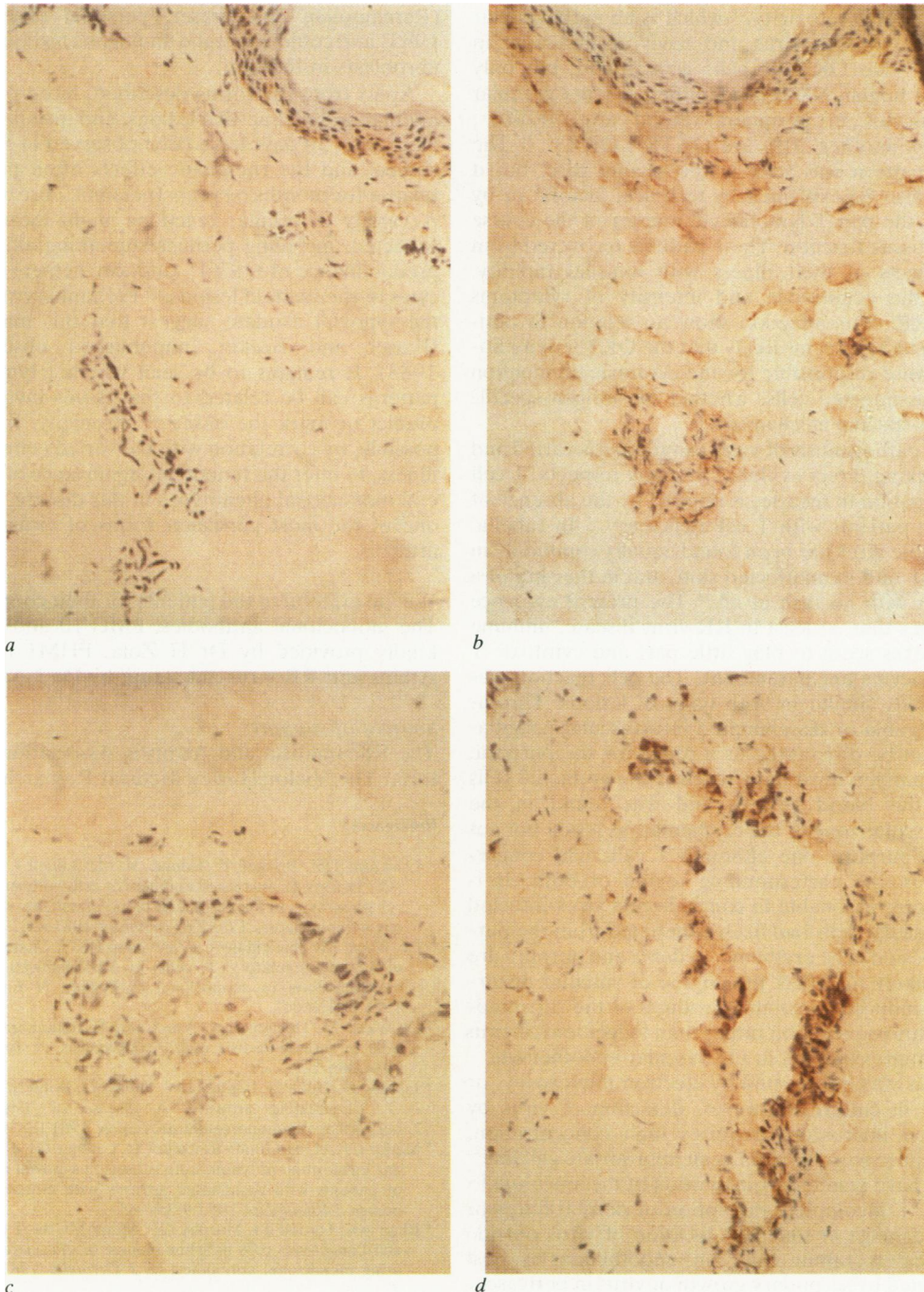
#### VIRUS CULTURE

All inoculated cultures were treated in a similar manner. Growth medium from *Aedes albopictus* cell cultures at the first, second, fourth, and seventh passages induced no cytopathic effects in Vero cell cultures. No virus antigen was detected in the *Aedes albopictus* cells at the fifth, ninth and eleventh passages.

#### Discussion

Opportunities for histological study of the skin in non-fatal exanthematous infections have been understandably few. The normal epidermis, light perivascular mononuclear cell infiltrate and slight oedema found in this study were identical with the changes described in dengue fever,<sup>23</sup> measles<sup>24</sup> and infectious mononucleosis.<sup>25</sup> The cellular reaction was remarkably slight in contrast with the erythema. It was nevertheless similar in nature to that observed in the synovial effusions of epidemic polyarthritis, where intracellular virus antigen is easily detected in the first few days, no other elements of immune complex have been found, and the cells are almost entirely mononuclear.<sup>11,12</sup> Monocytes and macrophages are, however, more numerous than lymphocytes in the early effusions. Vasodilation, the major clinical feature of this kind of rash, was obscured in the section by blanching after anaesthetic infiltration and retraction of the excised specimen. Despite the clinical similarity to Henoch-Schönlein disease in the second case, the characteristic histological features of this disease were entirely lacking.

The participating cells were characterised by monoclonal antibodies as T lymphocytes and cells of the monocyte-macrophage class, with few granulocytes and no B lymphocytes or other cells bearing surface immunoglobulin. The most conspicuous findings were the predominance of the OKT8 and the scarcity of the OKT4 phenotypes. The former have been shown *in vitro* mainly to suppress activation of B lymphocyte immunoglobulin synthesis, which requires OKT4 cell cooperation, and to exhibit alloantigen-specific lymphocytotoxicity.<sup>26,27,28</sup> Cloning of alloantigen-activated T lymphocytes has shown that OKT8<sup>+</sup> cells can alternatively manifest the less specific "natural killer" (NK)



**Fig. 4** Sections stained by monoclonal antibodies. Case 1. (a) Control preparation with unreactive monoclonal cell culture medium. Brown pigment is seen only as melanin in the epidermis. Magnification  $\times 250$ . (b) FMC32 antibody against monocytes and macrophages. Brown peroxidase staining in dermal perivascular cells, and scattered through dermis. Magnification  $\times 250$ . (c) OKT4 antibody against T helper/inducer lymphocytes. Light background staining, but no positive staining in cellular perivascular area. Clear area caused by separation artefact. Magnification  $\times 400$ . (d) OKT8 antibody against T cytotoxic/suppressor cells. Strong peroxidase staining in dermal cells round small vessels. Larger clear areas are artefacts. Magnification  $\times 400$ .

cell type of cytotoxicity,<sup>29</sup> which is an early cellular response to alphavirus and flavivirus infection in mice.<sup>30,31</sup> No OKT10<sup>+</sup> cells were found, but only 62% of human NK cells identified as large granular lymphocytes in peripheral blood are OKT10<sup>+</sup>, whereas another 20% are OKT8<sup>+</sup>, OKT3<sup>-</sup>.<sup>21</sup> The latter pattern was seen in the second case, but it might also be explained by technical factors<sup>8</sup> or by loss of the pan-T lymphocyte marker in the course of the tissue reaction. These patients recovered from all aspects of their illness with unusual rapidity. Since the occurrence and intensity of symptoms after RR virus infection show no relation to antibody levels, it seems likely that the OKT8<sup>+</sup> lymphocytes were responsible for the cytotoxic elimination of virus-infected cells, whether by antigen-specific or non-specific mechanisms.

The pathogenesis of virus exanthems is varied and still lacking direct evidence in many respects. T cell participation in measles is implied by the absence of rash in patients with T cell deficiency.<sup>32</sup> In rubella, cultivable virus has been found equally commonly in the rash and in unaffected skin, and in the skin of a patient with no rash at all.<sup>33</sup> The present evidence indicates that, at least in RR virus disease, immune complexes seem to play little part and cytotoxic T lymphocytes are paramount. The cell reaction was essentially similar in both types of lesions. Thrombocytopenia or disseminated intravascular coagulation can be discounted as a cause for the purpura. Virus antigen must have reached the epithelial cells from the blood vessels, and was found in the perivascular zone of the erythematous lesion but not of the purpuric one although T cells had congregated in the corresponding region of both. It is therefore reasonable to conclude that virus-infected perivascular cells had been eliminated from the purpuric lesion. The erythema, oedema and purpura are most likely to reflect the degree of vascular disturbance induced by soluble products of the surrounding cytotoxic reaction rather than lodgement of virus or immune complex in the vascular endothelium.

Virus was not located by electron microscopy, or grown in culture. However, detection of virus by electron microscopy requires high concentration, and failure to grow virus in an appropriate cell line<sup>34</sup> might have resulted from dilution of the inoculum ( $5 \times 10^{-4}$ ), incomplete disruption of dermal fibres or prior damage *in situ*. The location of virus outside the vessels rather than on endothelium is best explained by secondary growth of virus in perivascular dermal cells and spread to epithelium after the viraemic phase of infection. RR virus grows well in primary human synovial cell cultures (Cunningham and Fraser, unpublished observations 1980) and in early-passage human synovial lines of fibroblast type

(Ratnamohan and Fraser, personal observations 1983) and could infect the analogous histiocytes and fibroblasts in the skin.

Apart from the forms described, more persistent nodular and plaque-like lesions, and macules lasting more than 30 days have been observed in RR virus disease and the rheumatic effects often persist or relapse for months or years (personal observations). A variety of cellular reactions might therefore be expected, including perhaps something akin to the predominance of OKT4<sup>+</sup> (inducer-helper) lymphocytes in rheumatoid lesions.<sup>4,5</sup> Preliminary studies of the synovial exudate suggest that this may be so (Fraser and Becker, unpublished observations 1983). It remains to be seen whether lymphocyte patterns can be related to the tissues involved, or predict or mark the onset of chronicity. It may be possible, by correlation with the varied course of the illness, to infer the functional significance of the several monoclonal phenotypes in this disease, which is one of the most persistent forms of virus-induced arthritis.

We are grateful to the patients for their cooperation. The monoclonal antibodies, FMC 10 and 32 were kindly provided by Dr H Zola, PHM1 by Dr R Atkins and RR virus antiserum by Dr J Aaskov.

#### Sources of support:

The Rheumatism and Arthritis Association of Victoria. The Victor Hurley Medical Research Fund.

#### References

- Crawford DH, Brickell P, Tidman N, McConnell I, Hoffbrand AV, Janossy G. Increased numbers of cells with suppressor T cell phenotype in the peripheral blood of patients with infectious mononucleosis. *Clin Exp Immunol* 1981;**43**:291-7.
- De Waele M, Thielemans C, Van Camp BKG. Characterization of immunoregulatory T cells in EBV-induced infectious mononucleosis by monoclonal antibodies. *N Engl J Med* 1981;**304**:460-2.
- De Waele M, Thielemans C, Van Camp B. Immunoregulatory T cells in mononucleosis and toxoplasmosis. *N Engl J Med* 1981;**305**:228.
- Janossy G, Duke O, Poulter LW, Panayi G, Bofill M, Goldstein G. Rheumatoid arthritis: A disease of T-lymphocyte/macrophage immunoregulation. *Lancet* 1981;ii:839-42.
- Meijer CJLM, de Graaff-Reitsma CB, Lafeber GJM, Cats A. *In situ* localization of lymphocyte subsets in synovial membranes of patients with rheumatoid arthritis with monoclonal antibodies. *J Rheumatol* 1982;**9**:359-65.
- Bhan AK, Harrist TJ, Murphy GF, Mihm MC Jr. T cell subsets and Langerhans cells in lichen planus: *In situ* characterization using monoclonal antibodies. *Br J Dermatol* 1981;**105**:617-22.
- McMillan EM, Beeman K, Wasik R, Everett MA. Demonstration of OKT6-reactive cells in mycosis fungoides. *Am Acad Dermatol* 1982;**6**:880-7.
- Van Voorhis WC, Kaplan G, Sarno EN, *et al*. The cutaneous infiltrates of leprosy. *N Engl J Med* 1982;**307**:1593-7.
- Janossy G, Montano L, Selby WS, *et al*. T cell subset

- abnormalities in tissue lesions developing during autoimmune disorders, viral infection and graft-versus-host disease. *J Clin Immunol* 1983;**2**, 3 July suppl: 42-55.
- <sup>10</sup> Anderson SG, French EL. An epidemic exanthem associated with polyarthritis in the Murray Valley, 1956. *Med J Aust* 1957;**2**:113.
- <sup>11</sup> Clarris BJ, Doherty RL, Fraser JRE, French EL, Muirden KD. Epidemic polyarthritis: A cytological virological and immunochemical study. *Aust NZ J Med* 1975;**5**:450-7.
- <sup>12</sup> Fraser JRE, Cunningham AL, Clarris BJ, Aaskov JG, Leach R. Cytology of synovial effusions in epidemic polyarthritis. *Aust NZ J Med* 1981;**11**:168-73.
- <sup>13</sup> Becker GJ, Hancock WW, Kraft N, Lanyon HC, Atkins RC. Monoclonal antibodies to human macrophage and leucocyte common antigens. *Pathology* 1981;**13**:669-80.
- <sup>14</sup> Hancock WW, Becker GJ, Atkins RC. A comparison of fixatives and immunohistochemical techniques for use with monoclonal antibodies to cell surface antigens. *Am J Clin Pathol* 1982;**78**:825-31.
- <sup>15</sup> Kung PC, Goldstein G, Reinherz EL, Schlossman SF. Monoclonal antibodies defining distinctive human T cell antigens. *Science* 1979;**206**:347-9.
- <sup>16</sup> Reinherz EL, Kung PC, Goldstein G, Schlossman SF. Separation of functional subsets of human T cells by a monoclonal antibody. *Proc Natl Acad Sci USA* 1979;**76**:4061-5.
- <sup>17</sup> Reinherz EL, Kung PC, Goldstein G, Levey RH, Schlossman SF. Discrete stages of human intrathymic differentiation: analysis of normal thymocytes and leukemic lymphoblasts of T-cell lineage. *Proc Natl Acad Sci USA* 1980;**77**:1588-92.
- <sup>18</sup> Brooks DA, Zola H, McNamara PJ, Bradley J, Bradstock KF, Hancock WW, Atkins RC. Membrane antigens of human cells of the monocyte/macrophage lineage studied with monoclonal antibodies. *Pathology* 1983;**15**:45-52.
- <sup>19</sup> Fithian E, Kung P, Goldstein G, Rubenfeld M, Fenoglio C, Edelson R. Reactivity of Langerhans cells with hybridoma antibody. *Proc Natl Acad Sci USA* 1981;**78**:2541-4.
- <sup>20</sup> Zola H, McNamara P, Thomas M, Smart IJ, Bradley J. The preparation and properties of monoclonal antibodies against human granulocyte membrane antigens. *Br J Haematol* 1981;**48**:481-90.
- <sup>21</sup> Ortaldo JR, Sharrow SO, Timonen T, Herberman B. Determination of surface antigens on highly purified human NK cells by flow cytometry with monoclonal antibodies. *J Immunol* 1981;**127**:2401-7.
- <sup>22</sup> Nayashi M, Nakajima Y, Fishman WH. The cytologic demonstration of beta-glucuronidase employing naphthol AS-B1 glucuronide and hexazonium pararosanilin: a preliminary report. *J Histochem Cytochem* 1964;**12**:293-7.
- <sup>23</sup> Sabin AB. Research on dengue during World War II. *Am J Trop Med Hyg* 1952;**1**:130-50.
- <sup>24</sup> Allen AC. The skin. A clinicopathologic treatise. 1954. St Louis: CV Mosby Co, 1954:307-8.
- <sup>25</sup> Ackerman AB. Histologic diagnosis of inflammatory skin diseases. Philadelphia: Lea and Febiger, 1978:198.
- <sup>26</sup> Thomas Y, Sosman J, Irigoyen O, *et al.* Functional analysis of human T cell subsets defined by monoclonal antibodies. 1. Collaborative T-T interactions in the immunoregulation of B cell differentiation. *J Immunol* 1980;**125**:2402-8.
- <sup>27</sup> Reinherz EL, Kung PC, Goldstein G, Schlossman SF. A monoclonal antibody reactive with the human cytotoxic/suppressor T cell subset previously defined by a heteroantiserum termed TH<sub>2</sub>. *J Immunol* 1980;**124**:1301-7.
- <sup>28</sup> Reinherz EL, Schlossman SF. The differentiation and function of human T lymphocytes. *Cell* 1980;**19**:821-7.
- <sup>29</sup> Moretta L, Mingari MC, Sekaly PR, Moretta A, Chapuis B, Cerottini J-C. Surface markers of cloned human T cells with various cytolytic activities. *J Exp Med* 1981;**154**:569-74.
- <sup>30</sup> MacFarlan RI, Burns WH, White DO. Two cytotoxic cells in peritoneal cavity of virus-infected mice: Antibody-dependent macrophages and nonspecific killer cells. *J Immunol* 1977;**199**:1569-74.
- <sup>31</sup> MacFarlan RK, White DO. Further characterization of natural killer cells induced by Kunjin virus. *Aust J Exp Biol Med Sci* 1980;**58**:77-89.
- <sup>32</sup> Mims CA. The pathogenesis of infectious disease. London: Academic Press, 1977: 159.
- <sup>33</sup> Heggie AD. Pathogenesis of the rubella exanthem: Distribution of rubella virus in the skin during rubella with and without rash. *J Infect Dis* 1978;**137**:74-7.
- <sup>34</sup> Rosen L, Gubler DJ, Bennett PH. Epidemic polyarthritis (Ross River) virus infection in the Cook Islands. *Am J Trop Med Hyg* 1981;**30**:1294-302.

Requests for reprints to: Dr JRE Fraser, University of Melbourne Department of Medicine, The Royal Melbourne Hospital PO, Victoria, 3050, Australia.