

Detection of *Chlamydia trachomatis* inclusions in McCoy and HeLa-229 cells: an alternative staining technique using toluidine blue

NOORIA RS MOHAMMED, IRENE B HILLARY

From the Department of Medical Microbiology, University College Dublin, Ireland

SUMMARY Toluidine blue staining was used to detect *Chlamydia trachomatis* inclusions in both McCoy and HeLa-229 cells from clinical specimens. This method was more sensitive than iodine staining for detecting *C trachomatis* inclusions in both McCoy and HeLa-229 cells and also more sensitive than Giemsa staining for detecting chlamydial inclusions in HeLa-229 cells. While its sensitivity for detection of chlamydial inclusions in McCoy cells is equal to that of Giemsa staining, toluidine blue staining is easier and faster to perform.

Different staining methods have been used to detect chlamydial inclusions in cell cultures. Giemsa staining followed by dark ground microscopy has been the most commonly used technique. The glycogen matrix of *Chlamydia trachomatis* inclusions can be detected using various stains—for example, iodine,¹ carmine,² and periodic acid Schiff.³ Iodine staining combined with bright field microscopy is probably the simplest of all staining techniques for detecting *C trachomatis* inclusions, but compared with Giemsa and carmine it is less sensitive.⁴ Periodic acid Schiff stain is useful in that inclusions are detectable by both bright and dark field microscopy, but the actual staining technique is quite complex, as is that for carmine.⁵ Methylene blue stain combined with dark field microscopy is said to be useful for the diagnosis of infection caused by the enzootic ovine abortion strain of *C psittaci*.⁶ But it offers no advantage over Giemsa or iodine stains for the detection of *C trachomatis* inclusions.⁵

Immunofluorescent staining⁷ seems to be both fast and sensitive but it requires the use of expensive reagents. Recently, a methyl green-neutral red staining technique has been found to be highly sensitive for detecting *C psittaci* inclusions combined with bright field microscopy.⁸ It is as sensitive as Giemsa staining combined with dark field microscopy for detecting *C trachomatis* inclusions.

We report a simple, fast technique for detecting *C trachomatis* inclusions using toluidine blue, effective with both bright and dark field microscopy. We have compared its sensitivity with that of Giemsa and

iodine stains for detecting *C trachomatis* inclusions from clinical specimens using McCoy and HeLa-229 cells.

Material and methods

CLINICAL SPECIMENS

Cervical, urethral, and eye swabs received at the Virus Reference Laboratory, Department of Medical Microbiology, University College Dublin, which were positive for chlamydiae by Giemsa staining were used in this study.

Fresh swabs from patients were immersed in bijoux bottles containing 2 ml of transport medium consisting of medium 199 supplemented with 10% fetal calf serum, 10% sorbitol, 200 µg/ml streptomycin, and 100 units/ml mycostatin, adjusted to pH 7.2-7.4 with 4.4% sodium bicarbonate. All specimens were stored at -70°C on arrival at the laboratory until inoculated.

CELL CULTURES

The preparation of cycloheximide-treated McCoy coverslip monolayer cultures and isolation procedures were as described by Davies *et al*⁹ except that vials were seeded with 2 ml of cell suspension at a concentration of 3×10^5 cells per ml and allowed to form a monolayer.

For preparation of HeLa-229 monolayers 2 ml of cell suspension containing 3×10^5 cells per ml was dispensed into flat bottomed vials containing 10 mm diameter coverslips. The seeded vials were incubated at 36°C for 24 h. Cell monolayers which

Table 1 *Chlamydia trachomatis* inclusion counts in McCoy cells

Clinical specimens	*Mean inclusion count (Ic)		
	Giemsa	Iodine	Toluidine blue
Cervix	244	76	238
"	1602	389	1572
"	26	7	29
"	42	12	42
"	2783	900	2700
"	1115	269	1104
"	14	4	15
Urethral	10	3	10
"	5577	1138	5466
"	5	0	5
"	980	222	980
"	7038	2163	8652
Eye	733	138	704
"	18	4	17
"	368	69	335

*Mean number counted on two coverslips.

Ic = Inclusion count in 10 mm coverslip cultures.

formed on the coverslips were then treated with cycloheximide in fresh growth medium to give a final concentration of 1 µg/ml immediately before inoculation. Clinical specimens were homogenised on a Vortex mixer before inoculation. Six monolayer cultures of each cell line were used for each specimen and the inoculum volume was 0.2 ml. Inoculated cultures were centrifuged at 3500 rpm (MSE Super-Medium) for 1 h and then incubated at 36°C in an atmosphere of 5% CO₂. After 48 h, two cultures of each type were stained by Giemsa stain, two by iodine, and two by toluidine blue.

The procedure used for counting inclusions was as described by Johnson and Hobson.¹⁰

STAINING TECHNIQUES

Toluidine blue monolayer cultures infected with chlamydiae were fixed in absolute methanol for 5 min. This was replaced by toluidine blue (BDH Chemicals Ltd) solution (5 g/l), and cultures were stained for 5–10 min. The stain was then poured off, and the cultures were washed once in tap water, and then in tap water acidified to pH 2.5 with H₂SO₄, followed by another wash in tap water. The coverslip cultures were then removed from the vials, dehydrated in acetone and then cleared in xylene, and mounted on microscope slides with DPX. Examination of the cultures by bright field microscopy showed that cytoplasm was stained pale blue while nuclei stained slightly darker blue. The chlamydial inclusions stained a deep blue colour. With dark field microscopy the cytoplasm and cell nuclei appeared greenish brown while chlamydial inclusions appeared auto-fluorescing bright yellow.

Giemsa and iodine staining techniques were carried out according to Johnson.²

Results

The results with each of the three staining techniques were compared by counting the number of inclusions in 10 mm coverslip monolayer cultures by dark field microscopy.

Table 1 summarises the results of inclusion counts detected in clinical specimens by Giemsa, iodine, and toluidine blue staining techniques in McCoy cells. At least three times more chlamydial inclusions were detected with toluidine blue than with iodine staining. There was no significant difference between the numbers of inclusion counts using toluidine blue and Giemsa stains from clinical specimens ($p > 0.05$), but the inclusions were more defined with toluidine blue.

Table 2 summarises the results of inclusion counts detected in clinical specimens with Giemsa, iodine, and toluidine blue staining in HeLa-229 cells. Three to seven times more inclusions were detected with toluidine blue than with iodine staining and one and a half to three times more inclusions were detected with toluidine blue than with Giemsa staining, the difference being significant ($p < 0.01$).

Discussion

No clearly superior cytological staining method has been described for screening inoculated tissue cultures for chlamydial isolation. The options are largely limited to iodine, Giemsa, and fluorescence techniques. It appears that there may be some difference depending on cell type.¹¹

The results of this study show that toluidine blue staining was more sensitive than one of the conventionally used stains—that is, iodine—for detecting *C*

Table 2 *Chlamydia trachomatis* inclusion counts in HeLa-229 cells

Clinical specimens	*Mean inclusion count (Ic)		
	Giemsa	Iodine	Toluidine blue
Cervix	3009	1312	4952
"	16	8	29
"	121	45	314
"	8	3	17
"	1093	478	1672
"	105	39	241
"	2	0	4
Urethral	1398	557	2322
"	91	52	282
"	1102	501	1982
"	56	19	93
"	4108	1260	6500
"	1	0	3
Eye	800	265	1224
"	5	3	13

*Mean number counted on two coverslips.

Ic = Inclusion count in 10 mm coverslip cultures.

trachomatis in both McCoy and HeLa-229 cells. HeLa cells, however, do not lend themselves to routine use of the iodine staining technique because they occasionally have light iodine staining material in the cytoplasmic background;¹¹ also iodine staining is rather limited by being positive for a relatively short time within the developmental cycle of the inclusion.¹¹ Johnson *et al*⁴ found that staining with iodine resulted in appreciable underestimation of the number of inclusions present even after incuba-

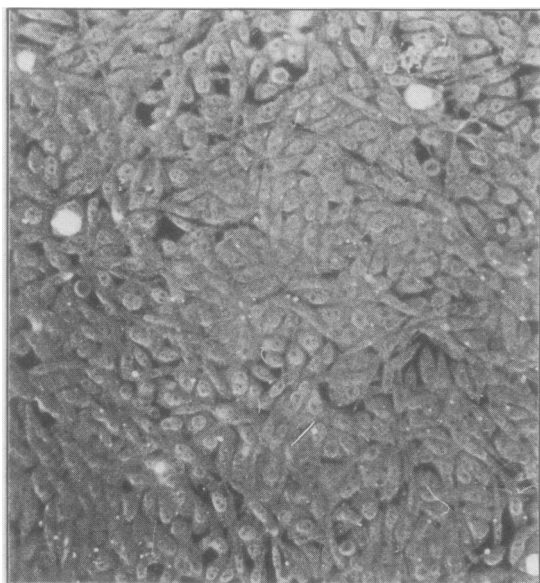
tion for 48 h. This may be because the amount of glycogen in the inclusions and therefore the effectiveness of a glycogen stain varies during the chlamydial growth cycle.^{1, 12}

Toluidine blue staining was more sensitive than Giemsa staining for detecting *C trachomatis* in HeLa-229 cells, while both stains were equally sensitive for detecting this organism in McCoy cells. Toluidine blue staining, however, has the following advantages over Giemsa staining: firstly, it is more sensitive for detecting inclusions in HeLa-229 cells; secondly, the bright yellow inclusions are more easily seen against the dull matt greenish brown background under dark field microscopy (see Figure); thirdly, toluidine blue is a stable solution which can be stored at room temperature for months, while Giemsa stain must be prepared freshly for each batch of cultures; and, finally, toluidine blue staining can be performed in 5–10 min whereas the Giemsa technique takes 30 min. These factors are clearly advantageous in routine screening of large numbers of clinical specimens in a busy laboratory.

We acknowledge the help of Seamus Dooley and Gerardine McQuoid in the preparation of this paper.

References

- Gordon FB, Quan AL. Occurrence of glycogen in inclusions of the Psittacosis-lymphogranuloma venereum agent. *J Infect Dis* 1965; **115**:186–96.
- Johnson FWA. A comparison of staining techniques for demonstrating group A chlamydia in tissue culture. *Med Lab Technol* 1975; **32**:233–8.
- Mallinson H, Sikotra S, Arga OP. Cultural method for large-scale screening for chlamydia trachomatis genital infection. *J Clin Pathol* 1981; **34**:712–8.



Chlamydia trachomatis inclusions in McCoy cells stained with toluidine blue under dark field microscopy. Original magnification $\times 200$.

- ⁴ Johnson FWA, Hobson D, Rees E, Tait IA. Quantitative aspects of the growth of *Chlamydia trachomatis* in diagnostic tissue culture procedures. In: Hobson D, Holmes KK, eds. *Non-gonococcal urethritis and related infections*. Washington DC: American Society for Microbiology, 1977:309-13.
- ⁵ Evans RT, Woodland RM. Detection of chlamydia by isolation and direct examination. *Br Med Bull* 1983;**39**:181-6.
- ⁶ Johnson FWA, Chancerelle LYJ, Hobson D. An improved method for demonstrating the growth of chlamydia in tissue culture. *Med Lab Sci* 1978;**35**:67-74.
- ⁷ Woodland RM, El-Sheikh H, Darougar S, Squires S. Sensitivity of immunoperoxidase and immunofluorescence staining for detecting chlamydia in conjunctival scrapings and in cell culture. *J Clin Pathol* 1978;**31**:1073-7.
- ⁸ Woodland RM, Malam J, Darougar S. A rapid method for staining inclusions of chlamydia psittaci and chlamydia trachomatis. *J Clin Pathol* 1982;**35**:642-4.
- ⁹ Davies JA, Rees E, Hobson D, Karayiannis P. Isolation of chlamydia trachomatis from Bartholin's ducts. *Br J Vener Dis* 1978;**54**:409-13.
- ¹⁰ Johnson FWA, Hobson D. Factors affecting the sensitivity of replicating McCoy cells in the isolation and growth of chlamydia A (TRIC agents). *J Hyg (Camb)* 1976;**76**:441-51.
- ¹¹ Schachter J, Dawson CR. Psittacosis—lymphogranuloma venereum agents/TRIC agents. In: Lennette EH, Schmidt NJ eds. *Diagnostic procedures for viral, rickettsial and chlamydial infection*. 5th ed. Washington DC: American Public Health Association, 1980:1021-59.
- ¹² Croy TR, Kuo C-C, Wang S-p. Comparative susceptibility of eleven mammalian cell lines to infection with Trachoma Organisms. *J Clin Microbiol* 1975;**1**:434-9.

Requests for reprints to: Dr NRS Mohammed, Department of Medical Microbiology, University College Dublin, Dublin 4, Ireland.