

IMAGES AND VIDEOS

A complicated trilogy: persistent left superior vena cava with hypertrophic cardiomyopathy and atrial septal defect

Umut Kocabas MD, Esra Kaya MD and Cahide Soydas Cinar MD

Department of Cardiology, Ege University School of Medicine, Izmir, Turkey

Correspondence
should be addressed
to U Kocabas

Email
umutkocabas@hotmail.com

Summary

A 28-year-old asymptomatic woman was referred to our clinic for evaluation of a heart murmur. Transthoracic echocardiography (TTE) demonstrated ventricular hypertrophy with septal thickness of 26 mm, consistent with hypertrophic cardiomyopathy (HCM) (Fig. 1A).

The diagnosis of HCM was confirmed by contrast-enhanced magnetic resonance imaging, and late gadolinium enhancement was observed in the anterior wall (Fig. 1B and C). The patient's coronary sinus (CS) was dilated and, therefore, underwent contrast echocardiography with a prediagnosis of PLSVC. (E) Saline was administered through a left brachial vein, and the CS opacified first followed by the right atrium. (F) TTE revealed a secundum ASD, and Doppler echocardiography confirmed a left-to-right shunt.

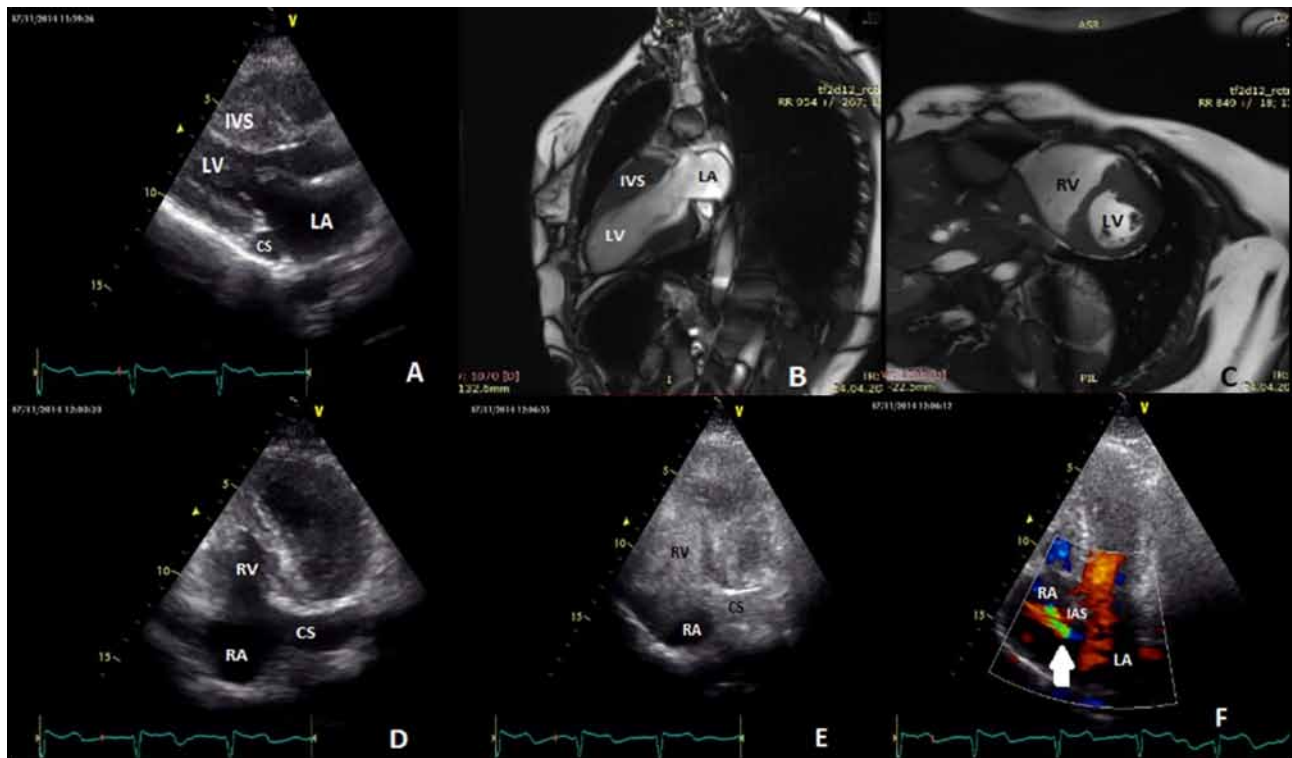


Figure 1

(A) TTE demonstrating ventricular hypertrophy with a septal thickness of 26 mm, consistent with HCM. (B and C) HCM diagnosis confirmed via contrast-enhanced MRI, and late gadolinium enhancement was observed in the anterior wall. (D) The patient's CS was dilated therefore underwent contrast echocardiography with a prediagnosis of PLSVC. (E) Saline was administered through a left brachial vein, and the CS opacified first followed by the right atrium. (F) TTE revealed a secundum ASD, and Doppler echocardiography confirmed a left-to-right shunt.

with a prediagnosis of persistent left superior vena cava (PLSVC) (Fig. 1A and D). Saline was administered through a left brachial vein, and the CS opacified first followed by the right atrium (Fig. 1E and Video 1). After saline was administered through the patient's right arm, her right atrium opacified before the CS. She was diagnosed with PLSVC. TTE revealed a secundum atrial septal defect (ASD), and Doppler echocardiography confirmed a left-to-right shunt (Fig. 1F and Video 2). Although the Qp:Qs ratio was <1.5, valvular function, right heart volume and systolic pulmonary arterial pressure were normal. She was included in a follow-up program.

PLSVC, HCM and ASD are common congenital heart diseases; however, they are rarely observed together. The risk of arrhythmia and sudden cardiac death is increased in HCM (1). An implantable cardioverter defibrillator is the only therapy in this clinical setting. PLSVC is a vascular anomaly and can be incidentally detected during right heart invasive procedures. However, PLSVC may cause technical difficulties during cardiac device implantation (2). The presence of a dilated CS should alter the medical team to the possibility of a PLSVC. We suggest that contrast echocardiography with agitated saline injected intravenously through the left arm is an important and useful technique in the diagnosis of PLSVC. To the best of our knowledge, our report is the first in the literature of a patient with PLSVC with HCM and ASD together.

Video 1

Saline contrast echocardiography through a left brachial vein showing dilated coronary sinus opacification just before the right atrium in an apical four-chamber view. View Video 1 at <http://movie-usa.glencoesoftware.com/video/10.1530/ERP-16-0017/video-1>.

Video 2

Doppler echocardiography showing a secundum atrial septal defect with left-to-right shunt in an apical four-chamber view. View Video 2 at <http://movie-usa.glencoesoftware.com/video/10.1530/ERP-16-0017/video-2>.

Declaration of interest

The authors declare that there is no conflict of interest that could be perceived as prejudicing the impartiality of this article.

Funding

This work did not receive any specific grant from any funding agency in the public, commercial, or not-for-profit sector.

Author contribution statement

Umut Kocabas, MD, performed transthoracic echocardiography and contrast echocardiography, and wrote the manuscript. Esra Kaya, MD, helped in manuscript preparation. Prof. Dr Cahide Soydas Cinar revised the paper.

References

- 1 Pantazis A, Vischer AS, Perez-Tome MC & Castelletti S 2015 Diagnosis and management of hypertrophic cardiomyopathy. *Echo Research and Practice* **1** 45–53. (doi:10.1530/erp-15-0007)
- 2 Kumar V, Yoshida N & Yamada T 2015 Successful implantable cardioverter-defibrillator implantation through a communicating branch of the persistent left superior vena cava. *Journal of Arrhythmia* **31** 331–332. (doi:10.1016/j.joa.2015.01.005)

Received in final form 25 April 2016

Accepted 17 June 2016

Accepted Preprint published online 17 June 2016