

Primary brain trauma in non-accidental injury

IAN M CALDER,* I HILL,† CL SCHOLTZ*

*From Departments of *Morbid Anatomy and †Forensic Medicine, The London Hospital, Whitechapel, London E1 1BB*

SUMMARY The brains from 12 babies up to 2½ years of age, who died after repeated non-accidental injury to the head, were subjected to detailed neuropathological examination. The nine brains from infants under 5 months showed contusional tears—slit like lesions in the white matter surrounded by astrocytes and associated with evidence of old and recent haemorrhage. The three brains from infants over 5 months showed white matter lesions similar to those seen in adults after closed head injury, including damage in the dorsolateral quadrant of the brain stem without axonal hemispheric damage, which may have been a result of whiplash injury after shaking. In addition, all the brains examined showed diffuse gliosis.

This paper draws attention to contusional tears and other white matter lesions, which the authors believe are manifestations of mechanical damage produced by trauma. The long term neurological and intellectual defects observed in patients suffering non-accidental injury early in life are increasingly being recognised, although it is difficult to identify the extent to which these are due to social or neuropathological factors. We suggest that the white matter damage we describe has an important role.

Since Caffey^{1,2} described the association of subdural haemorrhage and multiple limb fractures, the intracranial manifestations of non-accidental injury have become increasingly recognised and understood. Subdural haemorrhage and associated retinal haemorrhage, both common manifestations of head injury in childhood only,³ can be produced with minimal trauma.⁴ While subdural haematomas are associated with trauma, the aetiology of half of the subdural haematomas in childhood is not understood⁵ and may be associated with intracranial or generalised disease.

Little attention has been given to the white matter damage in abused babies under 5 months old since the contusional tears, or clefts in the white matter, were first described.⁶ These lesions are important because they represent the most important evidence of primary brain trauma in early infancy. The importance of white matter damage in adult head injury has recently been highlighted by Adams *et al.*⁷ These authors emphasised the importance of diffuse axonal injury. This was initially described by Strich⁸ in a group of patients with post-traumatic dementia, who exhibited these lesions in the corpus callosum

and the dorsolateral quadrants of the brain stem as well as more diffusely. Contusions, a common finding in adult head injury, do not occur in infants because of the smoothness of the inside of the skull.

Non-accidental injury as a form of child abuse probably contributes appreciably to mental handicap.⁹ About 3000 infants receive non-accidental injuries in the UK each year,¹⁰ and up to 5% of the survivors, or 150 a year, may become severely subnormal.¹¹ In one study of 146 children subjected to prolonged abuse,¹² impaired intellectual function was found in over a quarter of the children studied. Trauma in the under 4 year olds is particularly important because it is the period in which accelerated growth and rapid myelination occur.¹³

Skull fractures are present in many abused infants after non-accidental injury. Many, however, also receive primary brain trauma from whiplash injury^{14,15} without skull fracture. The extent of this diffuse axonal injury has been correlated directly with the severity of acceleration-deceleration injury in adult humans⁷ and other primates,¹⁶ and a similar relation may operate in infants. Such injuries may occur in small infants either as single episodes or as habitual prolonged casual whiplash shakings, described by Caffey as the "latent whiplash shaken

Details of the 12 cases studied, showing the presence of contusional tears, associated fractures, and extracranial trauma

Case	Age (days)	Sex	Contusional tears	Skull fracture	Subdural haematomas	Comment
1	12	M	+	No	Bilateral	Subretinal haemorrhage No other fractures
2	14	M	+			No detailed report available
3	17	M	+	Right parietal	Bilateral, small	Multiple fractures of long bones No detailed report available
4	28	M	+			No detailed report available
5	42	F	-	No	Bilateral, small	No trauma to the rest of the body
6	49	M	+	Right parietal	Small	Fractured ribs and right femur
7	63	M	+	Right parietal	Bilateral	Multiple fractures of long bones
8	84	M	+	Right parietal	Bilateral	Multiple bruises
9	91	M	-	No	Small, bilateral	Forehead bruises Extensive gliosis of brain Multiple rib fractures of varying ages
10	2 years	M	-	-	Large left	Extensive gliosis Brain stem lesion
11	2 years	M	-	-	-	Subarachnoid haemorrhage Multiple bruises, no fractures
12	2½ years	M	-	-	Bilateral	Extensive gliosis White matter damage Left subretinal haemorrhage Multiple bruises

+ = present; - = absent.

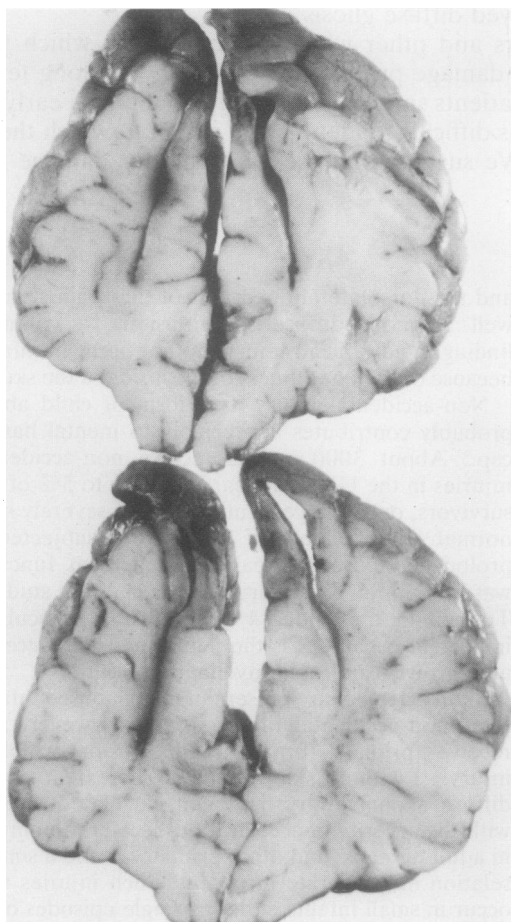


Fig. 1 Contusional tears in case 8 showing the slit like clefts in the frontal lobes.

infant syndrome".¹⁵ They may explain many minor cerebral motor, visual, and auditory defects as well as mental impairments which are not identified till school age.¹⁵

Material and methods

The brains of 12 infants received over a five year period in the Department of Forensic Medicine, The London Hospital Medical College, were studied. In all cases it was alleged that the infants had been subjected to repeated trauma and had died from trauma to the head. The brains were fixed in 10% formol-saline for a minimum of four weeks, weighed, sliced, and photographed both intact and sliced. Blocks were taken of the frontal, temporal, parietal, and occipital lobes to include the corpus callosum at two or three levels. Sections of the mid-brain and brain stem were also taken to include the rostral brain stem adjacent to the superior cerebellar peduncles as well as the cerebellum. The blocks were embedded in paraffin wax and stained by haematoxylin and eosin, Luxol fast blue with cresyl fast violet counter staining, a modified Palmgren method, Glees' and Marsland's stain, glial fibrillary acid protein, and other stains as appropriate. Brains of 10 infants of similar age were prepared identically to compare the staining of the white matter and cortex using all of the methods previously described.

Results

The main findings are summarised in the Table.

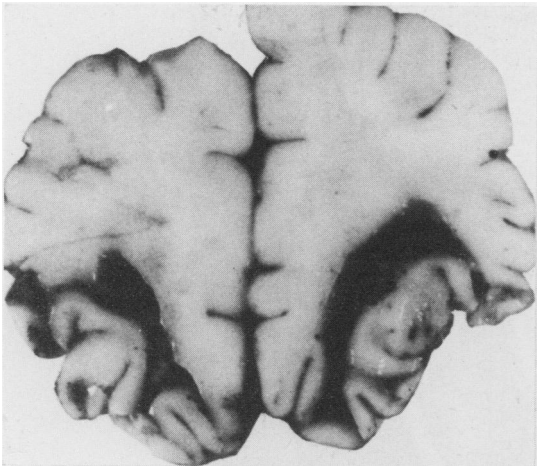


Fig. 2 Contusional tears in white matter deep to cortex in case 3.

INFANTS UNDER FIVE MONTHS OF AGE ($n = 9$; median age 42 days, range 12–91 days)

Contusions were not seen on any of these brains. Small areas of haemorrhage initially thought to be contusions were found on microscopical examination to be subarachnoid haemorrhage. Subdural haematomas of varying sizes were seen in all cases.

Contusional tears were seen in seven infants (Table). These were characterised by slit like tears in the white matter of the frontal and occipital lobes (Fig. 1). They were not cavities and did not contain blood in large quantities. They were easily identified by the presence of brown pigment in the walls, or by more recent haemorrhage. In one of the

youngest cases (case 3) there was a tear in the white matter over and parallel to the cortex (Fig. 2). Where the presence or absence of skull fractures was known, only in one case (case 1) was a contusional tear identified in the absence of a right parietal fracture (Table). Microscopical examination of the clefts showed that they contained recent haemorrhage in the younger infants (Fig. 3) and that their edges were lined by large reactive astrocytes (Fig. 4) and iron containing macrophages in the older cases. The glial fibrillary and protein method easily identified numerous large reactive astrocytes in the white matter of cases (Fig. 5a) without contusional tears. They were not seen in the control cases (Fig. 5b). Axonal injury, characterised by the presence of retraction balls using a routine neuropathological technique, was not identified in these infants.

INFANTS OVER FIVE MONTHS ($n = 3$; aged 2, 2, and 2½ years)

No contusions or contusional tears were identified in this group.

In case 12 diffuse axonal injury typical of that in adults was identified microscopically in the corpus callosum and was characterised by retraction balls (Fig. 6). In this infant there were no lesions in the dorsolateral quadrants of the brain stem. There was also a diffuse astrocytic reaction in the white matter. In case 11 a shearing lesion was identified microscopically in the dorsolateral quadrant (Fig. 7), but none was seen in the corpus callosum or hemispheric white matter. In case 10 there was diffuse gliosis in the absence of other evidence of white matter dam-

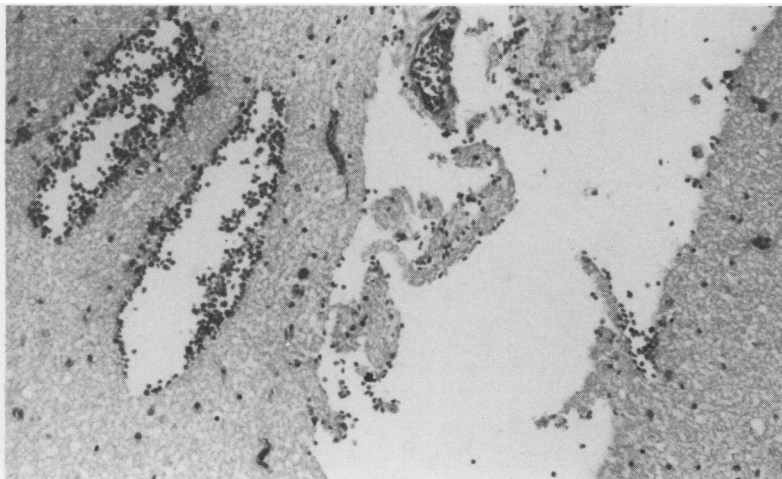


Fig. 3 Photomicrograph of clefts in case 1 showing acute haemorrhage in the wall of a cleft and in adjacent clefts, with necrotic white matter in the centre of the large cleft. Haematoxylin and eosin. Original magnification $\times 100$.

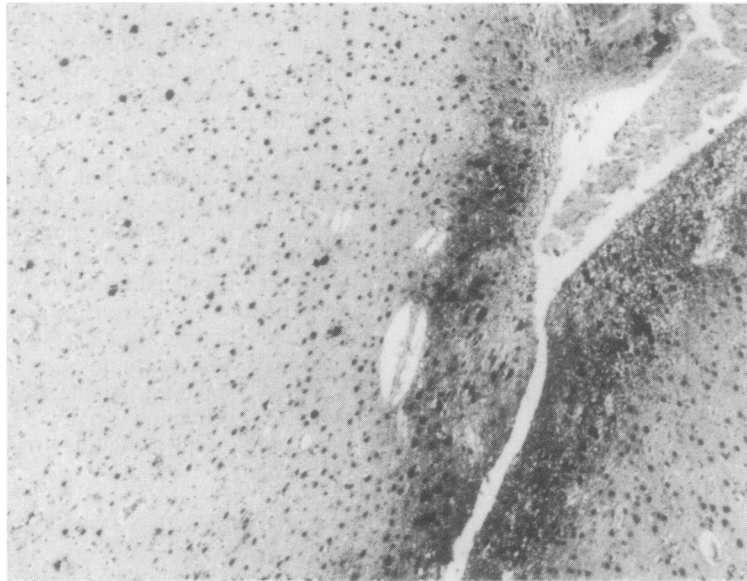


Fig. 4 *Photomicrograph of cleft in case 8 showing reactive astrocytes and gliosis of the edge of the clefts, with astrocytes in the surrounding necrotic white matter. Glial fibrillary acid protein. $\times 100$.*

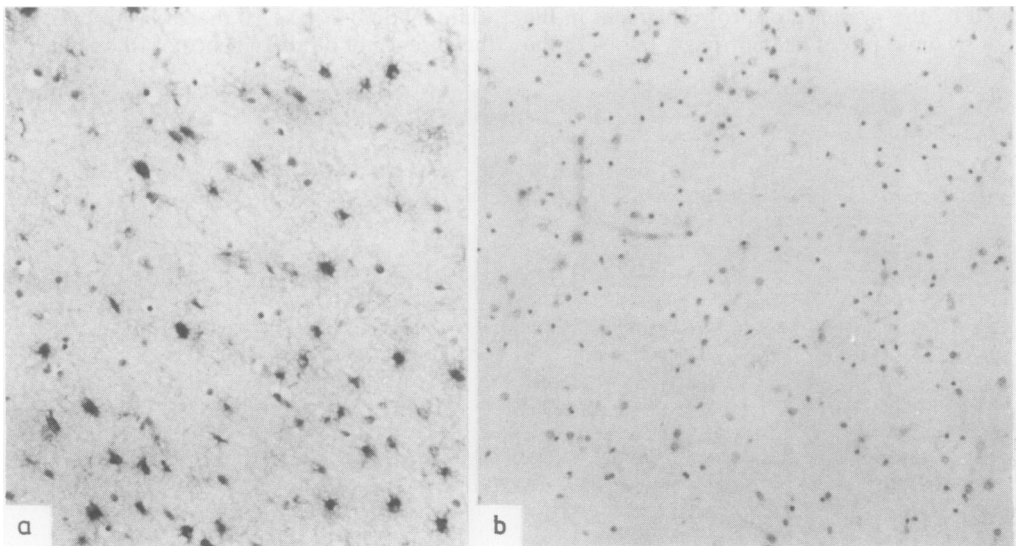


Fig. 5 *(a) Photomicrograph of the white matter from case 9, where there was no skull fracture or contusional tear, showing large numbers of reactive astrocytes. (b) Photomicrograph of white matter from control case. There are few astrocytes evident. (a) and (b) Glial fibrillary acid protein. $\times 100$.*

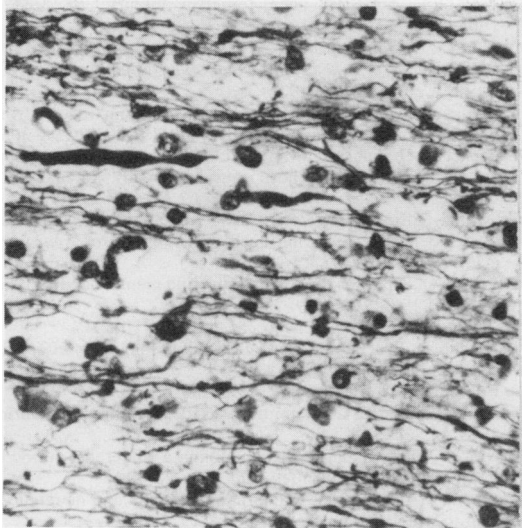


Fig. 6 High power photomicrograph of corpus callosum from case 12 showing retraction balls. Palmgren $\times 150$.

age. This infant showed severe external evidence of battering with head bruises, but there was no skull fracture.

The mean age of both groups, 13 months, is similar to that in other studies,¹⁷ but the overwhelming number of boys is different. The results of the study suggest that boys subjected to abuse are more likely to die from head injuries than girls.

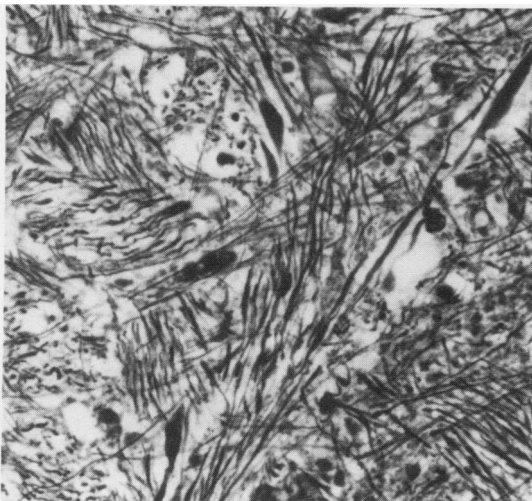


Fig. 7 Photomicrograph of dorso-lateral quadrant from case 11 showing retraction balls. Palmgren $\times 150$.

Discussion

This study has identified characteristic contusional tears, which occur in infants under 5 months old after repeated blunt trauma to the head. These lesions are usually associated with a fracture of the right parietal bone but can occur in the absence of a skull fracture. They are seen as an acute manifestation of trauma with haemorrhage, and in infants subject to chronic trauma the clefts are lined by astrocytes. White matter damage is an important aspect of head injury in adults,⁷ and this study has shown that it is equally so in infants.

The absence of contusions in young infants has been attributed to the smooth lining of the inside of the skull. This smooth lining may facilitate the transfer of shearing forces into the white matter. These forces in adults produce tears⁷ which are not as symmetrical as those seen in infancy. It is possible that the symmetrical clefts may result from the effect of shearing forces on unmyelinated axons. The absence of retraction balls, confirmed in this study, has been commented on by other authors.⁶ Gliosis was apparent in the walls of the clefts and large reactive astrocytes were also present throughout the white matter both in this study and those of other authors.⁶ These may be secondary to the trauma or oedema associated with the trauma.

In infants over 5 months old clefts were not seen. In one case the white matter damage was similar to that described in adults.⁷ Similar lesions have been described in children after accidental and non-accidental head injury and associated with mental handicap.¹⁸ In case 11 we identified shearing lesions in the brain stem but not elsewhere. This contrasts with the distribution of shearing lesions in adults, where they are seen at this site only if there are associated lesions in the hemispheres. The lesions seen may represent a specific lesion secondary to shaking where the acceleration-deceleration forces develop from movement of the body while the head is stationary. This type of lesion is not commonly a cause of head injury in adult life, but spinal injury has been described in sudden infant deaths¹⁹ and has been likened to the spinal injury seen after a difficult delivery.

The difference in the manifestation of primary brain trauma in infants and adults is probably due to a combination of several factors. Firstly, the brain of the very young infant is not completely myelinated and the thinner fibres present are more vulnerable to shearing forces. At this age the head is more mobile and represents up to 10% of the total body weight, compared with 2% in the adult. The weakness of the neck muscles and lack of mobility and control mean that the energy cannot be absorbed by

neck muscles or avoidance; the skull bones before fusion of the sutures are thin and mould with the blow. Thus the infant's brain represents a structure which is particularly vulnerable to acceleration-deceleration forces and their subsequent effects.

This study has not identified the long term pathological sequelae of repeated trauma. Clefts and glial scars have been identified in childhood after non-accidental injury¹⁸ but not in adults. The distribution of the lesions in the occipital and frontal lobes would produce symptoms which are difficult to identify clinically. It is becoming increasingly recognised that cerebral palsy can be correlated with non-accidental head injury,⁹ and its prevalence among children in long stay care exceeds that of Down's syndrome.¹⁸ Objective study of these patients will be particularly difficult because many of these cases suffer repeated trauma throughout life, both before and after the development of cerebral palsy.^{9 19-21}

We are grateful to Mr Ivor Northy of the Photographic Department of the Institute of Pathology, London Hospital Medical College, and Mrs Elsie Nehring for assistance with the manuscript.

References

- ¹ Caffey J. Multiple fractures in long bones of infants suffering from subdural haematoma. *Am J Roentgenol* 1946; **56**:163-73.
- ² Caffey J. Some traumatic lesions in growing bones other than fracture and dislocations: clinical and radiological features. *Br J Radiol* 1957; **30**:225-38.
- ³ Lewin W. Rehabilitation after head injury. *Br Med J* 1968; **i**:465-70.
- ⁴ Russell PA. Subdural haematoma in infancy. *Br Med J* 1965; **ii**:446-8.
- ⁵ Nelson JS. Acquired diseases of nervous system. In: Kissane JM, ed. *Pathology of infancy and childhood* 2nd ed. St Louis: CV Mosby Company, 1975:976.
- ⁶ Lindenberg R, Freytag E. Morphology of brain lesions from blunt trauma in early infancy. *Arch Pathol* 1969; **87**:298-305.
- ⁷ Adams HJ, Graham DI, Murray LS, Scott G. Diffuse axonal injury due to nonmissile head injury in humans. An analysis of 45 cases. *Ann Neurol* 1982; **12**:557-63.
- ⁸ Strich SJ. Diffuse degeneration of the cerebral white matter in severe dementia following head injury. *J Neurol Neurosurg Psych* 1956; **19**:163-85.
- ⁹ Afukko EO, Sylvester PE. Head injury and mental handicap. *J R Soc Med* 1983; **76**:545-9.
- ¹⁰ Anonymous. Violent parents. *Lancet* 1971; **ii**:1017.
- ¹¹ MacKeith R. Speculation of some possible long-term effects of child abuse. In: Franklin AW, ed. *Concerning child abuse*. Edinburgh: Churchill Livingstone, 1975:63-8.
- ¹² Gregg GS, Elmer E. Infant injuries: accident or abuse? *Pediatrics* 1969; **44**:434-9.
- ¹³ Davidson AN, Dobbing J. Myelination as a vulnerable period in brain development. *Br Med Bull* 1966; **22**:40-4.
- ¹⁴ Gulthkeleh AN. Infantile subdural haematoma and its relationship to whiplash injuries. *Br Med J* 1971; **ii**:420-31.
- ¹⁵ Caffey J. The whiplash syndrome. *Pediatrics* 1974; **4**:396-403.
- ¹⁶ Gennarelli TA, Thibault LE, Adams JH, Graham DI, Thomson CJ, Marcincin RP. Diffuse axonal injury and traumatic coma in the primate. *Ann Neurol* 1982; **12**:564-74.
- ¹⁷ Knight B. The battered child. In: Tedeschi CG, Eckert WG, Tedeschi LG, eds. *Forensic medicine: a study in trauma and environment hazards*. Philadelphia: WB Saunders Company, 1977:500-9.
- ¹⁸ Sylvester PE. Post-natal cerebral trauma and mental handicap. *Newsletter: The British Society for the Study of Mental Subnormality* 1978; **4**:1-7.
- ¹⁹ Towbin A. Sudden infant death (cot death) related to spinal injury. *Lancet* 1967; **ii**:940.
- ²⁰ Morse CW, Sahler OJ, Friedman SB. A three year follow up study of abused and neglected children. *Am J Dis Child* 1970; **120**:439-46.
- ²¹ Blumberg ML. Character disorders in traumatised and handicapped children. *Am J Psychother* 1979; **33**:201-3.

Requests for reprints to: CL Scholtz, Institute of Pathology, The London Hospital, Whitechapel, London E1 1BB.