

Retrospective Study

Femoro Patella Vialla patellofemoral arthroplasty: An independent assessment of outcomes at minimum 2-year follow-up

Mansur Halai, Andrew Ker, Iain Anthony, Graeme Holt, Bryn Jones, Mark Blyth

Mansur Halai, Andrew Ker, Iain Anthony, Bryn Jones, Mark Blyth, Department of Trauma and Orthopaedics, Glasgow Royal Infirmary, Glasgow G4 0SF, United Kingdom

Graeme Holt, Department of Trauma and Orthopaedics, University Hospital Crosshouse, Kilmarnock KA2 0BE, United Kingdom

Author contributions: Halai M conducted the study with the help of Ker A; Anthony I and Holt G performed the biostatistical analysis; Jones B and Blyth M conducted the study and supervised the entire project; all authors had read and approved the final version to be published.

Institutional review board statement: Not required. This study was performed as part our routine departmental audit process.

Informed consent statement: All study participants, or their legal guardian, provided informed written consent prior to study enrolment.

Conflict-of-interest statement: All the authors have no conflicts of interest to declare.

Data sharing statement: We confirm that this article is original, is not under consideration by another journal and has not been previously published. We consent to *World J Orthop* using our data for sharing. Technical appendix, statistical code, and dataset available from the corresponding author at mansurhalai@googlemail.com.

Open-Access: This article is an open-access article which was selected by an in-house editor and fully peer-reviewed by external reviewers. It is distributed in accordance with the Creative Commons Attribution Non Commercial (CC BY-NC 4.0) license, which permits others to distribute, remix, adapt, build upon this work non-commercially, and license their derivative works on different terms, provided the original work is properly cited and the use is non-commercial. See: <http://creativecommons.org/licenses/by-nc/4.0/>

Manuscript source: Invited manuscript

Correspondence to: Mansur Halai, Specialty Registrar, Department of Trauma and Orthopaedics, Glasgow Royal Infirmary, Gatehouse Building, 84 Castle Street, Glasgow G4 0SF, United Kingdom. mansurhalai@gmail.com
Telephone: +44-7790-508019

Received: February 27, 2016

Peer-review started: February 27, 2016

First decision: March 24, 2016

Revised: May 19, 2016

Accepted: June 1, 2016

Article in press: June 3, 2016

Published online: August 18, 2016

Abstract

AIM: To determine outcomes using the Femoro-Patella Vialla (FPV) arthroplasty and if there is an ideal patient for this implant.

METHODS: A total of 41 FPV patellofemoral joint replacements were performed in 31 patients (22 females, 9 males, mean age 65 years). Mean follow-up was 3.2 years (minimum 2 years). Radiographs were reviewed preoperatively and postoperatively. We assessed whether gender, age, previous surgery, patella atla or trochlear dysplasia influenced patient satisfaction or patient functional outcome.

RESULTS: The median Oxford Knee Score was 40 and the median Melbourne Patellofemoral Score was 21 postoperatively. Seventy-six percent of patients were satisfied, 10% unsure and 14% dissatisfied postoperatively. There was no radiological progression of tibiofemoral joint arthritis, using the Ahlback grading,

in any patient. One patient, who was diagnosed with rheumatoid arthritis postoperatively, underwent revision to total knee replacement. There were no intraoperative lateral releases and no implant failures. Gender, age, the presence of trochlear dysplasia, patella alta or bilateral surgery did not influence patient outcome. Previous surgery did not correlate with outcome.

CONCLUSION: In contrast to the current literature, the FPV shows promising early results. However, we cannot identify a subgroup of patients with superior outcomes.

Key words: Patellofemoral; Arthritis; Femoro-Patella Vialla; Outcomes; Arthroplasty

© **The Author(s) 2016.** Published by Baishideng Publishing Group Inc. All rights reserved.

Core tip: We demonstrate good outcomes regarding the Femoro-Patella Vialla implant which recently has had poor outcomes reported. As it is a popular implant, we think this article is important as there is a paucity of literature concerning outcomes from independent centres. In addition, we are the first group to use a patellofemoral score as one of the outcome measures. However, we cannot identify a subgroup of patients with superior outcomes.

Halai M, Ker A, Anthony I, Holt G, Jones B, Blyth M. Femoro Patella Vialla patellofemoral arthroplasty: An independent assessment of outcomes at minimum 2-year follow-up. *World J Orthop* 2016; 7(8): 487-493 Available from: URL: <http://www.wjgnet.com/2218-5836/full/v7/i8/487.htm> DOI: <http://dx.doi.org/10.5312/wjo.v7.i8.487>

INTRODUCTION

Patellofemoral arthroplasty (PFA) is a bone preserving procedure for the treatment of severe isolated patellofemoral arthritis. Its legacy dates back to Blazina's first report of PFA in 1979^[1]. Early designs, such as the Lubinus device, reported high failure rates^[2]. Since then, newer devices have been developed which more accurately mimic normal knee anatomy and patellar alignment. PFA is now a tibiofemoral joint-sparing alternative to traditional total knee arthroplasty in the treatment of patellofemoral arthritis.

The AVON (Stryker Howmedica Osteonics, Allendale, New Jersey) design was developed from the Kinemax plus (Stryker Howmedica Osteonics, New Jersey) which had a low rate of patellofemoral complications. The early results of this prosthesis from the originating centre have been promising^[3]. In another prospective review, good results were also experienced in 37 cases at 2 years^[4]. However, there have been mixed results in terms of revision rates at short term follow-up for patellofemoral arthroplasty in general, with rates of

between 3% and 15% quoted in the literature^[5].

Newer devices such as the Femoro-Patella Vialla (FPV, Wright Medical, United Kingdom) have more recently become available. Stated benefits include a broad trochlea with proximal extension, together with a sagittal curve that promotes superior patella tracking. The sulcus angle of the FPV is 140 degrees, which mimics the human trochlear anatomy more accurately, compared to the Avon which has an angle of 125 degrees^[6]. The trochlea is also designed to extend distally to the intercondylar notch, ensuring that the patella does not dislocate inferiorly in deep flexion. The patella features a faceted design with a longitudinal ridge which in theory contains the patella more readily in full extension. The footprint of the patella component is oval in shape, increasing patella contact area, in contrast to the AVON which has a medially offset dome.

There have been reports suggesting that the presence of preoperative trochlear dysplasia can be associated with superior outcomes after PFA^[7]. Another series have shown that patellofemoral arthritis associated with malalignment, such as patella alta, was the most common clinical presentation prior to PFA^[8]. Furthermore, Farr *et al*^[9] confirmed that the best outcome after PFA can be expected when the indication is trochlear dysplasia or patellar malalignment. All of these studies were not based on the FPV.

There are three independent outcome studies of the FPV in the literature, of which two of these report high rates of revision of 17%^[10,11]. We are not aware of any studies looking at the effects of pre-existing patella alta, trochlear dysplasia or bilateral disease on outcome of the FPV specifically. In addition, none of the published studies have used a validated patellofemoral score as one of their outcome measures. We report early outcomes of the FPV in 41 consecutive knees with a minimum follow up of 2 years.

MATERIALS AND METHODS

Forty-four consecutive FPV PFAs were performed at a single tertiary centre between November 2007 and November 2011. One patient died from unrelated causes and another patient, who had bilateral FPVs implanted, was lost to follow up. The patient lost to follow-up had a normal postoperative recovery and satisfactory radiographs, with no revision surgery documented in their case-notes.

This left 41 FPV procedures in 31 patients producing a 94% follow-up rate. There were 22 females and 9 males. There were 11 patients (22 FPVs) who had bilateral replacements as staged procedures. The mean age of the cohort was 65 years (range 41-81). The mean follow-up was 3.2 years with a minimum of 2-year follow-up for all patients. The causes of the patellofemoral arthritis were as follows: Osteoarthritis (39 cases, 95%) and trauma (2 cases, 5%).

Patients were considered for surgery if they had

Table 1 Previous surgery in 41 knees

Previous surgery	No. of knees (% of total)
Arthroscopy	3 (7)
Tibial tuberosity transfer	2 (5)
Medial patellofemoral ligament reconstruction	2 (5)
No intervention	34 (83)
Total	41 (100)

disabling knee pain, Outerbridge grade 4 patellofemoral arthritis and normal medial and lateral knee compartments on weight-bearing radiographs^[12]. The preoperative diagnosis was isolated severe patellofemoral arthritis in all cases. Diagnosis was based on a combination of clinical, radiological and, where available, arthroscopic findings. Previous surgery was documented and summarised in Table 1.

Each patient had a weight-bearing anteroposterior, lateral radiograph and skyline radiograph of their affected knee preoperatively (Figure 1). The presence of a dysplastic trochlea was evaluated on preoperative radiographs, including a true lateral. This was scored independently by two of the authors. Trochlear dysplasia was identified where there was a crossing sign and a sulcus angle greater than 145° as has been previously described^[13]. The presence of patella alta was also documented from the lateral preoperative radiographs using the Insall-Salvati ratio^[14]. A ratio of greater than 1.2 was taken to be indicative of patella alta.

All operations were performed by, or under direct supervision of, the two senior authors. A medial parapatellar approach was adopted in all cases under pneumatic tourniquet control. All patients had intravenous antibiotics at induction as per local microbiology policy. Palacos R and G cement was used in all cases. No lateral releases were performed. The mean tourniquet time was 49 min. No patients required a blood transfusion postoperatively. The median time for discharge for all patients was at day 3 postoperatively.

Patients were followed in our Outcomes Assessment clinic run by independent nurse practitioners. We performed a retrospective audit of case-notes and radiographs. Patient factors such as preoperative diagnosis and a history of previous surgery or trauma were noted. Functional outcome was assessed at scheduled appointments. These consisted of a preoperative visit and a 3 mo postoperative visit. Thereafter patients were reviewed on a yearly basis. The mean follow-up at the latest appointment was 3.2 years (range 24–58 mo). Patient reported outcome measures included the Oxford Knee Score (OKS) and the validated Melbourne Patellofemoral Score^[15,16]. Patient satisfaction with the outcome of the surgery was also documented using a simple 5 point question. The patient was asked in writing, at latest follow-up, to grade their satisfaction postoperatively as: Very satisfied, satisfied, unsure, dissatisfied or very dissatisfied. Radiographs were reviewed postoperatively for the development of

Table 2 Effect of different patient characteristics on outcome

Patient factor	Category	n	Median OKS (Q1, Q3)	P value	Mean Melbourne Score (SD)	P value
Sex	Male	12	42 (38, 46)	0.28	21.3 (4.7)	0.31
	Female	29	40 (37, 42)		19.1 (6.4)	
Trochlear dysplasia	Non-dysplastic	10	41 (36, 43)	0.95	20.0 (5.7)	0.67
	Dysplastic	31	41 (38, 43)		19.0 (7.1)	
Patella alta	Yes	21	41 (37, 42)	0.56	19.3 (6.4)	0.65
	No	20	40 (36, 44)		20.2 (5.6)	
Uni- or bi-lateral	Unilateral	19	41 (37, 42)	0.83	19.8 (5.6)	0.97
	Bilateral	22	41 (37, 43)		19.7 (6.4)	
Previous surgery	Yes	10	40 (37, 42)	0.70	22.0 (5.0)	0.28
	No	31	41 (37, 43)		19.0 (6.1)	

OKS: Oxford Knee Score.

tibiofemoral arthritis using the Ahlback grading^[17]. Complications were determined at postoperative clinic visits and from the case-notes. The data presented was collected retrospectively and analysed as part of a routine audit of our clinical practice.

Statistical analysis

All data was analysed using SigmaPlot vs11.0 (Systat Software Inc). Parametric data (Melbourne Score) was analysed using *t* test and non-parametric data (OKS) was analysed using Mann-Whitney test. Pearson's correlation was used to determine linear correlation between variables. *P* value less than 0.05 was considered significant for all tests. The statistical methods of this study were conducted by the biostatistician Iain Anthony of the Glasgow Royal Infirmary.

RESULTS

The median postoperative OKS and Melbourne scores were 40 and 21 respectively at latest follow-up. Thirty-eight percent of patients were very satisfied, 38% satisfied, 10% unsure and 14% dissatisfied with their final result. There were no patients who were "very dissatisfied". The results are summarised with respect to different patient characteristics in Table 2. Patient factors (gender, the presence of trochlear dysplasia or patella alta, or if bilateral surgery was performed) did not impact on clinical outcome scores. Previous surgery had no significant effect on clinical outcome. No significant correlation was found between age and OKS or Melbourne score ($P = 0.162$, $r = 0.273$ and $P = 0.278$, $r = -0.173$ respectively).

Two patients had superficial wound infections that were diagnosed and treated with a course of oral antibiotics in the community within 2 wk of discharge. Both patients went on to have favourable outcomes and were satisfied. There were no deep infections to date and there have been no infections that have required operative attention. We report no mechanical failures of the FPV prosthesis and there have been no

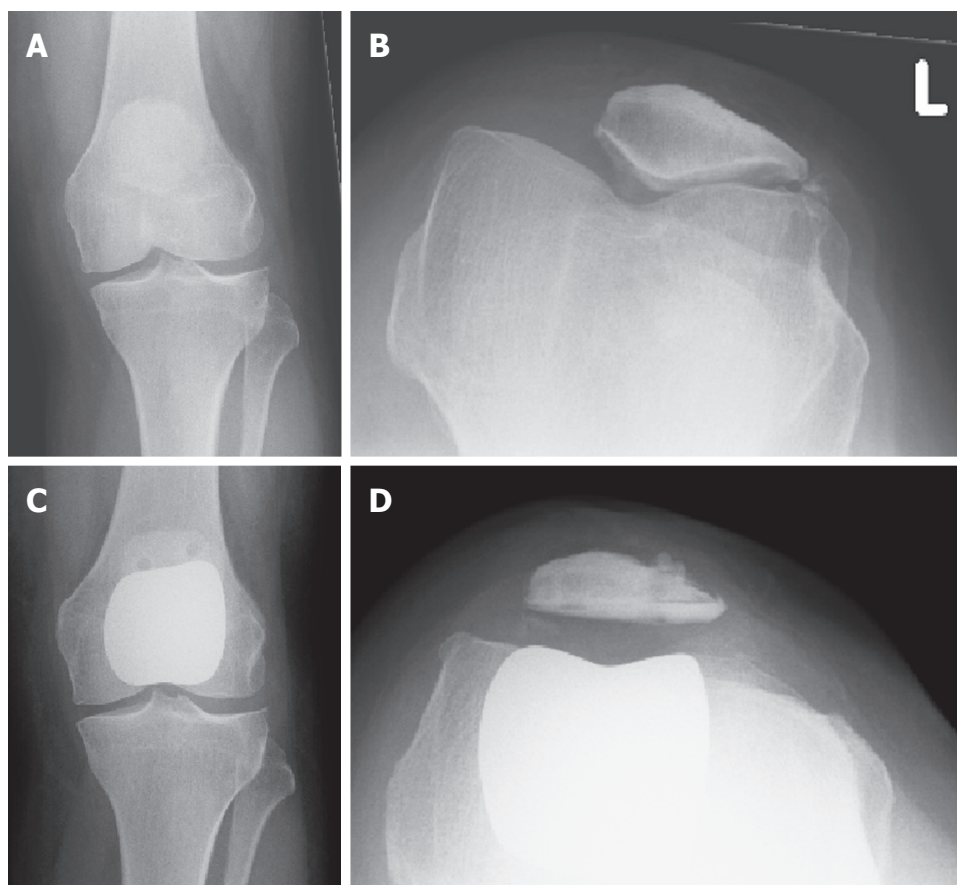


Figure 1 Preoperative and postoperative radiographs using the Femoro-Patella Vialla implant. Preoperative (A) weight-bearing anteroposterior, (B) skyline radiographs in a 60-year-old woman with severe patellofemoral degeneration and subluxation. Postoperative weight-bearing radiographs show satisfactory placement of the prosthesis on the (C) anteroposterior, and (D) skyline views of the same patient at 2 years.

periprosthetic fractures. The complications are included in Table 3.

One patient was diagnosed with seronegative rheumatoid arthritis subsequent to her FPV replacement and was revised to a total knee replacement (TKR) at 6 mo following her index procedure. This represents a 97.6% survival at minimum 2 years of follow-up.

At latest follow-up, there was no progression of arthritis of the tibiofemoral joint using the Ahlback grading in any case. In addition there was no medial or lateral tilt of the patella postoperatively and no lateral releases have been performed postoperatively.

DISCUSSION

Our study shows that good results can be achieved in the short term with the FPV patellofemoral joint replacement. The high Oxford and Melbourne scores observed are reflected in a 78% patient satisfaction rate (satisfied or very satisfied). The procedure compares favourably to TKR with a mean tourniquet time of 49 min, no blood transfusions, a mean length of stay of 3 d and an OKS of 40, at a minimum of 2 years follow-up.

The philosophy behind PFR is theoretically appealing for selected patients with isolated patellofemoral arthritis

whom have failed with non-operative therapies. The PFR spares the tibiofemoral joint, with both anterior and posterior cruciate ligaments and menisci, and therefore allows for more natural kinematics, leaving more bone stock for revision surgery^[18].

Anatomical patellofemoral abnormalities such as trochlear dysplasia and patella alta are increasingly recognised as the underlying cause of the later development of patellofemoral osteoarthritis. Farr *et al*^[9] concluded in their study that better outcomes after PFR were seen in patients with trochlear dysplasia. Williams *et al*^[10] has recently explored the relationship between trochlear dysplasia and FPV outcomes. They reported 7 revisions in their cohort of 48 knees at 2 years follow-up. Trochlear dysplasia was associated with a significantly lower rate of revision and a lower incidence of persistent pain in their cohort. In our study, it was interesting that over 80% of patients had a dysplastic trochlea according to Dejour's classification, with over half displaying patella alta. Patellofemoral abnormalities were therefore present in the majority of the patients undergoing surgery in our series, although their presence had neither a positive or negative effect on clinical outcome.

Interestingly, despite the relative paucity of published

Table 3 A comparison of our results with those previously published for patellofemoral arthroplasty and total knee replacement for isolated patellofemoral arthritis

Ref.	Implant	Number knees/patients	Mean age (yr)	Mean follow-up (yr)	OKS	Melbourne Score	Patient satisfaction	Trochlear dysplasia	Complications	Further operations
Dalury ^[23]	TKR	33/25	70	5.2	NR	NR	100%	NR	NR	0
Ackroyd <i>et al</i> ^[3]	AVON	109/85	68	5.0	39	25	80%	NR	4 superficial infections 2 stiffness	4 (4.2%) conversions to TKR
Starks <i>et al</i> ^[4]	AVON	37/29	66	2.0	39	28	86%	NR	1 patella fracture 1 patella resurfacing	1 (2.7%) patella resurfacing
Al-Hadithy <i>et al</i> ^[22]	FPV	49/41	62	3.0	38	NR	NR	NR	1 scar pain	3 (6%); 2 (4%) to TKR
Williams <i>et al</i> ^[10]	FPV	48/48	63	2.1	NR	NR	NR	Trochlear dysplasia associated with less revision	10 persistent pain 1 infection, 1 fracture, 1 hypertrophic scar	7 (15%); 5 to TKR
The present report	FPV	41/31	65	3.2	40	21	78%	84% of cases had trochlear dysplasia preoperatively No difference in outcomes	2 superficial infections: Treated with oral antibiotics	1 (2%) conversion to TKR. No lateral releases

NR: Not recorded; OKS: Oxford Knee Score; FPV: Femoro-Patella Violla; TKR: Total knee replacement.

results, the FPV is the second most used prosthesis for PFR in England and Wales, with the 10th annual National Joint Registry report stating that the FPV was used in approximately 20% of all PFRs performed in 2012 (National Joint Registry for England and Wales^[19]). Revision rates for PFR are reported in the National Joint Registry to be 6 times higher than that of primary cemented TKR. Persistent pain is the main cause of revision according to the recent registry data. If all FPVs are considered, the registry calculates a 6.4% (range 4.9%-8.2%) Kaplan-Meier estimate of the cumulative percentage probability of first revision (95%CI) at 3 years. Our 3-year data shows a FPV revision rate of 2%.

Baker *et al*^[20] examined the National Joint Registry and concluded that persistent unexplained pain was the principal reason for early revision following PFR, and that revisions usually occurred within the first 2 years. They suggested that patient selection was extremely important, and that PFR surgery should be concentrated in specialist centres. Therefore, we are encouraged by our 2% rate of revision at 3 years.

As with all partial knee replacements, ease of revision undoubtedly affects the rate of early failure. Faced with the unhappy patient, surgeons are potentially more likely to offer conversion to a TKR, as this can usually be achieved with straightforward surgery using primary TKR implants. However there is evidence that revision of partial joint replacements for unexplained pain does not give the pain relief experienced by those who are revised when a cause for failure has been identified^[21]. Our low early revision rate might be explained by our reluctance to offer revision surgery to

patients dissatisfied with the results of their procedure unless an identified cause for the dissatisfaction could be found.

A further apprehension about PFR is the advancement of osteoarthritis in the tibiofemoral articulation. In our series, there was no progression of tibiofemoral osteoarthritis at latest follow-up. Patient selection is critical and our success may be explained by our selection of patients with underlying trochlear dysplasia as a cause of their patellofemoral arthritis in the vast majority of cases. These patients are perhaps less likely to develop failure of the remainder of the knee over time, than patients whose patellofemoral arthritis develops as part of a more generalised degenerative process. Tibiofemoral osteoarthritis is not always easily identified either preoperatively. Magnetic resonance imaging (MRI) has been used to identify occult degenerative changes in the tibiofemoral articulation by the presence of subchondral cysts^[7]. We did not routinely use MRI to screen for occult tibiofemoral arthritis in our patients and our good early results question the requirement for this expensive screening investigation.

The main weakness of our study is a lack of pre-operative scores. In addition, this is a retrospective series with relatively small numbers and we do not have long-term follow-up yet. Nevertheless, our mean follow-up of 3.2 years is the longest for this implant in the literature. We specifically did not use a validated satisfaction score, such as the Western Ontario and McMaster Universities Osteoarthritis Index or SF12, for simplicity as we decided that the outcome measure process had to be streamlined. The satisfaction grading

that was used in this study is used for all research projects from our institution.

Table 3 shows that our postoperative results are comparable to those previously published for patellofemoral arthroplasty and for TKR for isolated patellofemoral arthritis. There is one published report by Al-Hadithy *et al*^[22], and they report similar satisfactory FPV outcomes with OKSs of 38 at 3 years. They reported 2 revisions, which were attributed to poor patient selection. Indeed, the one conversion to TKR in our series was due to a subsequent diagnosis of rheumatoid arthritis and this could also be retrospectively attributed to poor patient selection.

In conclusion, our early results suggest that the FPV patellofemoral joint replacement is a good alternative to TKR in the surgical management of advanced isolated patellofemoral osteoarthritis. However, we are unable to identify a subgroup of patients with superior outcomes, however do not recommend this procedure in patients suffering from rheumatoid arthritis. Further research is required to see if these initial promising results are maintained at longer term follow-up.

COMMENTS

Background

The knee joint has three compartments: Medial, lateral and patellofemoral. Some patients have isolated patellofemoral arthritis and therefore a novel "patellofemoral arthroplasty" is a treatment option to replace this compartment only, sparing the rest of the native knee joint.

Research frontiers

These patellofemoral replacements are new and there is limited outcome evidence on this particular implant: The Femoro Patella Vialla (FPV) arthroplasty.

Innovations and breakthroughs

In contrast to the current literature, the FPV shows promising early results at 2 years in this study. However, the authors cannot identify a subgroup of patients with superior outcomes. The authors do not recommend performing this procedure on patients with a history of inflammatory arthritis.

Applications

These encouraging outcomes are some of the first published outside the designing centre. The authors await longer outcome studies.

Terminology

"Patellofemoral" means the joint of the femur and patella (kneecap).

Peer-review

The authors have submitted a clinical analysis of the efficacy of using FPV patellofemoral joint replacement as a good alternative to total knee replacement in the surgical management of advanced isolated patellofemoral osteoarthritis. The authors have a relatively good selection of patients in the clinical trial (41 replacements in 31 patients) with radiographic observations and lysholm scoring techniques. The paper is well written and will be of interest to readers.

REFERENCES

- 1 **Blazina ME**, Fox JM, Del Pizzo W, Broukhim B, Ivey FM. Patellofemoral replacement. 1979. *Clin Orthop Relat Res* 2005; **(436)**: 3-6 [PMID: 15995413 DOI: 10.1097/00003086-197910000-00017]
- 2 **Tauro B**, Ackroyd CE, Newman JH, Shah NA. The Lubinus patellofemoral arthroplasty. A five- to ten-year prospective study. *J Bone Joint Surg Br* 2001; **83**: 696-701 [PMID: 11476308]
- 3 **Ackroyd CE**, Newman JH, Evans R, Eldridge JD, Joslin CC. The Avon patellofemoral arthroplasty: five-year survivorship and functional results. *J Bone Joint Surg Br* 2007; **89**: 310-315 [PMID: 17356140 DOI: 10.1302/0301-620X.89B3.18062]
- 4 **Starks I**, Roberts S, White SH. The Avon patellofemoral joint replacement: independent assessment of early functional outcomes. *J Bone Joint Surg Br* 2009; **91**: 1579-1582 [PMID: 19949120 DOI: 10.1302/0301-620X.91B12.23018]
- 5 **Sarda PK**, Shetty A, Maheswaran SS. Medium term results of Avon patellofemoral joint replacement. *Indian J Orthop* 2011; **45**: 439-444 [PMID: 21886926 DOI: 10.4103/0019-5413.83761]
- 6 **Davies AP**, Costa ML, Shepstone L, Glasgow MM, Donell S. The sulcus angle and malalignment of the extensor mechanism of the knee. *J Bone Joint Surg Br* 2000; **82**: 1162-1166 [PMID: 11132279 DOI: 10.1302/0301-620X.82B8.10833]
- 7 **Nicol SG**, Loveridge JM, Weale AE, Ackroyd CE, Newman JH. Arthritis progression after patellofemoral joint replacement. *Knee* 2006; **13**: 290-295 [PMID: 16769215 DOI: 10.1016/j.knee.2006.04.005]
- 8 **Cartier P**, Sanouiller JL, Grelsamer R. Patellofemoral arthroplasty. 2-12-year follow-up study. *J Arthroplasty* 1990; **5**: 49-55 [PMID: 2319248 DOI: 10.1016/S0883-5403(06)80009-4]
- 9 **Farr J**, Barrett D. Optimizing patellofemoral arthroplasty. *Knee* 2008; **15**: 339-347 [PMID: 18722775 DOI: 10.1016/j.knee.2008.05.008]
- 10 **Williams DP**, Pandit HG, Athanasou NA, Murray DW, Gibbons CL. Early revisions of the Femoro-Patella Vialla joint replacement. *Bone Joint J* 2013; **95-B**: 793-797 [PMID: 23723274 DOI: 10.1302/0301-620X.95B6.31355]
- 11 **Davies AP**. High early revision rate with the FPV patello-femoral unicompartmental arthroplasty. *Knee* 2013; **20**: 482-484 [PMID: 23953660 DOI: 10.1016/j.knee.2013.07.005]
- 12 **Outerbridge RE**. The etiology of chondromalacia patellae. 1961. *Clin Orthop Relat Res* 2001; **(389)**: 5-8 [PMID: 11501822]
- 13 **Dejour H**, Walch G, Nove-Josserand L, Guier C. Factors of patellar instability: an anatomic radiographic study. *Knee Surg Sports Traumatol Arthrosc* 1994; **2**: 19-26 [PMID: 7584171 DOI: 10.1007/BF01552649]
- 14 **Berg EE**, Mason SL, Lucas MJ. Patellar height ratios. A comparison of four measurement methods. *Am J Sports Med* 1996; **24**: 218-221 [PMID: 8775124 DOI: 10.1177/036354659602400218]
- 15 **Dawson J**, Fitzpatrick R, Murray D, Carr A. Questionnaire on the perceptions of patients about total knee replacement. *J Bone Joint Surg Br* 1998; **80**: 63-69 [PMID: 9460955 DOI: 10.1302/0301-620X.80B1.7859]
- 16 **Feller JA**, Bartlett RJ, Lang DM. Patellar resurfacing versus retention in total knee arthroplasty. *J Bone Joint Surg Br* 1996; **78**: 226-228 [PMID: 8666630]
- 17 **Ahlbäck S**. Osteoarthritis of the knee. A radiographic investigation. *Acta Radiol Diagn (Stockh)* 1968; **Suppl 277**: 7-27772 [PMID: 5706059]
- 18 **Hollingshurst D**, Stoney J, Ward T, Pandit H, Beard D, Murray DW. In vivo sagittal plane kinematics of the Avon patellofemoral arthroplasty. *J Arthroplasty* 2007; **22**: 117-123 [PMID: 17197318 DOI: 10.1016/j.arth.2006.02.160]
- 19 National Joint Registry for England and Wales 10th Report 2013. Available from: URL: <http://www.njrcentre.org.uk>
- 20 **Baker PN**, Refaie R, Gregg P, Deehan D. Revision following patellofemoral arthroplasty. *Knee Surg Sports Traumatol Arthrosc* 2012; **20**: 2047-2053 [PMID: 22228375 DOI: 10.1007/s00167-011-1842-0]
- 21 **Kerens B**, Boonen B, Schotanus MG, Lacroix H, Emans PJ, Kort NP. Revision from unicompartmental to total knee replacement: the clinical outcome depends on reason for revision. *Bone Joint J* 2013; **95-B**: 1204-1208 [PMID: 23997133 DOI: 10.1302/0301-620X.95B.9.31085]
- 22 **Al-Hadithy N**, Patel R, Navadgi B, Deo S, Hollingshurst D, Satish V. Mid-term results of the FPV patellofemoral joint replacement.

Knee 2014; **21**: 138-141 [PMID: 24579096 DOI: 10.1016/j.knee.2013.08.010]

23 **Dalury DF**. Total knee replacement for patellofemoral disease. *J Knee Surg* 2005; **18**: 274-277 [PMID: 16262008]

P- Reviewer: Cartmell S, Malik H **S- Editor:** Ji FF **L- Editor:** A
E- Editor: Wu HL





Published by **Baishideng Publishing Group Inc**

8226 Regency Drive, Pleasanton, CA 94588, USA

Telephone: +1-925-223-8242

Fax: +1-925-223-8243

E-mail: bpgoffice@wjgnet.com

Help Desk: <http://www.wjgnet.com/esps/helpdesk.aspx>

<http://www.wjgnet.com>

