

Bronchopulmonary disease in coeliac patients

C EDWARDS,* A WILLIAMS,† P ASQUITH‡

*From the Departments of *Histopathology, †Chest Medicine, and ‡Gastroenterology, East Birmingham Hospital, Bordesley Green East, Birmingham*

SUMMARY This paper describes the necropsy changes in a patient with coeliac disease and respiratory disease and the pulmonary biopsies from 13 other coeliac patients with physiological evidence of a parenchymal lung disorder. Postmortem examination showed partial fibrous obliteration of small airways and dilatation of larger airways, and the biopsies suggested similar changes in the other patients. We were unable to find any evidence of granulomatous or primary interstitial lung disease.

During the past 15 years there have been reports of several pulmonary disorders coexisting with coeliac disease.¹⁻⁹ In most cases cryptogenic fibrosing alveolitis or bird fancier's lung have been diagnosed,¹⁻⁶ but idiopathic pulmonary haem siderosis,⁷ sarcoidosis,⁸ and farmer's lung⁹ have also been implicated. These diagnoses have generally been made on clinical and radiological grounds alone; few patients have been biopsied.

Recently, we have found that some patients with gluten sensitive enteropathy have physiological evidence of a gas transfer defect,¹⁰ and our investigations suggest that the pulmonary lesion in such cases is a chronic inflammatory and fibrotic process affecting bronchioles and distal bronchi, with minimal involvement of the parenchyma. The first part of this paper reports the necropsy findings in a patient with coeliac disease and lung disease. The second part deals with the appearances in transbronchial biopsies from 13 coeliac patients with abnormal gas transfer.

Case reports

CASE 1

Clinical summary

A 48 year old woman presented in December 1965 with a one month history of dyspnoea and a dry cough. She had kept a budgerigar for four years. There were inspiratory crackles throughout both lung fields, most pronounced at the bases, but no other abnormal physical signs were detected. A chest radiograph showed bilateral lower and left mid-zone shadowing, and spirometry revealed a

pure restrictive defect. Precipitins were shown to budgerigar serum and droppings and to hen's egg yolk. A diagnosis of interstitial lung disease due to avian exposure was made. The patient disposed of her budgerigar, and was treated with a daily dose of 10 mg of prednisolone. Three months later her symptoms had improved, but further shadowing was seen in the right mid-zone. With continued prednisolone treatment there was some resolution at the bases but the mid-zone shadowing persisted.

By February 1967 her condition had deteriorated. She had become more breathless, and radiologically the basal shadowing had increased. Her daily dose of prednisolone was increased to 30 mg, and although there was no bacteriological evidence of tuberculosis, she was given a course of streptomycin, *p*-aminosalicylic acid, and isoniazid. Four months later her clinical and radiological condition had improved; her prednisolone was reduced to 15 mg per day, and the *p*-aminosalicylic acid and streptomycin were withdrawn. She continued with isoniazid for two years, and remained on 10 to 15 mg of prednisolone daily for nine years. During this period the lung shadowing persisted but did not progress, and there was no symptomatic deterioration.

In 1976 she was admitted to hospital again, this time with a three month history of diarrhoea and abdominal pain. She had lost 9 kg in weight during this period. On direct questioning she admitted to a similar episode as a child, which had cleared spontaneously. Results of investigations showed low serum iron and folate concentrations and a haemoglobin concentration of 12.3 g/dl. A jejunal biopsy showed sub-total villous atrophy. No avian precipitins were found in the serum on this or subsequent

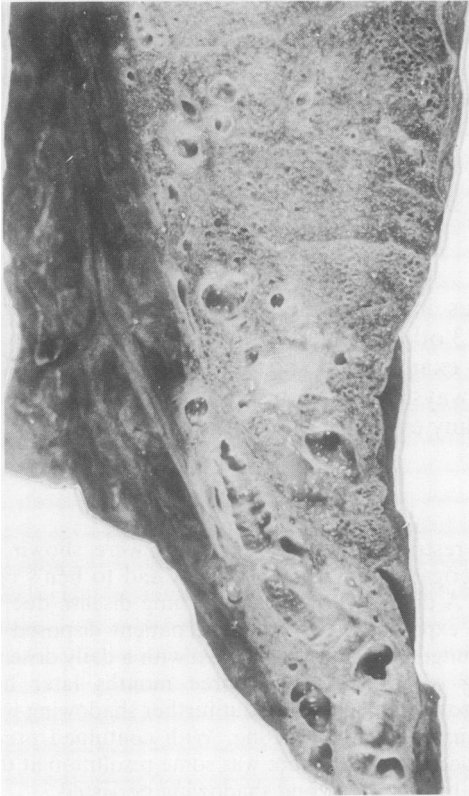

Fig. 1 Case 1. The lingula, showing fibrosis and dilatation of airways.

occasions. A diagnosis of adult coeliac disease was made, and she was started on a gluten free diet. She regained her normal weight over the ensuing eight months, although a further jejunal biopsy at the end of this period still showed sub-total villous atrophy.

The next year her diarrhoea returned, she lost 10 kg in weight, and a third jejunal biopsy again showed sub-total villous atrophy. She had adhered strictly to her diet, and it was apparent that she had unresponsive coeliac disease. Her daily dose of prednisolone was therefore increased to 20 mg, and on this regimen her bowel symptoms subsided and she gradually regained weight. A jejunal biopsy taken a few months later showed only minor villous abnormalities.

She remained well until August 1982, when she became lethargic, her dyspnoea increased, and she again lost weight. She also complained of paraesthesiae in the left hand and arm. Her bowels were regular, and her stools were normally formed. On examination there were coarse inspiratory crackles throughout both lung fields. She was slightly con-

fused and there was complete palsy of the left facial nerve. Her left arm was weak, and there was wasting of the intrinsic muscles of the left hand. Reflexes were abnormally brisk in all four limbs, and the left plantar response was extensor. Proprioception was impaired, she had a positive Romberg's sign, and vibration sense over the left ankle was reduced.

Over the next two months she slowly deteriorated, became more confused, and she died in October 1982.

Necropsy findings

The lungs were examined after fixation with formol-saline through the trachea. The main bronchi contained muco-pus. There was fibrosis of the lingula, which was reduced to a tag $3 \times 2 \times 1.5$ cm containing dilated airways. Contiguous with this there was a shrunken fibrotic area 4 cm long and up to 0.7 cm wide running along the anterior border of the upper lobe (Fig. 1). In the basal segments of the left lower lobe peripheral airways were dilated and surrounded by grey-white fibrotic areas up to 0.3 cm in diameter (Fig. 2). Similar changes were present in the basal segments of the right lower lobe. On the surface of the lower lateral part of the right upper lobe there was a depressed area 4 cm across, and beneath this a wedge of fibrosis containing dilated airways extended into the lung parenchyma for about 5 cm.

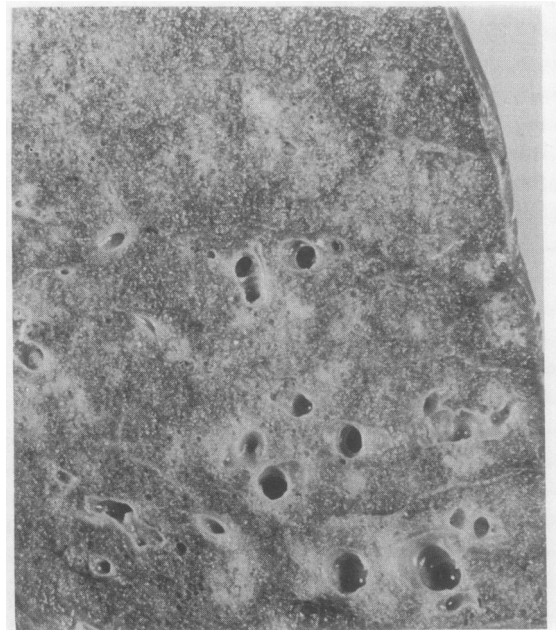


Fig. 2 Case 1. The base of the lower lobe. Small airways are dilated and are surrounded by firm white foci of fibrosis.

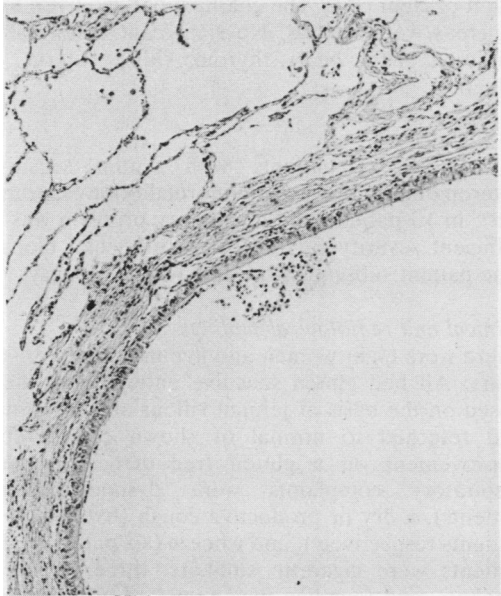


Fig. 3 Case 1. A dilated airway with a fibrotic wall containing neither glands nor cartilage. Haematoxylin and eosin. $\times 43$.

Histologically, the walls of the dilated airways consisted of cellular fibrous tissue and lacked mucous glands and cartilage (Fig. 3). In longitudinal sections these airways terminated abruptly in the fibrotic foci seen on naked eye examination (Fig. 4) and which consisted of cellular fibrous tissue extending

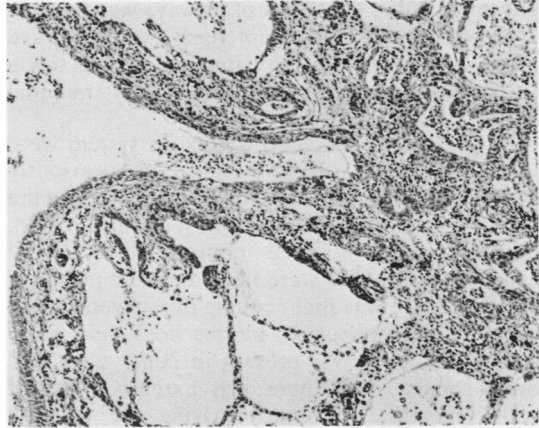


Fig. 4 Case 1. A dilated airway terminating abruptly in a focus of interstitial fibrosis. There is a moderate bronchopneumonia. Haematoxylin and eosin. Original magnification $\times 43$.

into the adjacent lung parenchyma in a stellate fashion (Fig. 5). The fibrous tissue contained spaces lined by cuboidal non-ciliated epithelium, which appeared to have budded off the parent airway (Fig. 5). In some areas there was proliferation of granular pneumocytes, and distal air spaces often contained foamy macrophages. Similar changes were seen in the upper lobes, but the lower lobes, and particularly the basal segments, were more severely affected. Basal bronchopneumonia was also present.

In the lingula and the lower lateral part of the

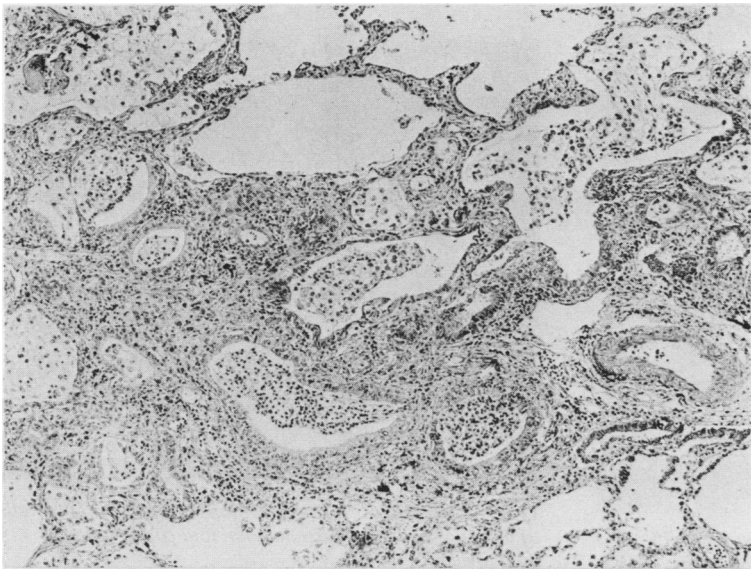


Fig. 5 Case 1. A fibrotic focus containing spaces lined by cuboidal, non-ciliated epithelium. The fibrosis extends for a short distance into the adjacent interstitium. Haematoxylin and eosin. Original magnification $\times 43$.

right upper lobe, dilatation of airways was particularly pronounced, and again there was extensive fibrosis of their walls. Intervening pulmonary tissue was compressed, but there was only minimal fibrosis.

The changes in the central nervous system were similar to those which have been previously described in association with coeliac disease.¹¹ In the spinal cord, and in particular in the lumbar region, there was loss of large motor neurones and degenerative changes were present in the posterior columns. There was slight cuffing of pial vessels. An infiltrate of lymphocytes, plasma cells, and occasional neutrophils was present in nerve roots and dorsal ganglia, and there was extensive loss of myelin sheaths. The pia overlying the cerebral hemispheres, midbrain, and cerebellum showed a subacute meningitis. There was perivascular lymphocytic cuffing in the cerebral cortex and white matter, together with astrocytic proliferation and marginal gliosis. Perivascular cuffing, astrocytic proliferation, and neuronal loss were seen in the hippocampus, basal ganglia, paraventricular nuclei, hypothalamus, and olivary nuclei. There was slight pial infiltration over the cerebellum, the folia of which were normal; there was no loss of Purkinje or granular cells but the dentate nucleus showed neuronal degeneration and astrocytic proliferation.

There was no villous abnormality in the small bowel, multiple blocks from which were examined. Sections of the cardia and body of the stomach showed dilatation of occasional glands and degranu-

lation of chief cells. The colon, appendix, liver, and pancreas were normal. No significant abnormality was seen in the heart, thyroid, kidney, uterus, or spleen.

CASES 2 TO 14

In 18 of 73 patients with gluten sensitive enteropathy there was an abnormality of gas transfer¹⁰; in 13 patients the respiratory problem was of sufficient severity to justify transbronchial biopsy. One patient subsequently came to open biopsy.

Clinical and radiological findings

There were eight women and five men, aged 30–69 years. All had gluten sensitive enteropathy, diagnosed on the basis of jejunal villous atrophy which had returned to normal or shown considerable improvement on a gluten free diet. The main respiratory complaints were dyspnoea (nine patients), a dry or productive cough (five and four patients respectively), and wheeze (six patients). Six patients were cigarette smokers, three were ex-smokers, and four had never smoked. One patient had been treated many years previously for tuberculosis, but there was nothing of relevance in the medical histories of the other patients. No abnormality was found on clinical examination, with the exception of one patient, who had finger clubbing and bilateral basal crackles. There was focal calcification in the apices of both upper lobes in the patient who had had tuberculosis; the chest radiographs of the other members of the group were normal.

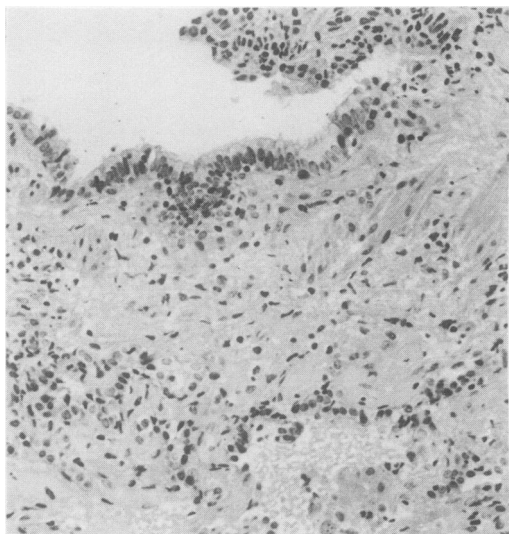


Fig. 6 Case 5. Transbronchial biopsy. Non-specific peribronchiolar fibrosis. Haematoxylin and eosin. $\times 107$.

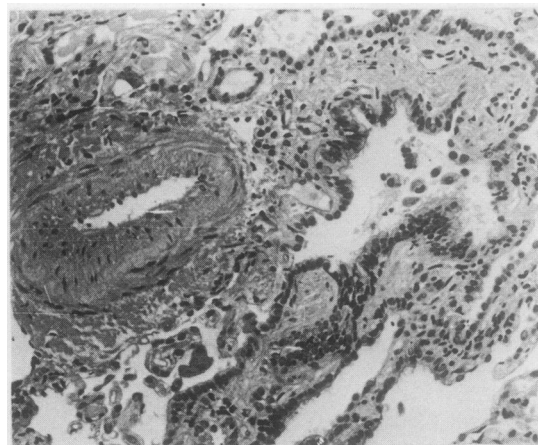


Fig. 7 Case 9. Transbronchial biopsy. Fibrosis of the walls of terminal airways. Haematoxylin and eosin. Original magnification $\times 107$.

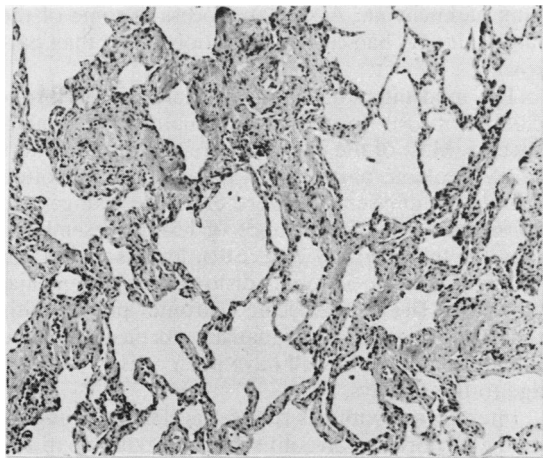


Fig. 8 Case 6. Transbronchial biopsy. Fibrotic thickening of alveolar septa. Haematoxylin and eosin. Original magnification $\times 43$.

Respiratory physiology

All patients had a reduced single breath transfer factor for carbon monoxide, corrected for lung volume and anaemia. The four non-smokers had normal static and dynamic lung volumes, but one had a slightly reduced arterial carbon dioxide tension ($p\text{CO}_2$ 4.6

kPa). The three ex-smokers had reduced forced expiratory volume in one second (FEV_1) to forced vital capacity (FVC) ratios at 67, 61, and 53% of the predicted values, indicative of mild airflow obstruction; in one of these patients the total lung capacity (TLC) was double the predicted value.

Among the six smokers, four had evidence of airflow obstruction. The FEV_1 :FVC ratio was reduced to 58 and 64% of predicted value in two, and in three the TLC was increased to 135, 120, and 125%. Three of the smokers were hypoxic, with arterial oxygen tensions of 8.7, 8.9, and 9.5 kPa.

Serology

There was no consistent abnormality of the serum immunoglobulins, and the prevalence of autoantibodies and immune complexes did not differ significantly from that found in the 54 patients with normal gas transfer.¹⁰ Four patients had precipitins to hen's egg yolk. Precipitins to other avian antigens were negative.

Transbronchial biopsy

Biopsy material was fixed in formol-saline for 24 h and embedded in hydroxyethyl methacrylate; sections were cut at $2\mu\text{m}$ and stained with haematoxylin and eosin, periodic acid-silver, and Perls' stain.¹²

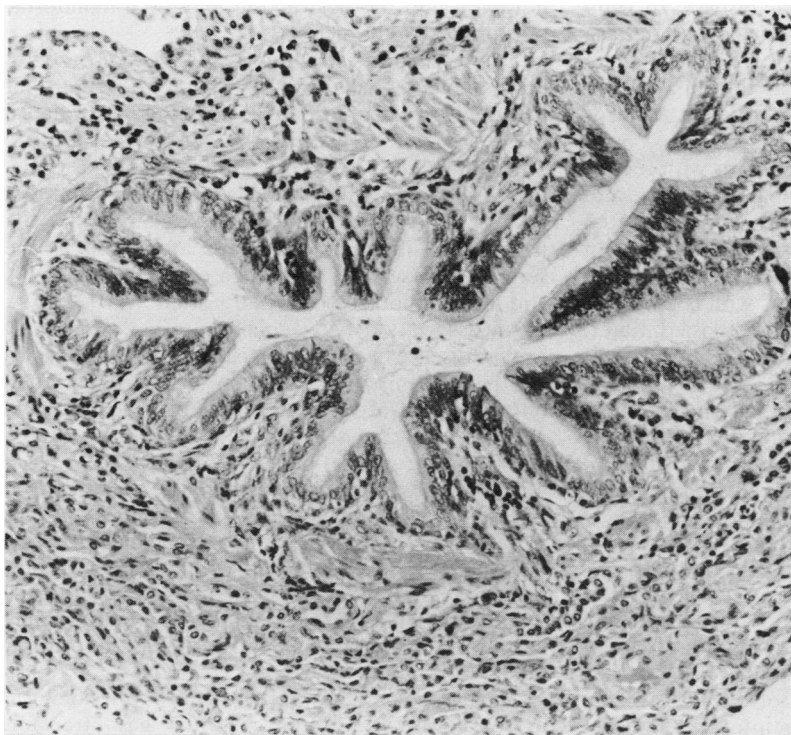


Fig. 9 Case 2. Open lung biopsy. A bronchiole surrounded by fibrous tissue infiltrated by chronic inflammatory cells. Haematoxylin and eosin. $\times 107$.

The changes were generally mild and non-specific, and in two patients the lung parenchyma was normal. In the others there were varying degrees of interstitial, peribronchiolar, and perivascular fibrosis (Figs. 6 and 7); adjacent lung parenchyma showed patchy thickening of the alveolar septa (Fig. 8), and sometimes prominence of granular pneumocytes.

No granulomata were present, and there was no inflammation and no evidence of pulmonary haemosiderosis. Arteries, arterioles, and veins were normal, and there was no abnormality of the capillary basement membranes.

Open biopsy

This showed fibrosis and thickening of alveolar walls and an excess of intra-alveolar macrophages. Bronchioles were surrounded by cuffs of fibrous tissue containing an infiltrate of lymphocytes and plasma cells (Fig. 9), but the extensive peribronchiolar fibrosis seen in case 1 was not present. The muscle coat of these airways was well preserved, and the lining epithelium was of columnar ciliated type. A little mucoid material was sometimes present in the lumen.

Discussion

A number of investigators have reported lung changes in association with coeliac disease. In 1969 Scadding¹ described a patient with coeliac disease who had been exposed to pigeons. At biopsy there were sarcoid like granulomata in the lung parenchyma; a Kveim test was negative. The disease progressed despite steroid treatment. The next year Hood and Mason² reported two patients with coeliac disease, dyspnoea, diffuse pulmonary opacities, and reduced gas transfer. A diagnosis of interstitial fibrosis was made, but no biopsies were taken. In 1971 Lancaster-Smith and others³ found diffuse lung disease in three of 24 patients with coeliac disease, but again these cases were not biopsied. Later, the same group investigated a further 33 coeliac subjects, but found no respiratory disorder.¹³ The biopsy findings in later cases vary, and include desquamative interstitial pneumonitis,¹⁴ idiopathic pulmonary haemosiderosis,⁷ non-specific pleural fibrosis and chronic bronchitis,¹⁵ granulomata associated with avian exposure,¹⁶ and sarcoidosis.⁸

We found no granulomata in any of our subjects, and although a few haemosiderin laden macrophages were sometimes present in the alveoli, they did not justify a diagnosis of pulmonary haemosiderosis. The changes in the lungs of case 1 were not those of a fibrosing alveolitis: instead, they suggested chronic inflammation of the walls of the smaller air passages, extending into the adjacent

lung parenchyma. A similar process in some of the larger airways had caused dilatation rather than narrowing.

The mild interstitial, perivascular, and peribronchiolar fibrosis in the biopsy material was non-specific. Most of the patients were cigarette smokers or ex-smokers, and similar appearances are often found in emphysema. Nevertheless, the changes are consistent with the presence of lesions resembling those in the necropsy case. Such lesions would not be demonstrable in small distorted transbronchial biopsies. The non-specific chronic pneumonitis found in the open biopsy may have been obstructive in nature and could well have been caused by damage to the airways.

Interference with gas transfer is classically associated with fibrosing alveolitis, but it also occurs in any condition causing a ventilation to perfusion mismatch, such as emphysema.¹⁷ The low gas transfer in our patients could therefore be due to damage to the peripheral airways, and the obstructive element could be attributed to involvement of larger airways by a similar process. Tarlo's group⁵ found that asthma, chronic cough, and airway obstruction was more frequent in coeliac than control subjects. None of their eighteen cases had interstitial lung disease. All of our patients with physiological evidence of airways obstruction were current or ex-smokers, however, and the obstruction may be a manifestation of chronic bronchitis.

The pathogenesis of the respiratory disorder in our patients remains obscure. There are no constant immunological abnormalities and their prevalence in coeliac patients with a low gas transfer was no different from that of those with a normal gas transfer.¹⁰ Coeliac patients often have a raised serum IgA and low IgM concentrations, and IgE may also be increased¹⁸; immune complexes are found in the serum of those who have been exposed to gluten¹⁸ and autoantibodies occur more often.¹⁹

An association between bird fancier's lung and coeliac disease has been suggested,^{1 2 16 20} but this has not been confirmed. Hendrick and others²¹ found only one case of bird fancier's lung in 61 patients with coeliac disease, and jejunal villous abnormalities were seen in only five of 143 cases of bird fancier's lung in a recent multicentre study carried out by the British Thoracic Society.²² Furthermore, it has been shown that although avian precipitins occur in 35% of patients with coeliac disease, their presence is related to abnormal absorption of protein by the damaged intestinal mucosa, because they cross react with hen's egg yolk.²³ The avian precipitins in our patients were of this type.

Thus although our patients show physiological evidence of interference with gas transfer,

pathological findings suggest that this is due to disturbed ventilation to perfusion relation consequent on airway rather than alveolar disease. Detailed necropsy studies of the lungs of further cases of adult coeliac disease are required.

We are grateful to Mrs Ruth Fry for secretarial assistance, and Dr Ruth Cayton for help in interpreting the respiratory physiology tests.

References

- ¹ Scadding JG. Lung biopsy in the diagnosis of diffuse lung disease. *Br Med J* 1970;ii:557-64.
- ² Hood J, Mason AMS. Diffuse pulmonary disease with transfer defect occurring with coeliac disease. *Lancet* 1970;i:445-8.
- ³ Lancaster-Smith MJ, Benson MK, Strickland ID. Coeliac disease and diffuse interstitial lung disease. *Lancet* 1971;i:473-6.
- ⁴ Eade OE, Berrill WT. Coeliac lung disease. *Lancet* 1978;i:1262-3.
- ⁵ Tarlo SMM, Broder I, Prokipchuk EJ, Peres L, Mintz S. Association between coeliac disease and lung disease. *Chest* 1981;80:715-8.
- ⁶ König G, Albert E, Dewait M, *et al.* Extrinsic allergic alveolitis combined with coeliac disease in childhood. *Respiration* 1982;43:444-51.
- ⁷ Wright PH, Menzies IS, Pounder RE, Kneeling PWN. Adult idiopathic pulmonary haemosiderosis and coeliac disease. *Q J Med* 1981;50:95-102.
- ⁸ Douglas JG, Gillon J, Logan RFA, Frant IWB, Crompton GK. Sarcoidosis and coeliac disease: an association? *Lancet* 1984;ii:13-5.
- ⁹ Robinson TJ. Coeliac disease with farmer's lung. *Br Med J* 1976;i:745-6.
- ¹⁰ Williams A, Asquith P, Edwards C, Stableforth DE. Alveolitis in adult coeliac disease—a new syndrome. *Thorax* 1984;39:219.
- ¹¹ Kinney HC, Burger PC, Hurwitz BJ, Hijman JC, Grant JP. Degeneration of the central nervous system associated with coeliac disease. *J Neurol Sci* 1982;53:9-22.
- ¹² Edwards C, Krypczyk A, Brownhill A. Plastic embedding of transbronchial biopsy specimens for light microscopy. *J Clin Pathol* 1979;32:1294-8.
- ¹³ Lancaster-Smith MJ, Perrin J, Swarbrick ET, Wright JT. Coeliac disease and autoimmunity. *Postgrad Med J* 1974;50:45-8.
- ¹⁴ Fitzgerald MX, Hegarty J, Brennan NJ. Desquamative interstitial pneumonia (DIP) and adult coeliac disease. *Am Rev Res Dis* (suppl) 1977;115:105.
- ¹⁵ Cummiskey J, Keelan P. Coeliac disease and diffuse pulmonary disease (letter). *Br Med J* 1976;i:1401.
- ¹⁶ Birrell WT, Eade OE, Fitzpatrick TF, Hyde I, McLeod WM, Wright R. Bird fancier's lung and jejunal villous atrophy. *Lancet* 1975;ii:1006-8.
- ¹⁷ Cotes JE. *Lung function. Assessment and application in medicine.* Oxford: Blackwell, 1979.
- ¹⁸ Cooke WT, Holmes GKT. *Coeliac disease.* Edinburgh: Churchill Livingstone, 1984.
- ¹⁹ Kumar P, Oliver RTD, O'Donoghue DP, *et al.* The relationship of HLA-A, B status to the clinical findings and autoimmunity in coeliac disease. In: McConnel RB, ed. *The genetics of coeliac disease.* Lancaster: MTP Press, 1981.
- ²⁰ Morris JS, Read AE, Jones B, Cotes JE, Edwards JH. Coeliac disease and lung disease (letter). *Lancet* 1971;i:754.
- ²¹ Hendrick DJ, Faux JA, Anand B, Piris J, Marshall R. Is bird fancier's lung associated with coeliac disease? *Thorax* 1978;33:425-8.
- ²² British Thoracic Society. A national survey of bird fanciers' lung: including its possible association with jejunal villous atrophy. *Br J Dis Chest* 1984;78:75-87.
- ²³ Faux JA, Hendrick DJ, Anand BS. Precipitins to different avian serum antigens in bird fancier's lung and coeliac disease. *Clin Allergy* 1978;8:101-8.

Requests for reprints to: Dr CW Edwards, Department of Histopathology, East Birmingham Hospital, Bordesley Green East, Birmingham B9 5ST, England.