

POSTERIOR FOSSA DERMOID CYSTS WITH SPECIAL REFERENCE TO INTRACRANIAL INFECTION

BY

VALENTINE LOGUE and KENNETH TILL

From the Department of Neurological Surgery, St. George's Hospital, London

The full understanding of the natural history of intracranial dermoid cysts has long remained incomplete owing to the infrequent occurrence of these tumours, but of recent years a sufficient number of isolated case reports have appeared to explain many of their obscure but interesting features. In particular these reports have revealed that dermoid cysts lying in the posterior fossa are prone to certain complications, notably infective, and have signs both clinical and radiological which are peculiar to their situation and which are not shared by the supratentorial dermoids.

Some aspects of dermoid cysts are well known. They arise from misplacement of fragments of ectoderm in the vicinity of the developing neural tube about the third or fourth week of embryonic life. Their derivation from skin is amply confirmed by microscopical examination of the cyst wall, which is seen to be composed of corium and epidermis in which appear some or all of the structures present in normal skin; sebaceous glands and sweat glands which may be well formed or only rudimentary, hair and hair follicles, fat, muscle, elastic fibres, and blood vessels. This complete skin layer, however, is variable in its extent and may be confined to a small area of the cyst wall, the remainder being lined solely by epidermis.

The contents of the cyst comprise fat cells, sebaceous material and cholesterol, with usually a number of long, coiled hairs lying separately or in clumps, and which at operation form the diagnostic feature of this type of tumour. An individual cyst may be round, oval, or bilocular, the shape depending to some extent on its situation, and in size varies from a few millimetres to several centimetres in diameter.

Dermoid cysts may occur anywhere within the skull, but their commonest single site is in the posterior fossa at or near the midline, where approximately one-third of the total number of recorded cases have been located (Brock and Klencke, 1931; Sweet, 1940).

It can be generally stated that whatever its intracranial situation a dermoid cyst tends slowly to enlarge as a result of the secretion of sebaceous material and the desquamation of epithelium within it, and that after a varying time symptoms are produced resembling those arising from the more slowly growing types of brain tumour. Occasionally the symptoms may be rapidly progressive or, on the other hand, the cyst may enlarge so slowly that it does not manifest its presence during the course of a long life.

Dermoid cysts lying adjacent to the ventricles or subarachnoid space carry a further hazard in that they may rupture and discharge their contents into the cerebrospinal fluid to produce symptoms bizarrely various. One clinical picture is that of an acute cerebral vascular accident resulting in coma and death within a few hours or days, the diagnosis being revealed by the oily fluid obtained at spinal puncture. Another syndrome resembles subacute meningitis which may run a course of several weeks before terminating in spontaneous recovery or death. A rarer manifestation of rupture is that of progressive internal hydrocephalus without symptoms of meningitis. This is the result of a diffuse hypertrophy of ependymal and leptomeningeal cells around deposits of lipoid, which leads to obstruction of the flow of cerebrospinal fluid through the aqueduct of Sylvius and over the convexity of the brain. It has been shown experimentally that the cholesterol in the cyst contents is the substance responsible for these meningeal reactions (Bender, 1925; Greenfield, 1932).

Metastatic blood stream infection from a focus elsewhere in the body is another rare complication. Among our own cases of posterior fossa dermoid cysts there is one in an 11-day-old infant which was infected as part of a pyaemia from umbilical cord sepsis.

These manifestations and complications are common to dermoid cysts whatever their intracranial situation, whether above or below the

tentorium, but those situated in the posterior fossa possess in addition certain features which, while making their clinical diagnosis more evident, add considerably to the danger of their presence within the skull.

Posterior Fossa Dermoid Cysts

The most notable characteristic of dermoid cysts in the posterior fossa is their tendency to lie in the midline of the skull whatever their relationship to the intracranial structures, whether outside or within the dura mater, and although in the latter position they may enlarge asymmetrically over one or other cerebellar hemisphere the main bulk of the tumour overlies the vermis or outlet of the fourth ventricle. This constant site is probably related to the development of the tentorium and falx cerebelli which occurs as an invagination of two folds of dura, strictly in the midline of the posterior fossa, and may draw in fragments of the skin layer with it. Confirmation is lent to this by the observation that the intradural cysts commonly have a firm attachment to the tentorium. Exceptionally a cyst may lie at a distance from the midline, in the cerebello-pontine angle or adjacent to the brain stem, but such deviations from the usual position are extremely rare.

Another peculiarity of these tumours is that the attachment to the skin from which they develop may be retained as a narrow sinus lined with epithelium, which links the cyst with the skin through an opening in the occipital bone. This is a feature which distinguishes them from the supratentorial dermoid cysts, where a primary skin attachment does not occur and which allies them developmentally with the dermoid cysts and congenital dermal sinuses occurring in the spinal canal. This connexion with the skin, perhaps better called the occipital dermal sinus, will permit extrusion of the dermoid contents to the exterior and, what is more important, will provide direct access to the cavity of the tumour for any bacteria lying on the surface. If the tumour should lie intradurally the invading organisms, once having entered the cyst, are separated from the cerebrospinal fluid only by the cyst lining and pia arachnoid, a tenuous barrier which may offer little resistance to the further spread of infection.

A study of the reported cases of posterior fossa dermoid cysts reveals that they can be divided into four groups depending on two criteria; first their anatomical situation, whether extradural or intradural, and secondly the degree of development of the occipital dermal sinus, whether absent altogether, partial or complete. Furthermore it is found that with cysts lying extradurally the occipital dermal

sinus seems always to persist in its entirety, linking the tumour with the skin through an opening in the occipital bone. With the intradural dermoid cysts, however, there is a wider variation in the dermal sinus. In most cases the connexion to the skin disappears completely leaving a cyst in the depths of the posterior fossa with no abnormality of the overlying bone or skin to record its presence. In those remaining cases where the dermal sinus persists it does so in one of two forms, either as a complete sinus leading from tumour to skin in a fashion similar to the extradural variety, or merely as a short tube attached to the skin and ending blindly in the subcutaneous tissue over the occipital protuberance.

These four groups, one extradural and three intradural, can be set down thus: (1) extradural dermoid cyst with complete dermal sinus; (2) intradural dermoid cyst (*with no dermal sinus*); (3) intradural dermoid cyst with an *incomplete dermal sinus*; and (4) intradural dermoid cyst with a *complete dermal sinus*.

These variants are illustrated diagrammatically in Fig. 1 and the relative frequency with which they occur can be seen from Table 1, which is composed of 25 cases gathered from the literature in which the descriptive details are adequate, and seven cases of our own, a total of 32.

TABLE I
RELATIVE FREQUENCY OF FOUR TYPES OF POSTERIOR FOSSA
DERMOID CYST IN 32 CASES

Type of Tumour	No. of Reported Cases*	No. in Present Series	Total
Extradural with complete sinus ..	2	1	3
Intradural without a dermal sinus ..	16	2	18
Intradural with incomplete sinus ..	3	1	4
Intradural with complete sinus ..	4	3	7
Total	25	7	32

*Belloni (1925). Clairat (1838); Courville and Kimball (1936); Downes (1923); Gladstone (1937); Gorog (1927); Horrax (1922); Irvin (1873); Kruse (1891); Kwan (1910); Lannelongue (1910); Love and Kernohan (1936); Martin and Davis (1943); Miller (1937); Munro and Wegner (1937); Quade and Craig (1939); Rand and Reeves (1943); Ruschhaupt (1903); Sweet (1940); Todesco (1927); Verbiest and Zeldenrust (1938); Webster (1938).

Clinical Features of Individual Cysts

Extradural Dermoid Cyst with Complete Dermal Sinus.—This type of tumour lies outside the dura embedded in the midline of the occipital bone which it thins and erodes in a typical manner. The dermal

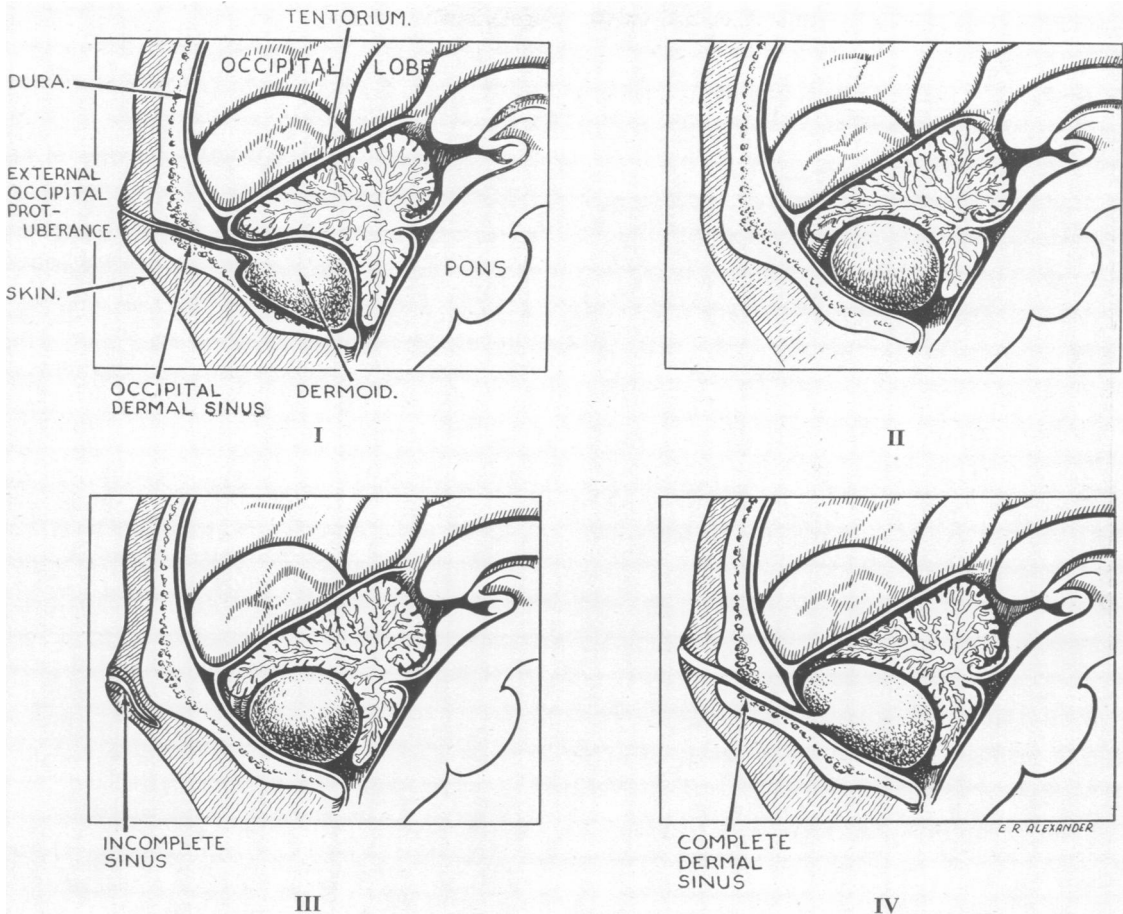


FIG. 1.—Semi-diagrammatic drawing of a sagittal section through the posterior fossa to illustrate the four varieties of posterior fossa dermoid cysts. I, Extradural dermoid cyst with complete dermal sinus; II, intradural dermoid cyst without a dermal sinus; III, intradural dermoid cyst with incomplete sinus; IV, intradural dermoid cyst with complete sinus.

sinus forms a fine stalk which arises from the upper pole of the tumour and pierces the remaining thickness of bone to gain attachment to the skin over the external occipital protuberance. The contents of the cyst pass along this stalk either to discharge on to the skin and so draw attention to its presence, or, if the exit is blocked, to collect in the terminal portion of the sinus and form a subcutaneous swelling, which is often removed surgically and mistakenly as a "sebaceous cyst", the incision never healing afterwards.

The history in this variety of dermoid is quite characteristic and is illustrated by our first case.

Case 1 : B. B.—This was a boy aged 2 years. Shortly after birth it was noticed that he had a lump the size of a pea at the back of his head. This was removed at a local hospital when he was 11 months old and was said

to have been a "cyst". The incision did not close after the operation and discharged yellow fluid intermittently. At the age of 18 months and again at 2 years the sinus was re-excised, without success, at the same hospital. Shortly after the third operation the child was admitted to this department. Clinical examination revealed a small sinus over the occipital protuberance which discharged pus containing *Staph. aureus*. No abnormality could be detected in the central nervous system.

A radiograph of the skull (in the half-axial view) showed a roughly circular defect 1.5 cm. in diameter, surrounded by a smooth margin of sclerotic bone situated in the midline of the occiput just below the inion (Fig. 2).

At operation the sinus and surrounding scar tissue was explored, but no connexion could be found with the underlying bone and it was unfortunately again only locally excised. This time it remained healed for a few weeks before breaking down once more. The sinus

was then re-explored (for the fifth time), and on this occasion a small stalk was seen leading obliquely downwards to enter a channel in the external occipital protuberance. The shell of bone around this channel was removed to uncap a dermoid cyst containing yellow, cheese-like material, lying in contact with, but outside, the dura just below the torcula, with the dermal sinus

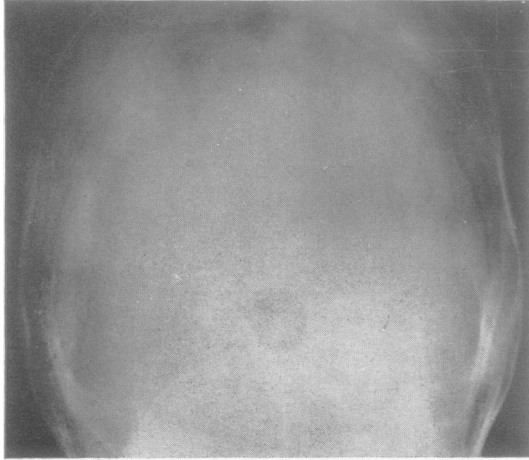


FIG. 2.—Radiograph (half-axial projection) of Case 1 showing the circular defect with sclerosed edge in the occipital bone.

entering at its upper pole. The capsule and contents were completely excised, after which the wound healed promptly and has remained so ever since.

Microscopical examination showed a lining of squamous epithelium bearing hair follicles and sebaceous glands (Fig. 3).

This case illustrates the significance of small "cysts" and sinuses over the midline of the occiput in children and the need for radiography of the bone in this region before contemplating surgical removal.

The x-ray appearance is unmistakable, although occasionally mimicked by the epidermoid tumour, and consists of a circular defect varying in different cases from 1.5 to 5 cm. in diameter, with a smooth, sometimes scalloped, margin of sclerotic bone, situated in the midline just below the inion. The small channel conveying the dermal sinus lies above the defect, but cannot as a rule be distinguished on account of its fine calibre and the fact that it passes obliquely through the thick bone of the external protuberance.

This variety of dermoid cyst typically does not produce intracranial symptoms, but occasional cases have been reported in which the extradural mass had enlarged sufficiently to compress the contents of the posterior fossa (Martin and Davis, 1943).

Intradural Dermoid Cyst without Dermal Sinus.—Table I shows this to be the commonest variety of

posterior fossa dermoid. In general this type of cyst tends to manifest itself at a later age than those in which the dermal sinus persists and symptoms do not usually appear until adult life. It has no certain diagnostic features and, as its symptoms do not differ notably from those of other tumours of the cerebellum, they do not warrant a detailed description. There are certain points, however, which may arouse suspicion of its identity. These are (1) an extremely slow evolution of symptoms; (2) signs pointing to a predominantly midline situation of the tumour, in contrast to the frankly neoplastic cysts in adult life, which tend to lie more laterally, in the cerebellar hemispheres; (3) the demonstration by radiography of congenital anomalies of the cervical spine, in particular, fusion of the laminae or vertebral bodies.

When exposed at operation the tumour, blue or green, is seen to overlie the vermis pushing it upwards and forwards, indenting the adjacent surfaces of the cerebellar hemispheres and displacing the cisterna magna downwards.

Less frequently it lies at a lower level and projects into the fourth ventricle, or may even extend through the foramen magnum to produce additional symptoms of involvement of the spinal cord.

Intradural Dermoid with Incomplete Dermal Sinus.—In this variety the tumour lies in a similar situation

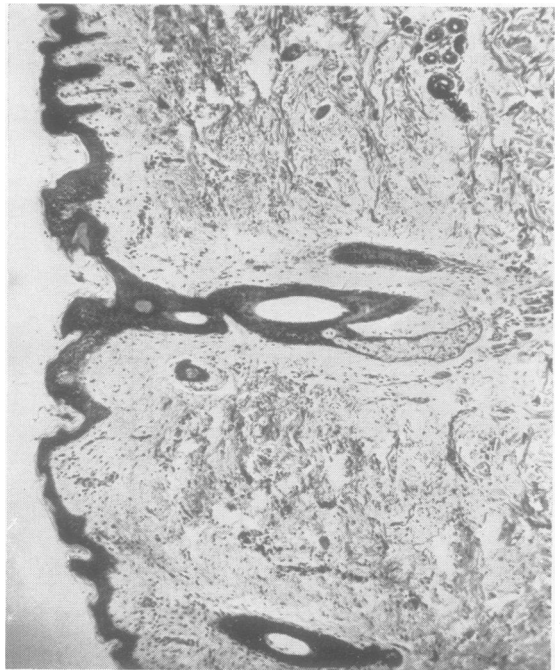


FIG. 3.—Section shows a well-preserved part of the cyst wall consisting of a deep collagen layer and well formed stratified squamous epithelium. Hair follicles and sebaceous glands are present. Haematoxylin and eosin. $\times 45$.

to the previous one and produces identical neurological symptoms.

The dermal sinus originates from a dimple in the skin overlying the occipital protuberance and extends for a short distance into the subcutaneous tissue to end either blindly, or attached to the periosteum. The sinus, although carrying no added risk of complications, will be of help in revealing the nature of the underlying tumour. This occurred in one of our cases.

Case 2 : E. B.—This was a woman aged 61, who for one year had had symptoms referable to a midline posterior fossa tumour causing an internal hydrocephalus.

Radiography showed, in addition to signs of raised intracranial pressure, fusion of the bodies and laminae of the second, third, fourth, and fifth cervical vertebrae. There was no defect in the bone of the occiput.

Ventriculography confirmed the hydrocephalus and demonstrated an aqueductal "kink" characteristic of a large midline cerebellar tumour. When the head was shaved a dimple 2 mm. in diameter was seen lying over the occipital protuberance and a small cord-like process could be palpated running obliquely downwards and forwards from it for a short distance. The presence of a dermoid tumour had been suggested by the congenital deformity of the cervical spine, and the discovery of the dermal sinus made this diagnosis unequivocal. Such a tumour, the size of an egg, was found lying over the vermis and adjacent portions of the cerebellar hemispheres and was completely removed. The sinus extended from the skin for 2 cm. into the subcutaneous tissue and ended blindly.

Intradural Dermoid with Complete Dermal Sinus.—The characteristic feature of this type is the presence of a dermal sinus leading from the midline intradural cyst through an opening in the occipital bone to be attached to the skin. The sinus discharges either as a natural phenomenon or, if its outlet is blocked, as a result of the surgical removal of its terminal dilated portion in the belief that it is a "sebaceous cyst". In addition to the intermittent discharge of sebaceous material, which may be extremely variable in amount, the sinus provides a pathway whereby organisms can gain access to the intradural tumour and thence to the subarachnoid space and cerebellum.

We have three cases which illustrate the serious complications resulting from the entry of organisms into this variety of dermoid cyst.

Case 3 : G. R.—This was a girl of 4 years of age who, some three months before admission to this department, had become drowsy and irritable, complained of severe headache, and was shortly admitted to a local hospital in a semi-comatose condition. On spinal puncture a milky fluid was obtained from which *Bact. coli* was cultured. She was treated with systemic and intrathecal penicillin (streptomycin was not at that time available).

The meningeal infection was overcome by the nineteenth day, but a raised pressure in the cerebrospinal fluid persisted with a slightly increased white cell count. During the fourth week after admission there was another episode of drowsiness, irritability, neck stiffness, and fever, but these signs subsided spontaneously and she was sent home three weeks later apparently well, except that she was unsteady on her feet and tended to fall if unsupported.

Two weeks elapsed and the child then began to vomit after her meals and again became drowsy and complained of headache. At this stage she was readmitted to the local hospital where examination revealed early papilloedema and a left lower facial weakness. A small fluctuant swelling had appeared over the occipital protuberance which was later incised releasing pus containing *Bact. coli*.

The patient was then transferred to this department. On examination, papilloedema was well marked in both eyes. The cranial nerves were otherwise normal, except for dilated, inactive pupils. The limbs on both sides showed an ataxia of cerebellar type with reduction of all tendon reflexes. The plantar responses were flexor. The child could walk only when supported and then very unsteadily, and if support was withdrawn she fell over.

Radiographs of the skull showed diastasis of the coronal and sagittal sutures. In the half axial projection a narrow channel 1 cm. in length with sclerosed walls leading down to an oval groove was seen in the occipital bone below and slightly to the left of the internal protuberance (Fig. 4). The significance of these findings was not appreciated at that time.

The diagnosis of a midline cerebellar abscess was made and the location confirmed by ventriculography. A needle introduced through a suboccipital burr hole entered an abscess from which 15 ml. of pus were aspirated and 20,000 units of penicillin and 2 ml. of thorotrast replaced. The infecting organism was identified as *Bact. coli*. The thorotrast outlined the abscess showing it to be irregularly spherical and measuring 3 cm. in diameter (Fig. 5). During the ensuing three and a half weeks serial radiographs showed that the abscess had grown bigger, and it was observed that the capsule did not take up the thorotrast in the manner usually seen in a brain abscess. It was decided to perform a total excision.

At operation a firm cord of tissue was found which ran from a skin dimple close to the scar over the occipital protuberance, obliquely down through a small channel in the bone to fuse with the dura just below the torcula. When this cord was cut across, pus and a number of long golden hairs extruded, which revealed the true nature of the tumour. The dura was then opened to expose a pus-filled dermoid cyst the size of an egg overlying the vermis and separating the hemispheres; this was removed with considerable difficulty owing to numerous adhesions. The dermal sinus entered at its upper pole and its lower extremity was attached by a strand of tissue to the medulla at the lower end of the fourth ventricle.

Post-operatively sulphonamides and penicillin were

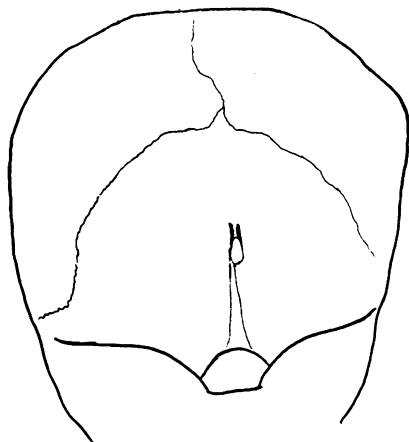
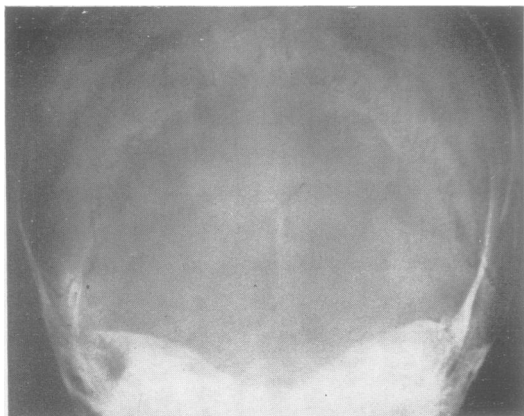

FIG. 4.—Radiograph and line drawing to show the channel and groove in the occipital bone in Case 3.

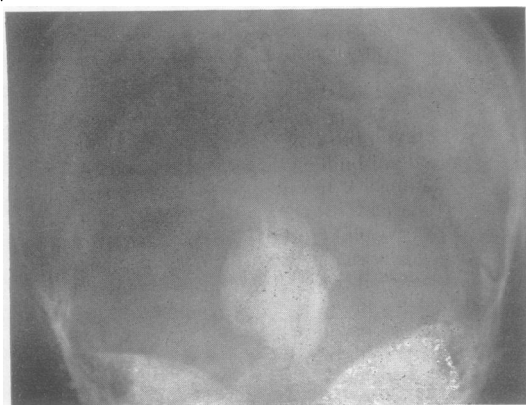

FIG. 5.—Radiograph of the skull of Case 3 showing the abscess cavity outlined by thorotrast. At the upper margin of the abscess the dense, bony walls of the channel conveying the dermal sinus can be seen.

continued and despite coliform bacilli being cultured from the ventricular fluid on two occasions, and the occurrence of a series of cerebellar fits, the child slowly

recovered. She returned home four weeks after operation, by which time the papilloedema and all signs of cerebellar dysfunction had disappeared. She has been seen at intervals during the past three years and appears to be developing as a normal child.

Microscopical examination of the tumour confirmed the typical features of an infected dermoid cyst.

The evolution of the infection in this case can be divided into three stages. First the entrance of *Bact. coli* into the dermal sinus leading to an infection of the cyst, with presumably an immediate spread to the leptomeninges. (It should be noted that there had never been sufficient discharge from the sinus to draw the parents' attention to it, and intracranial infection was the first sign of the presence of the tumour.) This initial attack of meningitis, and a second milder episode three weeks later, was overcome, but infection in the cyst progressed, converting it into an abscess which then produced all the signs of a midline expanding lesion. Also during this phase some pus tracked externally along the dermal sinus to collect under the scalp. Finally, the intracranial abscess increased in size despite aspiration and the introduction of an antibiotic and this, combined with the unusual behaviour of the thorotrast suggesting an atypical pathology, determined its surgical removal.

This case emphasizes the rule that the occurrence of what appears to be a primary coliform meningitis should demand a careful search for a "sebaceous cyst," dimple, or sinus in the skin of the occiput (and of course the spine). The case also demonstrates the radiological features which we have come to regard as diagnostic of this variety of dermoid cyst, consisting of a small channel with dense walls leading down to an oval groove in the midline of the occipital bone just below the inion. This appearance has to be distinguished from other openings in the bone in this situation and the main points of differential diagnosis will be mentioned later.

Case 4 : J. S.—This was a girl aged 16 months at her first admission to this department, who, shortly after birth, was noted to have a small swelling over the centre of the occiput which about once a month discharged some brownish material and then closed up. This lump had been excised two weeks earlier at another hospital, when a small cord was found leading down to a slit-like opening in the bone of the occipital protuberance. As this stalk was tied off it was observed to contain some fine black hairs. The wound did not heal and the child was then transferred to this department.

Examination revealed a small scab in the centre of an otherwise healed occipital incision. There was no abnormality detected in the central nervous system.

A radiograph of the skull in the half axial view showed, as in the previous case, a narrow channel in the midline of the occipital bone leading down to an oval groove

(Fig. 6). An air study was performed to determine whether there was an intradural extension of the tumour and this showed a ventricular system of normal size, with no deformity of the aqueduct or fourth ventricle. It was believed that these findings excluded the presence of an intradural tumour of any extent and it was thought safe to postpone surgery until the patient was older. The dermal sinus closed at this time and the child returned home.

She was seen three months after leaving hospital and again 12 months later, when she seemed perfectly well, and, as the sinus had remained healed, nothing further was done about the removal of the dermoid cyst.

The child was admitted as an emergency 20 months after leaving hospital. During the preceding four months she had experienced several attacks, lasting from 12 to 36 hours, of right occipital headache, associated with profuse vomiting and neck stiffness. Two days before admission a further attack occurred, after which she improved for a few hours and then rapidly became drowsy with a temperature of 101.4°F and had two generalized convulsions. On examination, the child was drowsy, but accessible. There was marked neck retraction and the skull had a boxy note on percussion. The occipital incision and dermal sinus were firmly healed. There was no papilloedema and the remainder of the nervous system disclosed no abnormality other than a positive Kernig's sign.

Ventricular puncture was performed and fluid under high pressure was withdrawn which contained 400 polymorphs per c.mm. and organisms identified as *Staph. aureus* (coagulase positive), which were sensitive to penicillin.

Despite intensive antibiotic therapy the patient's condition deteriorated, with a rising temperature and respiration rate and she died two days later. At necropsy a diffuse meningitis was revealed, the subarachnoid space being filled with thick, yellow exudate. A dermoid cyst measuring 3 × 2 × 2 cm., distended with pus and containing many long, golden hairs, was found lying between the cerebellar hemispheres. Attached to its upper pole was the dermal sinus which passed through a defect in the occipital bone to fuse with the skin (Figs. 7 and 8).

The course of the infection in this case can be divided into four phases: (1) organisms entered the cyst during one of the episodes when the sinus was discharging; (2) the sinus then healed and the infection remained quiescent for 16 months, with the child apparently perfectly well; (3) the organisms then assumed a more pathogenic character converting the cyst into an abscess with a resultant rise in intracranial tension and recurring attacks of headache and vomiting over four months; (4) infection finally spread to the meninges with a fulminating meningitis.

Bearing in mind the lessons learned from these two cases, we decided that when next a patient was seen with an occipital dermal sinus in conjunction with the typical radiographic appearances in the

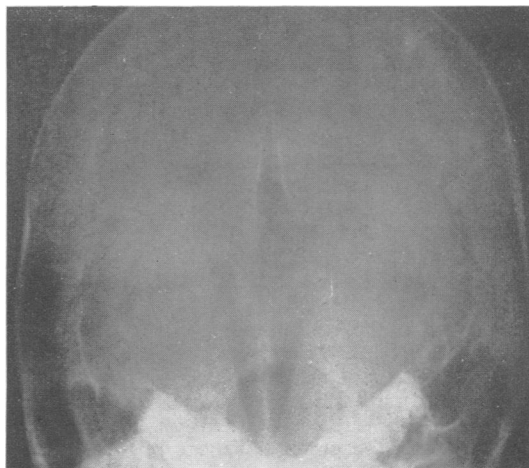
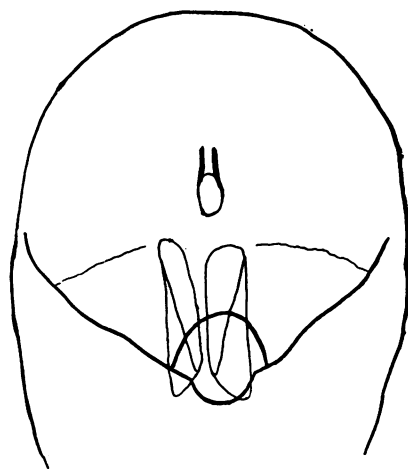


FIG. 6.—Radiograph (half-axial view) and line drawing to show the channel and groove in the occipital bone in Case 4. (A ventriculogram has been performed and air can be seen in the frontal horns and bodies of the ventricles.)



occiput indicating an intracranial extension, the dermoid cyst should be removed forthwith before the development of inflammatory complications.

The following case was referred for treatment.

Case 5: J. W.—This was a boy aged 11 months. Shortly after birth the mother noticed a pin-point opening at the back of the child's head. When 4 months old some fluid, which matted the child's hair, discharged from the opening. At 5 months of age and again at 9 months further discharges occurred, after which the sinus had remained healed for the two months before admission. There had been no intracranial symptoms.

Examination disclosed a soft swelling 2 cm. in diameter lying just above the occipital protuberance and bearing on its surface a dimple measuring 2 mm. across (Figs. 9 and 10). On rolling the skin the dimple retracted further, indicating a deep attachment, and a firm cord could be felt leading from it down to the bone. The punctum was healed and no sebaceous material

could be expressed from it. There were no abnormal signs in the central nervous system.

Radiographs of the skull in the half axial projection showed in the midline below the internal protuberance the typical short channel and groove (Fig. 11). In an attempt to ascertain the size of the intracranial portion of the dermoid, an encephalogram was performed which showed a normal cisterna magna, fourth ventricle, and aqueduct (Fig. 12). The cerebrospinal fluid obtained during this procedure was normal in all respects.

At operation, through a vertical incision, the punctum in the skin was encircled and the dermal sinus exposed. This ran obliquely downwards for 2 cm. to enter a slit-like channel in the bone just below the occipital protuberance (Fig. 13). The bone surrounding the channel was removed to reveal the inner end of the sinus which expanded in trumpet-like fashion, occupying the groove seen in the radiograph, and fused with the dura round the margins of the posterior surface of the intradural dermoid (Fig. 14). An incision was made in the dura mater to encircle this attachment. Projecting into the cisterna magna from the inner surface of the dura was a thin-walled, yellow dermoid cyst measuring 1×1.5 cm., its upper pole being adherent to the tentorium in the midline. This latter attachment, containing several large veins, was divided and the dermoid with the dermal sinus could then be lifted out (Fig. 15). Its only connexion with the cerebellum was by a small artery running to it from the vermis.

Some of the contents of the tumour were removed for culture as soon as it had been excised and a profuse growth of *B. proteus* resulted.

FIG. 7.—Photograph of base of brain of Case 4. The collapsed dermoid is seen overlying the vermis and outlet of the fourth ventricle. Some hairs are protruding from an opening in its upper pole where the dermal sinus was attached.

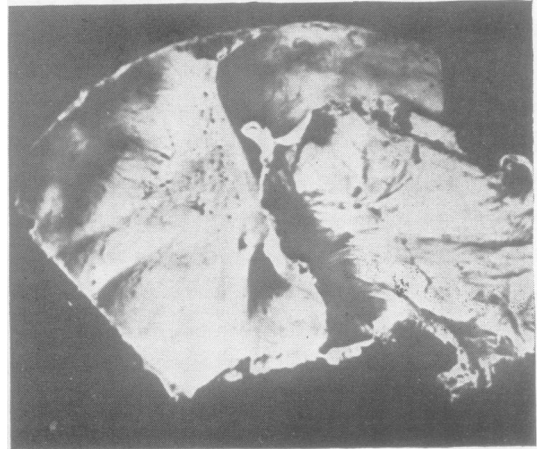
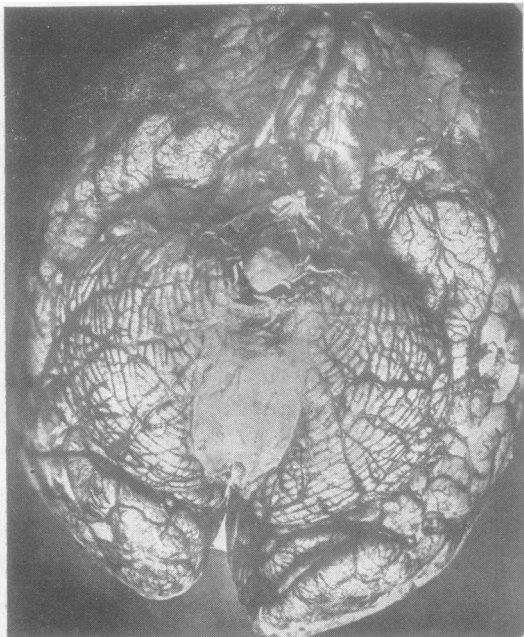


FIG. 8.—Photograph of the central portion of the occipital bone in Case 4 from which the dura has been partly stripped. The groove with its margins converging to enclose the opening of the channel is seen in the lower part of the bone.

Forty-eight hours after the operation the child developed a temperature of 104°F . and became restless and irritable. Spinal puncture disclosed a cloudy fluid containing 5,500 polymorphs, and culture grew the same *B. proteus* as found in the dermoid, which was sensitive to streptomycin. The child was treated with systemic and intrathecal streptomycin and the meningitis was cured in 12 days. He was sent home five weeks after operation and has remained perfectly well ever since (one year).

There are several points of resemblance between this and the previous case. Both presented in the same manner with a discharging dermal sinus. Both showed the pathognomonic x-ray change in the occipital bone, and careful air studies failed to demonstrate the presence of a tumour in the posterior fossa. The sinus remained healed, in the first patient for 16 months, and we inferred that the intracranial infection was due to the activation of organisms which had gained entry at a much earlier stage when the tumour was discharging and had then remained quiescent. This inference that pathogenic organisms could remain inactive in these dermoid cysts for long periods was amply confirmed by the second patient, when organisms were actually found in the cyst two months after the sinus had last discharged and a brisk meningitis left no doubt as to their pathogenicity.

Discussion

Symptomatology.—In the case of the intradural dermoid (*a*) with no dermal sinus, or (*b*) with an incomplete sinus, the cyst enlarges slowly and manifests itself in adult life with the symptoms of a midline cerebellar tumour, when it can be removed

FIG. 10.—The dimple and dermal sinus in Case 5 leading down to the small bone defect have been outlined with a skin pencil.

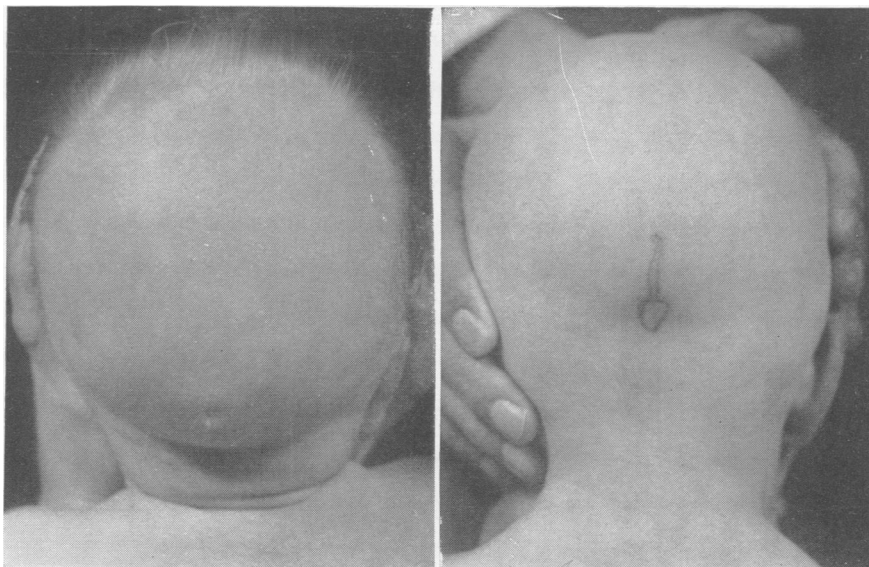


FIG. 9.—Photograph showing the skin dimple over the external occipital protuberance in Case 5.

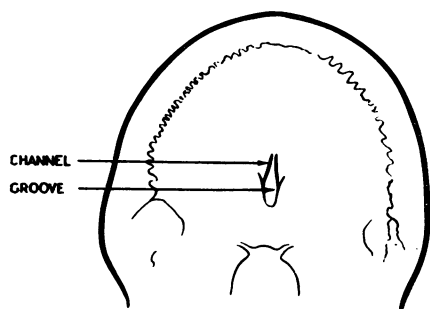
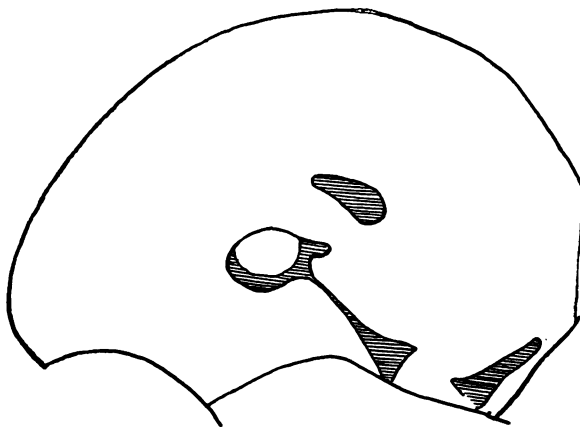


FIG. 11.—Radiograph and line drawing to show the groove and channel in the occipital bone in Case 5.

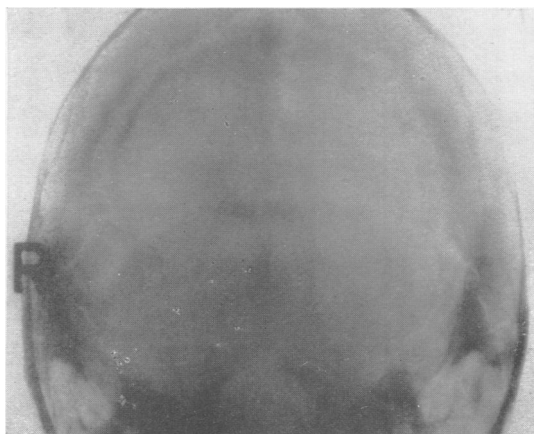

FIG. 12.—Tracing of encephalogram demonstrating the normal appearance of the cisterna magna, aqueduct, and fourth ventricle.



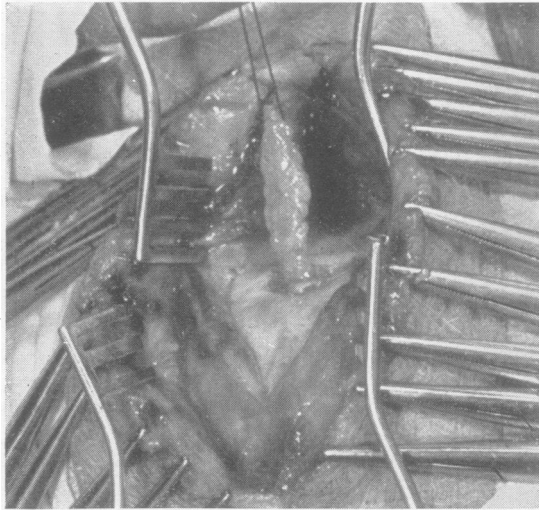


FIG. 13.—Photograph during operation on Case 5. The vertex of the child's head is towards the lower border of the photograph. The dermal sinus has been dissected out and then rotated caudally to expose its neck running into the bone.

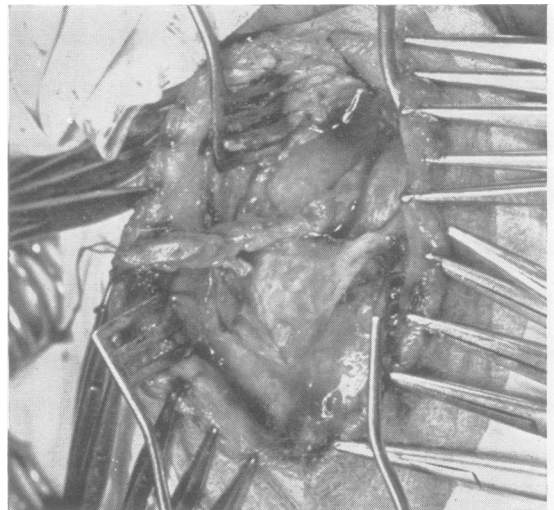


FIG. 14. Photograph during operation on Case 5. The bone has been removed to expose the dura of the posterior fossa and the dermal sinus has been rotated over to the patient's right. The trumpet-like expansion of the dermal sinus as it fuses with the posterior border of the dermoid is well shown.

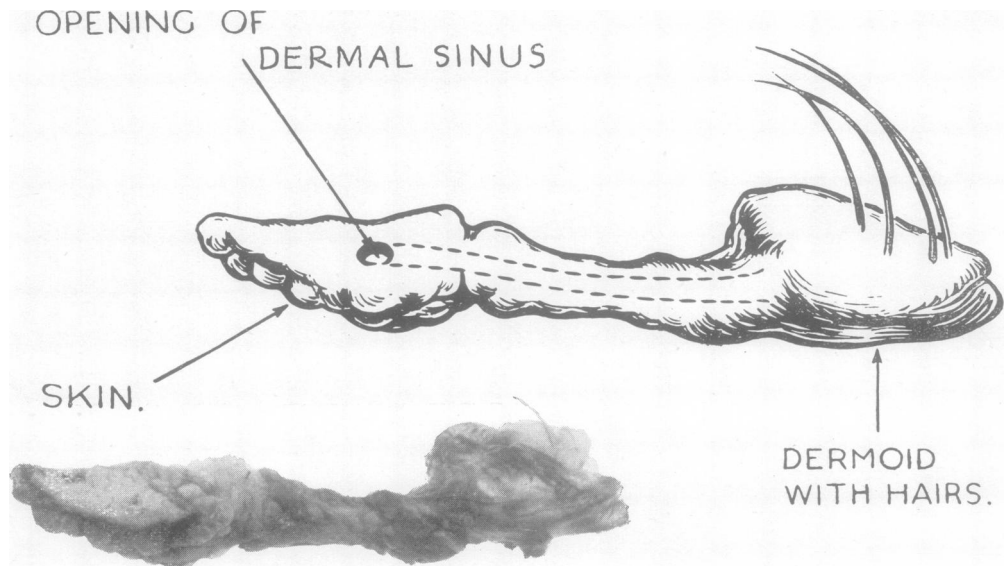


FIG. 15.—Photograph and line drawing of excised dermoid in Case 5.

without much difficulty and with an excellent prognosis.

It is the presence of the complete dermal sinus which alters the mode of presentation and the prognosis. In the case of the *extradural* tumour with complete sinus the outlook is not so grave, and except for the rare occasions when the tumour enlarges sufficiently to encroach on the capacity

of the posterior fossa it will merely present as a midline occipital sinus which discharges from time to time. A radiograph will demonstrate the typical bone change, and its surgical removal is simple.

It is when the intradural type of dermoid cyst retains its complete dermal sinus that the most serious results of this link with the skin are seen, and the fact that most of the reported cases, and

our own three examples, have occurred in infants or young children indicates that these tumours are vulnerable to infection at an early stage.

The first intimation of the presence of this type of dermoid cyst is usually that of a discharge of sebaceous contents from the occipital dermal sinus or the appearance of a subcutaneous swelling over the occipital protuberance. This swelling is often removed surgically so that a sinus appears secondarily. The discharge occurs intermittently, often at long intervals, but, as shown by Case 4, it is possible for septic complications to occur after the dermal sinus has been healed for a considerable time.

Once infection becomes active the subsequent course is variable. It may remain for a time confined to the cyst, converting it into a midline cerebellar abscess, but spread to the leptomeninges eventually occurs to cause a terminal meningitis (Case 4).

In other cases there is an early spread to the subarachnoid space, and if the child survives this attack of meningitis, then enlargement of the cyst as a midline abscess appears subsequently with or without further episodes of meningitis. A less frequent method of spread is that directly into the substance of the cerebellum to form a true cerebellar abscess, the dermoid cyst tending to remain small. This occurred in a case reported by Gladstone (1937).

In other patients where the discharge has not been sufficient to draw attention to the presence of the sinus, as in our Case 3, the first symptom will be referable to the intracranial spread of infection, either an abscess or meningitis, and it is in this type of case that the routine careful search of the occiput and spine for a dermal sinus may be so rewarding in diagnosis.

Diagnosis.—In cases where an occipital dermal sinus is suspected a search will reveal a dimple in the skin 1 or 2 mm. in diameter, often lying on top of a small subcutaneous swelling. The dimple is situated at a level just above the external occipital protuberance more or less in the midline and the dermal sinus can be palpated as a firm cord running from it obliquely down towards the occipital bone for a distance of about 2 cm.

The radiographic appearances of the extra- and intradural dermoid cysts with complete dermal sinus are characteristic. The appearance of the extradural variety has been described with Case 1. It may resemble that of a suboccipital meningocele, although clinical examination should leave little room for confusion, but its main points of difference are (1) that it tends to have a sclerotic margin, and (2) it erodes only the inner bone table and diploe, the outer table being preserved as a thin shell. The small opening for the

dermal sinus, which would be a certain diagnostic feature, cannot as a rule be visualized in this type of case because of its very fine calibre.

The typical feature of the intradural dermoid cyst is that of a short channel leading down to an oval groove. The channel, transmitting the dermal sinus, passes obliquely through the bone and measures from 1 to 1.5 cm. in length and 3 to 6 mm. in width. The groove is on an average 1 cm. wide and 1 to 1.5 cm. long and accommodates the posterior aspect of the dermoid cyst and the expanded inner end of the sinus as it fuses with the tumour.

This radiographic appearance has to be distinguished from other openings in the midline, in particular those associated with a large occipital emissary vein or a suboccipital meningocele. The fundamental point of difference is that the channel and groove of the dermoid lie in the vertical plane and pass obliquely through the bone, so that they tend to be only faintly visible. In the other two conditions the foramina run horizontally backwards, so that a circular opening of varying size is produced, which is clearly punched out of the whole thickness of bone.

Air studies are of little value in ascertaining the presence of an intradural tumour before the onset of septic complications (Cases 4 and 5). The cysts at this stage are small, perhaps 1 to 1.5 cm. in diameter, and are not large enough to deform the aqueduct or fourth ventricle. It is only when the cyst is converted into an abscess many times greater than its original size that the typical deformity of a midline cerebellar expanding lesion is produced. In any event air studies are superfluous because the channel and groove in the occipital bone are irrefutable proof of the presence of the intradural dermoid cyst.

Management.—Problems of management arise only in the case of intradural cysts with complete dermal sinus. Even with this variety there is no great difficulty once septic complications have appeared, for the cyst must be removed as soon as the infection can be brought under control. It is when the condition has been diagnosed before the onset of intracranial infection (Case 5) that difficulties arise.

In our own case in which we performed a prophylactic removal, we had the humbling experience of causing the transfer of organisms from the cyst to the meninges and producing the very complication we were trying to avoid. However, we were able to isolate the infecting organism from the dermoid contents and ascertain its antibiotic sensitivity before the onset of the meningitis and then recog-

nize and treat the meningitis from its earliest stages, with a happy result.

On the other hand the dangers of postponing surgery until the spread of intracranial infection has occurred are well illustrated by Cases 3 and 4. In the former case excision of the tumour was carried out on a child already very sick, the technical removal was difficult owing to inflammatory adhesions, and the patient was critically ill afterwards. In the latter, despite the intensive use of an antibiotic, the meningitis could not be controlled and the child died before removal of the tumour was feasible.

These tumours obviously carry a serious risk whichever line of treatment is adopted; whether it be early excision as a prophylactic against infection, or a removal delayed until intracranial spread of sepsis has occurred. However, although it may seem a drastic procedure to subject an infant or young child to a major intracranial operation when its only apparent disability is a discharging occipital sinus, the occurrence of serious inflammatory complications is inevitable sooner or later, and we believe that removal of the tumour without undue delay once the diagnosis has been made, and before septic complications occur, is the least dangerous method. The contamination of the meninges during the prophylactic excision of these dermoid cysts should not be unavoidable, for it is often possible to remove similar types of tumour from the lumbar portion of the spinal canal without producing meningitis, although it must be conceded that in this latter situation there is a greater tendency for the pia arachnoid to seal off the subarachnoid space round the cyst.

In any event it would probably be safer to anticipate post-operative meningitis, and in a future case we should give a full therapeutic course of the appropriate antibiotic once the organism had been isolated from the dermoid contents, and not wait for the development of meningitis. If it were possible, before operation, to identify the organisms from the discharge from the sinus, it would make for even greater safety.

Although posterior fossa dermoid cysts are uncommon tumours, they seem to occur more frequently than the paucity of recorded cases would suggest, in particular the variety of intradural dermoid with a complete dermal sinus, for the three cases reported here have come to this department in the last three and a half years. It is a condition which should be borne in mind when treating any infant or young child with symptoms of an abscess

in the posterior fossa situated in the midline, or meningitis which is resistant to, or relapses despite adequate treatment, particularly if it is due to the coliform group of organisms.

Summary

A study of 32 cases of posterior fossa dermoid cysts reveals that four clinical types can be recognized depending on their anatomical situation and the presence or absence of an occipital dermal sinus.

The characteristic features of each type and their radiographic appearances are described.

Attention is drawn to the ease with which infection can enter the skull to cause meningitis or an abscess, in particular in the variety of intradural dermoid cyst with a complete dermal sinus.

It is a pleasure to acknowledge our indebtedness to Mr. Wylie McKissock for the records of Cases 1 to 4; to Professor T. Crawford for the pathological report and photomicrograph of the dermoid cyst in Case 1; and to Dr. J. W. D. Bull for many of the radiographs.

REFERENCES

- Belloni, G. B. (1925). *Pensiero med.*, **14**, 254.
 Bender, L. (1925). *Amer. J. Path.*, **1**, 657, 667.
 Brock, S., and Klenke, D. A. (1931). *Bull. neurol. Inst.*, **1**, 328.
 Clairret, M. (1838). *Gaz. Hôp., Paris*, **12**, 166.
 Courville, C. B., and Kimball, T. S. (1936). *Bull. Los Angeles neurol. Soc.*, **1**, 84.
 Downes, R. M. (1929). *J. Coll. Surg. Aust.*, **2**, 268.
 Gladstone, N. H. (1937). *J. Indiana med. Ass.*, **30**, 282.
 Gorog, G. (1927). *Frankfurt. Z. Path.*, **35**, 265.
 Greenfield, J. G. (1932). In "Cytology and Cellular Pathology of the Nervous System," ed. Penfield, W., vol. 3, sect. 29, p. 1221. New York.
 Horrax, G. (1922). *Arch. Neurol. Psychiat., Chicago*, **8**, 265.
 Irvine, J. Pearson (1879). *Trans. path. Soc. Lond.*, **30**, 195.
 Kruse, A. (1891). *Dtsch. med. Wschr.*, **17**, 567.
 Kwan, S. T. (1910). *Arch. Neurol. Psych.*, **24**, 345.
 Lannelongue, J. (1910). *Bull. Acad. Med., Paris*, **63**, 345.
 Love, J. G., and Kernohan, J. W. (1936). *J. Amer. med. Ass.*, **107**, 1876.
 Martin, J., and Davis, L. (1943). *Arch. Neurol. Psychiat., Chicago*, **49**, 56.
 Miller, I. D. (1937). *Aust. N.Z. J. Surgery*, **7**, 74.
 Munro, D. J., and Wegner, W. (1937). *New Engl. J. Med.*, **216**, 273.
 Quade, R. H., and Craig, W. McK. (1939). *Proc. Mayo Clin.*, **14**, 459.
 Rand, C. W., and Reeves, D. L. (1943). *Arch. Surg. Chicago*, **46**, 350.
 Ruschhaupt, E. (1903). *Zbl. allg. Path. path. Anat.*, **14**, 945.
 Sweet, W. H. (1940). *Dis. Nerv. System*, **1**, 228.
 Todesco, J. (1927). *Lancet*, **2**, 366.
 Verbiest, H., and Zeldenrust, J. (1938). *Nervenarzt*, **11**, 366.
 Webster, R. (1938). *Med. J. Aust.*, **2**, 561.