

SPINAL MENINGITIS DUE TO *ACTINOMYCES BOVIS* TREATED WITH PENICILLIN AND STREPTOMYCIN

BY

COLIN EDWARDS, W. A. ELLIOTT, and KEITH J. RANDALL

From St. Alfege's Hospital, Greenwich

The involvement of the central nervous system by actinomycosis is rare. Ford stated in 1937: "There are 40 cases on record in which the nervous system has been invaded. All reported cases have been fatal; no treatment is of any value". Later Friedman and Levy (1937), in an extensive review of the literature, found 108 cases of actinomycotic involvement of the central nervous system. Treatment was symptomatic and the cases were "invariably fatal". Eckhoff (1941) has added two further cases to the literature.

The advent of antibiotics has greatly changed the prognosis of all varieties of actinomycosis. Cures with penicillin were reported in 1944 by Christie and Garrod, Wollgast, Herrell, and by many others since then. However, none of these writers reported on the treatment of a case where the disease invaded the central nervous system, and it was not until 1948 that Jacobson and Cloward described the cure of a patient with actinomycotic meningitis with sulphonamides, penicillin and streptomycin. Schneider and Rand (1949) later reported the recovery of a patient with an actinomycotic brain abscess treated by complete excision and antibiotics.

Actinomycosis of the nervous system may arise in one of three ways: (1) primary, (2) by direct extension, and (3) by metastasis. Most authors think that "primary" cases are those in which the original focus is healed or has remained undiscovered, and Cope (1938) drew attention to six cases in which an actinomycoma was discovered in the third ventricle. By direct extension the organism travels from lesions in the air sinuses, ear, pharynx, face, and the jaws. Spread is along the connective tissue planes but may occur through the bone. By the third route, the metastatic, the organism most commonly reaches the nervous system through the blood stream from other foci in the body, especially the lungs.

Friedman and Levy stated that in the 108 cases collected by them the distribution of origins were

metastatic (bloodborne) 63 cases, direct extension 23 cases, and primary 23 cases.

We report below a case of actinomycotic meningitis cured by antibiotics which is of particular interest, first, because the disease remained localized to the spinal meninges and, secondly, because it is probably of the primary type, no other focus having been discovered despite careful search.

Case History

V.R., a woman aged 26 years, attended the Dental Department with pain in the right ear and trismus. Caries of the right lower seventh and eighth teeth was found. She was referred to the Medical Out-Patient Department on March 15, 1950, with a history of two months' dyspnoea on exertion, but no other relevant symptoms. There was a history of pleurisy two years previously. Examination showed pallor of the mucous membranes. Blood pressure was 120/70 mm. Hg. The nails were flat, no glands were felt, and there were no other relevant physical signs. Haemoglobin was 50% (Haldane), the red cell count 3.92 million, the colour index 0.64.

The patient was admitted to hospital and the haemoglobin was found to have fallen to 40%. A fractional test meal showed a low acid curve; there was no occult blood in the stools. She was transfused with 2 pints of blood, given iron by mouth, and the lower right seventh and eighth teeth were removed under endotracheal anaesthesia. The crowns were very carious but no sinuses were present and the sockets healed normally. She was discharged on April 15 when the haemoglobin was 80%.

On April 23, 1950, the patient attended again complaining of severe pain in both buttocks and the back of the legs for the previous five days. There was tenderness over the right sciatic nerve only. A radiograph of the lumbar spine was normal. She was re-admitted on April 28 when the pain was more severe and was keeping her awake at night. In hospital the pain spread to the back and hypochondrium. The sedimentation rate on May 5 was 41 mm. in one hour, and on the following day she began to vomit and pain became severe in the neck and the whole of the spine; neck rigidity and a positive Kernig sign developed. On May 11 there was

marked head retraction and opisthotonos but headache was only slight. The patient remained lucid but there was a rise of temperature and the blood white cell count was 28,000 per c.mm. with 89% of polymorphonuclears. Intramuscular injection of penicillin and streptomycin

cerebrospinal fluid (7 lymphocytes and 3 polymorphonuclears per ml.; protein 25 mg. per 100 ml.; sugar 60 mg.; and chlorides 730 mg. per 100 ml.).

The patient was discharged to a convalescent home on July 25, and attended as an out-patient on August 25 when, apart from slight neck rigidity, she was quite well. Radiographs of the spine, jaws, sacrum, skull, and chest taken in hospital had shown no disease.

Bacteriology.—Gram films of the original pus showed many pleomorphic Gram-positive filaments of varying length and staining, branching, and having many coccoid forms some with clubbed ends.

Aerobic cultures were all sterile. Anaerobic cultures in glucose broth produced granules, and visible small dry, white, wrinkled colonies were seen on glucose agar in four to five days. Glucose, maltose, mannite, saccharose, and lactose were fermented with the production of acid but not gas. A glucose broth culture was inoculated into four guinea-pigs which were killed at intervals of three to eight weeks. No disease was seen in any of the animals but it is known to be difficult to produce the disease in animals.

As a result of these reactions we concluded that the organism was *Actinomyces bovis*. It was completely inhibited by a penicillin concentration of 2 units per ml.

Discussion

The fact that 12 lumbar punctures yielded no cerebrospinal fluid, and pus on two occasions only, clearly indicates a complete spinal block.

It might be contended that the infection was entirely extradural, but it is unlikely that it could spread from the lumbar to the cervical region without any sign of extension outside the spinal canal.

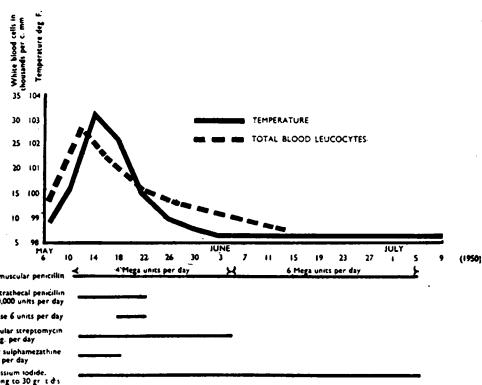


FIG. 1.—Chart showing response of temperature and leucocytes to treatment.

was begun (Fig. 1). On May 12, 5 ml. of thick pus was withdrawn at the third attempt to do a lumbar puncture. A stained film showed many pleomorphic Gram-positive filaments, some with clubbed ends (Fig. 2). A course of intrathecal penicillin was begun. A little more pus was withdrawn by lumbar puncture on May 13, - but, although daily lumbar puncture was performed for eight days, no further fluid was obtained, so intrathecal therapy was abandoned on May 22.

From the beginning of treatment the temperature began to settle, while the neck rigidity and pain in the back lessened. A left external rectus palsy appeared on May 14, and lasted for eight days.

Following the onset of headache and mental confusion a trephine and right ventricular puncture was performed on June 2. The cerebrospinal fluid withdrawn showed 8 lymphocytes per c.mm. and 15 mg. of protein per 100 ml. Globulin was not increased. Chlorides were 720 mg. per 100 ml. Later there was urinary incontinence for seven to ten days but otherwise recovery was uninterrupted. A further attempt at lumbar puncture on June 16 again yielded no fluid, but cisternal puncture on June 22 yielded a practically normal

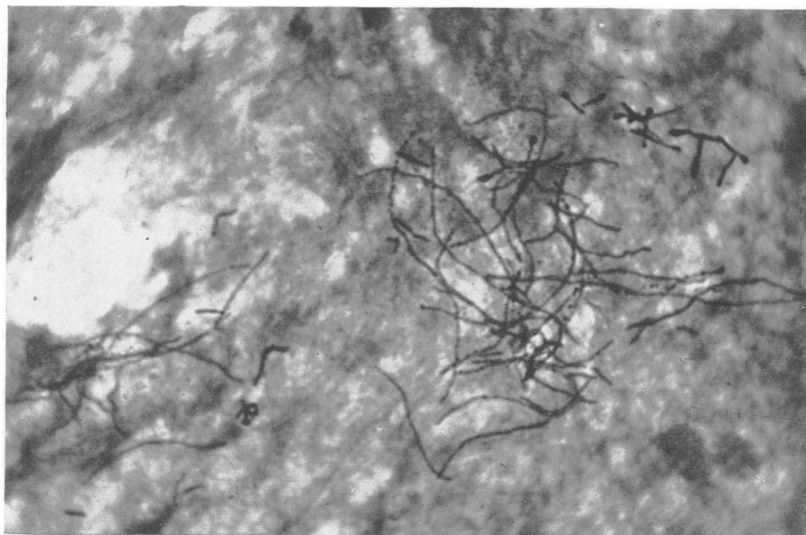


FIG. 2.—Microphotograph of stained film of pus withdrawn from theca at lumbar puncture. × 800

Both the ventricular and cisternal fluids examined showed only a slight increase in cells indicating that the coagulative nature of the exudate was responsible for limiting this disease to the spinal leptomeninges. It must have reached the upper cervical region to have produced such marked head retraction. Here the present case differs from that of Jacobson and Cloward where the cranial cavity was also involved. The transient sixth nerve palsy in our case can be explained on mechanical grounds. It is not infrequently seen in the absence of infection, for example, after lumbar puncture.

Despite careful radiological examination no primary bony focus was discovered in either jaw or vertebrae. Nevertheless it is tempting to associate the dental extraction on April 5 with the onset of symptoms 18 days later. Is it possible that the organism was present in the mouth and reached the meninges by blood-borne embolism following the extraction? Okell and Elliott (1945) demonstrated that in no less than 75% of patients positive blood cultures were found a few minutes after dental extraction. These were usually *Str. viridans* but occasionally other mouth bacteria were isolated, and it seems reasonable to suggest that this was the portal of entry for the actinomycetes. Mackie and McCartney (1945) state that "there is a considerable amount of evidence that the actinomycetes sometimes occurs as a commensal in the mouth".

Summary

The literature on actinomycotic meningitis is reviewed and a case of meningitis, limited to the spinal region, is described. It was treated and cured by penicillin and streptomycin.

We wish to acknowledge our thanks to Mr. J. Salem, Consulting Dental Surgeon at St. Alfege's Hospital; to Dr. C. K. MacDonald for advice on the bacteriological investigations, and to Mr. J. J. Puxley for technical assistance; to Mr. J. E. Andrews, F.I.B.P., of the Southern Group Laboratory for the microphotograph and, finally, to the nursing staff of St. Alfege's Hospital for their considerable assistance in the treatment of this case.

REFERENCES

- Christie, R. V., and Garrod, L. P. (1944). *Brit. med. J.*, **1**, 513.
 Cope, Z. (1938). "Actinomycosis." London.
 Eckhoff, N. L. (1941). *Lancet*, **1**, 7.
 Ford, F. R. (1937). "Diseases of the Nervous System in Infancy, Childhood and Adolescence." London.
 Friedman, E. D., and Levy, H. H. (1937). *Int. Clin.*, **47** ser., **2**, 36.
 Herrell, W. E. (1944). *J. Amer. med. Ass.*, **124**, 622.
 Jacobson, J. R., and Cloward, R. D. (1948). *Ibid.*, **137**, 769.
 Mackie, T. J., and McCartney, J. E. (1945). "Handbook of Practical Bacteriology", 7th ed. Edinburgh.
 Okell, C. C., and Elliott, S. D. (1935). *Lancet*, **2**, 869.
 Schneider, R. C., and Rand, R. W. (1949). *J. Neurosurg.*, **6**, 255.
 Wollgast, C. F. (1944). *Tex. J. Med.*, **40**, 225.

