

CASE REPORT

 OPEN ACCESS

## Disseminated sporotrichosis in an immunocompetent patient

Kareem Hassan<sup>a</sup>, Tolga Turker<sup>b</sup> and Tirdad Zangeneh<sup>c</sup>

<sup>a</sup>Division of Plastic and Reconstructive Surgery, Department of Surgery, The University of Chicago, Chicago, IL, USA; <sup>b</sup>Department of Orthopaedic Surgery, The University of Arizona, Tucson, AZ, USA; <sup>c</sup>Division of Infectious Diseases, Department of Medicine, Tucson, AZ, USA

### ABSTRACT

*Sporothrix schenckii*, the causative agent of sporotrichosis, is a relatively rare infection. Local infection usually occurs through direct inoculation of the organism through the skin; disseminated disease is rarely seen. This article describes a case of disseminated sporotrichosis in a middle-aged man without the commonly seen risk factors for dissemination.

### ARTICLE HISTORY

Received 22 February 2016  
Accepted 17 March 2016

### KEYWORDS

Sporotrichosis; disseminated; hand; pulmonary; ocular; lymphocutaneous; rose gardener's disease; *Sporothrix schenckii*

### Introduction

*Sporothrix schenckii*, the causative agent of sporotrichosis, is a relatively rare infection seen mainly in farmers, gardeners and carpenters. Infection usually occurs when either a contaminated thorn or a splinter directly inoculate the organism through the skin. Sporotrichosis is most frequently encountered as a localized infection of the hand, and disseminated disease is rarely seen. Reported cases of disseminated sporotrichosis to date have been in those with immunosuppression from organ transplantation or human immunodeficiency virus (HIV). This article describes a case of disseminated sporotrichosis in a middle-aged man without the commonly seen risk factors for dissemination with the exception of uncontrolled diabetes and alcoholism.



### Case report

A 56-year-old male farmer was presented to the emergency department (ED) complaining of right hand discomfort, pain and swelling of 2 days duration. The patient did not report any history of recent trauma. His past medical history was significant for alcoholism and insulin-dependent type 2 diabetes. The right hand demonstrated marked swelling, fluctuation, erythema and associated lymphangitis tracking to the volar aspect of the right forearm. His hand and forearm

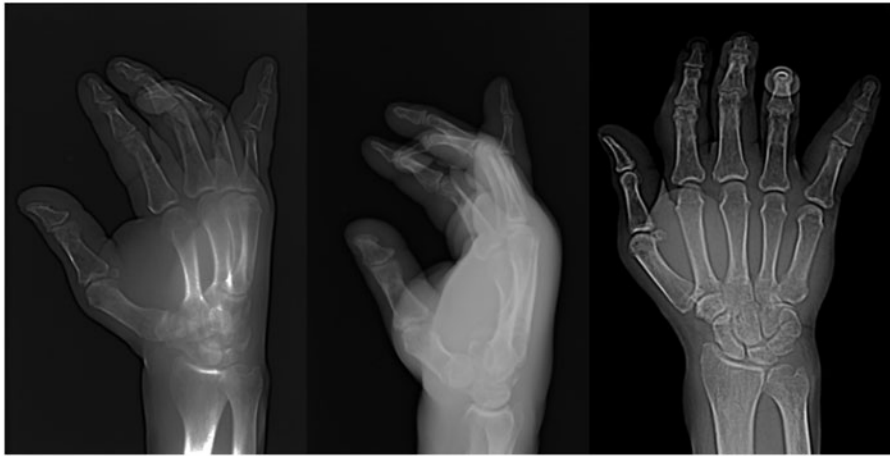
radiographs were significant for soft tissue edema (Figure 1). His comprehensive blood work was significant only for an elevated glucose level, however, other signs of infection, including erythrocyte sedimentation rate and C-reactive protein, were absent from laboratory testing.

A localized soft tissue abscess of the right hand was considered and the patient was taken to the operating room for incision and drainage. An abscess involving the middle phalanx of the 5th finger extending to the mid-forearm was incised and drained. Patient was initially administered piperacillin/tazobactam postoperatively. *Streptococcus pneumoniae*, *Klebsiella oxytoca*, *Pseudomonas aeruginosa* and coagulase negative Staphylococcus were identified in the wound cultures that were obtained during the operation. Blood cultures also grew *Streptococcus pneumoniae*. Despite antibiotic therapy and surgical debridement, the infection progressed to involve the entire fifth digit and amputation of the digit was performed on post-operative day 4.

Despite medical and surgical treatment, the purulent infection progressed and wound cultures confirmed *Sporothrix schenckii*. The patient was then started on itraconazole after culture results confirmed the organism. During the course of treatment and follow-up, the patient continued to experience right

**CONTACT** Kareem Hassan  keem@email.arizona.edu  Division of Plastic and Reconstructive Surgery, Department of Surgery, The University of Chicago, 5841 S. Maryland Ave, Rm. J-641, MC6035, Chicago, IL 60637, USA

© 2016 The Author(s). Published by Taylor & Francis. This is an Open Access article distributed under the terms of the Creative Commons Attribution-NonCommercial License (<http://creativecommons.org/licenses/by-nc/4.0/>), which permits unrestricted non-commercial use, distribution, and reproduction in any medium, provided the original work is properly cited.



**Figure 1.** Hand X-ray showing extensive soft tissue edema of the right hand.

index finger swelling for several weeks. The patient was seen in the outpatient clinic and completed 3 months of therapy. There was no reason to suspect non-compliance in this patient at this time.

Ten months following the course of his treatment, he returned to the ED with complaints of bilateral knee pain, swelling and weight loss. He reported a loss of his insurance and a lack of access to insulin for 4 months. His vital signs were within the normal range and exam findings were notable for 2+ pitting edema and effusions involving bilateral wrists, fingers and knees. An indurated poorly defined 3-cm mass was found in the right popliteal fossa. Significant laboratory values from a complete blood count and comprehensive metabolic panel were glucose 636 mg/dl, C-reactive protein 1.5 mg/dl, white blood cell count 1400 cells/ $\mu$ l and absolute neutrophil count 890 cells/ $\mu$ l. CT scan of the chest, abdomen and pelvis in the ED demonstrated splenomegaly and diskitis involving L4 and L5. The patient was found to have leukopenia but all laboratory tests for the differential causes of polyarthritides were found to be negative including: Antinuclear antibodies (AB), Rheumatoid factor, Anti-citrullinated protein AB, Anti-Ro AB, Anti-La AB, Anti-DNA AB, Serum Protein Electrophoresis, Urine Protein Electrophoresis, Beta-2-microglobulin, Peripheral Smear, Lactate Dehydrogenase, Human Immunodeficiency virus AB, Thyroid Stimulating Hormone and Parvovirus B19 serology. Subsequent bone marrow aspiration indicated only pancytopenia and negative potassium hydroxide preparations and cultures for fungi. CT-guided biopsy of the lumbar spine was performed demonstrating 1+ WBCs but without evidence of organisms, including fungi, through both cultures and staining. Subsequent left hand debridement, right elbow olecranon bursectomy, bilateral open

debridement and synovectomy of bilateral knee joints, and removal of left knee mass were performed to evaluate the swelling and pain each location. Cultures from the right elbow and left finger grew *Sporothrix schenckii*. The patient was started on 3 mg/kg daily dosing of liposomal amphotericin B following the first confirmation of repeat sporotrichosis infection.

In addition to the soft tissue, joint and bone infection with sporotrichosis, pulmonary and ophthalmologic complications also developed during the hospitalization. After 2 weeks into the hospitalization, the patient began to complain about decreased visual acuity of the left eye; ophthalmology was consulted and full examination revealed panuveitis with posterior synechiae. There was concern for endogenous endophthalmitis of the eye, and the patient was taken to the operating room for vitrectomy and posterior synecholysis of the left eye. Perioperatively, a 12 mm  $\times$  9 mm retinal choroidal infiltrate was found, consistent with fungal infection. Cultures, polymerase chain reaction (PCR) and cytology of the vitreous fluid demonstrated not diagnostic which may have been due to the patient having received amphotericin. Additionally, the patient developed epistaxis with hemoptysis, and CT scan demonstrated scattered ground glass opacities throughout the lungs with bilateral pleural effusions, consistent with an infectious process. Thoracocentesis was performed and cultures of the pleural fluid were non-diagnostic. However, the patient continued to improve clinically while receiving liposomal amphotericin.

The patient was discharged following clinical improvement of his conditions,  $\sim$ 1 month of hospitalization at the time of discharge on oral itraconazole. Despite close follow-up instructions, the patient did not return to clinic and was lost to follow-up.

## Discussion

This article presents a case of disseminated sporotrichosis infection in an immunocompetent host. The vast majority (70–80%) of sporotrichosis infections involve the lymphocutaneous system.[1,2] Joint involvement including the wrist, elbow, ankle and knee is the second most common site of infection.[3] Dissemination is rare, making up ~1% of all cases in most case series.[4–6] Dissemination occurs through hematogenous spread or direct inhalation of conidia in those infected with HIV. Reports of systemic disease in patients who have relative immunosuppression, such as those with diabetes and alcoholism, are scarce.[1,7] This patient suffered from both diabetes and alcohol dependence which likely facilitated the systemic involvement, making this case especially unusual given the lack of usual risk factors. Recent outbreaks have been reported in South America, particularly in Brazil, where the epidemics have been tied to exposure to feline hosts.[8]

In our case, disseminated disease was suspected since the patient had involvement of multiple sites. Although, culture results did not indicate growth of *Sporothrix schenckii* from several sites – including the lumbar spine, pleural fluid and the choroid of the eye – one can speculate that treatment with amphotericin could have led to the negative cultures. The negative cultures can also be attributed to the difficulty in obtaining an adequate sample.[9] Additionally, the diagnostic yield of fungal cultures has been reported to be as low as 1.4%; in one study, microorganism pleural fluid culture was positive in only 33% of patients with infectious pathology.[10,11] Biopsy and preparation with Grocott's methenamine silver (GMS) or Periodic Acid-Schiff (PAS) can be performed in cases where fungal etiology is suspected which will reveal budding yeast, however this relies strongly on the experience of the reader. While culture remains the gold standard for diagnosis of sporothrix infection, it remains a slow test, also requiring an experienced microbiologist for proper identification and diagnosis. For this reason, several molecular assays are currently under investigation for the diagnosis of sporothrix infection. While the use of PCR has been successfully applied to a case of disseminated cutaneous sporotrichosis, to date, none of the assays have received widespread adoption.[12] Ultimately, until alternatives to culture emerge as reliable alternatives, the clinical judgment of the physician is necessary in diagnosis fungal infections. Pathologic identification of biopsy specimens can reveal the diagnosis if the characteristic

cigar-shaped yeast are seen, but like culture the yield is not high.[3] In our patient, clinical improvement with antifungal therapy resulting in resolution of infection from these various sites may confirm the possibility of disseminated disease. The patient had been unable to work following his first infection, thus, ruling out the possibility of repeated inoculation.

Traditionally, saturated solutions of potassium iodide have been utilized in the treatment of sporotrichosis with generally good results.[13] However, the use of potassium iodide has never been validated through a clinical trial, nor has its mechanism of action been properly elucidated.[14] Itraconazole has become the mainstay of treatment of cutaneous and lymphocutaneous sporotrichosis, demonstrating >90% efficacy in treating the infection.[15,16] The typical dose of itraconazole is 200 mg daily or twice daily depending on the site of infection for 3–6 months, unless the treatment is for a relapse or there is involvement of tissue other than the skin or lymph, in which case 12 months of treatment is recommended. In immunosuppressed individuals, or in patients with chronic infections, 200 mg of daily itraconazole may be used for lifelong suppression at the clinician's discretion. Voriconazole and other newer -azole agents have not demonstrated sufficient efficacy at this time to be recommended as a standard treatment.[17] In cases where therapy fails, some research shows that terbinafine at doses of 1000 mg each day may be used.[3]

While itraconazole levels were not checked in this patient, drug levels can be monitored through commercially available laboratory tests if there are concerns for low bioavailability in the setting of immunosuppression, compliance or toxicity of the drug. In this case, concerns regarding compliance may have been alleviated by serum monitoring. Furthermore, in a long-term follow-up study of patients infected with sporothrix, it was found that 25 of 30 people responded to therapy, however 7 of the 25 responders relapsed despite long-term treatment.[18] While relapses can be treated with a repeated course of itraconazole, if infection is deemed life threatening, as was this case in this patient, liposomal amphotericin B at a dose of 3–5 mg/kg daily is the recommended treatment in order to induce remission, followed by oral itraconazole therapy for a total of 12 months.[19] In disseminated disease – especially with brain or meningeal involvement – 5-fluorocytosine may be added to the amphotericin regimen.[3] Drug sensitivity tests were performed on isolates from this patient; however, at this time agreement between different testing

methods and definitions of mean inhibitory concentrations are not widely available.[20]

Disseminated sporotrichosis can be a difficult disease to diagnose and treat. Education is paramount to the identification of the illness at presentation. This case highlights the difficulty in culturing the fungus and confirming the diagnosis through laboratory analysis and the importance of a thorough history and physical exam. Relapse of the infection, as seen in this case, is not a rare occurrence, and therefore serious infections require strict follow-up.

### Disclosure statement

The authors report no conflicts of interest. The authors alone are responsible for the content and writing of this article.

### References

- [1] Werner AH, Werner BE. Sporotrichosis in man and animal. *Int J Dermatol*. 1994;33:692–700.
- [2] Everett MA. Atypical sporotrichosis. *J Okla State Med Assoc*. 1963;56:483–486.
- [3] Mandell GL, Bennett JE, Dolin R. Mandell, Douglas, and Bennett's principles and practice of infectious diseases e-book. Elsevier Health Sciences; 2009.
- [4] Itoh M, Okamoto S, Kariya H. Survey of 200 cases of sporotrichosis. *Dermatologica*. 1986;172:209–213.
- [5] Da Rosa ACM, Scroferneker ML, Vettorato R, et al. Epidemiology of sporotrichosis: a study of 304 cases in Brazil. *J Am Acad Dermatol*. 2005;52:451–459.
- [6] Pappas PG, Tellez I, Deep AE, et al. Sporotrichosis in Peru: description of an area of hyperendemicity. *Clin Infect Dis*. 2000;30:65–70.
- [7] Fonseca-Reyes S, López Maldonado FJ, Miranda-Ackerman RC, et al. Extracutaneous sporotrichosis in a patient with liver cirrhosis. *Rev Iberoam Micol*. 2007;24:41–43.
- [8] Barros MB de L, Schubach A de O, do Valle ACF, et al. Cat-transmitted sporotrichosis epidemic in Rio de Janeiro, Brazil: description of a series of cases. *Clin Infect Dis*. 2004;38:529–535.
- [9] Hoog GS, de Vitale RG. Bipolaris, exophiala, scedosporium, sporothrix, and other dematiaceous fungi. In: Murray PR, Baron EJ, Jorgensen JH, et al., editors. *Book manual of clinical microbiology*. Vol. 2. Washington: ASM Press; 2006. p. 1898–1917.
- [10] Barnes TW, Olson EJ, Morgenthaler TI, et al. Low yield of microbiologic studies on pleural fluid specimens. *Chest*. 2005;127:916–921.
- [11] Ferrer A, Osset J, Alegre J, et al. Prospective clinical and microbiological study of pleural effusions. *Eur J Clin Microbiol Infect Dis*. 1999;18:237–241.
- [12] Fujii H, Tanioka M, Yonezawa M, et al. A case of atypical sporotrichosis with multifocal cutaneous ulcers. *Clin Exp Dermatol*. 2008;33:135–138.
- [13] De Beurmann L, Gougerot H. Les sporotrichoses hypodermiques. *Ann Derm Syph (Paris)*. 1906;4:837–864.
- [14] Rippon JW. *Medical mycology; the pathogenic fungi and the pathogenic actinomycetes*. Eastbourne: WB Saunders Company; 1982.
- [15] De Lima Barros MB, Schubach AO, de Vasconcellos Carvalhaes de Oliveira R, et al. Treatment of cutaneous sporotrichosis with itraconazole – study of 645 patients. *Clin Infect Dis*. 2011;52:e200–e206.
- [16] Kauffman CA. Old and new therapies for sporotrichosis. *Clin Infect Dis*. 1995;21:981–985.
- [17] McGinnis MR, Nordoff N, Li RK, et al. Sporothrix schenckii sensitivity to voriconazole, itraconazole and amphotericin B. *Med Mycol*. 2001;39:369–371.
- [18] Sharkey-Mathis PK, Kauffman CA, Graybill JR, et al. Treatment of sporotrichosis with itraconazole. NIAID Mycoses Study Group. *Am J Med*. 1993;95:279–285.
- [19] Kauffman CA, Bustamante B, Chapman SW, et al. Clinical practice guidelines for the management of sporotrichosis: 2007 update by the Infectious Diseases Society of America. *Clin Infect Dis*. 2007;45:1255–1265.
- [20] Alvarado-Ramírez E, Torres-Rodríguez JM. In vitro susceptibility of Sporothrix schenckii to six antifungal agents determined using three different methods. *Antimicrob Agents Chemother*. 2007;51:2420–2423.