

tion.^{1 3 4} These factors were used successfully to restore the acid fastness of *M leprae* and *M tuberculosis* in epoxy resin sections.

It must be emphasised that the method described must be followed accurately. If this is done the results are both reliable and consistent.

J Kan and J Holzl provided excellent technical help.

References

- ¹ Brassil KE. Demonstration of Mycobacterium tuberculosis in epoxy resin sections by the Ziehl-Neelsen technique. *J Clin Pathol* 1985;38:110-1.
- ² Drury RAB, Wallington EA. *Carleton's histological technique*. 5th ed. Oxford: Oxford University Press, 1980.
- ³ Nyka W. Studies on Mycobacterium tuberculosis in lesions of the human lung. A new method of staining tubercle bacilli in tissue sections. *Am Rev Resp Dis* 1963;88:670-9.
- ⁴ Nyka W. Method for staining both acid-fast and chromophobic tubercle bacilli with carbolfuchsin. *J Bacteriol* 1967;93:1458-60.

Requests for reprints to: KE Brassil, Department of Histopathology, Repatriation General Hospital, Greenslopes, Queensland, Australia.

Detection of *Campylobacter pyloridis* in gastric mucosa by phase contrast microscopy

KEITEE J PINKARD,* B HARRISON,* JA CAPSTICK,* G MEDLEY,† JR LAMBERT.‡ *From the Departments of *Microbiology, †Anatomical Pathology, and ‡Medicine, Prince Henry's Hospital, Melbourne, Victoria, Australia*

Curved bacteria were recently detected in gastric biopsy specimens using histological stains.¹⁻³ Marshall and Warren established methods for the isolation of these bacteria and described their *Campylobacter* like properties⁴: they proposed the name *Campylobacter pyloridis* and postulated an aetiological role for these bacteria in gastritis and peptic ulceration. Subsequently, some workers found culture more sensitive than histological stains for detecting *C pyloridis*,^{5 6} whereas others achieved a higher detection rate with the Warthin-Starry silver stain.^{7 8} We used phase contrast microscopy for the direct examination of gastric antral biopsy specimens for these curved bacteria and compared it with the above mentioned methods.

Accepted for publication 2 October 1985

Material and methods

Gastric biopsy specimens were obtained from consecutive patients undergoing routine upper gastrointestinal endoscopy. Informed consent was obtained from all subjects. Three endoscopic biopsy samples were obtained from the antral mucosa within a 5 cm radius of the pylorus.

MICROSCOPY AND CULTURE

Two biopsy specimens were collected in 0.25 ml sterile saline (0.85%) for transport to the laboratory and were processed within three hours. They were minced finely in two drops of saline and about a quarter of this homogenate was pressed firmly between two glass microscope slides. One slide was stained with Gram stain using 0.2% carbol fuchsin as counterstain. A coverslip was placed over the other slide, which was then examined under phase contrast ($\times 400$ magnification).

The rest of the sample was cultured on chocolate (horse) blood agar (Columbia agar, Oxoid CM331) and on brain heart infusion agar (Oxoid CM375) supplemented with 7% horse blood, 3 $\mu\text{g}/\text{lm}$ vancomycin, 50 $\mu\text{g}/\text{ml}$ nalidixic acid, and 5 $\mu\text{g}/\text{ml}$ trimethoprim. The plates were incubated at 37°C for up to six days in a humid atmosphere of 5% oxygen, 10% carbon dioxide and 85% nitrogen.

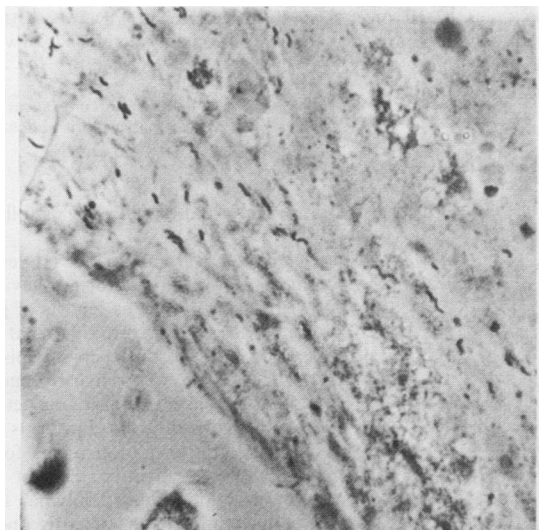
Isolates were considered to be *C pyloridis* if they grew as 1-2 mm translucent greyish colonies after three days on chocolate agar, were Gram negative, curved or S shaped rods which became coccoid in older cultures, and were positive for oxidase and catalase, as described by Marshall and Warren.⁴ Further tests were done using brucella broth (BBL 11088) containing 0.16% agar and 5% normal horse serum as basal medium. Tests were incubated as above for 10 days.

HISTOLOGY

The third biopsy specimen was fixed in 10% phosphate buffered neutral formalin and 4-5 μm sections stained by the Warthin-Starry method.⁹ The three microscopic methods were assessed blindly by independent observers.

Results

Under phase contrast microscopy *C pyloridis* appeared as characteristic black, well defined, curved or S shaped rods, 2-3 μm long, lying in close association with the mucus and epithelial cell layer (Figure). This morphology was retained for at least five hours in preparations kept in a moist chamber at room temperature.



Curved bacteria in gastric antral biopsy specimen (Phase contrast microscopy).

Using Warthin-Starry silver stain, the bacteria were readily differentiated from debris. They were present as clumps or diffusely spread on the luminal surface of inflamed gastric antral epithelium and were often seen in the necks and crypts of gastric glands.

C. pyloridis was isolated from forty four biopsy specimens, and sixteen isolates were characterised further. They grew at 37°C, but not at 25°C or 43°C, and in 10% carbon dioxide in air but not aerobically or anaerobically. They did not reduce nitrate to nitrite, produce acid from glucose, hydrolyse hippurate, or grow in 1% glycine, 2% sodium chloride, or on Kligler iron agar. Fifteen isolates out of the 16 tested required serum for growth.

Seventy biopsy specimens from 65 patients were examined by Warthin-Starry silver stain, Gram stain, culture, and phase contact microscopy. *C. pyloridis* was detected in 48 specimens: 48 were positive by silver stain and phase contact microscopy and 44 by Gram stain and culture. The 22 other specimens were negative by all four methods (Table). When *C. pyloridis* was detected by phase contact microscopy

Table Detection of *C. pyloridis* in gastric antral biopsy specimens

No of biopsy specimens	Silver stain	Phase contact microscopy	Gram stain	Culture
40	+	+	+	+
4	+	+	+	-
4	+	+	-	+
22	-	-	-	-

but not by Gram stain, usually one patch of a few organisms was seen. In the four cases in which the organisms were detected microscopically but not isolated there was a heavy overgrowth of contaminating flora.

Discussion

This study showed that, compared with the Warthin-Starry silver stain, direct examination of gastric antral biopsy specimens by phase contrast microscopy detected 100% of *C. pyloridis* whereas Gram stain or culture each detected 92%. The correlation between histological stain, Gram stain, and culture compares favourably with other reported findings.⁵⁻⁸

Although phase contrast is not usually considered to be applicable to biopsy tissue, this report indicates its value as a rapid, reliable method for detecting *C. pyloridis* in human gastric antral mucosa. As a result of this study phase contact microscopy has now replaced the Gram stain in the initial screening stage for *C. pyloridis*. Moreover, the degree of accuracy permits early therapeutic intervention, if indicated.

References

- Steer HW, Colin-Jones DG. Mucosal changes in gastric ulceration and their response to carbenoxolone sodium. *Gut* 1975;16:590-7.
- Warren JR. Unidentified curved bacilli on gastric epithelium in active chronic gastritis. *Lancet* 1983;i:1273.
- Rollason TP, Stone J, Rhodes JM. Spiral organisms in endoscopic biopsies of the human stomach. *J Clin Pathol* 1984;37:23-6.
- Marshall BJ, Warren JR. Unidentified curved bacilli in the stomach of patients with gastritis and peptic ulceration. *Lancet* 1984;i:1311-5.
- Jones DM, Lessels AM, Eldridge J. Campylobacter like organisms on the gastric mucosa: culture, histological, and serological studies. *J Clin Pathol* 1984;37:1002-6.
- Langenberg ML, Tytgat GNJ, Schipper MEI, Rietra PJGM, Zanen HC. Campylobacter-like organisms in the stomach of patients and healthy individuals. *Lancet* 1984;i:1348.
- McNulty CAM, Watson DM. Spiral bacteria of the gastric antrum. *Lancet* 1984;i:1068-9.
- Marshall BJ, McGeachie DB, Rogers PA, Clancy RJ. Pyloric campylobacter infection and gastroduodenal disease. *Med J Aust* 1985;142:439-44.
- Drury RAB, Wallington EA. *Carleton's histological technique*. 4th ed. Oxford University Press: New York, 1967.

Requests for reprints to: Miss KJ Pinkard, Microbiology Department, Prince Henry's Hospital, Melbourne, Victoria, Australia 3004.