

Immunocytochemical expression of tissue specific transcription factor-1 in lung carcinoma

C Di Loreto, V Di Lauro, F Puglisi, G Damante, D Fabbro, C A Beltrami

Abstract

Aims—To investigate the immunocytochemical expression of the tissue specific transcription factor-1 (TTF-1) on cytological specimens of small cell lung carcinoma (SCLC) and to establish its value in the cytological diagnosis of lung cancer.

Methods—For each case, the diagnosis was made on cytological specimens and confirmed on subsequent bronchial biopsy specimens. TTF-1 was detected immunocytochemically using the avidin-biotin complex technique with a rabbit antiserum. Expression of TTF-1 was evaluated in 41 cases of SCLC and 17 cases of non-small cell carcinoma (NSCC). The latter were subdivided into eight cases of adenocarcinomas and nine cases of squamous cell carcinomas (SCC).

Results—Positive nuclear immunoreactivity to TTF-1 was identified in 38 (92.7%) of the 41 cases of SCLC, in five (62.5%) of eight cases of adenocarcinoma, and one (11%) of nine cases of SCC. A significant difference was observed between the two main groups, SCLC and NSCC. A comparison between SCLC and adenocarcinoma and SCC showed that TTF-1 expression was significantly different. TTF-1 immunoreactivity was not detected in the inflammatory cells of the same cases.

Conclusions—TTF-1 is strictly associated with SCLC; it was weakly expressed in the various subtypes of NSCC. Although TTF-1 is not specific for SCLC, it can be used to highlight neoplastic cells to good effect when a large inflammatory component is present, and to differentiate SCLC from lymphoid infiltrates.

(*J Clin Pathol* 1997;50:30-32)

tic agents.² Therefore, oncologists need to define tumour type accurately, a task often requiring the use of cytology.

Tissue specific transcription factor-1 (TTF-1) is expressed by epithelial cells of thyroid, lung, and, during development, by some areas of the brain.³ TTF-1 can be detected immunohistochemically in human fetal lung as early as 11 weeks of gestation, being localised in the nuclei of epithelial cells of the developing airways. After birth, TTF-1 is selectively expressed in type II alveolar cells and in a subset of bronchiolar epithelial cells of the lung.⁴ TTF-1 activates the transcription of thyroglobulin and thyroperoxidase genes in follicular thyroid cells and the transcription of the surfactant protein genes in alveolar cells.⁵ A recent study reported that TTF-1 is immunohistochemically expressed in SCLC.⁶ The present study investigates the potential use of TTF-1 immunostaining to improve the value of cytology in the diagnosis of SCLC.

Methods

Fifty eight samples of bronchial cytology from 58 patients (mean age, 65.6 years, range 49-93; male:female ratio, 2.6:1) collected from the files of the Institute of Anatomic Pathology, University of Udine, Italy, were studied. For each case, the diagnosis was made on bronchial cytological material and confirmed on the corresponding biopsy specimens. A total of 41 cases of SCLC, eight cases of adenocarcinoma, and nine cases of squamous cell carcinoma (SCC) were evaluated for TTF-1 immunocytochemical expression. Routinely processed paraffin wax sections from four representative cases of normal lung tissue were also used as controls.

The cytological material was processed for microscopic examination using a cell block technique.⁷ The sputum and bronchial lavage specimens were fixed in 70% alcohol for 12-24 hours and routinely embedded in paraffin wax. Multiple sections, 5 µm thick, were obtained for each case and stained with haematoxylin and eosin for microscopic examination. According to the WHO classification,⁸ SCLC was divided into two subgroups: the classic oat cell carcinoma (12 cases) and the intermediate type (10 cases); the cytological subtype was not determined in 19 cases. TTF-1 was detected immunocytochemically using a rabbit antiserum to TTF-1. The specificity of this antiserum in immunohistochemical studies has been established before.³

Briefly, after rehydration and inhibition of endogenous peroxidase, the sections were

University of Udine,
Department of
Pathology
C Di Loreto
CA Beltrami

Postgraduate School of
Oncology
V Di Lauro
F Puglisi

Department of
Biomedical Sciences
and Technology
G Damante
D Fabbro

Correspondence to:
Dr Carla Di Loreto,
Istituto di Anatomia
Patologica,
Piazzale Santa Maria della
Misericordia,
33100 Udine, Italy.

Accepted for publication
13 September 1996

Keywords: TTF-1; lung carcinoma; inflammatory cells; cytology.

Lung cancer is the leading cause of death from cancer in the West.¹ The basic division of lung cancer in two categories—namely small cell (SCLC) and non-small cell types (NSCC)—is valuable because of the significant differences in biological and clinical behaviour. The therapeutic approach to patients with NSCC differs from that in patients with SCLC. In fact, the former may benefit from a surgical approach, but this is not usually the case in the latter.¹ In addition, combined chemotherapy may induce a complete remission of SCLC because of the high sensitivity of this tumour type to antitumor

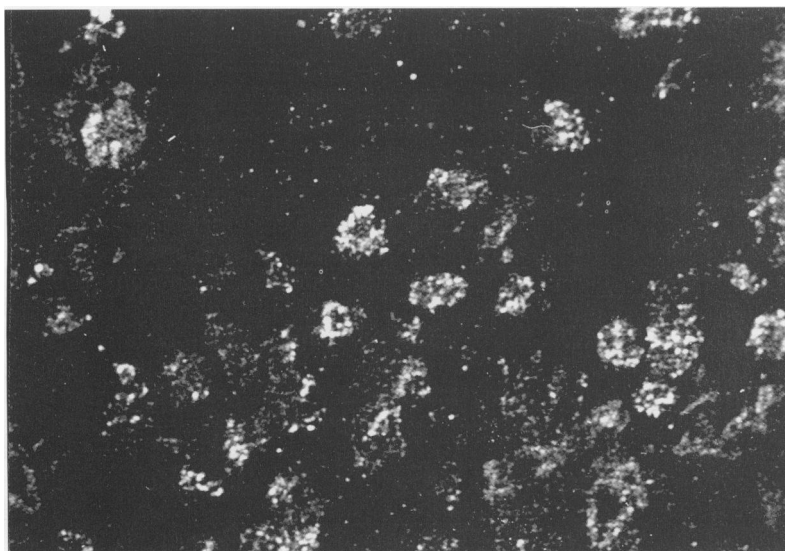


Figure 1 Small cell lung carcinoma: many cells show a strong nuclear granular immunoreactivity for TTF-1. (Fluorescence-confocal laser scanning.)

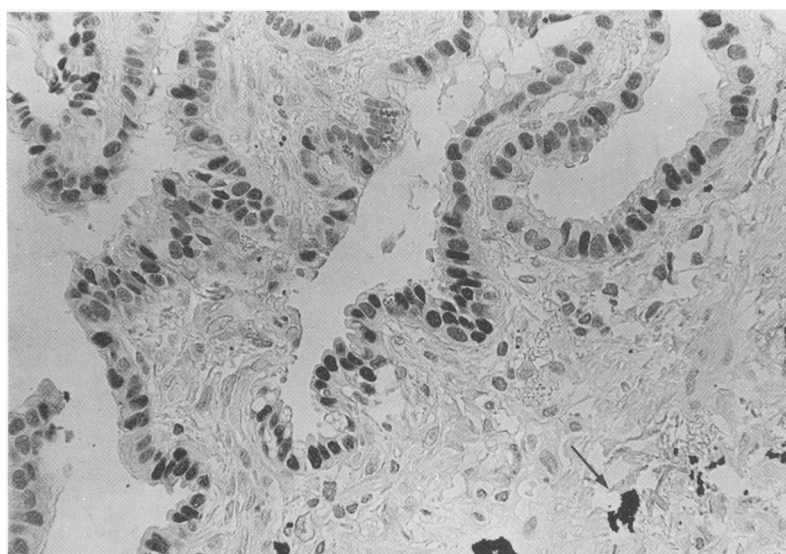


Figure 2 Normal lung tissue showing some bronchiolar epithelial cells with nuclear positivity for TTF-1. Anthracotic deposits can be seen in the interstitium (arrow). (Immunoperoxidase-haematoxylin.)

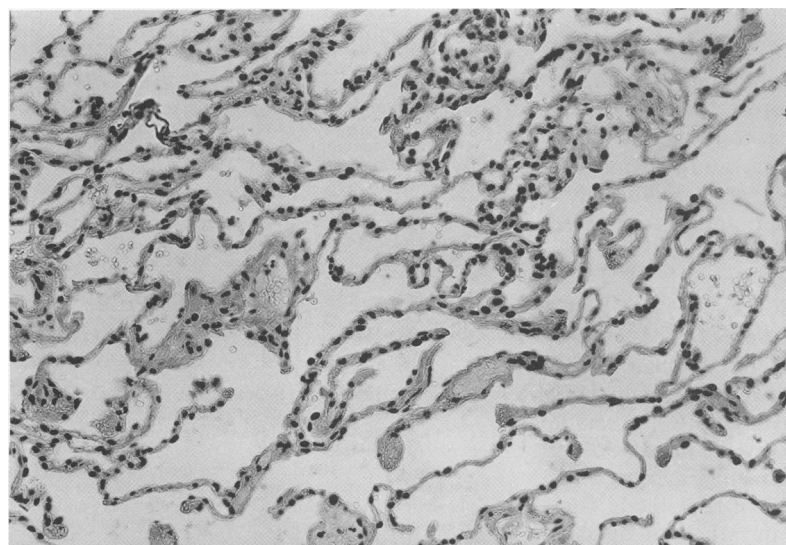


Figure 3 Normal lung tissue showing diffuse nuclear immunoreactivity for TTF-1 in alveolar cells. (Immunoperoxidase-haematoxylin.)

Table 1 TTF-1 immunoreactivity in small and non-small cell lung carcinoma

	TTF-1 positive(%)	TTF-1 negative(%)	Total
SCLC	38 (92.7)	3 (7.3)	41
SCC	1 (11)	8 (89)	9
AC	5 (62.5)	3 (37.5)	8

200 for two hours; biotin labelled goat anti-rabbit for 30 minutes; avidin-biotin peroxidase complex (ABC; Vector Laboratories, Burlingame, California, USA) for 30 minutes; incubation in substrate solution. 3,3'-diaminobenzidine was used as the chromogen. The sections were counterstained with light Harris' haematoxylin, dehydrated, cleared, and mounted in Eukitt.

The immunocytochemical preparations were evaluated by two independent observers. The reaction was considered positive if nuclear immunostaining was seen. The percentage of positive cells was evaluated for each immunoreactive case. Fisher's exact test was used for statistical evaluation of the data.

Results

Immunostaining for TTF-1 was limited to the nuclei of epithelial cells with a finely granular pattern decorating the chromatin, more clearly shown by means of a confocal laser scanning microscope (0.488 $\mu\text{m}/\text{pixel}$, $\times 40$ objective) (fig 1).

In non-neoplastic tissues, nuclear TTF-1 immunoreactivity was seen in the alveolar and bronchiolar epithelial cells; interstitial cells, lymphocytes, alveolar macrophages did not immunostain for TTF-1 (figs 2-4).

Data about TTF-1 immunoreactivity in lung tumours are summarised in table 1.

Nuclear immunoreactivity for TTF-1 was identified in neoplastic cells in 38 (92.7%) of the 41 cases of SCLC (fig 5), five (62.5%) of the eight cases of adenocarcinoma and in one (11%) of the nine cases of SCC. The percentage of positive neoplastic cells in cases of SCLC ranged from 10% to 100% (mean 62.2; SD 30.1). In TTF-1 positive adenocarcinomas, the percentage of positive cells ranged from 30% to 80% (mean (SD) 52 (21.7) %). The immunoreactive case of SCC contained 80% positive cells. A significant difference in TTF-1 immunoreactivity was found between the two main groups of SCLC and NSCC ($p < 0.001$). When we compared TTF-1 expression in SCLC and adenocarcinoma and SCC, the difference remained significant, with p values, respectively, of < 0.05 and < 0.001 .

Inflammatory cells, such as macrophages, neutrophils, and lymphocytes, did not stain for TTF-1.

Discussion

TTF-1 expression has been investigated both in thyroid and lung tumours.^{6,9} In contrast to differentiated thyroid carcinomas where TTF-1 is always expressed, in lung carcinomas TTF-1 immunoreactivity varies according to tumour type. A recent study showed that immunostaining for TTF-1 was positive in all

incubated with normal goat serum. Subsequent incubations were as follows (all at room temperature): antibody to TTF-1 diluted 1 in

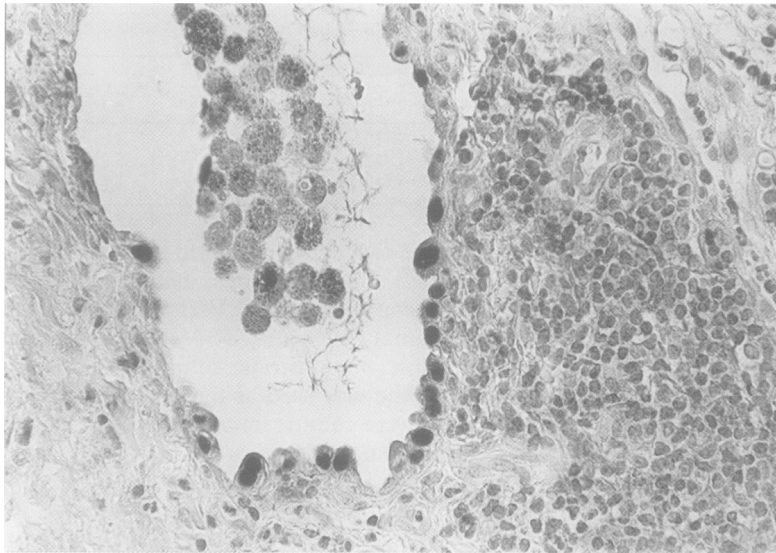


Figure 4 Interstitial pulmonary fibrosis. Alveolar cells are positive for TTF-1 whereas lymphocytes and intra-alveolar macrophages are negative. Note anthracotic pigment in the cytoplasm of macrophages. (Immunoperoxidase-haematoxylin.)

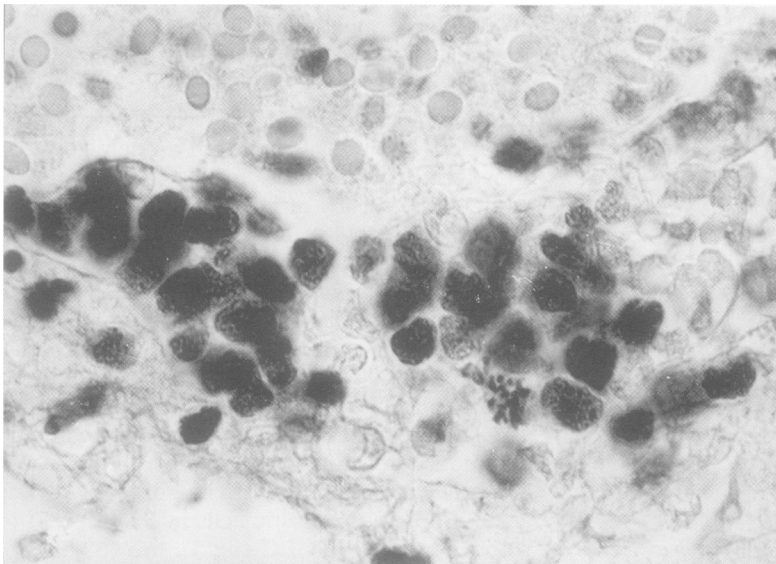


Figure 5 Small cell lung carcinoma: a group of non-cohesive neoplastic cells shows nuclear TTF-1 immunoreactivity. The variable intensity seems to be correlated with chromatinic compactness. The chromosomes of a mitotic figure are also positive. (Immunoperoxidase-haematoxylin.)

cases of SCLC evaluated on biopsy specimens; the percentage of immunoreactive cells ranged from 54 to 97%. On the contrary, in SCC, bronchioalveolar carcinoma, and adenocarcinoma, positivity for TTF-1 was found in only a few cases.⁶ Recently, other authors reported similar results in NSCC.¹⁰

In the present cytological series, TTF-1 was expressed in 92.7% of SCLC, 11% of SCC, and 62.5% of adenocarcinomas.

Although TTF-1 is strictly associated with SCLC, our results show its low specificity and, as a consequence, its unsuitability as specific marker of SCLC. However, detection of TTF-1 could be valuable for highlighting neoplastic cells when cytological specimens contain only a few cells, or when neoplastic elements are obscured by inflammatory cells or necrosis.

Furthermore, in some pathological conditions, such as inflammatory diseases or pulmonary lymphomas, small lymphocytes may be

misinterpreted as SCLC. As a rule, TTF-1 immunostaining may be used as an ancillary diagnostic method in the differential diagnosis between neoplastic epithelial cells and lymphocytes because of the absence of TTF-1 in the latter. This is especially valuable when the cytoplasm is absent or not well preserved, and cytoplasmic immunostaining—namely cytokeratins and leucocyte common antigen—does not clarify diagnosis.

The high percentage of positivity observed in adenocarcinoma could also be favourably used to differentiate primary pulmonary adenocarcinoma from metastatic adenocarcinoma, as recently reported by Bejarano *et al.*¹⁰

Finally, because of the high prevalence of TTF-1 in SCLC and the differential expression of this marker in NSCC, its potential prognostic role seems to be promising. Indirect support for this hypothesis comes from the findings of the study by Bejarano and colleagues in which TTF-1 and surfactant protein A (SP-A) are shown to be frequently co-expressed in pulmonary tumours.¹⁰ In fact, in NSCC, surfactant associated protein SP-A and 10 kilodalton Clara cell protein (CC10) have been reported to have prognostic value and, in particular, SP-A is associated with a slower development of metastases.¹¹ Furthermore, TTF-1 was recently shown to be involved as a transcription factor in the regulation of surfactant proteins and CC10 gene expression.^{5, 12}

This work was supported by a grant from CNR, ACRO project and AIRC (Associazione Italiana Ricerca sul Cancro). We thank Mrs Di Gaspero Marina for her technical help.

- 1 Minna JD, Pass H, Glatstein E, Ihde DC. Cancer of the lung. In: De Vita VT, Hellman S, Rosemberg SA, eds. *Cancer: principles and practice of oncology*. 3rd edn. Philadelphia: JB Lippincott, 1989:591–705.
- 2 Perry MC, Eaton WL, Propert KJ, Ware JH, Zimmer B, Chahnam AP, *et al.* Chemotherapy with or without radiation therapy in limited small cell carcinoma of the lung. *N Engl J Med* 1987;316:912–18.
- 3 Lazzaro D, Price M, De Felice M, Di Lauro R. The transcription factor TTF-1 is expressed at the onset of thyroid and lung morphogenesis and in restricted regions of fetal brain. *Development* 1991;113:1093–104.
- 4 Ikeda K, Clark JC, Shaw-White JR, Stahlman MT, Boutell CJ, Whitsett JA. Gene structure and expression of human thyroid transcription factor-1 in respiratory epithelial cells. *J Biol Chem* 1995;270:8108–14.
- 5 Bohinski RJ, Di Lauro R, Whitsett JA. The lung-specific surfactant protein B promoter is a target for thyroid transcription factor 1 and hepatocyte nuclear factor 3, indicating common factors for organ specific gene expression along the foregut. *Mol Cell Biol* 1994;14:5671–81.
- 6 Fabbro D, Di Loreto C, Stamerra O, Beltrami CA, Lo Nigro R, Damante G. TTF-1 gene expression in human lung tumours. *Eur J Cancer* 1996;32A:512–17.
- 7 Koss Leopold G (ed). Cytologic techniques. In: *Diagnostic cytology and its histopathology bases*. Vol II. 4th edn. Philadelphia: JB Lippincott, 1992:1472–3.
- 8 Koss Leopold G (ed). Tumours of lung: conventional cytology and aspiration biopsy. In: *Diagnostic cytology and its histopathology bases*. Vol I. 4th edn. Philadelphia: JB Lippincott, 1992:784–5.
- 9 Fabbro D, Di Loreto C, Beltrami CA, Belfiore A, Di Lauro R, Damante G. Tissue-specific transcription factors TTF-1 and PAX-8 in human thyroid neoplasms. *Cancer Res* 1994;54:4744–9.
- 10 Bejarano PA, Baughman RP, Biddinger PW, Miller MA, Fenoglio-Preiser C, Al-Kafaji B, *et al.* Surfactant proteins and thyroid transcription factor-1 in pulmonary and breast carcinomas. *Mod Pathol* 1996;9:445–52.
- 11 Linnoila RJ, Jensen SM, Steinberg SM, Mulshine JM, Eggleston JC, Gazdar AF. Peripheral airway cell marker expression in non-small cell lung carcinoma. *Am J Clin Pathol* 1992;97:233–43.
- 12 Bohinski RJ, Huffman JA, Whitsett JA, Lattier DL. Cis-active elements controlling lung cell-specific expression of human pulmonary surfactant protein B gene. *J Biol Chem* 1993;268:11160–6.