

## Management of hepatocellular carcinoma with portal vein tumor thrombosis: Review and update at 2016

Stephen L Chan, Charing CN Chong, Anthony WH Chan, Darren MC Poon, Kenneth SH Chok

Stephen L Chan, State Key Laboratory in Oncology of South China, Institute of Digestive Disease, The Chinese University of Hong Kong, Hong Kong, China

Stephen L Chan, Darren MC Poon, Department of Clinical Oncology, Sir YK Pao Center for Cancer, Hong Kong Cancer Institute, The Chinese University of Hong Kong, Prince of Wales Hospital, Hong Kong, China

Charing CN Chong, Department of Surgery, Prince of Wales Hospital, The Chinese University of Hong Kong, Hong Kong, China

Anthony WH Chan, State Key Laborator in Oncology of South China, Department of Anatomical and Cellular Pathology, The Chinese University of Hong Kong, Hong Kong, China

Kenneth SH Chok, Department of Surgery, Queen Mary Hospital, The University of Hong Kong, China

**Author contributions:** Chan SL and Chok KSH designed the research; Chan SL, Chong CCN, Chan AWH, Poon DMC and Chok KSH performed the research; Chan SL, Chong CCN, Chan AWH, Poon DMC and Chok KSH analyzed the data; and Chan SL, Chong CCN, Chan AWH, Poon DMC and Chok KSH wrote the paper. An author may list more than one contribution, and more than one author may have contributed to the same aspect.

**Supported by the Hong Kong Research Grants Council General Research Fund Scheme, No. 462013.**

**Conflict-of-interest statement:** Stephen L Chan has acted as an advisor to Novartis and MSD.

**Open-Access:** This article is an open-access article which was selected by an in-house editor and fully peer-reviewed by external reviewers. It is distributed in accordance with the Creative Commons Attribution Non Commercial (CC BY-NC 4.0) license, which permits others to distribute, remix, adapt, build upon this work non-commercially, and license their derivative works on different terms, provided the original work is properly cited and the use is non-commercial. See: <http://creativecommons.org/licenses/by-nc/4.0/>

Manuscript source: Invited manuscript

**Correspondence to:** Stephen L Chan, Department of Clinical Oncology, Sir YK Pao Center for Cancer, Hong Kong Cancer Institute, The Chinese University of Hong Kong, Prince of Wales Hospital, Shatin, Hong Kong, China. [chanlam\\_stephen@cuhk.edu.hk](mailto:chanlam_stephen@cuhk.edu.hk)  
Telephone: +852-2632-2118  
Fax: +852-2648-7097

Received: March 29, 2016  
Peer-review started: April 1, 2016  
First decision: May 30, 2016  
Revised: June 27, 2016  
Accepted: August 1, 2016  
Article in press: August 1, 2016  
Published online: August 28, 2016

### Abstract

Portal vein tumor thrombosis (PVTT) is a common phenomenon in hepatocellular carcinoma (HCC). Compared to HCC without PVTT, HCC with PVTT is characterized by an aggressive disease course, worse hepatic function, a higher chance of complications related to portal hypertension and poorer tolerance to treatment. Conventionally, HCC with PVTT is grouped together with metastatic HCC during the planning of its management, and most patients are offered palliative treatment with sorafenib or other systemic agents. As a result, most data on the management of HCC with PVTT comes from subgroup analyses or retrospective series. In the past few years, there have been several updates on management of HCC with PVTT. First, it is evident that HCC with PVTT consists of heterogeneous subgroups with different prognoses. Different classifications have been proposed to stage the degree of portal vein invasion/thrombosis, suggesting that different treatment modalities may be individualized to patients with different risks. Second, more studies indicate that more aggressive treatment, including surgical resection or locoregional treatment, may benefit select HCC patients with PVTT. In this review, we aim to discuss

the recent conceptual changes and summarize the data on the management of HCC with PVTT.

**Key words:** Liver cancer; Vascular invasion; Targeted agent; Surgery; Radiotherapy

© **The Author(s) 2016.** Published by Baishideng Publishing Group Inc. All rights reserved.

**Core tip:** Conventionally, the presence of portal vein tumor thrombosis (PVTT) indicated an extremely poor prognosis for hepatocellular carcinoma (HCC) patients and was considered a contraindication to both surgery and trans-arterial procedures. Recent studies indicate that HCC with PVTT represents a heterogeneous group with variable prognoses. Several classifications have been proposed to gauge the prognoses of PVTT. For selected patients with less severe PVTT, surgery with curative intent is feasible with favorable outcomes. Further, expanding treatment options, such as radiotherapy, radioembolization and systemic treatment, could improve the outcomes of patients with more severe forms of PVTT in patients with HCC.

Chan SL, Chong CCN, Chan AWH, Poon DMC, Chok KSH. Management of hepatocellular carcinoma with portal vein tumor thrombosis: Review and update at 2016. *World J Gastroenterol* 2016; 22(32): 7289-7300 Available from: URL: <http://www.wjgnet.com/1007-9327/full/v22/i32/7289.htm> DOI: <http://dx.doi.org/10.3748/wjg.v22.i32.7289>

## INTRODUCTION

Hepatocellular carcinoma (HCC) is characterized by its propensity to invade the vasculature within the liver. The invasion of the hepatic vasculature is of macroscopic or microscopic type. Macrovascular invasion refers to gross invasion into the main portal veins or their branches, hepatic veins or the inferior vena cava in the liver, while microscopic vascular invasion is defined as tumors within a vascular space lined by endothelium that is identifiable only by microscopy<sup>[1]</sup>.

Portal vein tumor thrombosis (PVTT) is the most common form of macrovascular invasion of HCC. Multiple case series have suggested that the PVTT is a common phenomenon with a prevalence rate ranging from 10% to over 60%<sup>[2-5]</sup>. The presence of PVTT in patients with HCC has been consistently demonstrated by different series to be associated with poor prognoses, with a hazard ratio of death close to 2<sup>[5,6]</sup>. The poor prognosis of PVTT in HCC patients is the result of combined factors including impaired hepatic reserves, intrinsic aggressiveness of tumor, reduced intolerance to anti-neoplastic treatment and a high rate of developing complications related to portal hypertension. Clinically, PVTT is associated with large tumor size, increased

tumor number, higher tumor grade, worse Child-Pugh class and higher serum alpha-fetoprotein (AFP)<sup>[7]</sup>. At the genetic level, next generation sequencing identified that mutations of the *KDM6A*, *CUL9*, *FDG6*, *AKAP3*, and *RNF139* genes were associated with the development of PVTT in advanced Hepatitis B virus-related HCC<sup>[8]</sup>.

It has to be noted that not all portal vein thrombosis in HCC patients is due to neoplastic thrombus. It is evident that a portion (ranging from 0.6% to 11%) of cirrhotic patients, particularly those with portal hypertension, are complicated by non-neoplastic portal vein thrombosis (NPVT)<sup>[9]</sup>. Up to 72.7% of portal thrombi in HCC patients are indeed NPVT<sup>[10]</sup>. Patients with NPVT have better prognoses than those with PVTT; therefore, the differentiation between NPVT and PVTT is of clinical relevance. Theoretically, image-guided percutaneous fine needle aspiration or a biopsy of portal vein thrombosis could provide a definite pathological diagnosis<sup>[9,11]</sup>. However, biopsy procedures are not frequently conducted in clinical practice to confirm PVTT because of concerns about life-threatening complications such as injuries to the bile ducts or hepatic arteries<sup>[11]</sup>. Instead, non-invasive imaging studies are the most frequently used diagnostic tool for PVTT. Contrast-enhanced ultrasonography, dynamic contrast enhanced computed tomography and gadoxetic acid-enhanced magnetic resonance could achieve a diagnosis of PVTT with sensitivities of 82.5%-98%, 68%-86% and 92%-95%, respectively<sup>[11-13]</sup>.

Conventionally, the treatment algorithm proposed by the Barcelona Clinic Liver Cancer (BCLC) system considers the presence of PVTT, regardless of the degree of invasion, as a contra-indication to surgery or transarterial chemoembolization (TACE)<sup>[14]</sup>. Patients with PVTT are classified in the BCLC stage C category and are considered candidates for systemic agents. However, a recent concept has evolved, which considers HCC with PVTT to consist of heterogeneous populations with different disease behaviors and prognoses, and selected patients with PVTT may benefit from more aggressive treatment modalities. In the current review, we aim to discuss these changing concepts in the management of HCC with PVTT with a focus on the latest data on the adoption of a more aggressive treatment approach for this disease entity.

## CLASSIFICATIONS OF PVTT

The management of patients with PVTT can be challenging because the clinical course is typically characterized by poor underlying liver reserve and high portal vein pressure. A complicated operation is usually required if an aggressive treatment approach is contemplated. To devise the best treatment strategy for patients with PVTT, a universally accepted classification of PVTT is necessary for the guidance of treatment and a comparison of outcomes between

**Table 1 Common classifications of portal vein tumor thrombosis in hepatocellular carcinoma**

Group	Types of PVTT	Survival
Ikai <i>et al</i> <sup>[80]</sup>	Vp0: Absent	59% at 5 yr
	Vp1: Distal to but not in second-order branches	39.1% at 5 yr
	Vp2: In second-order branches	23.3% at 5 yr
	Vp3: In first-order branches	18.3% at 5 yr (Vp3 and Vp4)
	Vp4: In the main trunk or contralateral or both	
Shi <i>et al</i> <sup>[17]</sup>	10: Microscopic	26.7% at 3 yr (Type 10 included)
	1: In segmental branches or above	
	2: In the left or right branch	
	3: In the main trunk	
	4: In the superior mesenteric vein	
Xu <i>et al</i> <sup>[18]</sup>	A: In the main trunk or both the left and right branches	0% at 5 yr
	B: In only the left or right branch	5.2% at 5 yr

HCC: Hepatocellular carcinoma; PVTT: Portal vein tumor thrombosis.

different groups. At present, various classification systems have been developed in different centers. The more conventional and better-known classification is the one proposed by the Liver Cancer Study Group of Japan (LCSGJ). In their General Rules for the Clinical and Pathological Study of Primary Liver Cancer<sup>[15]</sup>, there is a macroscopic classification of HCC with PVTT: Vp0, no PVTT; Vp1, the presence of a PVTT distal to, but not in, the second-order branches of the portal vein; Vp2, the presence of a PVTT in the second-order branches of the portal vein; Vp3, the presence of a PVTT in the first-order branches of the portal vein; and Vp4, the presence of a PVTT in the main trunk of the portal vein or a contralateral portal vein branch or both. According to the guideline, resection is one of the feasible options for treatment in case of minor portal vein involvement (*i.e.*, Vp1 and Vp2)<sup>[16]</sup>. For selected Vp3 or Vp4 patients, surgical resection would still be considered, and a 5-year survival of 18.3% has been reported<sup>[16]</sup>. In view of the guarded prognosis, few centers would adopt this aggressive approach. Moreover, the required expertise is not always available (Table 1).

In 2007, Shi *et al*<sup>[17]</sup> devised a classification of HCC with PVTT that incorporated microscopic PVTT as Type 1. In this classification, Type 1 is a PVTT involving segmental branches or above; Type 2 is a PVTT involving the right or left portal vein; Type 3 is a PVTT involving the main portal vein; and Type 4 is a PVTT involving the superior mesenteric vein. In general, surgical resection can be applied to Type 3 and to selected patients with Type 4. In their report, the numbers of patients with Types 1, 2, 3 and 4 were 144 (32.7%), 189 (42.9%), 86 (19.5%) and 22 (5.0%), respectively. The 1-, 2-, and 3-year overall survival rates were 54.8%, 33.9% and 26.7% for Type 1 patients, respectively, 36.4%, 24.9% and 16.9% for Type 2 patients, respectively, 25.9%, 12.9% and 3.7% for Type 3 patients, respectively, and 11.1%, 0% and 0% for Type 4 patients, respectively ( $P < 0.0001$ ).

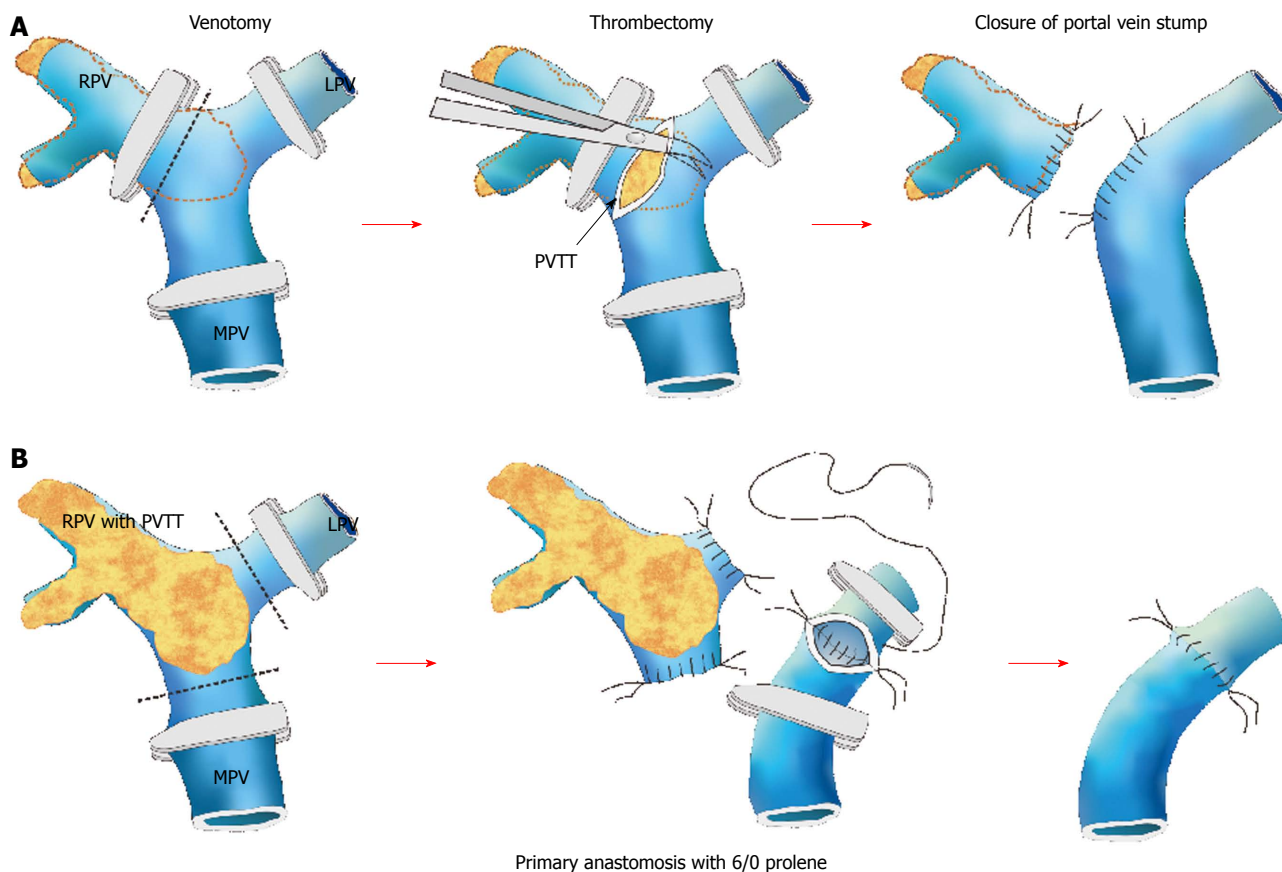
A simplified classification by Xu *et al*<sup>[18]</sup> divided patients with PVTT into two groups: Group A, with

involvement of the main portal vein trunk or both the left and right portal veins, and Group B, with involvement of only the left or right portal vein. In their report, the Group A 1-year overall survival rate was 31.5% after resection, and the 1-, 3- and 5-year overall survival rates of Group B patients were 62.3%, 16.1% and 5.2%, respectively. This simple classification could be used as a quick reference when counseling patients (especially Group A patients) about surgical treatment. No matter which of the above classifications is used, the prognosis would be determined by the extent of the PVTT and its proximity to the main, or even the contralateral, portal vein.

## SURGERY (*EN BLOC* PORTAL VEIN RESECTION VS TUMOR THROMBECTOMY)

The prognosis is notoriously poor for HCC patients with macrovascular PVTT, especially those whose PVTT has extended to the main or contralateral portal vein<sup>[19]</sup>. The PVTT could propagate further and obstruct the whole vein lumen, resulting in liver failure or life-threatening variceal bleeding. One of the treatment modalities is surgical resection, the two common modes of which are tumor thrombectomy and *en bloc* resection of the thrombus and the portal vein followed by portal vein reconstruction. Tumor thrombectomy is technically less demanding but might result in a residual tumor. As for the latter mode, it is associated with high morbidity and mortality rates despite a "perceived" better oncological outcome<sup>[20]</sup>. However, there has been no randomized controlled trial to determine the superiority of one over the other, and the choice rests with individual centers and individual surgeons (Figure 1).

A PVTT confined to the hepatic lobe harboring the HCC (ipsilateral PVTT) is usually resected when a hepatectomy is conducted to remove the HCC<sup>[21]</sup>. For the management of PVTT extending to the portal vein bifurcation or the main or contralateral portal vein,



**Figure 1** Schematic diagrams demonstrating different types of portal vein tumor thrombosis and the relevant surgical approaches. A: Thrombectomy; B: *En bloc* resection with portal vein reconstruction. RPV: Right portal vein; LPV: Left portal vein; MPV: Main portal vein. Courtesy of Chok *et al*<sup>[21]</sup>.

different approaches have been recommended. *En bloc* resection, including bifurcation with or without the main portal vein and/or the contralateral portal vein, is believed to produce good oncological outcomes<sup>[22]</sup>. However, it has been documented that thrombectomy can produce similar survival outcomes with lower operative mortality and morbidity<sup>[20-22]</sup>. In a study from Japan, 979 consecutive patients were evaluated, and 45 of them had Vp3 or Vp4 PVTT<sup>[23]</sup>. They received hepatectomy with tumor thrombectomy. The 3- and 5-year survival rates in the Vp3 and Vp4 groups were 35.3% and 41.8%, and 21.2% and 20.9%, respectively.

In a study by The University of Hong Kong trying to address the controversy about *en bloc* resection vs thrombectomy<sup>[21]</sup>, patients were divided into three groups: Group 1 ( $n = 71$ ), with ipsilateral PVTT resected in a hepatectomy; Group 2 ( $n = 10$ ), with PVTT extending to or beyond the bifurcation, treated by *en bloc* resection followed by portal vein reconstruction; and Group 3 ( $n = 7$ ), with PVTT extending to or beyond the bifurcation, treated by thrombectomy. The median overall survival duration was 10.91 mo in Group 1, 9.4 mo in Group 2, and 8.58 mo in Group 3, and it was shown that *en bloc* resection and thrombectomy were not significantly different in terms of hospital mortality and morbidity. The frequent practice of living donor

liver transplantation at this center certainly contributed to the low morbidity rate after portal vein resection<sup>[24]</sup>. The 1-, 3- and 5-year overall survival rates were 50%, 12.5% and 12.5%, respectively, in Group 2 and 28.6%, 14.3% and 14.3%, respectively, in Group 3. The 1-year disease-free survival rates were 24.3, 0, and 14.3%, respectively. The 3-year DFS rates were 14.3, 0, and 14.3%, respectively. The 5-year DFS rates were 10.7, 0, and 14.3%, respectively. Again, the two approaches had no significant differences in terms of overall survival or disease-free survival. Patients with ipsilateral PVTT also had similar survival outcomes compared with patients with PVTT extending to or beyond the bifurcation. These survival outcomes were satisfactory when compared with those (a median survival duration of only 2.7 mo) of patients with PVTT who were untreated<sup>[1]</sup>. Peng *et al*<sup>[25]</sup> compared hepatic resection and transarterial chemoembolization (TACE) for patients with PVTT and found that the resection group had significantly longer overall survival. The 1-, 3-, and 5-year overall survival rates were 42.0%, 14.1% and 11.1%, respectively, in the resection group and 37.8%, 7.3% and 0.5%, respectively, in the TACE group ( $P < 0.001$ ). In the subgroup analysis, the resection group had better overall survival in regard to Type 1 PVTT, Type 2 PVTT, single tumor, and tumor >5 cm ( $P < 0.001$ ,  $P = 0.002$ ,  $P < 0.001$ , and  $P < 0.001$ ,



**Table 2** Prospective trials on transarterial chemoembolization for hepatocellular carcinoma with portal vein tumor thrombosis

Group	No. of patients	Treatments	Child-Pugh A	Survival
Luo <i>et al</i> <sup>[81]</sup>	164 (84 vs 80)	TACE vs Control	Not known	1-yr survival 30.9% vs 9.2%
Niu <i>et al</i> <sup>[82]</sup>	150 (115 vs 35)	TACE vs Control	88 vs 21	Median survival 8.67 mo vs 14 mo
Kim <i>et al</i> <sup>[83]</sup>	110 (49 vs 61)	TACE vs TACI	30 vs 22	Median survival 14.9 mo vs 4.4 mo
Peng <i>et al</i> <sup>[25]</sup>	603 (402 vs 201)	TACE vs Resection	389 vs 197	Median survival 42 mo vs 14.1 mo

TACE: Transarterial chemoembolization; PVTT: Portal vein tumor thrombosis; TACI: Transcatheter arterial chemoinfusion.

respectively). No difference in overall survival was shown in regard to Type 3 PVTT, Type 4 PVTT, multiple tumors, and tumor < 5 cm ( $P = 0.541$ ,  $P = 0.371$ ,  $P = 0.264$ ,  $P = 0.338$ , and  $P = 0.125$ , respectively).

In a number of reports concerning all degrees of PVTT, the median survival durations varied from 8.9 mo to 33 mo, and the operative mortality rates varied from 0% to 5.9%<sup>[22,26-30]</sup>. For patients with PVTT confined to the ipsilateral first-generation portal vein, resection of the PVTT in a hepatectomy is recommended. With a good resection margin, intrahepatic recurrence could be prevented. For PVTT extending to or beyond the bifurcation, an *en bloc* resection or thrombectomy should be considered. Nonetheless, if the liver is cirrhotic or if the resection would leave an inadequate liver remnant, major resection will not be possible.

## TRANS-ARTERIAL CHEMOEMBOLIZATION

Trans-arterial chemoembolization takes advantage of the relatively selective arterial vascularization of hepatic tumors. Chemotherapeutic agents are delivered with simultaneous embolization to increase the local chemotherapeutic dwell time and induce tumor ischemia<sup>[31]</sup>. The technique of TACE varies; typically, super-selective cannulation of the artery supplying the tumor is performed whenever possible. An emulsion of cisplatin (1 mg/mL) and Lipiodol (Lipiodol Ultrafluide®; Laboratoire Guerbet, Aulnay-Sous-Bois, France) in a volume ratio of 1:1 is injected up to a maximum of 60 mL, depending on the size and number of the tumor<sup>[32,33]</sup>, with or without embolization. TACE is repeated every 8 to 12 wk, and the treatment is to be stopped when there is progressive disease, extrahepatic disease, a severe life-threatening complication, or evidence of liver failure or decompensation (serum total bilirubin > 50 μmol/L, gross ascites with uncontrollable with diuretics, or hepatic encephalopathy)<sup>[34]</sup>. TACE is considered the primary treatment for patients who have inoperable HCC that is confined to the liver and

in the absence of contraindications to TACE. Studies have reported that 35% of patients had a complete or progressive response to TACE, with < 2% of patients having a complete response<sup>[35,36]</sup>. Lo *et al*<sup>[37]</sup> compared TACE with symptomatic treatment and found that the patient survival rate at 2 years after treatment was higher with TACE (41%) than that with symptomatic treatment (27%).

The thought behind using TACE for the treatment of HCC with PVTT is evolving. Traditionally, TACE is generally not recommended for patients with PVTT because of the increased risk of liver failure<sup>[38,39]</sup>, but there have been no large trials to validate this recommendation. For the past 5 years, a growing number of studies showed that TACE could be safely conducted in patients with PVTT, provided that there is an adequate hepatic reserve and the establishment of collateral blood circulation around the obstructed PVTT (Table 2)<sup>[40,41]</sup>. Of note, there are two randomized prospective studies comparing TACE to conservative management in patients with PVTT. Both studies consistently demonstrated improved overall survival in the TACE arm when compared to patients undergoing conservative management. Both studies have also conducted subgroup analyses in a population with different degrees of PVTT. Niu *et al* has shown that the survival benefits in PVTT type I (TACE: 19 mo vs conservative: 4 mo,  $P = 0.001$ ); type II (TACE: 11 mo vs conservative: 1.43 mo,  $P < 0.001$ ); type III (TACE: 7.1 mo vs conservative: 1.3 mo,  $P < 0.001$ ) and type IV (TACE: 4 mo vs conservative: 1 mo,  $P = 0.005$ ). Luo *et al* showed that the 6-mo survival rates of the TACE arm for branch and main PVTT were 75% and 38.7%, respectively, compared to 45.5% and 20% in the conservative arm. There are also prospective studies comparing TACE vs the hepatic arterial infusion of chemotherapy, of which superior survival outcomes were observed in the TACE arm.

Currently, there are no prospective data from a head-to-head comparison between TACE and systemic therapy in patients with PVTT. However, taking the above studies into consideration, it is generally accepted that TACE is feasible and effective in select patients with branch PVTT because the overall survival appeared to be longer than that achieved in most clinical trials of systemic therapy. As shown in Table 2, many more Child-Pugh A patients underwent TACE, and the benefits of TACE were significantly less in Child-Pugh B patients with PVTT. Liver function remains the most important criteria for selecting patients to receive TACE treatment. The role of TACE in the treatment of main PVTT (Vp4 or type III/IV) is more controversial. Although randomized studies indicated the survival benefits of TACE in these groups of patients, overall survival (4-7 mo) was similar, if not inferior, to survival observed in clinical trials on systemic agents such as sorafenib (see below: systemic therapy).

**Table 3 Studies on radiation therapy for hepatocellular carcinoma with portal vein tumor thrombosis**

<i>n</i>	Treatment	Total RT dose/ fractional dose (in Gy)	Response rate (CR + PR, %)	Median survival (mo)	Toxicity grade ≥ 3 (%)	Ref.
45	3D-CRT (+TACE/PEI/RFA; 7% RT only)	38-65/1.8-2.5	62.3 (CR 6.7)	11.2	2	Rim <i>et al</i> <sup>[51]</sup>
412	3D-CRT + TACE	21-60/2-5	27.9 (CR 3.6)	10.6	10	Yoon <i>et al</i> <sup>[44]</sup>
40	IGRT + IA 5FU/IFN <i>vs</i> IA 5FU/ IFN	30-48/7-16	60 (CR 5)	12 (RT) 9.1 (non-RT)	15	Chuma <i>et al</i> <sup>[52]</sup>
32	IA 5FU/IFN + 3D-CRT <i>vs</i> IA 5FU/ IFN	30-45/3	75 (CR 19)	7.5 (RT) 7.9 (non-RT)	G4: 2 G3: 7% (leucopenia)/ 6% (thrombocytopenia)/ 1 (anorexia)	Katamura <i>et al</i> <sup>[46]</sup>
45	PV stenting + TACE + 3D-CRT <i>vs</i> PV stenting + TACE	30-60/2	35.6 (CR 0)	16.5 (RT) 4.8 (non-RT)	0	Zhang <i>et al</i> <sup>[45]</sup>
326	3D-CRT (IMRT 14.1%)	60/2-3	18.1 (CR 5.8)	4	0	Huang <i>et al</i> <sup>[53]</sup>
38	3D-CRT	17.5-50.4/1.8-4	44.7 (CR 15.8)	9.6	0	Toya <i>et al</i> <sup>[47]</sup>
59	3D-CRT	30-54/2-3	45.8 (CR 6.8)	7.8	0	Kim <i>et al</i> <sup>[48]</sup>
44	RT + TACE	36-60/2	45.5 (CR 34.1)	8	0	Kim <i>et al</i> <sup>[49]</sup>
19	3D-CRT (+ TACE for liver tumor)	46-60/2	57.9 (CR 0)	7	G3: 5% (thrombocytopenia)/ 2% (leucopenia)/ 2 (GI ulcers)	Yamada <i>et al</i> <sup>[54]</sup>
20	RT + TACE	50/2	50 (CR 0)	5.3	5	Ishikura <i>et al</i> <sup>[55]</sup>
24	RT + TACE	50/2	50 (CR 16.7)	CR/PR (9.7) NR/PD (3/8)	13%	Tazawa <i>et al</i> <sup>[56]</sup>
281	3D-CRT + TACE	30-54/1.8 -4.5	53.8 (CR 3.6)	11.6	20%	Yu <i>et al</i> <sup>[57]</sup>

3D-CRT: 3 dimensional conformal radiotherapy; GI: Gastrointestinal; PR: Partial response; RT: Radiotherapy; TACE: Transarterial chemoembolization; NR: Non-responder; PD: Progressive disease; PVTT: Portal vein tumor thrombosis.

## RADIOTHERAPY

### External radiotherapy

Historically, external radiotherapy (RT) is not considered a feasible treatment in the management of HCC. This is because the liver is highly radiosensitive, and the delivery of a sufficient high dose RT without excessive hepatotoxicity is challenging. However, as a result of the advances in RT technology, including the conformal RT planning and breathing motion management and image-guided radiation therapy, RT has emerged as a valid treatment option in the treatment of HCC<sup>[42,43]</sup>. A number of retrospective studies have studied the efficacy of RT as single treatment or in combination with other treatment modalities, particularly TACE, in treating HCC with PVTT (Table 3). These reports have consistently reported a favorable toxicity profile and modest efficacy of RT<sup>[44-57]</sup>. In one of the largest series, 412 patients with PVTT were treated with 21-60 Gy in 2- to 5-Gy fractions in combination with sequential TACE. The median survival was 10.6 mo with a 2-year survival rate of 23%, while grade 3 or above toxicity was observed in 10% of patients<sup>[44]</sup>. The radiologic response of PVTT to RT is the most significant prognostic factor, with a median overall survival of 19.4 mo in the responder group *vs* 7.0 mo in the non-responder group.

There is also a growing body of evidence suggesting that the concurrent administration of RT and locoregional treatment could improve the response rate or treatment outcomes of PVTT. In a retrospective study reported by Zhang *et al*<sup>[45]</sup>, patients with PVTT were

treated with percutaneous transhepatic PV stenting and TACE, with or without RT. The median overall survival was 16.5 mo in the RT cohort compared with 4.8 mo in the non-RT cohort. In a matched cohort study by Katamura *et al*<sup>[46]</sup>, a significant improvement in the objective response rate in PVTT was observed in the RT group compared with the non-RT group (75% *vs* 25%) in patients treated with intra-arterial 5-fluorouracil and interferon-alpha. Several studies had evaluated the dose-response of RT in the treatment of HCC with PVTT. The response rate was better when the biologically effective dose (BED) exceeded 58 Gy<sup>[47,48,50]</sup>. Therefore, an attempt to deliver a BED as high as possible is preferred during the planning of RT to HCC with PVTT. However, this can only be achieved in cases of small primary HCC, where both HCC and PVTT could be covered within a high dose target volume without compromising the normal liver. In clinical practice, because bulky HCC is frequently encountered, a combined approach with RT to focus on PVTT and TACE for the treatment of the intra-hepatic tumor is generally preferred to keep the normal liver radiation tolerance within a safe limit. Well-designed prospective studies are required to evaluate this combination for patients with PVTT.

### Selective internal radiation therapy

Selective internal radiation therapy (SIRT), or transarterial radioembolization with Yttrium-90, involves the transarterial administration of therapeutic doses of radiation to the hepatic tumor *via* resin or glass particles. Although resin and glass are both considered

permanent embolic agents, their embolic effects are less than those of a TACE procedure due to their small size, as is their effect on hepatic vascular dynamics<sup>[58]</sup>. During radioembolization, a radioactive microsphere is selectively injected into the hepatic artery or its branch, delivering intense local tumor radiation. SIRT provides adequate radiation to the tumor with little radiation to the rest of the liver and to the patient's body. Because it does not cause ischemia, SIRT can be performed in patients with portal vein thrombosis, making SIRT a feasible choice for HCC with PVTT. Common complications of SIRT include fatigue and deranged liver function<sup>[59]</sup>. Serious complications such as radiation pneumonitis, radiation cholecystitis, liver abscess and radiation-induced liver disease occur in less than 1% of patients. In general, technetium-labeled macroaggregated albumin scanning is performed prior to SIRT to quantify the fraction of lung shunting and/or the tumor/normal uptake ratio. The accepted safe radiation dose to the lung is less than 30 Gy in a single procedure and less than 50 Gy in total over multiple procedures<sup>[59,60]</sup>.

Studies on SIRT focusing on patients with HCC and PVTT are limited. However, numerous retrospective series have reported the safety and efficacy of SIRT in patients with HCC<sup>[61-64]</sup>. Subgroup analyses from the three largest series of HCC patients who underwent SIRT involving more than 200 patients with PVTT demonstrated the overall survival to be approximately 10 mo. Ozkan *et al*<sup>[65]</sup> reported a better median overall survival of 17 mo among 29 HCC patients treated with SIRT, with and without PVTT. There was no significant difference in survival between patients with and without PVT. A report from the largest group of PVT patients showed concordant results<sup>[63]</sup>, in which it was also found that patients with Child-Pugh A cirrhosis, with or without PVT, benefited the most from SIRT. In a recent prospective phase II trial of 35 patients with PVT treated with SIRT, the overall survival of Child-Pugh A and B patients were 16 mo and 6 mo, respectively.

The efficacy of SIRT in unresectable HCC was compared with sorafenib in a recent study. Edeline *et al*<sup>[66]</sup> retrospectively reviewed the records of 151 HCC patients with PVTT. The overall survival of 34 patients treated with SIRT was compared with 117 patients treated with sorafenib only. SIRT was associated with a higher median overall survival compared to sorafenib (18.8 mo vs 6.5 mo,  $P < 0.001$ ). A prospective randomized study comparing SIRT and sorafenib has already completed accrual with preliminary results expected to be available in late 2016 (NCT01135056). At present, there have been no randomized controlled trials directly comparing SIRT to TACE in patients with HCC and PVTT. Several small-scale studies have suggested that the efficacy of SIRT is comparable to TACE in unresectable HCC. Of note, She *et al*<sup>[67]</sup> performed survival analysis of 16 patients who underwent SIRT and compared it with another

16 patients in a matched cohort treated with TACE. Half of the patients in each group had major vascular invasion, and those treated with SIRT had an overall survival of 12.0 mo compared to 8.0 mo in the TACE cohort. These data provide preliminary clues that SIRT might be more effective than TACE in the setting of HCC with PVT, but this hypothesis requires further validation in prospective randomized clinical trials.

## SYSTEMIC THERAPY

Compared to other cancer types, the progress in the development of systemic therapy is slower for HCC. Conventional cytotoxic chemotherapy, such as doxorubicin or doxorubicin-based combinations, could lead to significant toxicity, which limits the potential benefits in cirrhotic populations<sup>[68]</sup>. Other more "novel" regimens of systemic chemotherapy have also been evaluated. In particular, the combination of oxaliplatin and 5-fluorouracil and leucovorin, known as the FOLFOX4 regimen, has been compared to doxorubicin in patients with advanced HCC in an Asian population with HCC<sup>[69]</sup>. The overall study fails to demonstrate a statistically significant difference between the two regimens, but FOLFOX4 was found to have small survival benefits in the subgroup population of Chinese patients<sup>[70,71]</sup>. There have been a handful of case reports or series showing that cytotoxic chemotherapy could improve the severity of PVTT, but there are no dedicated prospective studies to validate such efficacy of systemic chemotherapy in the treatment of PVTT. Further, the toxicity of systemic chemotherapy has been shown to be higher in the presence of impaired liver function and portal hypertension, which frequently occur in patients with PVTT.

Sorafenib is a multi-targeted small molecule with specific activity against vascular endothelial growth factor receptor. Its use in the setting of BCLC stage C HCC, including patients with PVTT, extra-hepatic metastases, and ECOG performance status of 1 or higher, is known to modestly prolong median overall survival by approximately 2 mo, compared to a placebo<sup>[72,73]</sup>. In both Phase III clinical trials, namely the SHARP<sup>[72]</sup> and the Asian pacific study<sup>[73]</sup>, there are no detailed analyses on the efficacy of sorafenib according to the different severities of PVTT. Nevertheless, the efficacy of sorafenib in PVTT may still be indirectly reflected by the subgroup analyses in patients with macrovascular invasion. In both studies, the proportion of macrovascular invasion in the sorafenib arm was 36%, and subgroup analyses unanimously indicated similar survival benefits between patients with and without macrovascular invasion<sup>[72,73]</sup>. Regarding the specific treatment for patients with Vp3 and Vp4 PVTT, a retrospective review was published by a Korean center, which analyzed the outcome of sorafenib in 6 patients with Vp3 and 24 patients with Vp4 PVTT<sup>[74]</sup>. It was shown that 10% (3 patients) had a partial response in the PVTT arm with revascularization, and

the median overall survival was 3.1 mo. The above dataset suggested that sorafenib demonstrated a modest efficacy in the treatment of PVTT, but given the low response rate of likely lower than 10%, the treatment is mainly reserved as a palliative treatment for patients with Vp3 or Vp4 who are not amenable to more aggressive treatment.

Recently, the direction of the development of systemic treatment for HCC has shifted from targets along signaling pathways to immunotherapy and, in particular, to the check-point inhibitors. There have been one phase I clinical trial of a cytotoxic T-lymphocyte-associated protein 4 (CTLA-4) inhibitor, tremelimumab, and another ongoing trial on a programmed cell death protein-1 (PD-1) inhibitor, nivolumab, in patients with advanced HCC<sup>[75,76]</sup>. Both studies have suggested that check-point inhibitors are tolerable and potentially efficacious in HCC. In particular, some remarkable and durable radiological responses have been observed. Given the more mature and robust data of the immune check-point inhibitor in the treatment of HCC, its use in the treatment of PVTT can be better elucidated. Another direction is biomarker-driven drug development, which aims to improve the response *via* patient selection with predictive biomarkers in the tissue or plasma<sup>[77]</sup>.

## PORTAL VEIN STENTING

Theoretically, the placement of an endovascular stent into the portal vein could increase the portal blood flow into the liver parenchyma in HCC complicated with PVTT. This may, in turn, relieve the portal hypertension-related complications, especially variceal bleeding, and expand treatment options for the tumor. Most of the studies on portal vein stenting in the treatment of PVTT of HCC are case reports or small-scale series. Two large-scale case series suggest that portal vein stenting is feasible in select patients. One series come from a Japanese group that reported the percutaneous placement of stents in the portal vein following the administration of TACE or trans-arterial infusion of chemotherapy in 21 patients<sup>[78]</sup>. With a 100% success rate of placement, it was demonstrated that the portal pressure decreased by approximately 3 mmHg. A short course of an anticoagulant was administered in 14 patients, but it was not suitable for the others due to coagulopathy. The patency rate was 53.6% at 1 year with a mean patency period of 12.4 mo. Procedure-related complications appeared to be uncommon, with only a case of pseudoaneurysm reported. Another large case series from a French group reviewed the records of 54 patients with PVTT who underwent portal stenting under general anesthesia by a percutaneous approach or an open approach *via* catheterization of the superior mesenteric vein after exteriorization of the terminal ileum<sup>[79]</sup>. Twenty percent of patients developed complications after portal stenting, mostly in the form

of hepatic failure, and 7% died within 30 d of stenting. Bilirubin levels > 30  $\mu\text{mol/L}$  and an open surgical approach were predictors of short-term mortality. TACE was administered in 48% of patients after stenting, and the 12-mo survival rate was 44%. Both of these series indicate that the placement of portal stents is a feasible procedure with potential efficacy. However, because of the concern of bleeding complications during the anticoagulation period and the potential risk of tumor dissemination during the stenting procedures, in addition to the complicated procedures involved, portal vein stenting has not gained wide acceptance among HCC experts.

## FUTURE PERSPECTIVES

### *The need for high-level evidence*

Conventionally, HCC with PVTT is considered to be an advanced disease with clinical management similar to HCC with extra-hepatic metastases. There are no dedicated clinical trials to study the treatment of this population. As a result, the efficacy and safety of different treatment modalities on PVTT are mainly generated from retrospective studies or extrapolated from subgroup analyses of prospective clinical trials. Currently, it is evident that the prognoses and disease behavior of patients with PVTT differ from those of patients without PVTT. In addition, patients with PVTT are more prone to develop complications due to portal hypertension or hepatic failure. Therefore, to define a better treatment strategy for patients with HCC with PVTT, dedicated clinical trials in this population are warranted. Because the prognoses differ between patients with different severities and degrees of PVTT, it is important to accurately gauge the outcome of patients during the design of clinical trials for HCC with PVTT. To achieve this goal, a uniform classification of PVTT is required for the stratification of risk groups during randomization and to facilitate the comparison of results between different studies. At present, at least three classifications have been developed for PVTT in HCC. It is crucial to reach consensus on the classification of PVTT amongst the HCC experts.

### *Multi-disciplinary approach*

Management of HCC with PVTT is a clinical dilemma with challenges. On one hand, despite the recommendation of sorafenib as the standard treatment for HCC with PVTT by the BCLC guidelines, emerging evidence clearly shows that select patients could benefit from more aggressive treatment approaches. On the other hand, not all patients may uniformly benefit from aggressive treatment. PVTT represents an adverse prognostic factor with an underlying more rapid disease course. Aggressive treatment may not lead to better outcomes in some patients; for example, in the setting of poor performance or with impaired hepatic function. Therefore, when facing patients with HCC with PVTT,



clinicians have to balance the potential benefits and toxicity of different treatments in the individual patients. A multi-disciplinary tumor board is required to determine the most appropriate management of patients with PVTT. Furthermore, the cumulative evidence indicates that a single treatment modality is unlikely to achieve a remarkable effect in PVTT, and the combination of different treatment modalities, such as RT to PVTT and TACE or the addition of SIRT to systemic agents, may be more efficacious in select patients. Future research should focus on combinations of different established treatment modalities for PVTT in HCC.

## CONCLUSION

The management of HCC with PVTT is evolving. The treatment modality for HCC with PVTT includes surgical resection, TACE, radiation therapy including external RT or SIRT of the liver lesions, and systemic agents, while portal vein stent treatment remains investigational. Dedicated clinical studies on HCC complicated with PVTT are inadequate. The decision of the optimal treatment for individual patients requires multi-disciplinary input. Future research should be geared towards the generation of high-level evidence of novel treatments and combinations of established treatments for this population.

## REFERENCES

- 1 **Roayaie S**, Blume IN, Thung SN, Guido M, Fiel MI, Hiotis S, Labow DM, Llovet JM, Schwartz ME. A system of classifying microvascular invasion to predict outcome after resection in patients with hepatocellular carcinoma. *Gastroenterology* 2009; **137**: 850-855 [PMID: 19524573 DOI: 10.1053/j.gastro.2009.06.003]
- 2 **Quirk M**, Kim YH, Saab S, Lee EW. Management of hepatocellular carcinoma with portal vein thrombosis. *World J Gastroenterol* 2015; **21**: 3462-3471 [PMID: 25834310 DOI: 10.3748/wjg.v21.i12.3462]
- 3 **Pirisi M**, Avellini C, Fabris C, Scott C, Bardus P, Soardo G, Beltrami CA, Bartoli E. Portal vein thrombosis in hepatocellular carcinoma: age and sex distribution in an autopsy study. *J Cancer Res Clin Oncol* 1998; **124**: 397-400 [PMID: 9719503]
- 4 **Chan SL**, Mo FK, Wong CS, Chan CM, Leung LK, Hui EP, Ma BB, Chan AT, Mok TS, Yeo W. A study of circulating interleukin 10 in prognostication of unresectable hepatocellular carcinoma. *Cancer* 2012; **118**: 3984-3992 [PMID: 22180222 DOI: 10.1002/ncr.26726]
- 5 **Llovet JM**, Bustamante J, Castells A, Vilana R, Ayuso Mdel C, Sala M, Brú C, Rodés J, Bruix J. Natural history of untreated nonsurgical hepatocellular carcinoma: rationale for the design and evaluation of therapeutic trials. *Hepatology* 1999; **29**: 62-67 [PMID: 9862851]
- 6 **Chan SL**, Mo FK, Johnson PJ, Liem GS, Chan TC, Poon MC, Ma BB, Leung TW, Lai PB, Chan AT, Mok TS, Yeo W. Prospective validation of the Chinese University Prognostic Index and comparison with other staging systems for hepatocellular carcinoma in an Asian population. *J Gastroenterol Hepatol* 2011; **26**: 340-347 [PMID: 21261725 DOI: 10.1111/j.1440-1746.2010.06329.x]
- 7 **Connolly GC**, Chen R, Hyrien O, Mantry P, Bozorgzadeh A, Abt P, Khorana AA. Incidence, risk factors and consequences of portal vein and systemic thromboses in hepatocellular carcinoma. *Thromb Res* 2008; **122**: 299-306 [PMID: 18045666]
- 8 **Huang J**, Deng Q, Wang Q, Li KY, Dai JH, Li N, Zhu ZD, Zhou B, Liu XY, Liu RF, Fei QL, Chen H, Cai B, Zhou B, Xiao HS, Qin LX, Han ZG. Exome sequencing of hepatitis B virus-associated hepatocellular carcinoma. *Nat Genet* 2012; **44**: 1117-1121 [PMID: 22922871 DOI: 10.1038/ng.2391]
- 9 **Tarantino L**, Francica G, Sordelli I, Esposito F, Giorgio A, Sorrentino P, de Stefano G, Di Sarno A, Ferraioli G, Sperlongano P. Diagnosis of benign and malignant portal vein thrombosis in cirrhotic patients with hepatocellular carcinoma: color Doppler US, contrast-enhanced US, and fine-needle biopsy. *Abdom Imaging* 2006; **31**: 537-544 [PMID: 16865315 DOI: 10.1007/s00261-005-0150-x]
- 10 **Piscaglia F**, Gianstefani A, Ravaioli M, Golfieri R, Cappelli A, Giampalma E, Sagrini E, Imbriaco G, Pinna AD, Bolondi L. Criteria for diagnosing benign portal vein thrombosis in the assessment of patients with cirrhosis and hepatocellular carcinoma for liver transplantation. *Liver Transpl* 2010; **16**: 658-667 [PMID: 20440775 DOI: 10.1002/lt.22044]
- 11 **Rammohan A**, Jeswanth S, Sukumar R, Anand L, Kumar PS, Srinivasan UP, Ravi R, Ravichandran P. Percutaneous ultrasound-guided fine-needle aspiration of portal vein thrombi as a diagnostic and staging technique for hepatocellular carcinoma. *Abdom Imaging* 2013; **38**: 1057-1060 [PMID: 23579929 DOI: 10.1007/s00261-013-9997-4]
- 12 **Rossi S**, Ghittoni G, Ravetta V, Torello Viera F, Rosa L, Serassi M, Scabini M, Vercelli A, Tinelli C, Dal Bello B, Burns PN, Calliada F. Contrast-enhanced ultrasonography and spiral computed tomography in the detection and characterization of portal vein thrombosis complicating hepatocellular carcinoma. *Eur Radiol* 2008; **18**: 1749-1756 [PMID: 18369630 DOI: 10.1007/s00330-008-0931-z]
- 13 **Kim JH**, Lee JM, Yoon JH, Lee DH, Lee KB, Han JK, Choi BI. Portal Vein Thrombosis in Patients with Hepatocellular Carcinoma: Diagnostic Accuracy of Gadoteric Acid-enhanced MR Imaging. *Radiology* 2016; **279**: 773-783 [PMID: 26780538 DOI: 10.1148/radiol.2015150124]
- 14 **Llovet JM**, Brú C, Bruix J. Prognosis of hepatocellular carcinoma: the BCLC staging classification. *Semin Liver Dis* 1999; **19**: 329-338 [PMID: 10518312]
- 15 **Kudo M**, Kitano M, Sakurai T, Nishida N. General Rules for the Clinical and Pathological Study of Primary Liver Cancer, Nationwide Follow-Up Survey and Clinical Practice Guidelines: The Outstanding Achievements of the Liver Cancer Study Group of Japan. *Dig Dis* 2015; **33**: 765-770 [PMID: 26488173 DOI: 10.1159/000439101]
- 16 **Kokudo N**, Hasegawa K, Akahane M, Igaki H, Izumi N, Ichida T, Uemoto S, Kaneko S, Kawasaki S, Ku Y, Kudo M, Kubo S, Takayama T, Tateishi R, Fukuda T, Matsui O, Matsuyama Y, Murakami T, Arii S, Okazaki M, Makuuchi M. Evidence-based Clinical Practice Guidelines for Hepatocellular Carcinoma: The Japan Society of Hepatology 2013 update (3rd JSH-HCC Guidelines). *Hepatol Res* 2015; **45** [PMID: 25625806 DOI: 10.1111/hepr.12464]
- 17 **Shi J**, Lai EC, Li N, Guo WX, Xue J, Lau WY, Wu MC, Cheng SQ. A new classification for hepatocellular carcinoma with portal vein tumor thrombus. *J Hepatobiliary Pancreat Sci* 2011; **18**: 74-80 [PMID: 20686792 DOI: 10.1007/s00534-010-0314-0]
- 18 **Xu JF**, Liu XY, Wang S, Wen HX. Surgical treatment for hepatocellular carcinoma with portal vein tumor thrombus: a novel classification. *World J Surg Oncol* 2015; **13**: 86 [PMID: 25889711 DOI: 10.1186/s12957-015-0493-x]
- 19 **Kumada K**, Ozawa K, Okamoto R, Takayasu T, Yamaguchi M, Yamamoto Y, Higashiyama H, Morikawa S, Sasaki H, Shimahara Y. Hepatic resection for advanced hepatocellular carcinoma with removal of portal vein tumor thrombi. *Surgery* 1990; **108**: 821-827 [PMID: 2173162]
- 20 **Tanaka A**, Morimoto T, Yamaoka Y. Implications of surgical treatment for advanced hepatocellular carcinoma with tumor thrombi in the portal vein. *Hepatogastroenterology* 1996; **43**: 637-643 [PMID: 8799408]
- 21 **Chok KS**, Cheung TT, Chan SC, Poon RT, Fan ST, Lo CM.

- Surgical outcomes in hepatocellular carcinoma patients with portal vein tumor thrombosis. *World J Surg* 2014; **38**: 490-496 [PMID: 24132826 DOI: 10.1007/s00268-013-2290-4]
- 22 **Wu CC**, Hsieh SR, Chen JT, Ho WL, Lin MC, Yeh DC, Liu TJ, P'eng FK. An appraisal of liver and portal vein resection for hepatocellular carcinoma with tumor thrombi extending to portal bifurcation. *Arch Surg* 2000; **135**: 1273-1279 [PMID: 11074879]
  - 23 **Ban D**, Shimada K, Yamamoto Y, Nara S, Esaki M, Sakamoto Y, Kosuge T. Efficacy of a hepatectomy and a tumor thrombectomy for hepatocellular carcinoma with tumor thrombus extending to the main portal vein. *J Gastrointest Surg* 2009; **13**: 1921-1928 [PMID: 19727969 DOI: 10.1007/s11605-009-0998-0]
  - 24 **Chan SC**, Liu CL, Lo CM, Lam CM, Poon RT, Yuen WK, Fan ST, Wong J. Value of live donor liver transplantation experience in major hepatectomy for hepatocellular carcinoma. *Arch Surg* 2003; **138**: 265-271 [PMID: 12611572]
  - 25 **Peng ZW**, Guo RP, Zhang YJ, Lin XJ, Chen MS, Lau WY. Hepatic resection versus transcatheter arterial chemoembolization for the treatment of hepatocellular carcinoma with portal vein tumor thrombus. *Cancer* 2012; **118**: 4725-4736 [PMID: 22359112 DOI: 10.1002/cncr.26561]
  - 26 **Ohkubo T**, Yamamoto J, Sugawara Y, Shimada K, Yamasaki S, Makuuchi M, Kosuge T. Surgical results for hepatocellular carcinoma with macroscopic portal vein tumor thrombosis. *J Am Coll Surg* 2000; **191**: 657-660 [PMID: 11129815]
  - 27 **Konishi M**, Ryu M, Kinoshita T, Inoue K. Surgical treatment of hepatocellular carcinoma with direct removal of the tumor thrombus in the main portal vein. *Hepatogastroenterology* 2001; **48**: 1421-1424 [PMID: 11677978]
  - 28 **Pawlik TM**, Poon RT, Abdalla EK, Ikai I, Nagorney DM, Belghiti J, Kianmanesh R, Ng IO, Curley SA, Yamaoka Y, Lauwers GY, Vauthey JN. Hepatectomy for hepatocellular carcinoma with major portal or hepatic vein invasion: results of a multicenter study. *Surgery* 2005; **137**: 403-410 [PMID: 15800485]
  - 29 **Ikai I**, Hatano E, Hasegawa S, Fujii H, Taura K, Uyama N, Shimahara Y. Prognostic index for patients with hepatocellular carcinoma combined with tumor thrombosis in the major portal vein. *J Am Coll Surg* 2006; **202**: 431-438 [PMID: 16500247]
  - 30 **Le Treut YP**, Hardwigen J, Ananian P, Saisse J, Grégoire E, Richa H, Campan P. Resection of hepatocellular carcinoma with tumor thrombus in the major vasculature. A European case-control series. *J Gastrointest Surg* 2006; **10**: 855-862 [PMID: 16769542]
  - 31 **Liu CL**, Fan ST. Nonresectional therapies for hepatocellular carcinoma. *Am J Surg* 1997; **173**: 358-365 [PMID: 9136797]
  - 32 **Ngan H**, Lai CL, Fan ST, Lai EC, Yuen WK, Tso WK. Treatment of inoperable hepatocellular carcinoma by transcatheter arterial chemoembolization using an emulsion of cisplatin in iodized oil and gelfoam. *Clin Radiol* 1993; **47**: 315-320 [PMID: 8389682 DOI: 10.1016/S0009-9260(05)81446-1]
  - 33 **O'Suilleabhain CB**, Poon RT, Yong JL, Ooi GC, Tso WK, Fan ST. Factors predictive of 5-year survival after transarterial chemoembolization for inoperable hepatocellular carcinoma. *Br J Surg* 2003; **90**: 325-331 [PMID: 12594668]
  - 34 **Yu SC**, Hui JW, Hui EP, Chan SL, Lee KF, Mo F, Wong J, Ma B, Lai P, Mok T, Yeo W. Unresectable hepatocellular carcinoma: randomized controlled trial of transarterial ethanol ablation versus transcatheter arterial chemoembolization. *Radiology* 2014; **270**: 607-620 [PMID: 24126369 DOI: 10.1148/radiol.13130498]
  - 35 **Llovet JM**, Bruix J. Systematic review of randomized trials for unresectable hepatocellular carcinoma: Chemoembolization improves survival. *Hepatology* 2003; **37**: 429-442 [PMID: 12540794 DOI: 10.1053/jhep.2003.50047]
  - 36 **Bruix J**, Sala M, Llovet JM. Chemoembolization for hepatocellular carcinoma. *Gastroenterology* 2004; **127**: S179-S188 [PMID: 15508083]
  - 37 **Lo CM**, Ngan H, Tso WK, Liu CL, Lam CM, Poon RT, Fan ST, Wong J. Randomized controlled trial of transarterial lipiodol chemoembolization for unresectable hepatocellular carcinoma. *Hepatology* 2002; **35**: 1164-1171 [PMID: 11981766]
  - 38 **Minagawa M**, Makuuchi M. Treatment of hepatocellular carcinoma accompanied by portal vein tumor thrombus. *World J Gastroenterol* 2006; **12**: 7561-7567 [PMID: 17171782 DOI: 10.3748/WJG.v12.i47.7561]
  - 39 **Yamada R**, Sato M, Kawabata M, Nakatsuka H, Nakamura K, Takashima S. Hepatic artery embolization in 120 patients with unresectable hepatoma. *Radiology* 1983; **148**: 397-401 [PMID: 6306721]
  - 40 **Leng JJ**, Xu YZ, Dong JH. Efficacy of transarterial chemoembolization for hepatocellular carcinoma with portal vein thrombosis: a meta-analysis. *ANZ J Surg* 2014; Epub ahead of print [PMID: 25088384 DOI: 10.1111/ans.12803]
  - 41 **Xue TC**, Xie XY, Zhang L, Yin X, Zhang BH, Ren ZG. Transarterial chemoembolization for hepatocellular carcinoma with portal vein tumor thrombus: a meta-analysis. *BMC Gastroenterol* 2013; **13**: 60 [PMID: 23566041 DOI: 10.1186/1471-230x-13-60]
  - 42 **Klein J**, Dawson LA. Hepatocellular carcinoma radiation therapy: review of evidence and future opportunities. *Int J Radiat Oncol Biol Phys* 2013; **87**: 22-32 [PMID: 23219567 DOI: 10.1016/j.ijrobp.2012.08.043]
  - 43 **Dawson LA**. Overview: Where does radiation therapy fit in the spectrum of liver cancer local-regional therapies? *Semin Radiat Oncol* 2011; **21**: 241-246 [PMID: 21939852 DOI: 10.1016/j.semradonc.2011.05.009]
  - 44 **Yoon SM**, Lim YS, Won HJ, Kim JH, Kim KM, Lee HC, Chung YH, Lee YS, Lee SG, Park JH, Suh DJ. Radiotherapy plus transarterial chemoembolization for hepatocellular carcinoma invading the portal vein: long-term patient outcomes. *Int J Radiat Oncol Biol Phys* 2012; **82**: 2004-2011 [PMID: 21621346 DOI: 10.1016/j.ijrobp.2011.03.019]
  - 45 **Zhang XB**, Wang JH, Yan ZP, Qian S, Du SS, Zeng ZC. Hepatocellular carcinoma with main portal vein tumor thrombus: treatment with 3-dimensional conformal radiotherapy after portal vein stenting and transarterial chemoembolization. *Cancer* 2009; **115**: 1245-1252 [PMID: 19156918 DOI: 10.1002/cncr.24139]
  - 46 **Katamura Y**, Aikata H, Takaki S, Azakami T, Kawaoka T, Waki K, Hiramatsu A, Kawakami Y, Takahashi S, Kenjo M, Toyota N, Ito K, Chayama K. Intra-arterial 5-fluorouracil/interferon combination therapy for advanced hepatocellular carcinoma with or without three-dimensional conformal radiotherapy for portal vein tumor thrombosis. *J Gastroenterol* 2009; **44**: 492-502 [PMID: 19330281 DOI: 10.1007/s00535-009-0033-y]
  - 47 **Toya R**, Murakami R, Baba Y, Nishimura R, Morishita S, Ikeda O, Kawanaka K, Beppu T, Sugiyama S, Sakamoto T, Yamashita Y, Oya N. Conformal radiation therapy for portal vein tumor thrombosis of hepatocellular carcinoma. *Radiation Oncol* 2007; **84**: 266-271 [PMID: 17716760 DOI: 10.1016/j.radonc.2007.07.005]
  - 48 **Kim DY**, Park W, Lim DH, Lee JH, Yoo BC, Paik SW, Kho KC, Kim TH, Ahn YC, Huh SJ. Three-dimensional conformal radiotherapy for portal vein thrombosis of hepatocellular carcinoma. *Cancer* 2005; **103**: 2419-2426 [PMID: 15822130 DOI: 10.1002/cncr.21043]
  - 49 **Kim TH**, Kim DY, Park JW, Kim YI, Kim SH, Park HS, Lee WJ, Park SJ, Hong EK, Kim CM. Three-dimensional conformal radiotherapy of unresectable hepatocellular carcinoma patients for whom transcatheter arterial chemoembolization was ineffective or unsuitable. *Am J Clin Oncol* 2006; **29**: 568-575 [PMID: 17148993 DOI: 10.1097/01.coc.0000239147.60196.11]
  - 50 **Lee JH**, Kim DH, Ki YK, Nam JH, Heo J, Woo HY, Kim DW, Kim WT. Three-dimensional conformal radiotherapy for portal vein tumor thrombosis alone in advanced hepatocellular carcinoma. *Radiat Oncol J* 2014; **32**: 170-178 [PMID: 25324989 DOI: 10.3857/roj.2014.32.3.170]
  - 51 **Rim CH**, Yang DS, Park YJ, Yoon WS, Lee JA, Kim CY. Effectiveness of high-dose three-dimensional conformal radiotherapy in hepatocellular carcinoma with portal vein thrombosis. *Jpn J Clin Oncol* 2012; **42**: 721-729 [PMID: 22689916 DOI: 10.1093/jcco/hys082]
  - 52 **Chuma M**, Taguchi H, Yamamoto Y, Shimizu S, Nakanishi M, Ogawa K, Sho T, Horimoto H, Kobayashi T, Nakai M, Terashita K, Sakuhara Y, Abo D, Tsukuda Y, Tsunematsu S,

- Hige S, Kato M, Shirato H, Asaka M. Efficacy of therapy for advanced hepatocellular carcinoma: intra-arterial 5-fluorouracil and subcutaneous interferon with image-guided radiation. *J Gastroenterol Hepatol* 2011; **26**: 1123-1132 [PMID: 21501224 DOI: 10.1111/j.1440-1746.2011.06745.x]
- 53 **Huang YJ**, Hsu HC, Wang CY, Wang CJ, Chen HC, Huang EY, Fang FM, Lu SN. The treatment responses in cases of radiation therapy to portal vein thrombosis in advanced hepatocellular carcinoma. *Int J Radiat Oncol Biol Phys* 2009; **73**: 1155-1163 [PMID: 18760547 DOI: 10.1016/j.ijrobp.2008.06.1486]
- 54 **Yamada K**, Izaki K, Sugimoto K, Mayahara H, Morita Y, Yoden E, Matsumoto S, Soejima T, Sugimura K. Prospective trial of combined transcatheter arterial chemoembolization and three-dimensional conformal radiotherapy for portal vein tumor thrombus in patients with unresectable hepatocellular carcinoma. *Int J Radiat Oncol Biol Phys* 2003; **57**: 113-119 [PMID: 12909223]
- 55 **Ishikura S**, Ogino T, Furuse J, Satake M, Baba S, Kawashima M, Nihei K, Ito Y, Maru Y, Ikeda H. Radiotherapy after transcatheter arterial chemoembolization for patients with hepatocellular carcinoma and portal vein tumor thrombus. *Am J Clin Oncol* 2002; **25**: 189-193 [PMID: 11943901]
- 56 **Tazawa J**, Maeda M, Sakai Y, Yamane M, Ohbayashi H, Kakinuma S, Miyasaka Y, Nagayama K, Enomoto N, Sato C. Radiation therapy in combination with transcatheter arterial chemoembolization for hepatocellular carcinoma with extensive portal vein involvement. *J Gastroenterol Hepatol* 2001; **16**: 660-665 [PMID: 11422619]
- 57 **Yu JI**, Park HC, Lim DH, Park W, Yoo BC, Paik SW, Koh KC, Lee JH. Prognostic index for portal vein tumor thrombosis in patients with hepatocellular carcinoma treated with radiation therapy. *J Korean Med Sci* 2011; **26**: 1014-1022 [PMID: 21860551 DOI: 10.3346/jkms.2011.26.8.1014]
- 58 **Sato K**, Lewandowski RJ, Bui JT, Omary R, Hunter RD, Kulik L, Mulcahy M, Liu D, Chrisman H, Resnick S, Nemcek AA, Vogelzang R, Salem R. Treatment of unresectable primary and metastatic liver cancer with yttrium-90 microspheres (TheraSphere): assessment of hepatic arterial embolization. *Cardiovasc Intervent Radiol* 2006; **29**: 522-529 [PMID: 16729228 DOI: 10.1007/s00270-005-0171-4]
- 59 **Coldwell D**, Sangro B, Wasan H, Salem R, Kennedy A. General selection criteria of patients for radioembolization of liver tumors: an international working group report. *Am J Clin Oncol* 2011; **34**: 337-341 [PMID: 20921882 DOI: 10.1097/COC.0b013e3181ec61bb]
- 60 **Kennedy A**, Nag S, Salem R, Murthy R, McEwan AJ, Nutting C, Benson A, Espat J, Bilbao JI, Sharma RA, Thomas JP, Coldwell D. Recommendations for radioembolization of hepatic malignancies using yttrium-90 microsphere brachytherapy: a consensus panel report from the radioembolization brachytherapy oncology consortium. *Int J Radiat Oncol Biol Phys* 2007; **68**: 13-23 [PMID: 17448867 DOI: 10.1016/j.ijrobp.2006.11.060]
- 61 **D'Avola D**, Lñarriraegui M, Bilbao JI, Martinez-Cuesta A, Alegre F, Herrero JI, Quiroga J, Prieto J, Sangro B. A retrospective comparative analysis of the effect of Y90-radioembolization on the survival of patients with unresectable hepatocellular carcinoma. *HepatoGastroenterology* 2009; **56**: 1683-1688 [PMID: 20214218]
- 62 **Hilgard P**, Hamami M, Fouly AE, Scherag A, Müller S, Ertle J, Heusser T, Cicinnati VR, Paul A, Bockisch A, Gerken G, Antoch G. Radioembolization with yttrium-90 glass microspheres in hepatocellular carcinoma: European experience on safety and long-term survival. *Hepatology* 2010; **52**: 1741-1749 [PMID: 21038413 DOI: 10.1002/hep.23944]
- 63 **Salem R**, Lewandowski RJ, Mulcahy MF, Riaz A, Ryu RK, Ibrahim S, Atassi B, Baker T, Gates V, Miller FH, Sato KT, Wang E, Gupta R, Benson AB, Newman SB, Omary RA, Abecassis M, Kulik L. Radioembolization for hepatocellular carcinoma using Yttrium-90 microspheres: a comprehensive report of long-term outcomes. *Gastroenterology* 2010; **138**: 52-64 [PMID: 19766639 DOI: 10.1053/j.gastro.2009.09.006]
- 64 **Sangro B**, Carpanese L, Cianni R, Golfieri R, Gasparini D, Ezziddin S, Paprottka PM, Fiore F, Van Buskirk M, Bilbao JI, Ettorre GM, Salvatori R, Giampalma E, Geatti O, Wilhelm K, Hoffmann RT, Izzo F, Iñarrairaegui M, Maini CL, Urigo C, Cappelli A, Vit A, Ahmadzadehfar H, Jakobs TF, Lastoria S. Survival after yttrium-90 resin microsphere radioembolization of hepatocellular carcinoma across Barcelona clinic liver cancer stages: a European evaluation. *Hepatology* 2011; **54**: 868-878 [PMID: 21618574 DOI: 10.1002/hep.24451]
- 65 **Ozkan ZG**, Poyanli A, Ucar A, Kuyumeu S, Akyuz F, Keskin S, Saglam S, Yilmaz E, Karaca C, Turkmen C. Favorable survival time provided with radioembolization in hepatocellular carcinoma patients with and without portal vein thrombosis. *Cancer Biother Radiopharm* 2015; **30**: 132-138 [PMID: 25760644 DOI: 10.1089/cbr.2014.1748]
- 66 **Edeline J**, Crouzet L, Campillo-Gimenez B, Rolland Y, Pracht M, Guillygomarc'h A, Boudjema K, Lenoir L, Adhoute X, Rohou T, Boucher E, Clément B, Blanc JF, Garin E. Selective internal radiation therapy compared with sorafenib for hepatocellular carcinoma with portal vein thrombosis. *Eur J Nucl Med Mol Imaging* 2016; **43**: 635-643 [PMID: 26455499 DOI: 10.1007/s00259-015-3210-7]
- 67 **She WH**, Cheung TT, Yau TC, Chan AC, Chok KS, Chu FS, Liu RK, Poon RT, Chan SC, Fan ST, Lo CM. Survival analysis of transarterial radioembolization with yttrium-90 for hepatocellular carcinoma patients with HBV infection. *Hepatobiliary Surg Nutr* 2014; **3**: 185-193 [PMID: 25202695 DOI: 10.3978/j.issn.2304-3881.2014.07.09]
- 68 **Chan SL**, Yeo W. Targeted therapy of hepatocellular carcinoma: present and future. *J Gastroenterol Hepatol* 2012; **27**: 862-872 [PMID: 22369685 DOI: 10.1111/j.1440-1746.2012.07096.x]
- 69 **Qin S**, Bai Y, Lim HY, Thongprasert S, Chao Y, Fan J, Yang TS, Bhudhisawasdi V, Kang WK, Zhou Y, Lee JH, Sun Y. Randomized, multicenter, open-label study of oxaliplatin plus fluorouracil/leucovorin versus doxorubicin as palliative chemotherapy in patients with advanced hepatocellular carcinoma from Asia. *J Clin Oncol* 2013; **31**: 3501-3508 [PMID: 23980077 DOI: 10.1200/JCO.2012.44.5643]
- 70 **Qin S**, Cheng Y, Liang J, Shen L, Bai Y, Li J, Fan J, Liang L, Zhang Y, Wu G, Rau KM, Yang TS, Jian Z, Liang H, Sun Y. Efficacy and safety of the FOLFOX4 regimen versus doxorubicin in Chinese patients with advanced hepatocellular carcinoma: a subgroup analysis of the EACH study. *Oncologist* 2014; **19**: 1169-1178 [PMID: 25223462 DOI: 10.1634/theoncologist.2014-0190]
- 71 **Chan SL**. Drug development for hepatocellular carcinoma: knowing the past helps to understand the future. *Oncologist* 2014; **19**: 1115-1117 [PMID: 25223461 DOI: 10.1634/theoncologist.2014-0304]
- 72 **Llovet JM**, Ricci S, Mazzaferro V, Hilgard P, Gane E, Blanc JF, de Oliveira AC, Santoro A, Raoul JL, Forner A, Schwartz M, Porta C, Zeuzem S, Bolondi L, Greten TF, Galle PR, Seitz JF, Borbath I, Häussinger D, Giannaris T, Shan M, Moscovici M, Voliotis D, Bruix J. Sorafenib in advanced hepatocellular carcinoma. *N Engl J Med* 2008; **359**: 378-390 [PMID: 18650514]
- 73 **Cheng AL**, Kang YK, Chen Z, Tsao CJ, Qin S, Kim JS, Luo R, Feng J, Ye S, Yang TS, Xu J, Sun Y, Liang H, Liu J, Wang J, Tak WY, Pan H, Burock K, Zou J, Voliotis D, Guan Z. Efficacy and safety of sorafenib in patients in the Asia-Pacific region with advanced hepatocellular carcinoma: a phase III randomised, double-blind, placebo-controlled trial. *Lancet Oncol* 2009; **10**: 25-34 [PMID: 19095497 DOI: 10.1016/S1470-2045(08)70285-7]
- 74 **Jeong SW**, Jang JY, Shim KY, Lee SH, Kim SG, Cha SW, Kim YS, Cho YD, Kim HS, Kim BS, Kim KH, Kim JH. Practical effect of sorafenib monotherapy on advanced hepatocellular carcinoma and portal vein tumor thrombosis. *Gut Liver* 2013; **7**: 696-703 [PMID: 24312711 DOI: 10.5009/gnl.2013.7.6.696]
- 75 **Sangro B**, Gomez-Martin C, de la Mata M, Iñarrairaegui M, Garralda E, Barrera P, Riezu-Boj JI, Larrea E, Alfaro C, Sarobe P, Lasarte JJ, Pérez-Gracia JL, Melero I, Prieto J. A clinical trial of CTLA-4 blockade with tremelimumab in patients with hepatocellular carcinoma and chronic hepatitis C. *J Hepatol* 2013; **59**: 81-88 [PMID: 23466307 DOI: 10.1016/j.jhep.2013.02.022]

- 76 **El-Khoueiry AB**, Melero I, Crocenzi TS, Welling TH, Yau TC, Yeo W, Chopra A, Grosso J, Lang L, Anderson J, Dela Cruz CM, Sangro B. Phase I/II safety and antitumor activity of nivolumab in patients with advanced hepatocellular carcinoma (HCC): CA209-040. *J Clin Oncol* 2015; **33** Suppl: abstr LBA101
- 77 **Chan SL**, Wong AM, Lee K, Wong N, Chan AK. Personalized therapy for hepatocellular carcinoma: Where are we now? *Cancer Treat Rev* 2016; **45**: 77-86 [PMID: 26995632 DOI: 10.1016/j.ctrv.2016.02.008]
- 78 **Yamakado K**, Tanaka N, Nakatsuka A, Matsumura K, Takase K, Takeda K. Clinical efficacy of portal vein stent placement in patients with hepatocellular carcinoma invading the main portal vein. *J Hepatol* 1999; **30**: 660-668 [PMID: 10207808]
- 79 **Vibert E**, Azoulay D, Cunha AS, Adam R, Samuel D, Castaing D. Portal stenting for hepatocellular carcinoma extending into the portal vein in cirrhotic patients. *J Surg Oncol* 2013; **107**: 696-701 [PMID: 23280593 DOI: 10.1002/jso.23306]
- 80 **Ikai I**, Kudo M, Arii S, Omata M, Kojiro M, Sakamoto M, Takayasu K, Hayashi N, Makuuchi M, Matsuyama Y, Monden M. Report of the 18th follow-up survey of primary liver cancer in Japan. *Hepatol Res* 2010; **40**: 1043-1059 [DOI: 10.1111/j.1872-034X.2010.00731.x]
- 81 **Luo J**, Guo RP, Lai EC, Zhang YJ, Lau WY, Chen MS, Shi M. Transarterial chemoembolization for unresectable hepatocellular carcinoma with portal vein tumor thrombosis: a prospective comparative study. *Ann Surg Oncol* 2011; **18**: 413-420 [PMID: 20839057 DOI: 10.1245/s10434-010-1321-8]
- 82 **Niu ZJ**, Ma YL, Kang P, Ou SQ, Meng ZB, Li ZK, Qi F, Zhao C. Transarterial chemoembolization compared with conservative treatment for advanced hepatocellular carcinoma with portal vein tumor thrombus: using a new classification. *Med Oncol* 2012; **29**: 2992-2997 [PMID: 22200992 DOI: 10.1007/s12032-011-0145-0]
- 83 **Kim JH**, Yoon HK, Kim SY, Kim KM, Ko GY, Gwon DI, Sung KB. Transcatheter arterial chemoembolization vs. chemoinfusion for unresectable hepatocellular carcinoma in patients with major portal vein thrombosis. *Aliment Pharmacol Ther* 2009; **29**: 1291-1298 [PMID: 19392861 DOI: 10.1111/j.1365-2036.2009.04016.x]

**P- Reviewer:** Cardinale V, Tchilikidi KY, Wei W, Zhang Q

**S- Editor:** Yu J **L- Editor:** A **E- Editor:** Ma S







Published by **Baishideng Publishing Group Inc**

8226 Regency Drive, Pleasanton, CA 94588, USA

Telephone: +1-925-223-8242

Fax: +1-925-223-8243

E-mail: [bpgooffice@wjgnet.com](mailto:bpgooffice@wjgnet.com)

Help Desk: <http://www.wjgnet.com/esps/helpdesk.aspx>

<http://www.wjgnet.com>



ISSN 1007-9327



9 771007 932045