

Simple objective criteria for diagnosis of causes of acute diarrhoea on rectal biopsy

D Jenkins, A Goodall, B B Scott

Abstract

Aim—To identify simple, objective, accurate histological criteria for distinguishing acute infective-type colitis, chronic idiopathic inflammatory bowel disease, and irritable bowel syndrome on rectal biopsy in patients with acute onset diarrhoea at first presentation, one to 10 weeks after onset.

Methods—Cell counts and measurements of mucosal architecture were made on initial rectal biopsies from 18 patients with acute infective-type colitis, 17 patients with first acute presentation of chronic idiopathic inflammatory bowel disease, and 23 patients with irritable bowel syndrome. The data were analysed by ANOVA and discriminant analysis.

Results—Lamina propria cells were mainly in the upper third in irritable bowel syndrome patients. Increased lamina propria cellularity, mainly in the middle third, and numbers of crypt intraepithelial neutrophils distinguished acute infective-type colitis from irritable bowel syndrome in 93% of cases. Chronic idiopathic inflammatory bowel disease differed from irritable bowel syndrome and acute infective-type colitis in a decreased number of crypts and altered crypt architecture. Chronic idiopathic inflammatory bowel disease showed higher lamina propria cellularity, especially in the basal third, with an increased number of lamina propria neutrophils. On discriminant analysis, crypt numbers distinguished 86% of the cases of chronic idiopathic inflammatory bowel disease from the other groups.

Conclusion—At one week or more from onset, acute infective-type colitis is characterised by a superficial increase in lamina propria cellularity, with only a slight increase in the number of polymorphs. At this stage, chronic idiopathic inflammatory bowel disease is characterised by a transmucosal increase in cellularity together with crypt loss and architectural abnormality. Thus, measurement of mucosal architecture establishes simple, accurate, objective criteria for routine biopsy diagnosis of chronic idiopathic inflammatory bowel disease from acute infective-type colitis and irritable bowel syndrome at initial presentation, one to 10 weeks after onset. (*J Clin Pathol* 1997;50:580-585)

Keywords: chronic idiopathic inflammatory bowel disease; infective colitis; biopsy diagnosis

The differential diagnosis of the causes of acute diarrhoea includes infective-type colitis, chronic idiopathic inflammatory bowel disease, and irritable bowel syndrome. Usually, the colorectal mucosa in irritable bowel syndrome is regarded as histologically normal for inflammation and architecture. Rectal biopsy is used routinely to detect clinically important inflammation and distinguish acute infective-type colitis from chronic idiopathic inflammatory bowel disease.¹ The histological features of different types of infective colitis and of antibiotic associated colitis have been described.²⁻⁴ Many of the features used to diagnose acute infective-type colitis and chronic idiopathic inflammatory bowel disease in routine diagnostic practice are not reproducible or accurate.^{5,6} Specific histological criteria have not been identified for acute infective-type colitis,⁷⁻⁹ although abnormal mucosal architecture and some inflammatory features have been found to distinguish chronic idiopathic inflammatory bowel disease from acute infective-type colitis and normality in some studies.⁵⁻¹³

Previously, we reported the accuracy of quantitative histology in separating chronic idiopathic inflammatory bowel disease from irritable bowel syndrome on rectal biopsy using the increased cellularity in the basal third of the lamina propria, surface irregularity, and surface epithelial flattening.¹² The present study was performed to obtain additional, objective histological criteria for routine use in the differential diagnosis of acute diarrhoea, including the problem of identifying acute infective-type colitis. Counts and measurements were made on rectal biopsy specimens from groups of patients with acute infective-type colitis, with acute presentation of chronic idiopathic inflammatory bowel disease confirmed by subsequent follow-up, and with irritable bowel syndrome. Statistically significant differences between the groups were investigated further using discriminant analysis to identify diagnostic criteria.

Methods

The study was a retrospective study of patients presenting in routine practice to the Gastroenterology Clinic at Lincoln County District General Hospital.

Division of Pathology,
Queen's Medical
Centre, Nottingham,
UK

D Jenkins

Department of
Medicine, County
Hospital, Lincoln, UK
A Goodall
B B Scott

Correspondence to:
Dr Jenkins, Division of
Pathology, Queen's Medical
Centre, Nottingham
NG7 2UH, UK.

Accepted for publication
8 April 1997

Table 1 Measurements used in the analyses

Abbreviations	Measurement
CIE	Crypt intraepithelial neutrophils per 10 crypts
CLUM	Crypt lumen neutrophils per 10 crypt lumens
LPP	Lamina propria neutrophils/mm mucosal length
CELLEN	Total lamina propria cells/mm mucosal length
HCDENSI, 2, 3	Total cell densities in superficial, middle, and basal bands of lamina propria, respectively
HCDRAT	Total cell density in superficial, horizontal band of lamina propria/density in basal band
SLR	Measured surface length/smoothed surface length
MHMEAN	Mean of mucosal height measurements
CRYPTS	Number of crypts/mm surface length
CLMEAN	Mean of crypt length measurements
ICDMEAN	Mean of intercrypt distance measurements

PATIENTS

Irritable bowel syndrome

Twenty three patients with acute presentation of diarrhoea. There were nine men and 14 women, median age 31 years (range 20–73), considered to have irritable bowel syndrome by standard criteria and no relevant organic disease at presentation or disclosed on follow up for at least five years.

Acute presentation of first onset of chronic idiopathic inflammatory bowel disease

Seventeen patients with a total history up to the biopsy of less than 10 weeks (median five weeks). There were nine men and eight women, median age 38 years (range 18–75). All had subsequent follow up of at least three years. Six patients had a final diagnosis of ulcerative colitis (four men, two women) with typical sigmoidoscopic appearances and disease above the sigmoid colon. Four had Crohn's colitis (two men, two women). The final diagnosis was based on characteristic histology and typical radiological appearances. Six had distal proctosigmoiditis (two men, four women) with sigmoidoscopically continuous disease. In three patients the disease extended into the sigmoid colon but not into the descending colon. One man had chronic idiopathic inflammatory bowel disease of indeterminate type with no firm diagnosis of Crohn's disease or ulcerative colitis.

Acute infective-type colitis

Eighteen patients with acute diarrhoea. There were 10 men and eight women, median age 51 years (range 21–80). All had a stool culture: five were positive for salmonella, four for campylobacter, four for *Clostridium difficile*, and one for *Yersinia* spp. Four had antibiotic associated diarrhoea, which was self-limiting and was presumed to be infective, although *C difficile* culture was not performed. The median duration of disease was two weeks (range one to eight).

PROCEDURE

Formalin fixed rectal biopsy specimens taken during routine management were embedded

into paraplast and cut at 1 µm thickness perpendicular to the mucosal surface. Sections were stained with haematoxylin and eosin. Measurements and cell counts were carried out on the stained sections using a MOPPET image analyser. All processing, measurements, and counts were performed without knowledge of the diagnostic group to minimise experimental and observer bias. The method has been described in detail previously.¹² The measurements are shown in table 1. None of the biopsies showed granulomas or giant cells and these, therefore, were not studied further as diagnostic criteria.

STATISTICAL ANALYSIS

The measurements were log transformed when necessary to normalise the distribution. The Mann-Whitney U test was used to compare age and duration of disease. All other analyses were carried out on the Amdahl computer at the University College (London) Computer Centre using package BMDP (University of California, 1985). Comparison by ANOVA and discriminant analysis were performed. Discriminant analysis (BMDP7D) computes a linear classification for each of the selected groups in a stepwise manner; at each step the variable that adds most to the separation of the groups is entered into the function. A "jack-knife" procedure was then used. This procedure simulates a separate dataset by removing one case, using all the remaining cases to produce a discriminant function, and then classifying the excluded case with this function. The whole process is repeated for each case in the set.

Results

Table 2 shows the results of selected measurements for each diagnostic group with statistically significant differences between the groups.

ACUTE INFECTIVE-TYPE COLITIS VERSUS IRRITABLE BOWEL SYNDROME

In acute infective-type colitis there was increased lamina propria cellularity compared with irritable bowel syndrome. In all cases of irritable bowel syndrome cell density was greatest in the superficial third of the lamina propria compared with the middle or basal thirds. This pattern usually is considered normal. In acute infective-type colitis the increased lamina propria cellularity was in the middle third or the basal third. The increase was usually less than twofold. Importantly, in 95% of the cases of acute infective-type colitis the cell density was greater in the upper two-thirds of the lamina propria compared to the basal third (fig 1).

Neutrophil counts were increased in the crypt epithelium and lamina propria in acute infective-type colitis compared with irritable bowel syndrome. Some increase in the number of crypt intraepithelial neutrophils (> 10 per crypt lumen over 10 crypt lumens) was seen in 39% of acute infective-type colitis compared with 4% of irritable bowel syndrome, and small numbers of intraluminal neutrophils (> 10 per

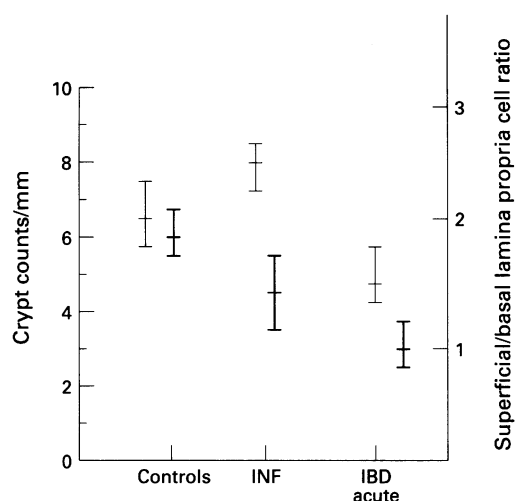


Figure 1 Bar chart showing median and 95% confidence limits of measurements of superficial/basal lamina propria cell density (thick lines) (HCDRAT) and crypt counts per millimetre surface (thin lines) (CRYPTS). Controls, irritable bowel disease patients; INF, acute infective-type colitis; IBD, chronic idiopathic inflammatory bowel disease.

crypt lumen over 10 crypt lumens) were present in 17% of acute infective-type colitis but not in irritable bowel syndrome. Surface intraepithelial neutrophils were increased in only a few acute infective-type colitis cases.

In discriminant analysis, total lamina propria cellularity was the most important variable distinguishing acute infective-type colitis from irritable bowel syndrome, with crypt intraepithelial neutrophils also making a contribution. On jack-knife testing a discriminant function derived from these correctly classified 93% of cases.

CHRONIC IDIOPATHIC INFLAMMATORY BOWEL DISEASE VERSUS ACUTE INFECTIVE-TYPE COLITIS AND IRRITABLE BOWEL SYNDROME

In chronic idiopathic inflammatory bowel disease lamina propria cellularity was increased two- to threefold compared with irritable bowel syndrome and was up to twofold greater than in acute infective-type colitis. The increase was most marked in the basal third compared with both irritable bowel syndrome and acute infective-type colitis (fig 1).

There was a reduction in crypt numbers per millimetre of surface epithelium in chronic idiopathic bowel disease, with significant differences in intercrypt distance and crypt volume.

The measures of crypt and mucosal architectural change correlated highly. In discriminant analysis, crypt counts alone classified 86% of cases of acute infective-type colitis and chronic idiopathic inflammatory bowel disease correctly (fig 1).

Although lamina propria counts of up to 100/mm were found frequently (83%) in acute infective-type colitis, very high counts of lamina propria polymorphs (> 1000/mm), crypt intraepithelial neutrophils (> 10 per crypt over 10 crypts) and crypt lumen neutrophils (> 10 per crypt lumen over 10 crypt lumens) were infrequent (6%, 12%, and 7%, respectively) but unique features of chronic idiopathic inflammatory bowel disease.

Discussion

The study defined objective, histological features that distinguished accurately acute infective-type colitis, chronic idiopathic inflammatory bowel disease, and irritable bowel syndrome in colorectal biopsies taken at first presentation from patients with acute onset diarrhoea. The cases studied represent routine, British district hospital practice and reflect the usual time of presentation after onset of symptoms of patients with acute infective-type colitis (median two weeks), and chronic idiopathic inflammatory bowel disease (median five weeks). In this type of referral practice very few patients are seen in the first week of acute diarrhoea. Other studies of patients during the very early stage of acute colitis have suggested that the architectural changes described here in acute onset chronic idiopathic bowel disease may not be present during the first week.^{14 15} Also, more intense acute inflammation with erosion and ulceration has been described in acute infective-type colitis during the very early phase.²⁻⁴ The findings of this study, therefore, apply to biopsy diagnosis of colorectal biopsies taken for the investigation of suspected chronic idiopathic inflammatory bowel disease of acute onset in routine practice at one to 10 weeks after onset. The purpose of this study was not to separate Crohn's disease from ulcerative colitis, as clinical management at this stage is determined mainly by the need to separate chronic idiopathic inflammatory bowel disease from acute infective-type colitis, and from functional causes of diarrhoea (irritable bowel syndrome). The distinction of Crohn's disease

Table 2 Derived means and 95% confidence limits (CL) for measurements in each diagnostic group

Variable	Controls (IBS) (n=23)		Acute infective-type colitis (AIC) (n=18)			Chronic idiopathic inflammatory bowel disease (n=17)			
	95% CL	Mean	96% CL	Mean	p value (v IBS)	95% CL	Mean	p value (v IBS)	p value (v AIC)
CIE	0-2	1	3-14	7	<0.001	10-59	25	<0.001	
CLUM	0-1	0	0-14	1		1-5	3	<0.01	
LPP	8-14	11	31-93	53	<0.001	86-269	160	<0.001	<0.05
CELLEN	1255-1490	1368	1885-2622	2223	<0.001	2675-3999	3271	<0.001	<0.01
HCDENS1	6695-8915	7727	7459-9984	8630		6900-9484	8089		
HCDENS2	4587-6287	5370	7502-9568	8472	<0.001	7834-9913	8812	<0.001	
HCDENS3	3656-4820	4198	5369-7702	6427	<0.001	7661-10150	8818	<0.001	<0.05
HCDRAT	1.73-2.01	1.87	1.16-1.72	1.44	<0.05	0.82-1.009	0.96	<0.001	<0.01
SLR	1.04-1.06	1.05	1.05-1.11	1.08		1.08-1.16	1.12	<0.01	
MHMEAN	369-427	398	436-528	482	<0.01	517-628	572	<0.001	
CRYPTS	5.8-7.5	6.6	7.3-8.3	7.8		4.1-5.3	4.7	<0.001	<0.001
CLMEAN	333-378	356	385-474	430	<0.05	451-569	497	<0.001	
ICDMEAN	28-38	32	24-33	29		39-58	48	<0.001	<0.001

IBS, irritable bowel syndrome.

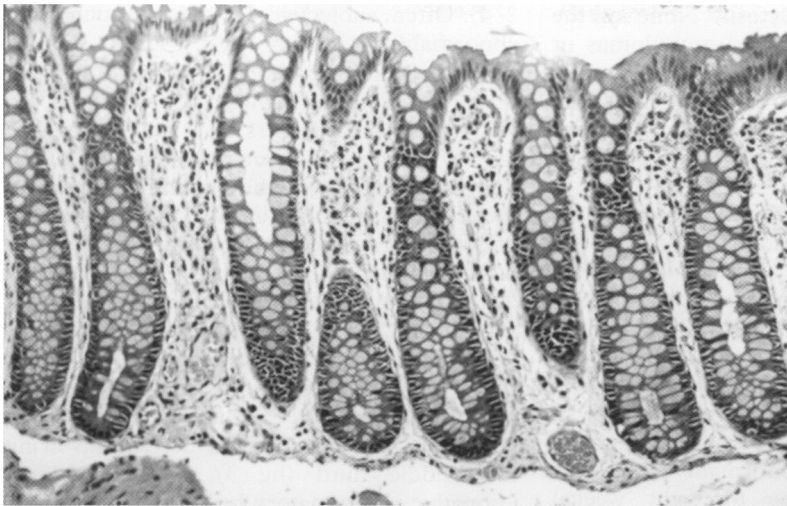


Figure 2 Irritable bowel syndrome showing the superficial distribution of cells in the upper third of the lamina propria. Note also the "test-tube rack" arrangement of crypts.

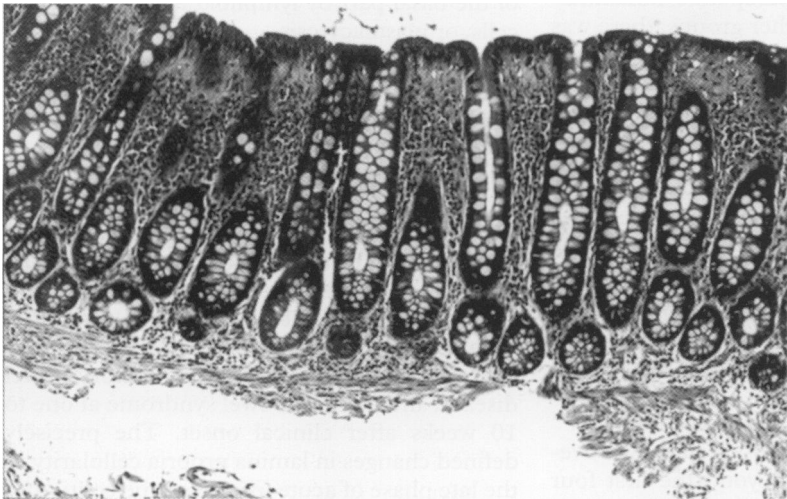


Figure 3 Acute infective-type colitis showing a twofold increase in cells in the mid-zone of the lamina propria. This produces the appearance of a "mild superficial increase in chronic inflammation".

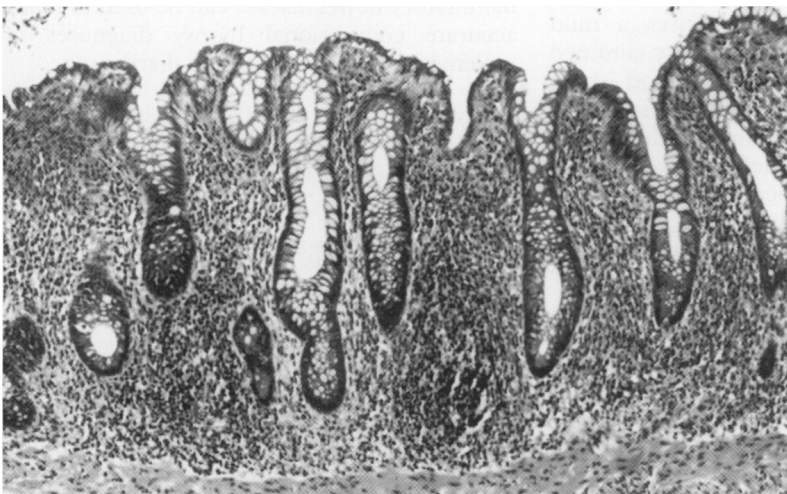


Figure 4 Chronic idiopathic inflammatory bowel disease. Crohn's disease showing increased cellularity in the basal third of the lamina propria. This produces the appearance of a "moderate or severe transmucosal increase in chronic inflammation".

from ulcerative colitis becomes important in any subsequent surgical management. The measurements used to distinguish chronic idiopathic inflammatory bowel disease from acute infective-type colitis have been shown previously to identify both Crohn's disease and ulcerative colitis.¹²

The biopsy appearances of irritable bowel syndrome usually are considered "normal". Irritable bowel syndrome was used in this study as the "control" group because it comprises the main group of individuals who can present with acute diarrhoea and initially are suspected of having the diseases studied but turn out not to have acute colitis or any other organic disease. The main objective differences identified by discriminant analysis between acute infective-type colitis and normal/irritable bowel syndrome are increased lamina propria cellularity and numbers of neutrophils in acute infective-type colitis. In normal/irritable bowel syndrome the maximal lamina propria cellularity was beneath the surface epithelium in the upper third (figs 1 and 2). This distribution was altered in acute infective-type colitis by a mild (up to twofold) increase, affecting mainly the middle third giving a "mild superficial increase in lamina propria cellularity" in 95% of cases (figs 1 and 3). The main differences identified between chronic idiopathic inflammatory bowel disease and acute infective-type colitis or normal/irritable bowel syndrome were both features that are typical of chronic idiopathic inflammatory bowel disease: reduced crypt numbers (which correlate with architectural irregularity) and a two- or threefold increase in cellularity in the basal third of the lamina propria, producing a "moderate or severe transmucosal increase in lamina propria cellularity" (figs 1 and 4).

Numbers of neutrophils provided some additional discrimination between acute infective-type colitis and irritable bowel syndrome. There were very few in irritable bowel syndrome/normal, with an upper 95% confidence limit of fewer than two neutrophils per 10 crypts. Neutrophils were increased in acute infective-type colitis and in chronic idiopathic inflammatory bowel disease. However, very high lamina propria neutrophil counts, severe cryptitis, and crypt abscesses (as defined above) were found only (and infrequently) in chronic idiopathic inflammatory bowel disease. The relatively low neutrophil counts in acute infective-type colitis in this study may reflect the late presentation (one to eight weeks after onset) in these patients. Biopsies taken during the first few days of a severe acute infective episode may show much heavier neutrophil infiltration.^{2-4 8}

Generally, there is good agreement between the findings of this study and studies of conventional biopsy diagnosis.^{5-9 11-16} Both approaches suggest that distorted crypt architecture, crypt atrophy, and mixed lamina propria inflammation are important distinguishing features of chronic idiopathic inflammatory bowel disease. Previously, we have identified the importance of the diffuse transmucosal increase in lamina propria cellularity for distinguishing chronic idiopathic inflammatory bowel disease from normal/irritable bowel syndrome cases. Other studies have drawn attention to different patterns of increased basal cellularity in diagnosing chronic idiopathic inflammatory bowel disease.^{5 7 9 11-13} These include basal lymphoid aggregates, basal giant

cells, and basal plasmacytosis. None of the biopsies in this study showed granulomas or giant cells. Although both are reported as specific diagnostic features in other series, their absence in this series confirms their poor diagnostic sensitivity.

We agree with the conclusions of Surawicz and Belic⁷ and Allison *et al*⁹ that normal crypt architecture is an important feature distinguishing acute infective-type colitis from chronic idiopathic inflammatory bowel disease, even at acute, first onset. Our study did not find any evidence in the British population of distorted crypt architecture in acute infective-type colitis comparable to that reported in Indian patients with shigellosis or any increase in crypt architectural abnormality with time during the period (one to eight weeks) studied.^{17, 18} Although the extremes of the ranges of architectural measurements approximated between chronic idiopathic inflammatory bowel disease and other groups, there was minimal overlap. Our data suggest that most patients who subsequently are proven to have chronic idiopathic inflammatory bowel disease have abnormal crypt architecture within a few weeks of initial clinical onset. Comparison between acute chronic idiopathic inflammatory bowel disease at first onset and its more chronic form showed that the decrease in crypt numbers was similar to that reported previously in longstanding chronic idiopathic inflammatory bowel disease with no correlation between the duration of disease and crypt response.

The series agrees with other studies^{1, 7, 9, 11} that it is possible to diagnose acute infective-type colitis by histology beyond the first four days as proposed by Nostrant *et al* and suggests that there is a characteristic histological pattern in the late/resolving phase of acute infective-type colitis (one to eight weeks).⁸ This late phase diagnostic pattern comprises a mild increase in lamina propria cellularity confined mainly to the upper two-thirds and slight increases in neutrophil numbers in crypt epithelium and lamina propria. The late phase pattern is that seen routinely in UK practice and may explain the appearance reported by some pathologists as "non-specific proctitis or colitis".⁵ It is possible that many patients labelled as having "non-specific inflammation" have resolving acute infective-type colitis. Understanding the time sequence of the evolution of acute infective-type colitis and chronic idiopathic inflammatory bowel disease together with the use of better criteria to separate irritable bowel syndrome, acute infective-type colitis, and chronic idiopathic inflammatory bowel disease should reduce the need for this unsatisfactory "non-specific" category.

The objective changes described can be used to refine conventional histopathological diagnosis. Crypt architectural abnormality can be detected by conventional microscopy as change from the straight, close-packed, parallel, "test-tube rack" arrangement of crypts in irritable bowel syndrome or acute infective-type colitis to the fewer, irregular crypts of chronic idiopathic inflammatory bowel disease (figs

2–4). Often, subjective detection of such crypt abnormalities is not easy.⁶ Crypt counts provide an easy accurate alternative and can be made directly using a microscope micrometer. A reduction in numbers of crypt openings to five or fewer per millimetre of surface epithelium measured along one 3 mm of surface epithelium in a single section was pathognomonic of chronic idiopathic inflammatory bowel disease (fig 1).

The pattern of lamina propria cellularity (fig 1) usually can be detected easily in conventional examination. In normal/irritable bowel syndrome the cells are mostly in the upper third (fig 2). In acute infective-type colitis usually there is a mild superficial increase, involving the middle third (fig 3), and in chronic idiopathic inflammatory bowel disease there is either a moderate or severe transmucosal increase (fig 4) in active disease or involvement of the basal part by lymphoid aggregates, giant cells, or plasmacytosis.

Polymorph numbers are useful in distinguishing normal/irritable bowel syndrome from active inflammation but need to be interpreted carefully in attempting to separate acute infective-type colitis and chronic idiopathic inflammatory bowel disease. There is a wide overlap and any diagnostic differences depend on the timing of the biopsy in relation to presence and onset of clinical activity.

Precise measurement has refined diagnostic criteria for distinguishing acute infective-type colitis, chronic idiopathic inflammatory bowel disease, and irritable bowel syndrome at one to 10 weeks after clinical onset. The precisely defined changes in lamina propria cellularity in the late phase of acute infective-type colitis and in chronic idiopathic inflammatory bowel disease, and the reduced crypt numbers and altered architecture in chronic idiopathic inflammatory bowel disease can be used to make accurate conventional biopsy diagnoses of patients presenting with acute diarrhoea.

We are grateful to the National Association for Colitis and Crohn's Disease for financial support. We also thank Mr P M Stephenson for technical help.

- 1 Surawicz CM. Diagnosing colitis: biopsy is best. *Gastroenterology* 1987;92:538–40.
- 2 Price AB, Jewkes J, Sanderson PJ. Acute diarrhoea, *Campylobacter colitis* and the role of rectal biopsy. *J Clin Pathol* 1979;32:990–7.
- 3 Price AB, Day DW. Pseudomembranous and infective colitis. In: Anthony PP, MacSween RN M, eds. *Recent advances in histopathology 11*. Edinburgh: Churchill-Livingstone, 1981:99–117.
- 4 Talbot IC, Price AB. *Biopsy pathology in colorectal disease*. London: Chapman & Hall Medical, 1987.
- 5 Theodossi A, Spiegelhalter DJ, Jass J, Firth J, Dixon M, Leader M, *et al*. Observer variation and discriminatory value of biopsy features in inflammatory bowel disease. *Gut* 1994;35:961–8.
- 6 Cooke MG, Dixon MF. An analysis of the reliability of detection and diagnostic value of various pathological features in Crohn's disease and ulcerative colitis. *Gut* 1973;14:255–62.
- 7 Surawicz CM, Belic L. Rectal biopsy helps to distinguish acute self-limited colitis from idiopathic inflammatory bowel disease. *Gastroenterology* 1984;86:104–13.
- 8 Nostrant TT, Kumar NB, Appelman HD. Histopathology differentiates acute self-limited colitis from ulcerative colitis. *Gastroenterology* 1987;92:318–28.
- 9 Allison MC, Hamilton-Dutoit SJ, Dhillon AP, Pounder RE. The value of rectal biopsy in distinguishing self-limited colitis from early inflammatory bowel disease. *Quar J Med* 1987;65:985–95.

- 10 Thompson EM, Price AB, Altman DG, Sowter C, Slavin G. Quantitation in inflammatory bowel disease using computerised interactive image analysis. *J Clin Pathol* 1985;38:631-8.
- 11 Surawicz CM, Haggitt RC, Husseman M, McFarland LV. Mucosal biopsy diagnosis of colitis: acute self-limited colitis and idiopathic inflammatory bowel disease. *Gastroenterology* 1994;107:755-63.
- 12 Jenkins D, Goodall A, Drew K, Scott BB. What is colitis? Statistical approach to distinguishing clinically important inflammatory bowel change in rectal biopsy specimens. *J Clin Pathol* 1988;41:82-9.
- 13 Seldenrijk CA, Morson BC, Meuwissen SGM, Schipper NW, Lindeman J, Meijer CJLM. Histopathological evaluation of colonic mucosal biopsy specimens in chronic inflammatory bowel disease: diagnostic implications. *Gut* 1991;32:1514-20.
- 14 Schumacher G. First attack of inflammatory bowel disease and infectious colitis. *Scand J Gastroenterol* 1993;28(suppl 198):1-24.
- 15 Therkildsen MH, Jensen BN, Tegibjaerg PS, Rasmussen SN. The final outcome of patients presenting with their first episode of acute diarrhoea and an inflamed rectal mucosa with preserved crypt architecture. A clinicopathologic study. *Scand J Gastroenterol* 1989;24:158-64.
- 16 Kumar NB, Nostrant TT, Appleman HD. The histopathologic spectrum of acute self-limited colitis (acute infectious-type colitis). *Am J Surg Pathol* 1982;6:523-9.
- 17 Anand BS, Malhotra V, Battacharya SK, Datta P, Datta D, Sen D, *et al*. Rectal histology in acute bacillary dysentery. *Gastroenterology* 1986;90:654-60.
- 18 Mathan MM, Mathan VI. Morphology of rectal mucosa of patients with shigellosis. *Rev Infect Dis* 1991;13(suppl 4):S314-18.