

Treatment of benign prostatic hyperplasia with 5- α -reductase inhibitor: morphological changes in patients who fail to respond

R Montironi, M Valli, G Fabris

Abstract

Aims—To describe the prostatic adenectomy specimens of six patients with symptomatic benign prostatic hyperplasia (BPH) who failed to respond to long term treatment with a 5- α -reductase inhibitor, finasteride.

Methods—Histological sections from six cases of BPH who had been treated with finasteride were investigated. Five patients were prescribed 5 mg finasteride daily for six months and one patient 5 mg daily for 12 months. The patients underwent adenectomy as their urethral obstruction failed to resolve. Twenty cases of untreated BPH served as controls.

Results—In patients taking finasteride for six months the prostatic adenectomy specimens showed a reduction in the size of the prostate and an increase in the stroma:epithelial and stroma:lumen ratios compared with controls. The size of the ducts and acini was not as uniform as in the controls. In particular, some ducts and acini were still lined by a bistratified epithelium similar to that found in controls but lacked undulations at the epithelial border; other ducts/acini were atrophic. Some scattered clusters of small acini with a focally fragmented basal cell layer were observed in two of the five treated cases. One prostatic adenectomy specimen, from the patient treated for one year, showed extensive lobular atrophy and diffuse squamous and transitional cell metaplasia. At the periphery of the transition zone, there was a complex intra-acinar papillary-cribriform proliferation of clear cells without nuclear atypia, similar to clear cell papillary hyperplasia. The periurethral region showed stromal nodules in both patients and controls.

Conclusions—Morphological evaluation of finasteride treated BPH showed changes in the lobules of the transition zone, but not in the periurethral stroma.

(J Clin Pathol 1996;49:324-328)

Keywords: benign prostatic hyperplasia, finasteride, 5- α -reductase, postatrophic hyperplasia, clear cell papillary hyperplasia.

Benign prostatic hyperplasia (BPH) arises within the transition zone of the prostate, including the periurethral region.¹ Most of the periurethral nodules are pure stromal nodules, reminiscent of embryonic mesenchyme. In the transition zone, however, almost all of the nod-

ules are glandular from their inception. The hyperplastic glands differ from the surrounding transition zone tissue only in their architectural arrangement. Nodules arise by the budding of new small glands from pre-existing ducts and acini.¹ The resulting enlargement of the prostate gland often leads to urethral obstruction and even complete urinary retention.^{2,3}

Androgens are required to maintain the size and function of the prostate.^{2,4,5} The androgen primarily responsible for prostatic growth and enlargement is dihydrotestosterone (DHT).² DHT, converted from testosterone by the enzyme 5- α -reductase, is also thought to be the major factor in the development of BPH. Selective inhibition of 5- α -reductase is considered to be an effective treatment for BPH, without causing severe androgen deficiency effects in other tissues.³ Some reports have proposed that the administration of a competitive inhibitor of 5- α -reductase, such as finasteride, can cause a decrease in the size of the prostate by an order of magnitude similar to that seen in androgen ablation with luteinising hormone-releasing hormone analogs or flutamide administration, or both.^{6,7} In fact, a significant decrease in the symptoms of obstruction, including increased urinary flow, and in prostatic volume has been observed in many patients.⁶ The effects of finasteride are thought to be the result of involution of the prostatic epithelium,^{6,7} as described recently by Cohen *et al*,⁸ Juniewicz *et al*⁹ and Prahallada *et al*¹⁰ in the rat and canine prostate, respectively. However, to the best of our knowledge, no previous detailed morphological description of 5- α -reductase inhibition in human prostate has been published before.

The purpose of this study was to describe the prostatectomy specimens of six patients with symptomatic BPH who failed to respond to long term treatment with finasteride.

Methods

Histological sections from six consecutive cases of BPH who had been treated with finasteride were retrieved from the files of the Institute of Pathological Anatomy, Ancona University. Five patients were prescribed 5 mg finasteride daily for six months and one patient 5 mg daily for 12 months. All six patients underwent prostatic adenectomy (simple prostatectomy) as their urethral obstruction failed to resolve. Prostatic adenectomy was carried out while the patients were still receiving therapy. Twenty cases of untreated BPH served as controls. None of

The content of this paper was discussed at the Recent Advances in Chemoprevention of Preinvasive Neoplasia course, Ancona, Italy, April 4-6, 1995.

Institute of Pathological Anatomy and Histopathology, School of Medicine, University of Ancona, Nuovo Ospedale Regionale, Via Conca, I-60020 Torrette di Ancona, Ancona, Italy
R Montironi
M Valli
G Fabris

Correspondence to: Professor R Montironi.

Accepted for publication 5 January 1996

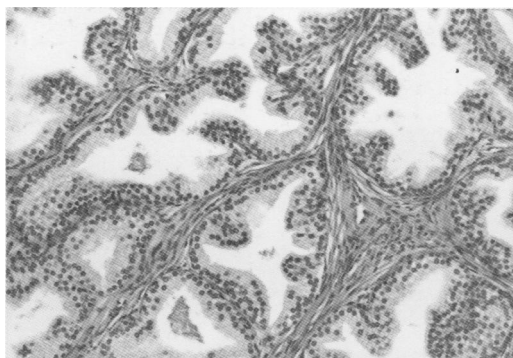


Figure 1 Untreated BPH (haematoxylin and eosin, $\times 16$).

the patients in either group had evidence of prostatic cancer, urinary tract infection, chronic prostatitis, or a neurogenic bladder. The ages of the patients in both groups ranged from 60 to 70 years.

Using haematoxylin and eosin stained sections, one of the authors (RM) reviewed all of the histological slides, checked the quality of the material and selected slides for further morphological and immunohistochemical evaluation.

Immunohistochemical staining for basal cells was carried out on sections, 5 μm thick, cut from formalin fixed, paraffin wax embedded tissue blocks. The avidin-biotin complex immunoperoxidase technique (Vector Laboratories, Burlingame, California, USA) was used to evaluate the reactivity of the lesion for basal cell-specific keratin (34 β E12 antikeratin monoclonal antibody provided by Dako SpA, Milan, Italy). Normal prostatic tissue served as a positive control; substitution of primary antibody with normal mouse serum served as a negative control.

Results

FINASTERIDE TREATMENT FOR SIX MONTHS

On examination of prostatic adenectomy specimens from treated patients, the size of the prostate was reduced compared with controls (untreated BPH samples). In particular, considering the transverse diameter of the specimens (that is, width from left lateral to right lateral side), the values recorded in the untreated patients were always >6 cm. By contrast, the lengths in the treated patients were between 4 and 6 cm.

The untreated group showed ducts and acini of relatively uniform size (fig 1). In the treated group there was an increase in the stroma:epithelial and the stroma:lumen ratios—for example, in the untreated group, the stroma:epithelial and the stroma:lumen ratios, judged visually, were 5:1 and 3:1, respectively; in the treated group, the stroma:lumen and stroma:epithelial ratios were 7–10:1, because of a reduction in the epithelial and lumen components, whereas the size of the ducts and acini was not as uniform as in untreated BPH. In fact, some ducts and acini in the treated group were still lined by a bistratified epithelium similar to that of untreated BPH but lacked un-

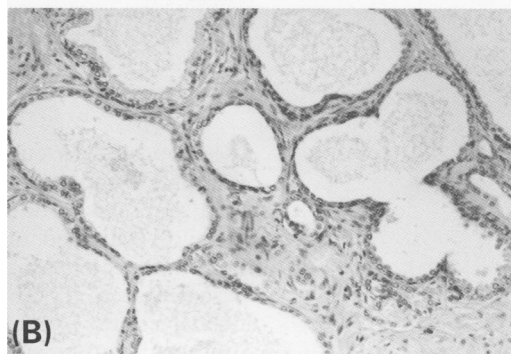
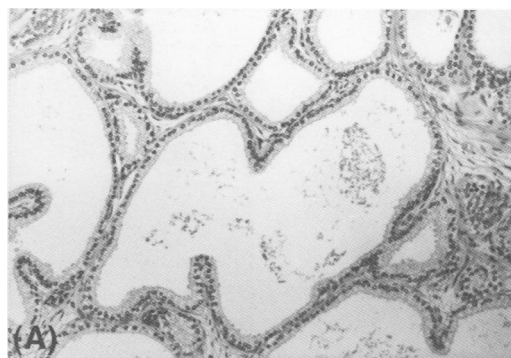


Figure 2 Finasteride treated BPH. Some ducts and acini are lined by a bistratified epithelium similar to that of untreated BPH but lack undulations at the epithelial border (A); others are atrophic (B) ("incomplete atrophy") (haematoxylin and eosin, $\times 16$).

dululations at the epithelial border; other ducts/acini were atrophic (fig 2). In the treated group, the secretory cells had inconspicuous nucleoli and nuclear shrinkage together with some chromatin condensation. Some apoptotic bodies¹¹ were present between the epithelial cells as well as in the lumens; no mitotic figures were seen. A degree of secretory cell cytoplasmic clearing and also basal cell layer prominence were present after the treatment with finasteride. Focal squamous and transitional cell metaplasia was seen mainly in the periurethral region in the treated group.

Budding of some small glands from pre-existing ducts and acini (fig 3) was rarely seen in untreated BPH.¹ Some scattered clusters of small acini with a mixture of round, regular and irregular contours were observed in two cases of the finasteride treated group (fig 4). Adjacent acini invariably showed typical atrophic changes. In these small acini the secretory

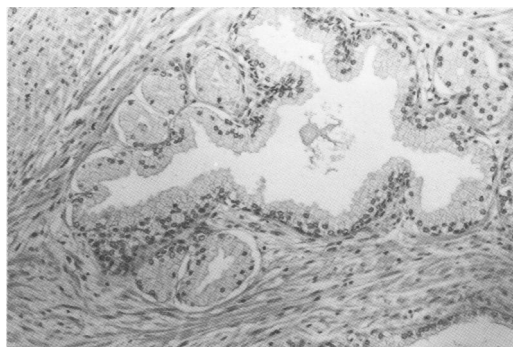


Figure 3 Untreated BPH. Budding of some small glands from a pre-existing duct/acinus (haematoxylin and eosin, $\times 16$).

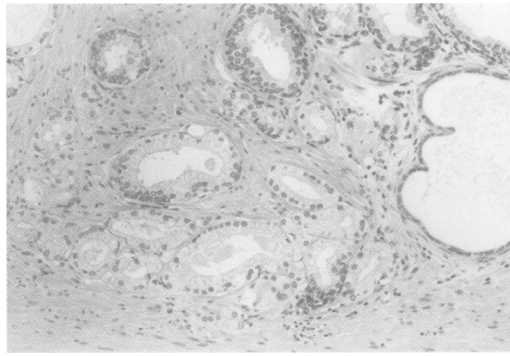


Figure 4 Finasteride treated BPH with groups of small acini originating from a pre-existing duct (haematoxylin and eosin, $\times 16$).

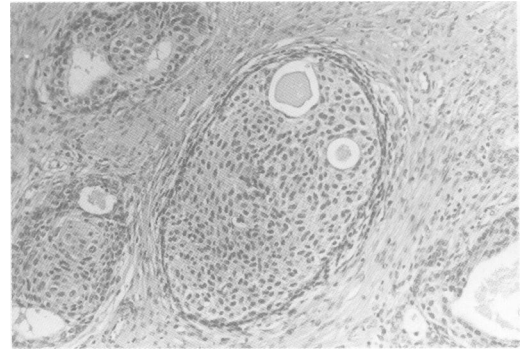


Figure 6 Finasteride treated BPH. Squamous metaplasia as an indication of the previous existence of a lobule (haematoxylin and eosin, $\times 16$).

cells appeared as cuboidal or columnar cells with pale cytoplasm, round basal nuclei, uniform granular chromatin, and inconspicuous or mildly enlarged nucleoli. No intraluminal basophilic mucin was identified. Crystalloids were not seen. The basal cell layer was often inconspicuous by routine light microscopy. However, immunostaining with 34 β E12 anti-keratin antibody showed that all small acini contained basal cells, although the basal cell layer was focally fragmented. Basal cell hyperplasia, mostly of the incomplete type, was seen in two finasteride treated cases which lacked small acini.

In both patients and controls the periurethral region showed stromal nodules of primitive mesenchyme (fig 5). These nodules were particularly prominent in one of the five finasteride treated cases. Scattered atrophic ducts/acinar structures were seen in this region in both groups.

FINASTERIDE TREATMENT FOR 12 MONTHS

The width from left lateral to right lateral side of the prostate specimen was 5 cm. Lobular structures, mostly composed of atrophic ducts and acini, were rare. Prominent squamous and transitional cell metaplasia were observed (fig 6). Abundant fibromuscular stroma was present in the transition zone and in the periurethral region, where stromal nodules were also seen. At the periphery of the transition zone there was a complex intra-acinar papillary-cribriform proliferation of clear cells without nuclear

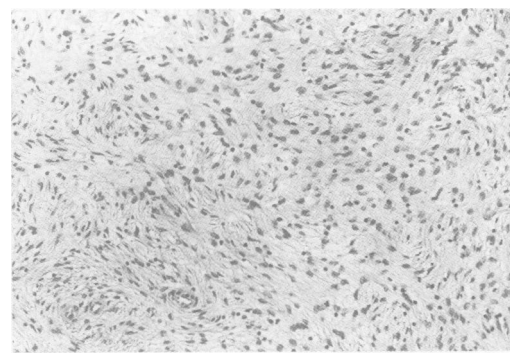


Figure 5 Finasteride treated BPH with a nodule of primitive mesenchyme (haematoxylin and eosin, $\times 16$).

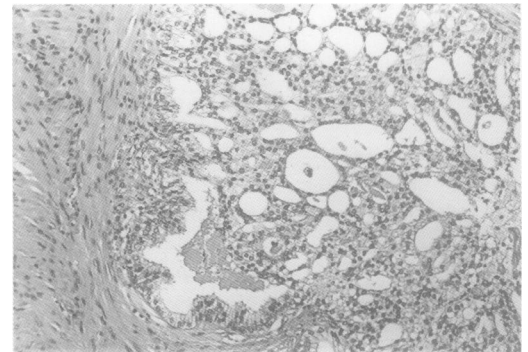


Figure 7 Finasteride treated BPH with a complex intra-acinar papillary-cribriform proliferation of clear cells, similar to so-called clear cell papillary hyperplasia (haematoxylin and eosin, $\times 16$).

atypia (fig 7). Nucleoli were small. The cytoplasm borders were well delineated. Immunostaining with 34 β E12 anti-keratin antibody revealed the presence of basal cells.

Discussion

Our findings in specimens from patients treated for six months with a 5- α -reductase inhibitor confirm what has already been suggested for the human prostate—that is, that finasteride affects the epithelium.^{3,6,7} However, the effect on the ducts and acini was not evenly distributed either within or among the individual lobules, contrary to what was found previously after total androgen ablation.^{12,13} In fact, some ducts and acini were atrophic, the basal cell layer was not always easily identifiable, and others were still lined by a bistratified epithelium similar to that seen untreated BPH. This morphological observation is in agreement with the experimental study by Cohen *et al*,⁸ involving canine hyperplastic prostates treated with steroid 5- α -reductase inhibitors, such as finasteride. The authors noticed that the glandular atrophy in the ventral prostate lobe involved most or all of a given lobule; the gland was lined by flattened or cuboidal cells with scanty cytoplasm. In the less affected lobules there was a decrease in or absence of papillary infolding of the epithelium into the glandular lumina. Juniewicz *et al*⁹ investigated the prostate of beagle dogs. Like Cohen *et al*,⁸ they observed that finasteride induced “incomplete atrophy”.

It is generally accepted that finasteride blocks 5- α -reductase, thereby reducing hormonal stimulation of the epithelial prostate component.³ In fact, the lack of mitotic figures in the ducts and acini indicates that there is no growth of the epithelial component as a result of this treatment. This is in agreement with a recent study published by Bologna *et al*¹⁴ who assessed the effects of finasteride on the growth rate of the LnCap human prostate carcinoma cell line. They found that the growth rate of this cell line could be inhibited by the inhibition of 5- α -reductase. The question one might ask is whether the epithelial atrophy is the result of a lack of stimulation or the result of activation of other involution mechanisms. As apoptotic bodies were present in our specimens, apoptosis was probably triggered by finasteride.¹⁵ This phenomenon has already been observed and described in normal, preinvasive and invasive human prostate lesions after total androgen ablation.¹¹⁻¹³ Tuttle *et al*¹⁶ investigated the effect of 5- α -reductase inhibition on the growth characteristics of the non-androgen dependent human prostate cancer line PC-3. They observed that finasteride caused apoptosis. Lamb *et al*¹⁷ also reported that 5- α -reductase inhibitors promoted prostatic cell death in rodents. In an experimental study Cohen *et al*⁸ briefly mentioned a net increase in prostatic cell death in canine BPH. They suggested that greater numbers of cells died after castration than after treatment with inhibitors of 5- α -reductase.

The finasteride treated group in the present study showed some clusters of small acini morphologically similar to those described in post-atrophic hyperplasia of the prostate.¹⁸ Even though it is unclear how these foci are formed, their formation occurs in untreated prostate as a result of proliferation of small acini originating from atrophic ducts and acini.¹⁸ They are distinguished from carcinoma by their intact or fragmented basal cell layer, inconspicuous or mildly enlarged nucleoli, and adjacent acinar atrophy.

In the specimen from the patient treated with finasteride for 12 months, the ducts and acini had undergone further atrophy and eventually almost disappeared, leaving foci of squamous metaplasia scattered throughout the prostate as a sign of a previous lobule existence. This latter feature is similar to that described by Bainborough¹⁹ following oestrogen therapy. Squamous metaplasia was not a prominent feature in specimens from patients treated for six months, although it was present occasionally.

Changes in the epithelium of some ducts and acini at the periphery of the transition zone were also observed after treatment with finasteride for 12 months. These changes were similar to clear cell papillary hyperplasia—that is, a benign change which could mimic a malignant lesion growing in the duct lumen.²⁰ In our case, a postsurgical follow up of two years was available at the time this article was written. The patient was well, with no evidence of malignant lesions originating at or present in the portion of the prostate not removed during

adenectomy. This patient did have a benign lesion, which is consistent with a two year, experimental study of finasteride on the rat ventral prostate by Prahallada *et al*.¹⁰ These authors observed “focal hyperplasia”, characterised by multilayered epithelial cells arranged in a cribriform or papillary pattern, partly or completely occupying the lumen of a solitary acinus or multiple acini. The same authors also described the occurrence of “prostatic adenomas”. They did not show any histomorphological images. However, based on the morphological description given in their text, we assume that their adenomas were not what we describe here as an adenosis-like change. The adenomas described by Prahallada *et al*¹⁰ could represent a more severe change which, morphologically, is very similar to “focal hyperplasia”.

Gormley *et al*⁶ reported a lack of efficacy in 4% of the men receiving a 5 mg tablet of finasteride daily. They did not comment on the reasons for the lack of success in these men, even though their study concentrated on the evaluation of urinary flow. As our current paper was not based on a double blind, placebo controlled study, we cannot give an exact figure for the lack of clinical improvement in urinary symptoms after long term treatment with finasteride. At our Urology Clinic, finasteride, given to over 100 men with BPH, produced a decrease in obstructive urinary symptoms in most cases. No specimens of successful finasteride treatment were available to us as the patients were not candidates for surgery. In approximately 5% of patients—that is, the six patients whose adenectomy specimens are reported in this study, finasteride did not have any effect. The reason for the lack of clinical efficacy might not be related to the glandular component itself, but could be related to the prostate stroma. For example, nodules of primitive mesenchyme were present in the periurethral region after treatment. This could be the result of local variations in 5- α -reductase expression as well as other factors which might influence the behaviour of the stroma cells, including smooth muscle cells.²¹

In conclusion, the morphological evaluation of finasteride treated BPH showed changes in the lobules of the transition zone, but not in the periurethral stroma.

- McNeal JE. The pathobiology of nodular hyperplasia. In: Bostwick DG, ed. *Pathology of the prostate*. New York: Churchill Livingstone, 1990:31-6.
- Isaacs JY. Etiology of benign prostatic hyperplasia. *Eur Urol* 1994;25(Suppl):6-9.
- The Finasteride Study Group. Finasteride (MK-906) in the treatment of benign prostatic hyperplasia. *Prostate* 1993; 22:291-9.
- Imperato-McGinley J. 5 α -reductase deficiency: human and animal models. *Eur Urol* 1994;25(Suppl):20-3.
- Tewari A, Shinohara K, Narayan P. Transition zone volume and transition zone ratio: predictor of uroflow response to finasteride therapy in benign prostatic hyperplasia patients. *Urology* 1995;45:258-65.
- Gormley GJ, Stoner E, Bruskewitz RC and the Finasteride Study Group Members. The effect of finasteride in men with benign prostatic hyperplasia. *N Engl J Med* 1992; 327:1185-91.
- Peter CA, Walsh PC. The effect of nafarelin acetate, a luteinizing-hormone-releasing hormone agonist, on benign prostatic hyperplasia. *N Engl J Med* 1987;317:599-604.
- Cohen SM, Werrmann JG, Rasmusson GH, Tanaka WK, Malatesta PF, Prahallada S, *et al*. Comparison of the effects of new specific azasteroid inhibitors of steroid 5 α -reductase

- on canine hyperplastic prostate: suppression of prostatic DHT correlated with prostate regression. *Prostate* 1995; 26:55-71.
- 9 Juniewicz PE, Hoekstra SJ, Lemp BM, Barbolt TA, Devin JA, Gauthier E, *et al.* Effect of combination treatment with zanoterone (WIN 49596), a steroidal androgen receptor antagonist, and finasteride (MK-906), a steroidal 5-reductase inhibitor, on the prostate and testes of beagle dogs. *Endocrinology* 1993;133:904-13.
 - 10 Prahalada S, Keenan KP, Hertzog PR, Gordon LR, Peter CP, Soper KA, *et al.* Qualitative and quantitative evaluation of prostatic histomorphology in rats following chronic treatment with finasteride, a 5-alpha reductase inhibitor. *Urology* 1994;43:680-5.
 - 11 Montironi R, Magi Galluzzi C, Scarpelli M, Diamanti L. Quantitative characterisation of the frequency and location of cell proliferation and death in prostate pathology. *J Cell Biochem* 1994;19(Suppl):238-45.
 - 12 Montironi R, Magi Galluzzi C, Muzzonigro G, Prete E, Polito M, Fabris G. Effect of combination endocrine therapy (LHRH agonist and flutamide) on normal prostate, prostatic intraepithelial neoplasia and prostatic adenocarcinoma. *J Clin Pathol* 1994;47:906-13.
 - 13 Montironi R, Muzzonigro G, Magi Galluzzi C, Giannulis I, Diamanti L, Polito M. Effect of LHRH agonist and flutamide (combination endocrine therapy) on the frequency and location of proliferating cell nuclear antigen and apoptotic bodies in benign prostatic hyperplasia. *J Urol Pathol* 1994;2:161-71.
 - 14 Bologna M, Muzi P, Biordi L, Festuccia C, Vicentini C. Finasteride dose-dependently reduces the proliferation rate of the LnCap human prostatic cancer line in vitro. *Prostate* 1995;45:282-90.
 - 15 Russo P, Warner JA, Perez G, Heston WDW. TRPM-2 gene expression in normal rat ventral prostate following castration and exposure to diethylstilbestrol, flutamide, MK-906 (finasteride), and Coumarin. *Prostate* 1994;24: 237-43.
 - 16 Tuttle RM, Loop S, Jones RE, Meikle AW, Ostenson RC, Plymate SR. Effect of 5-alpha-reductase inhibition and dexamethasone administration on the growth characteristics and intratumor androgen levels of the human prostate cancer cell line PC-3. *Prostate* 1994;24:229-36.
 - 17 Lamb JC, English H, Levandoski PL, Rhodes GR, Johnson RK, Isaacs JT. Prostatic involution in rats induced by a novel 5-alpha-reductase inhibitor, SK&F 105657: role for testosterone in the androgenic response. *Endocrinology* 1992;130:685-94.
 - 18 Cheville JC, Bostwick DG. Postatrophic hyperplasia of the prostate. A histologic mimic of prostatic adenocarcinoma. *Am J Surg Pathol* 1995;19:1068-76.
 - 19 Bainborough AR. Squamous metaplasia of the prostate following estrogen therapy. *J Urol* 1952;68:329-36.
 - 20 Ayala AG, Srigley JR, Ro JY, Abdul-Karim FW, Johnson DE. Clear cell cribriform hyperplasia of prostate: report of 10 cases. *Am J Surg Pathol* 1986;10:665-71.
 - 21 Shapiro E, Hartanto V, Lepor H. The response to alpha blockade in benign prostatic hyperplasia is related to the percent area density of prostate smooth muscle. *Prostate* 1992;21:297-307.
 - 22 Miller PD, Brewster S, Reynard J, Kirby RS. Prostatic morphometry following treatment with finasteride (abstract). *J Urol* 1993;149:423A.