

Histology of chronic gastritis with and without duodenitis in patients with *Helicobacter pylori* infection

P S Phull, A B Price, J Stephens, B J Rathbone, M R Jacyna

Abstract

Aim—To compare the histological characteristics of *Helicobacter pylori* positive chronic gastritis in patients with and without associated duodenitis.

Methods—Gastric mucosal biopsy specimens were obtained from patients undergoing endoscopy for dyspepsia. Severity of gastritis and density of *H pylori* infection were graded according to the Sydney system.

Results—Of the 69 patients studied, 15 had normal histology, 22 had chronic gastritis only (77.3% *H pylori* positive), 21 had duodenitis (90.5% *H pylori* positive), and 11 had other diagnoses. In the *H pylori* positive patients, the median gastritis score was higher in the duodenitis group (6, range 3–9) than in the chronic gastritis only group (5, range 2–8), because of greater neutrophil activity scores in patients with duodenitis (median score 2 v 1). There were no differences in the density of *H pylori* infection, inflammation, atrophy, or intestinal metaplasia between patients with chronic gastritis only and those with duodenitis.

Conclusions—These results suggest that *H pylori* positive patients with duodenitis have a more severe form of gastritis than those without associated duodenal inflammation. This is because of increased neutrophil activity, which seems to be independent of the density of *H pylori* infection.

(J Clin Pathol 1996;49:377–380)

Keywords: duodenitis, *Helicobacter pylori*, gastritis.

Helicobacter pylori infection is the major cause of chronic gastritis,¹ and is associated with more than 90% of duodenal ulcers.² Eradication of the organism dramatically alters the natural history of duodenal ulcer disease by preventing relapse.³ However, it is not clear why only some subjects with chronic gastritis develop duodenal ulceration. Although the close relation between *H pylori* and the gastroduodenal mucosa has been studied extensively,^{1,2,4–8} there is little information on the histology of the gastric mucosa in patients with and without associated duodenal inflammation/ulceration. Duodenitis is almost invariably present in duodenal ulceration and is believed to be part of the same pathophysiological spectrum.^{2,9,10}

Methods

The study was approved by the Northwick Park Hospital ethical committee. Patients under-

going routine upper gastrointestinal endoscopy for dyspepsia were invited to participate in the study and written informed consent was obtained. Patients were excluded if there was a history of therapy with H₂-receptor antagonists, proton-pump inhibitors or antibiotics in the preceding four weeks, or if there was endoscopic evidence of oesophagitis or malignancy. All of the endoscopies were performed by a single operator (PSP) using an Olympus Q20 gastroscope. Two mucosal biopsy specimens were taken from each site: the gastric corpus (anterior and posterior wall), the antrum (within 3 cm of the pylorus), as well as the first part of the duodenum.

The gastroduodenal biopsy specimens were examined histologically by a single pathologist (ABP), who was unaware of the endoscopic findings. Biopsy tissue, fixed in 10% formalin and embedded in paraffin wax, was sectioned at 3 µm and stained with haematoxylin and eosin, as well as a cresyl-fast violet stain for *H pylori*. Gastritis was graded according to the Sydney System.¹¹ This grades the severity of inflammation, activity (the degree of polymorph neutrophil infiltration), atrophy, and intestinal metaplasia on a scale from 0 to 3. A subsequent "gastritis score" for each biopsy site was obtained by combining the scores for the four individual characteristics (maximum possible score = 12). The "total gastritis score" was obtained by combining the gastritis scores for the corpus and antrum (maximum possible score = 24). In accordance with the Sydney system, the density of *H pylori* infection was also graded semiquantitatively on a scale from 0 to 3. Duodenitis was graded on a scale from 0 to 3, according to Whitehead.¹² Patients with special forms of gastritis, gastric ulceration or those with malignancy were excluded. For analysis, the patients were divided into three groups: (1) normal (gastritis score = 0, duodenitis score = 0); (2) chronic gastritis only (gastritis score 1 or more, duodenitis score = 0); and (3) duodenitis (duodenitis score 1 or more).

Statistical analysis was performed using the χ^2 test for comparing proportions between groups. The Mann-Whitney U test for non-parametric data was used to compare the gastritis scores between groups. A p value of less than 0.05 was regarded as significant.

Results

Complete sets of biopsy specimens were available for 69 patients. Eleven patients were excluded from the analyses (one with gastric cancer, one with gastric ulcer, eight with re-

Department of
Gastroenterology,
Northwick Park
Hospital, Harrow
P S Phull
M R Jacyna

Department of
Histopathology
A B Price

Department of
Gastroenterology,
Leicester Royal
Infirmary, Leicester
J Stephens
B J Rathbone

Correspondence to:
Dr P S Phull, Department
of Gastroenterology,
Northwick Park Hospital,
Harrow,
Middlesex HA1 3UJ.

Accepted for publication
16 January 1996

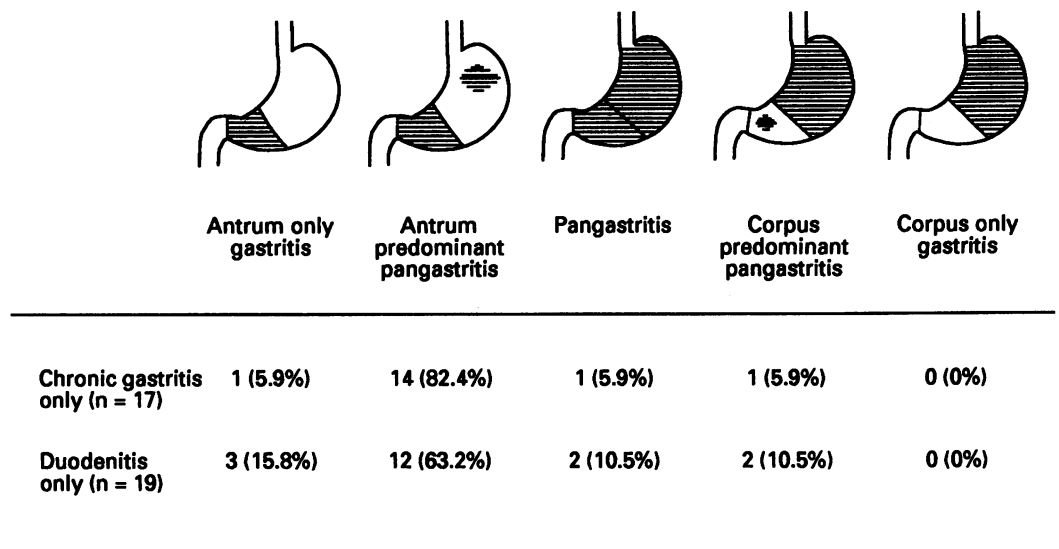


Figure 1 Topography of chronic gastritis in *H pylori* positive patients.

active gastritis, and one with lymphocytic gastritis). Table 1 summarises the demographic characteristics of the remaining 58 patients. Fifteen of these patients had normal gastro-duodenal histology, 22 had chronic gastritis only, and 21 had duodenal inflammation. Seventeen (77.3%) of the patients with chronic gastritis only were *H pylori* positive compared with 19 (90.5%) of the patients with duodenitis. All of the patients in the duodenitis group (group 3) had an associated chronic gastritis except for the two *H pylori* negative patients who had normal gastric histology. The following results refer only to *H pylori* positive patients.

GASTRIC HISTOPATHOLOGY

Examination of the topography of the chronic gastritis did not reveal any significant differences (χ^2 test) between patients with chronic gastritis only and those with duodenitis (fig 1), with all patients having some degree of antral involvement.

Analysis of the gastritis scores (table 2) revealed that patients with duodenitis had a more severe form of gastric inflammation than those with chronic gastritis alone. The total gastritis score was significantly higher in the duodenitis group compared with the chronic gastritis group ($p < 0.05$, Mann-Whitney U test). This was attributable to greater neutrophil infiltration into the gastric mucosa in patients with duodenitis, with the activity scores being significantly higher than in the chronic gastritis only group (group 2) ($p < 0.02$, Mann-Whitney U test). There were no significant differences between the groups in the density of *H pylori* infection, inflammation, atrophy, or intestinal metaplasia.

The presence of lymphoid hyperplasia (lymphoid follicles and lymphoid aggregates) was noted in the gastric mucosa of 14 (73.7%) of the 19 patients in the duodenitis group compared with seven (41.2%) of the 17 patients in the chronic gastritis only group ($\chi^2 = 3.9$, DF = 1, $p < 0.05$). Lymphoid hyperplasia was mainly located in the antrum in 95.2% of the cases. Interestingly, lymphoid hyperplasia was detected in two (13.3%) of the 15 normal patients.

DUODENAL HISTOPATHOLOGY

The presence of gastric metaplasia of the duodenal mucosa was noted in 12 (63.2%) of 19 patients from the duodenitis group compared with four (23.5%) of 17 patients with chronic gastritis only ($\chi^2 = 5.7$, DF = 1, $p < 0.02$). Duodenal *H pylori* colonisation was only seen in patients with duodenitis. Six (31.6%) of 19 patients in this group had organisms detected in the duodenum; all of these patients had gastric metaplasia and gastric *H pylori* infection.

Discussion

It has been known for many years that chronic gastritis, particularly affecting the antrum, is found in association with most cases of duodenal inflammation and ulceration.¹³ Furthermore, this form of chronic gastritis increases the risk of developing duodenal ulceration by over 10-fold over a 10 year period.¹⁴ Since the discovery of the bacterium *H pylori*, it has been recognised that infection with this organism is the major cause of chronic gastritis.¹ It is now clear that *H pylori* also plays a critical role in duodenal ulcer disease. Over 90% of duodenal ulcer cases have an *H pylori* associated

Table 1 Demographic characteristics

	Normal (n = 15)	Chronic gastritis (n = 22)	Duodenitis (n = 21)
Mean age (years; range)	48 (26-80)	44 (24-80)	50 (34-72)
Men	5 (33.3%)	10 (45.5%)	19 (90.5%)
Smokers	3 (20%)	8 (36.4%)	8 (38.1%)

Table 2 Histological scores (median, range)

		Chronic gastritis (n = 17)	Duodenitis (n = 19)
Inflammation	Corpus	1 (0-2)	1 (0-2)
	Antrum	2 (1-3)	2 (1-3)
	Total	3 (1-4)	3 (1-5)
Activity	Corpus	0 (0-1)*	1 (0-2)*
	Antrum	1 (0-2)†	1 (1-2)†
	Total	1 (0-3)†	2 (1-3)†
Atrophy	Corpus	0 (0-1)	0 (0-3)
	Antrum	0 (0-2)	1 (0-2)
	Total	0 (0-2)	1 (0-3)
Intestinal metaplasia	Corpus	0 (0-1)	0 (0-1)
	Antrum	0 (0-1)	0 (0-2)
	Total	0 (0-1)	0 (0-2)
Gastritis score	Corpus	1 (0-5)	2 (0-6)
	Antrum	3 (1-7)	4 (2-7)
	Total	5 (2-8)*	6 (3-9)*
<i>H pylori</i> density	Corpus	1 (0-2)	1 (0-2)
	Antrum	2 (1-3)	2 (1-3)
	Total	3 (1-5)	3 (1-4)
Duodenitis score		0 (0)	1 (1-3)

* p<0.05, † p<0.02 (Mann-Whitney U test).

chronic gastritis²; eradication of the organism dramatically alters the natural history of the disease by preventing further relapse.³

This study confirms the previously noted relation between *H pylori* infection, chronic gastritis and duodenitis.¹² A number of studies have examined the morphology of the gastric mucosa in *H pylori* infection.^{12,4-8} They have demonstrated the close association between density of infection with the organism and the evoked inflammatory response. Both chronic inflammatory and neutrophil cell infiltrates correlate with the density of *H pylori* infection in the antrum. However, two studies have suggested that despite a similar density of *H pylori* infection the gastritis is less severe in the corpus.^{7,15}

There are little comparative data available on the histology of the chronic gastritis between patients with duodenitis and those with chronic gastritis alone. As mentioned above, duodenal inflammation/ulceration is almost invariably associated with an antrum predominant pan-gastritis.^{2,13} The results from this study are in agreement, but it is of note that we did not find any differences in the topographical distribution of the gastritis in patients with chronic gastritis alone or in association with duodenitis.

Using the standardised Sydney system for grading gastritis, we have demonstrated that the gastric inflammation in patients with duodenitis is more severe than in those with chronic gastritis alone. This seems to be because of higher activity scores, reflecting greater neutrophil infiltration. Of particular note is that the greater severity of gastritis in the patients with duodenitis did not seem to be associated with any statistically significant differences in the density of *H pylori* colonisation. In addition, there were no significant differences between the chronic gastritis only and the duodenitis groups in the degree of atrophy or intestinal metaplasia. Our results are in agreement with those reported by Genta *et al.*,¹⁶ who were also unable to find any significant differences in the density of *H pylori* infection between patients with duodenal ulceration and those with chronic gastritis alone. Two studies confirm our findings of a more severe gastritis and higher neutrophil activity in patients with duo-

denal ulceration when compared with those with either non-ulcer dyspepsia¹⁷ or gastritis only.¹⁸ However, in contrast to our results, both of these studies found higher *H pylori* density scores in the antrum of patients with duodenal ulceration. It is important to note that the results from these studies may not be directly comparable with those presented in this paper as duodenal histology was not used to categorise patients. It is possible that endoscopically normal cases with histological evidence of duodenitis may have been misclassified. A further explanation for the difference in our results may be that as the overall severity of chronic gastritis in our cohort of patients was relatively mild, these patients may not be representative of *H pylori* positive subjects in other countries. Lastly, the possibility cannot be entirely excluded that the number of patients in our study may not have been large enough to detect a small difference in *H pylori* density between the two groups of patients.

The prevalence of gastric metaplasia in our dyspeptic patients was similar to that reported by other groups.^{10,19} We have also shown that the incidence of gastric metaplasia is higher in patients with duodenitis. In this study, colonisation of the duodenum by *H pylori* was seen only in the duodenitis group. These findings are in agreement with previously published work (reviewed by Wyatt²), which suggests that gastric metaplasia develops as a response to the presence of an increased gastric acid load in the duodenum. The presence of gastric metaplasia allows *H pylori* to colonise the duodenum, as the organism can only colonise gastric-type mucosa.^{2,19,20} It is interesting to speculate whether the patients with chronic gastritis and gastric metaplasia, but without duodenitis, will go on to develop duodenal ulceration or have had ulceration in the past and therefore represent a high-risk group.

Infection of the gastric mucosa with *H pylori* elicits a complex inflammatory and immunological response.²¹ Lymphoid hyperplasia has been noted in *H pylori* gastritis by other workers, with a higher prevalence in the antrum than the corpus.²² The proportion of cases seen with lymphoid hyperplasia correlated with the severity of gastritis and density of *H pylori* infection. The results of our study confirm the higher prevalence of lymphoid hyperplasia in *H pylori* infection and also the greater antral involvement. Our results also demonstrate a higher prevalence of lymphoid hyperplasia in patients with duodenitis than in those with chronic gastritis alone; this seemed to be independent of the density of *H pylori* infection. These results are in agreement with those reported by Genta *et al.*²³ It is likely that the higher prevalence of lymphoid hyperplasia in patients with duodenitis is a consequence of the more severe inflammatory and neutrophil response seen in these patients.

Although host factors are also likely to be of importance in determining which patients with *H pylori* positive chronic gastritis develop duodenal ulceration, recent work has suggested that some strains of *H pylori* may be more

virulent and therefore more likely to be "ulcerogenic".²⁴ These more virulent strains produce a vacuolating cytotoxin,²⁵ which is found more often in *H pylori* positive patients with ulcers than those without.²⁶ Production of the cytotoxin by the *vacA* gene^{27,28} is associated with expression of a 120–128 kilodalton protein,^{29–32} which itself is a product of the *cagA* gene.^{28,32} A number of studies have demonstrated increased recognition of the 120 kilodalton CagA protein in patients with duodenal ulcer, compared with *H pylori* positive patients with chronic gastritis alone, in the gastric mucosa^{30,33} and in the serum.^{31,32,34} CagA positive strains of *H pylori* have been shown to induce greater production of pro-inflammatory cytokines than CagA negative strains.^{35,36} This may provide an explanation for the higher neutrophil activity that we have observed in the *H pylori* positive patients with duodenitis compared with the *H pylori* positive patients with chronic gastritis alone.

In summary, we have demonstrated that *H pylori* positive patients with duodenal inflammation have a more severe form of chronic gastritis than those without associated duodenitis. This is because of an increase in the neutrophil activity, which seems to be independent of the density of *H pylori* infection. The results of this study are in agreement with published work, suggesting that *H pylori* positive patients with duodenal inflammation/ulceration represent a particular cohort in whom there is a more severe gastric inflammatory response to the infection. The strain of the organism may be a more important factor than the density of infection in determining the gastric inflammatory response to *H pylori*.

PSP is partly funded by a grant from Glaxo Group Research, UK.

- Dixon MF. Helicobacter pylori and chronic gastritis. In: Rathbone BJ, Heatley RV (eds). *Helicobacter and gastro-duodenal disease*. Oxford: Blackwell Scientific Publications, 1992:124–39.
- Wyatt JI. Helicobacter pylori, duodenitis and duodenal ulceration. In: Rathbone BJ, Heatley RV (eds). *Helicobacter and gastro-duodenal disease*. Oxford: Blackwell Scientific Publications, 1992:140–9.
- Tytgat GN, Noach LA. H. pylori eradication. In: Hunt RH, Tytgat GN (eds). *Helicobacter pylori – basic mechanisms to clinical cure*. Dordrecht: Kluwer, 1994:550–69.
- Price AB, Levi J, Dolby JM, Dunscombe PL, Smith A, Clark J, Stephenson ML. Campylobacter pylori in peptic ulcer disease: microbiology, pathology and scanning electron microscopy. *Gut* 1985;26:1183–8.
- Siurala M, Sipponen P, Kekki M. Campylobacter pylori in a sample of Finnish population: relations to morphology and functions of the gastric mucosa. *Gut* 1988;29:909–15.
- Collins JSA, Sloan JM, Hamilton PW, Watt PCH, Love AHG. Investigation of the relationship between gastric antral inflammation and Campylobacter pylori using graphic tablet planimetry. *J Pathol* 1989;159:281–5.
- Stolte M, Eidt S, Ohnsmann A. Differences in Helicobacter pylori associated gastritis in the antrum and body of the stomach. *Z Gastroenterol* 1990;28:229–33.
- Bayerdorffer E, Oertel H, Lehn N, Kasper G, Mannes GA, Sauerbruch T, et al. Topographic association between active gastritis and Campylobacter pylori colonisation. *J Clin Pathol* 1989;42:834–9.
- Hasan M, Sircus W, Ferguson A. Duodenal mucosal architecture in non-specific and ulcer-associated duodenitis. *Gut* 1981;22:637–41.
- Cotton PB, Price AB, Tighe JR, Beales JSM. Preliminary evaluation of 'duodenitis' by endoscopy and biopsy. *BMJ* 1973;3:430–3.
- Price AB. The Sydney system: histological division. *J Gastroenterol Hepatol* 1991;6:209–22.
- Whitehead R (ed). Small intestinal biopsy in disease. In: *Mucosal biopsy of the gastrointestinal tract*. Philadelphia: WB Saunders, 1990:171–8.
- Kekki M, Sipponen P, Siurala M. Progression of antral and body gastritis in patients with active and healed duodenal ulcer and duodenitis. *Scand J Gastroenterol* 1984;19:382–8.
- Sipponen P, Varis K, Fraki O, Korri UM, Seppala K, Siurala M. Cumulative 10-year risk of symptomatic duodenal and gastric ulcer in patients with or without chronic gastritis. *Scand J Gastroenterol* 1990;25:966–73.
- Bayerdorffer E, Lehn N, Hatz R, Mannes GA, Oertel H, Sauerbruch T, et al. Difference in expression of Helicobacter pylori gastritis in antrum and body. *Gastroenterology* 1992;102:1575–82.
- Genta RM, Hubermann RM, Graham DY. The microscopic topography of Helicobacter pylori in patients with different expressions of the infection. *Acta Gastroenterol Belg* 1993;56(Suppl):124.
- Fiocca R, Villani L, Luinetti O, Gianaffi A, Perego M, Alvisi C, et al. Helicobacter colonization and histopathological profile of chronic gastritis in patients with or without dyspepsia, mucosal erosion and peptic ulcer: a morphological approach to the study of ulcerogenesis in man. *Virchows Arch A Pathol Anat Histopathol* 1992;420:489–98.
- Eidt S, Stolte M. Differences between Helicobacter pylori associated gastritis in patients with duodenal ulcer, pyloric ulcer, other gastric ulcer, and gastritis without ulcer. In: Malferteiner P, Ditschuneit H (eds). *Helicobacter pylori, gastritis and peptic ulcer*. Berlin: Springer-Verlag, 1990:228–36.
- Wyatt JI, Rathbone BJ, Sobala GM, Shallcross T, Heatley RV, Axon ATR, et al. Gastric epithelium in the duodenum: its association with Helicobacter pylori and inflammation. *J Clin Pathol* 1990;43:981–6.
- Wyatt JI, Rathbone BJ, Dixon MF, Heatley RV. Campylobacter pylori and acid induced gastric metaplasia in the pathogenesis of duodenitis. *J Clin Pathol* 1987;40:841–8.
- Ernst PB, Jin Y, Navarro J, Reyes V, Crowe S. Overview of the immune response to H. pylori. In: Hunt RH, Tytgat GN (eds). *Helicobacter pylori – basic mechanisms to clinical cure*. Dordrecht: Kluwer, 1994:295–305.
- Eidt S, Stolte M. Prevalence of lymphoid follicles and aggregates in Helicobacter pylori gastritis in antral and body mucosa. *J Clin Pathol* 1993;46:832–5.
- Genta RM, Hamner HW, Graham DY. Gastric lymphoid follicles in Helicobacter pylori infection. *Hum Pathol* 1993;24:577–83.
- Blaser MJ. Helicobacter pylori phenotypes associated with peptic ulceration. *Scand J Gastroenterol* 1994;29(Suppl 205):1–5.
- Leunk RD, Johnson PT, David BC, Kraft WG, Morgan DR. Cytotoxic activity in broth-culture filtrates of Campylobacter pylori. *J Med Microbiol* 1988;26:93–9.
- Figura N, Guglielmetti P, Rossolini A, Barberi A, Cusi G, Musmanno RA, et al. Cytotoxin production by Campylobacter pylori strains isolated from patients with peptic ulcers and from patients with chronic gastritis only. *J Clin Microbiol* 1989;27:225–6.
- Telford JL, Ghiara P, Dell'Orco M, Comanducci M, Burrone D, Bugnoli M, et al. Gene structure of the Helicobacter pylori cytotoxin and evidence of its key role in gastric disease. *J Exp Med* 1994;179:1653–8.
- Phadnis SH, Iiver D, Janzon L, Normark S, Westblom TU. Pathological significance and molecular characterization of the vacuolating toxin gene of Helicobacter pylori. *Infect Immun* 1994;62:1557–65.
- Tummuru MKR, Cover TL, Blaser MJ. Cloning and expression of a high molecular mass major antigen of Helicobacter pylori – evidence of linkage to cytotoxin production. *Infect Immun* 1993;61:1799–809.
- Crabtree JE, Figura N, Taylor JD, Bugnoli M, Armellini D, Tompkins DS. Expression of 120 kilodalton protein and cytotoxicity in Helicobacter pylori. *J Clin Pathol* 1992;45:733–4.
- Cover TL, Dooley CP, Blaser MJ. Characterization of and human serologic response to proteins in Helicobacter pylori broth culture supernatants with vacuolizing cytotoxin activity. *Infect Immun* 1990;58:603–10.
- Covacci A, Censini S, Bugnoli M, Petracca R, Burrone D, Macchia G, et al. Molecular characterization of the 128 kDa immunodominant antigen of Helicobacter pylori associated with cytotoxicity and duodenal ulcer. *Proc Natl Acad Sci USA* 1993;90:5791–5.
- Crabtree JE, Taylor JD, Wyatt JI, Heatley RV, Shallcross TM, Tompkins DS, et al. Mucosal IgA recognition of Helicobacter pylori 120 kDa protein, peptic ulceration and gastric pathology. *Lancet* 1991;338:332–5.
- Crabtree JE, El-Omar E, Bugnoli M, Covacci A, Eyre D, Rappuoli R, et al. Serum CagA IgG antibodies in Helicobacter pylori positive healthy volunteers and patients with dyspeptic disease. *Gut* 1994;35(Suppl 2):S35.
- Crabtree JE, Farmery SM, Lindley IJD, Figura N, Peichl P, Tompkins DS. CagA/cytotoxic strains of Helicobacter pylori and interleukin-8 in gastric epithelial cell lines. *J Clin Pathol* 1994;47:945–50.
- Peek RM, Blaser MJ, Miller GG. CagA-positive Helicobacter pylori strains induce preferential cytokine expression in gastric mucosa (abstract). *Gastroenterology* 1994;106:A158.