



Laboratory diagnosis of malaria

D C Warhurst, J E Williams

Introduction

Persons with a history of travel in parts of the world where malaria is endemic who develop fever within weeks of return, may be suffering from malignant tertian malaria (*Plasmodium falciparum*). *P falciparum* infections rarely persist for more than one year untreated, but may be fatal within days. In 1994 and 1995 there were 11 and four, respectively, imported malaria fatalities in the UK.

The other three species of malaria infecting humans may, after the initial feverish symptoms have died down, recur after several months to four years in the case of *P vivax* and *P ovale*, which have dormant liver forms, and for up to 40 or more years in the case of *P malariae*, which can persist in the blood of untreated persons.¹

Although a history of overseas travel is usually a factor when malaria presents, it should be remembered that malarial infections may be acquired by blood transfusion, sharing syringes, organ transplants, and accidental laboratory inoculation. A significant number of reports exist of malaria transmission having taken place in the vicinity of airports in non-endemic countries, owing to the accidental importation of infected vector female *Anopheles* mosquitoes.

Currently, the accepted diagnostic technique for malaria is the examination of stained blood films under the oil immersion lens of the microscope. Serology plays a part in epidemiology and in various special investigations.²

Samples for blood film diagnosis

For malaria diagnosis blood should ideally be taken direct from the patient's finger or ear and the smears prepared at the bedside or in the clinic. Films adhere better to the slides, leave a clearer background after lysis, and parasite and red cell changes are minimal.

If it is necessary to use anticoagulants, then the films should be made as soon as possible, certainly less than three hours, after the blood was drawn. EDTA is superior to other anticoagulants for this purpose. Parasite and red blood cell morphology can be seriously affected if the blood has been in anticoagulant for too long.³

Further development of the sexual stages may occur (even within 20 minutes under the right conditions) and the male gametes re-

leased into the plasma may be mistaken for other organisms, such as *Borrelia*. They may be distinguished from *Borrelia* by the central location of the red-staining nucleus, and the absence of notable, repetitive sinuous curves.

If parasitised blood is left at warm laboratory temperature, red cells may be invaded by released merozoites. This may lead—for example, to the occurrence of appreciable numbers of “accolé” forms, characteristic of *P falciparum*, in blood parasitised by *P vivax*.

Heavier parasitaemias left for several hours may lead to the serious deterioration of the already delicate parasitised erythrocytes, owing to a build-up of acid in the blood sample. Those parasitised with early *P vivax* forms may shrink or become crenated. Later stages of the parasite may become compact, and the erythrocyte membrane may become very delicate so that it stretches when the film is prepared. Prolonged exposure, for more than 10–12 hours, may result in the total destruction of the later stages of *P vivax*, making recognition difficult or, in some instances, impossible.

Blood should, if possible, be taken during or after pyrexia, and before the administration of antimalarial drugs. Drug treatment, besides making parasitaemia harder to detect, causes confusing morphological changes in the parasites. Chloroquine—for example, causes clumping of pigment vesicles and can lead to other species being mistaken for *P falciparum*.

Where a bone marrow biopsy specimen is available, this may be a fruitful specimen for malaria diagnosis. Buffy coat smears may be useful for the detection of scanty maturing stages and gametocytes, but are not recommended routinely.

For routine diagnosis of malaria, four thin and four thick blood films should be prepared. One of the thin films, stained with Giemsa, should be adequate for detection of normal parasitaemias and for determination of species. To save time, where essential, the rapid Field's technique may be used, but should be backed up by Giemsa stained thin films. The thick films should be stained using Giemsa or Field's stain. If problems with diagnosis arise the other films are available for further study. In addition, the PHLS Malaria Reference Laboratory would appreciate having unstained films, both thick and thin, for confirmation. (Malaria is a notifiable disease in the UK.) If

This Broadsheet has been prepared by the authors at the invitation of the Association of Clinical Pathologists who reserve the copyright. Further copies of this Broadsheet may be obtained from the Publishing Manager, Journal of Clinical Pathology, BMA House, Tavistock Square, London WC1H 9JR.

PHLS Malaria Reference Laboratory, London School of Hygiene and Tropical Medicine

Correspondence to: Dr D C Warhurst, Reader in Medical Protozoology, London School of Hygiene and Tropical Medicine, Keppel Street, London WC1E 7HT.

Accepted for publication 17 March 1996

clinical evidence of malaria is strong, yet parasites are not found in the films taken initially, then further films should be taken at six hourly intervals.

Stained thin blood film

PRINCIPLE

Two methods are described. A rapid method, where an urgent diagnosis is required, and a longer method which provides the best staining for the successful identification of species.

Preparation of the smear and the staining is similar to that used for normal haematology, except that Giemsa stain is used, and dilution is made in alkaline buffer (pH 7.2) instead of the usual slightly acidic buffer used by most haematology laboratories.

EQUIPMENT

Staining tray, constructed so that the slides may be stained face downwards in a small volume of solution; 20 ml disposable syringe and 5 cm × 19 g blunt needle; Coplin jars.

STAINS AND REAGENTS

- Giemsa stain solution (BDH, R66; Product 35086). This has variable batch quality and each new batch should be checked against a known *P vivax* before routine use. Field's stain solution A (BDH; Product 35056) and Field's stain solution B (BDH; Product 35057).
- As an alternative to commercial Field's stain, the solutions may be made up as follows: (1) methylene blue (medicinal), 0.8 g; Azure I, 0.5 g; Na₂HPO₄, 5.0 g; KH₂PO₄, 6.25 g; distilled water, 500 ml. (2) Eosin, 1.0 g; Na₂HPO₄, 5.0 g; KH₂PO₄, 6.25 g; distilled water, 500 ml. The solutions should be filtered after being allowed to stand overnight.
- Phosphate buffered distilled water (pH 7.2): KH₂PO₄, 0.7 g; Na₂HPO₄, 1.0 g; distilled water, 1.0 litre.
- Absolute methanol (Analar).

STAINING METHOD

Giemsa

- 1 Prepare thin blood film as for routine haematology. Ensure that the film has a good "tail" and does not reach the edges of the slide laterally.
- 2 Allow the film to dry in air and fix with methanol for 30 to 60 seconds.
- 3 Tip off excess methanol and place face down on a staining tray.
- 4 Using the 20 ml syringe and blunt needle, dilute the stock Giemsa 1 in 10 with buffered distilled water. Mix well and expel air.
- 5 Infiltrate the stain, using the syringe and needle, under the slide, taking care not to trap large air bubbles. Stain for 40–45 minutes.
- 6 At the end of the staining time, rinse the slides briefly with tap water and allow to drain dry in a vertical position. A ×50 or ×63 oil immersion objective is invaluable for preliminary examination of blood films.

The syringe method for dilution of Giemsa is strongly recommended, as once the stain is diluted with water, precipitation of the stain begins, which is hastened by exposure to air. Staining face-downwards also reduces precipitation, and any that does develop falls away

from the smear. Cleanly stained smears are very important when searching for small, intracellular parasites.

The buffered water at pH 7.2 *must* be used for the dilution of stain for blood parasites. It is only at this alkaline pH that proper differentiation of parasite nuclear and cytoplasmic material takes place, as well as the staining of cytoplasmic and membrane changes in infected red blood cells (for example, Schüffner's dots and Maurer's clefts). It must be stressed that acidic staining is not suitable for proper diagnosis of blood parasites on thin films.

Rapid Field's method for thin films

- 1 Prepare and fix film as for the Giemsa technique.
- 2 Flood slide with 1 ml Field's stain B (red solution) diluted 1 in 4 in buffered water (pH 7.2).
- 3 Immediately add an equal volume of Field's stain A (blue solution), mix well and stain for one minute.
- 4 Rinse in tap water and drain dry.

Thick blood film

Thick blood films allow a rapid examination of a relatively large volume of blood, enabling the detection of even scanty parasitaemias of all blood parasites. A well prepared thick blood film gives more than a 10-fold increase in sensitivity over thin films.

As with thin films, two techniques are given: a rapid Field's technique (giving excellent coloration, but more dependent on the skill of the operator for optimum results) and a slower Giemsa stain method which is more consistent in its staining quality.

PRINCIPLE

An unfixed dried film, about five to six red blood cells thick, is made and the haemoglobin lysed out either before or during the staining process. The malaria parasites in the film are stained with little interference from the large numbers of red blood cells present, and can be seen against a relatively clear background.

PREPARATION OF THICK BLOOD FILM

- 1 A drop of blood, 3–5 mm in diameter (3–5 µl) is put into the centre of a 76 × 26 mm slide and spread, with the corner of another slide or a swab stick, to cover an oval area of approximately 10–15 mm diameter.
- 2 The final density of the smear should allow newsprint to be just visible through it.
- 3 Thoroughly dry the smear, horizontally, in an incubator at 37°C for one hour.

STAINING METHOD

Giemsa

- 1 Do *not* fix the dry film, but place it gently in a Coplin jar containing buffered water (pH 7.2) and allow to lyse until no more haemoglobin can be seen falling away from the smear (usually three to five minutes).
- 2 Remove from water, place face-down on staining dish, and stain with Giemsa diluted 1 in 10 with water, as for the thin film method.
- 3 Stain for 30 minutes; then rinse briefly with tap water and drain dry. Examine film as described for a thin blood film.

Field's stain

- 1 Do *not* fix the dry film.
- 2 Dip film for three seconds in Field's solution A.
- 3 Wash gently in a jar of tap water and quickly drain off excess water onto absorbent paper.
- 4 Dip film for three seconds into Field's solution B.
- 5 Wash gently in a jar of tap water, and allow to drain dry in a vertical position.
- 6 When dry, examine as for a thin blood film, paying particular attention to the lower half of the film, where haemoglobin from the lysis makes the best background colour contrast for detection of the parasites.

Films must be absolutely dry before lysis, or else the blood smear is likely to detach from the slide. The films should be washed, in steps 3 and 5, until no more colour comes away from the film.

Blood films from suspected haemorrhagic fevers or HIV

The recommended technique is as follows:

THICK FILMS

- 1 Fix the dried smear directly in 10% buffered formalin for 10 minutes.
- 2 Wash three times (total three minutes) in buffered water and stain with Giemsa as usual.

THIN FILMS

- 1 Fix in methanol for five minutes.
- 2 Fix in formalin as above, wash and stain with Giemsa.

Comment

Nuclei of malaria parasites stain darker by this technique, and the characteristic red blood cell stippling is not always satisfactorily stained.

Examination of films

The theoretical increase in efficiency of examining a thick film rather than a thin one is by a factor of 44 because of the larger volume of blood examined. However, when the parameters of thin and thick blood films were studied by Dowling and Shute⁴ they found that compared with thin films, 60% of parasites were missing or obscured on thick films, and this rose to 80% for very low parasitaemias. For *P. falciparum* gametocytes this value rose to 86% or more. In practice, for ring stages, thick films are 11 times more sensitive than thin. Because of superior preservation of morphology, recognition of parasite species on the thin film is more reliable.

In 100 high power ($\times 100$) fields of the thickest part of a thick film, which takes an expert about three minutes to examine, approximately 0.28 μl blood is present and, if one parasite is seen, there are estimated to be four to five parasites/ μl . In a 30 minute examination of a thick film, the microscopist is estimated to have a 2/3 chance of detecting one parasite/ μl . Where detection of parasite presence is crucial, reexamination of the film by another, equally skilled operator can increase sensitivity.⁵

In a diagnostic laboratory, where blood films are regularly examined for malaria and other parasites, it has been found effective to ensure that each thick film is examined consecutively

by two persons, each of whom will scan 100 high power fields. In special circumstances where the parasite count is thought to be very low and approaching one parasite/ μl , the microscopists may examine 500 high power fields each. In the experience of the authors more extensive examinations are rarely justified, even in the Reference Laboratory.

The thin film is extremely valuable for the specific determination of the malaria parasite, for counting the higher parasitaemias and also as a fail-safe for the thick film procedure. To enhance the possibility of parasite detection on the thin film, particularly for *P. ovale* and *P. vivax*, examine the edges and tail of the film.

In view of the intense visual and mental concentration involved in the examination of blood films, it is important that the operatives should be comfortably seated with the arms suitably supported. The microscope should have a binocular head, and be correctly adjusted for each eye. Not more than 20 films should be examined without a break of 30 minutes doing another, non-microscope activity. In the authors' view 50 thick films, of which the majority are scanty or uninfected, is probably too many for one operative to examine on a daily basis while retaining sanity and the ability to diagnose. A maximum of around 35 should be aimed at.

Counting the parasitaemia

A recognised way of estimating the parasite count per μl on thick films is to use a standard value (8000/ μl) for the white cell count as a multiplier. Thus, parasites in thick film fields are counted until 200 leucocytes have been seen, the parasite count is then multiplied by 40 to give parasites per μl of blood. This takes no account of the known loss of parasites in the thick film, which suggests it is an underestimate, but the "standard" white blood cell value is probably too high, which helps to cancel out this error. The method is widely used for estimation of the intensity of the infection. To convert approximately to percentage parasitaemia, the number of parasites per 200 white cells is divided by 1250.

Similarly, the parasitised cell percentage can be estimated from thin films. Generally, the number of infected cells per 100 red blood cells is counted. The infected cells are counted as one, whether they contain one, or several parasites. Sufficient red blood cells are examined to obtain an estimate of the mean number per high power field in an evenly spread area of the film. Then, parasitised cells in 10 fields are counted to give a mean parasitised cell percentage.

The use of an eyepiece graticule consisting of a square covering most of the field, with a smaller square 1/9 the area of the large square scribed in the corner will facilitate counting the number of erythrocytes per parasite, as follows:

- Choose an area of the film showing evenly distributed erythrocytes, as above.
- Count the erythrocytes in the small square and the parasitised cells in the large square.

Table 1 Differential diagnosis of *Plasmodium* species of man in Giemsa stained thin films of peripheral blood

	<i>P falciparum</i>	<i>P vivax</i>	<i>P malariae</i>	<i>P ovale</i>
Trophozoites				
Ring forms	0.15–0.5 of diameter of RBC; RBC normal size. Cytoplasm very fine with young rings; thick irregular in old rings. Marginal “accolé” forms, forms with two chromatin dots and multiple infections common.	0.3–0.5 of diameter of RBC which are unaltered in size. Cytoplasm circle, thin.	0.3–0.5 of diameter of RBC which are unaltered in size. Cytoplasm circle, thicker.	0.3 of diameter of RBC which are unaltered in size. Cytoplasm circle, thicker.
Growing forms	RBC unaltered in size, sometimes spotted, pale. Parasite compact; pigment dense brown or black mass.	RBC enlarged, stippled. Parasite amoeboid, vacuolated; pigment fine and scattered golden brown.	RBC unaltered in size. Parasite compact, rounded or band shaped; dark brown or black pigments, often concentrates in a long line along one edge of the band.	RBC unaltered in size or slightly enlarged; stippled; may be oval and fimbriated. Parasite compact, rounded; pigment fine brown grains.
Mature schizonts	RBC unaltered in size, sometimes spotted, pale. Parasites about 0.6 of diameter of RBC; nuclei or merozoites 8–24; pigment clumped, black. <i>Not usually seen in peripheral blood.</i>	RBC much enlarged, stippled. Parasites large, filling enlarged RBC; nuclei or merozoites 12–24, usually 16; pigment a golden brown central loose mass.	RBC unaltered in size. Parasite fills RBC completely; nuclei or merozoites 6–12, usually 8, sometimes forming a rosette; pigment brown black central clump.	RBC frequently oval, fimbriated, enlarged and stippled. Parasite as for <i>P malariae</i> but does not fill the RBC entirely; pigment brown central clump.
Gametocytes	RBC distorted. Parasite crescentic.	RBC enlarged, stippled. Parasite large, rounded, filling enlarged RBC.	RBC unaltered in size. Parasite small, round, filling RBC.	RBC slightly enlarged, stippled. Parasite round, not usually filling cell.
Stippling	Maurer’s clefts	Schüffner’s dots	None. (Fine dots after prolonged staining may be seen.)	James’s dots

RBC = red blood cells.

- Repeat the count on subsequent fields until 50 parasitised cells have been counted or 200 erythrocytes have been counted in the small square.
- Multiply the total erythrocytes in the small squares counted by 9. This is the denominator to use when calculating the percentage parasitised erythrocytes.

Comment

Parasitaemia estimation is highly valuable for the clinician, as it is an important determinant of treatment schedules for *P falciparum*. For example, if parasitaemia exceeds 10% in *P falciparum*, exchange transfusion may be indicated. If late trophozoites or early dividing forms of this parasite (usually containing noticeable pigment deposits) are seen in the peripheral blood, this should be reported, as it may indicate that the patient is in a critical condition.⁶

The presence of gametocytes of *P falciparum* in the absence of growing stages is clinically significant in an untreated symptomatic patient as it may indicate the presence of a suppressed active infection. Gametocytes seen in the blood after treatment, however, are of no significance.

Interpretation of thin and thick films

The presence of intra-erythrocytic bodies, generally consisting of a blue staining cytoplasmic area closely associated with a small reddish staining nuclear area and, in the larger, more mature parasites, the presence within the organism of yellow-brown to black malaria pigment, is diagnostic of malaria infection. During the intra-erythrocytic growth of the malaria parasite, it finally divides to give a maximum of 24 infective merozoites. The host cell may show enlargement (*P vivax* and *P ovale*), remain the same size, or shrink (sometimes in *P falciparum* and often in *P malariae*). The erythrocyte membrane may develop surface markings (Schüffner’s and James’s dots) which stain pink with Giemsa at pH 7.2 (*P vivax* and *P ovale*). All stages of the parasite

may be seen in the peripheral blood in the case of *P vivax*, *ovale* and *malariae*, but generally only the small ring parasites and (in older infections) the banana-like gametocytes are found in *P falciparum*. In infections of *P falciparum*, a few intra-erythrocytic spots appear, particularly noticeable in erythrocytes inhabited by the thicker ring forms. These are termed Maurer’s clefts, and should be distinguished carefully from the finer, much more numerous Schüffner’s and James’s dots found in *P vivax* and *P ovale* (table 1 and fig 1)

Serology

Serology is not used routinely for diagnostic purposes as blood films are quicker and detect active infection. However, serology is valuable for:

- Transfusion blood screening, and the investigation of transfusion acquired infections. Serology is the only satisfactory technique currently available for adequately screening transfusion blood, as an antigen or nucleic acid method would have to detect one malaria parasite in a unit of blood. A donor who visited an endemic area more than six months previously and has not developed antibody is unlikely to be carrying a malaria infection. In the unlikely case of an antibody negative donor becoming infective from newly developing dormant hypnozoites in the liver, the organism is expected to be *P vivax* or *ovale*, not the potentially fatal *P falciparum*.
- Retrospective diagnosis.
- Investigation of “cryptic” malaria.
- In endemic areas, serology is invaluable for epidemiological purposes.

For serological studies, blood stage antigen is used, prepared from primate blood infections or from *P falciparum* cultures in the laboratory. Falciparum antigen tends to cross react with antibodies directed against the other species, although generally at a lower titre, so that it can be used as a general screen. The schizont stage of the blood cycle (obtained from cultures in the case of *P falciparum*) is used for

preparation of antigen as this gives a more sensitive test. The blood or culture should be washed well with phosphate buffered saline before use to remove serum or plasma proteins.

For the indirect fluorescent antibody test (IFAT), antigen thick films are made on slides, dried, wrapped in tissue, and stored frozen under desiccation. This antigen is very stable and will last for years provided thawing is carried out in a desiccator.

For ELISA antigen, the infected erythrocytes are lysed with saponin in the presence of protease inhibitors, the erythrocyte material is

removed by centrifugation, nonidet P40 extracts are prepared, and stored frozen. Antigen prepared for ELISA is relatively ephemeral and needs to be used within six months, otherwise false positivity is observed. Commercial kits are available.

Other methods of malaria parasite detection

QUANTITATIVE BUFFY COAT

The first of the practicable commercial kits for diagnosis (quantitative buffy coat, QBC) was based on technology which has been available

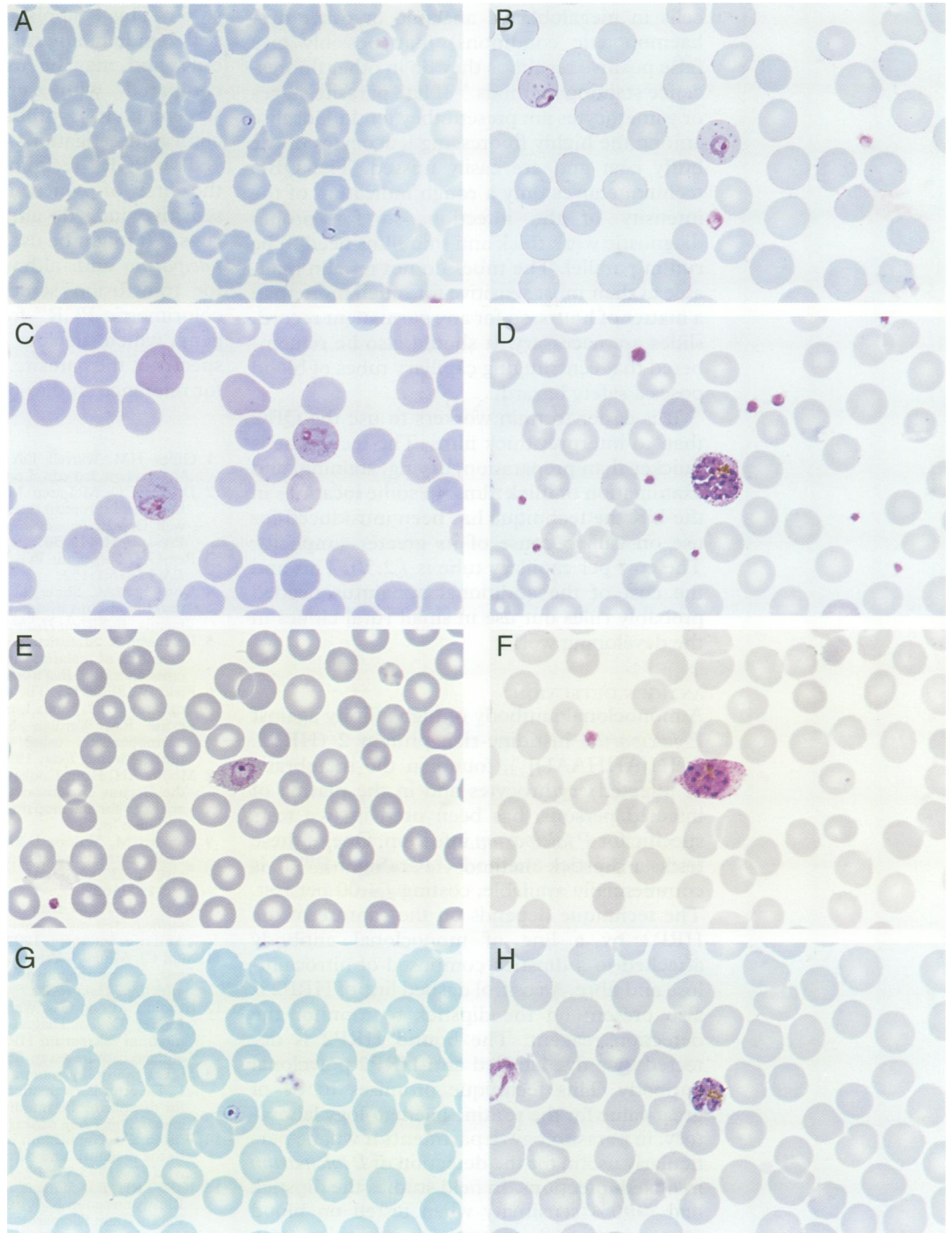


Figure 1 *Plasmodium falciparum*: (A) small ring stage trophozoites and (B) late trophozoite and "accolé" form, showing Maurer's clefts. *Plasmodium vivax*: (C) ring stage amoeboid trophozoites in enlarged cells showing developing Schüffner's dots and (D) mature schizont filling a heavily stippled, enlarged erythrocyte. *Plasmodium ovale*: (E) trophozoite showing an elongated, stippled and fimbriated erythrocyte and (F) almost mature schizont showing eight(?) nuclei, not filling an elongated, stippled and fimbriated erythrocyte. *Plasmodium malariae*: (G) "bird's eye" ring stage and (H) mature schizont with five(?) merozoites filling an unenlarged, unstippled erythrocyte.

for decades, the differential centrifugation of blood and the acridine orange staining of the malaria parasite.⁷ Blood samples in acridine orange coated heparinised tubes are centrifuged and the area just below the buffy coat is examined in situ under a fluorescence microscope to detect the parasitised cells.

In studies in UK laboratory⁸ and in field conditions⁹ the sensitivity has been found to be about the same as the Field's stained thick film. It is still necessary to use films for specific determinations, and it is recognised that the sensitivity for detection of species other than *P falciparum* is appreciably less. Howell-Jolly bodies (nucleic acid remnants in red blood cells in megaloblastic anaemia or other dys-haemopoietic conditions) may possibly give false positive results as they do in other fluorescence staining methods.¹⁰ If late parasite stages or gametocytes are present they tend to localise among the highly fluorescing leucocytes of the buffy coat and are easily missed. The QBC technique gives only a rough indication of the intensity of the infection, so for proper diagnostic work thick and thin films need to be run in parallel. The tubes do not remain readable at their most sensitive for much more than a matter of hours, so for any permanent record, slides are necessary. It should also be remembered that centrifuging capillary tubes of blood poses a safety hazard.

It is easier to train workers to use the QBC than to interpret thick films. The technique is quicker than preparation, drying, staining, and examination of thick films. In some locations in the UK the technique has been introduced for use on call, because of its greater simplicity. The cost per capillary tube is £2.50. This and the cost of the additional apparatus needed probably rules out use in small rural clinics in the developing world.

ANTIGEN DETECTION

A monoclonal antibody of high affinity against *P falciparum* histidine-rich protein 2 (HRP2: AHH[AHHAAD]₂), found in the membrane of infected erythrocytes and in the plasma of infected persons, has been used in two tests specific for *P falciparum* infection. One of these tests, a dipstick method ("ParaSight-F"),¹¹ is commercially available, costing £4.00 per test. The technique depends on the capture of the HRP2 by a line of monoclonal antibody attached to a dipstick composed of nitrocellulose and fibre. A control dashed line of HRP2 is also present on the dipstick to monitor the detection reagent. The bound HRP2 is detected by a dye labelled anti-HRP2 polyclonal antibody. This technique promises to be of great value for the routine haematology laboratory; in parasitology departments it will be particularly useful for the detection of *P falciparum* in mixed infections. In field studies the dipstick had >90% sensitivity when tested on blood containing >60 parasites/μl; positivity may sometimes persist for several days after treatment, and has rarely been reported in unexposed persons.¹² More importantly, false negative results have been reported in a small

number of patients even when parasitaemia above 1000/μl was present. It may be that high antibody level in plasma in some samples from endemic areas is rendering the antigen inaccessible, but this observation remains a worry. It cannot be assumed that a negative ParaSight F test rules out malaria.

NUCLEIC ACID METHODS

We have selected three reports from a rapidly growing literature on nucleic acid detection of malaria.

The probe method,¹³ using alkaline phosphatase for the detection system, seems to be the best of the non-radioactive probes reported so far. This is applicable to carrying out large scale epidemiological surveys for *P falciparum* only, and may be useful, though insensitive compared with serology, for transfusion screening. It is probably not practicable for clinical investigations.

Two PCR¹⁴ techniques are mentioned here, the first of which is reported to be very sensitive indeed, and is applicable to large runs.¹⁵ It might be used epidemiologically for *P falciparum* and, although still too insensitive, for transfusion screening. The second is a colorimetric PCR¹⁶ for a small subunit rRNA gene which detects and identifies all four species of the parasite. It is particularly suitable for reference studies or microepidemiology.

- Gilles HM, Warrell DA (eds). *Bruce Chwatt's Essential Malariaology*. 3rd edn. London: Edward Arnold, 1993.
- Draper CC, McLaren ML. Some applications of immunoassays in tropical diseases. In: Voller A, Bartlett A, Bidwell D, eds. *Immunoassays for the 80's*. Lancaster: MTP Press, 1981:449-56.
- Ree GH, Sargeant PG. Laboratory diagnosis of malaria. *BMJ* 1976;1:152.
- Dowling MAC, Shute GT. A comparative study of thick and thin blood films in the diagnosis of scanty malaria parasitaemia. *Bull World Health Organ* 1966;34:249-67.
- Raghavan K. Statistical considerations in the microscopical diagnosis of malaria, with special reference to the role of cross checking. *Bull World Health Organ* 1966;34:788-91.
- Field JW, Shute PG. The microscopical diagnosis of human malaria. Vol 2. Kuala Lumpur: Government Press, 1956.
- Levine RA, Wardlaw SC, Patton CL. Detection of haemoparasites using quantitative buffy coat analysis tubes. *Parasitol Today* 1990;5:132-4.
- Moody AH, Hunt-Cooke A, Chiodini PL. Experience with the Becton Dickinson QBC II centrifugal haematology analyser for haemoparasites. *Trans R Soc Trop Med Hyg* 1990;84:782.
- Bawden M, Malone J, Slaten D. QBC malaria diagnosis: easily learned and effectively applied in a temporary military field laboratory. *Trans R Soc Trop Med Hyg* 1994;88:302.
- Facer CA. Rapid malaria diagnosis: an update. In: *Rapid methods and automation in microbiology and immunology*. Andover: Intercept, 1994:14-143.
- Shiff CJ, Minjas J, Premji Z. The rapid manual ParaSight-F test. A new diagnostic tool for *Plasmodium falciparum* infection. *Trans R Soc Trop Med Hyg* 1993;87:646-8.
- Beadle C, Long GW, Weiss WR, McElroy PD, Maret SM, Aggrey JO, et al. Diagnosis of malaria by detection of *Plasmodium falciparum* HRP2 antigen with a rapid dipstick antigen capture assay. *Lancet* 1994;343:564-8.
- McLaughlin GL, Subramanian S, Lepers JP, Raharimalala L, Deloron P. Evaluation of a nonisotopic DNA assay kit for diagnosing *Plasmodium falciparum* malaria in Madagascar. *Am J Trop Med Hyg* 1993;48:211-15.
- Wilson SM. Application of nucleic acid based technologies to the diagnosis and detection of disease. *Trans R Soc Trop Med Hyg* 1993;87:609-11.
- Barker RH, Banhongaksora T, Courval JM, Suwonkerd W, Rimwuntragoon K, Wirth DF. A simple method to detect *Plasmodium falciparum* directly from blood samples using the polymerase chain reaction. *Am J Trop Med Hyg* 1992;46:416-26.
- Oliveira DA, Holloway BP, Durigon EL, Collins WE, Lal AA. Polymerase chain reaction and a liquid phase nonisotopic hybridization for species specific and sensitive detection of malaria infection. *Am J Trop Med Hyg* 1995; 52:139-44.