

# Lymphocytic gastritis and coeliac disease: evidence of a positive association

K M Feeley, M A Heneghan, F M Stevens, C F McCarthy

## Abstract

**Aims**—To investigate the prevalence of lymphocytic gastritis in patients with coeliac disease.

**Methods**—Gastric biopsies from 70 patients with coeliac disease were examined by light microscopy for the presence of lymphocytic gastritis, defined as 25 or more intraepithelial lymphocytes/100 gastric columnar epithelial cells.

**Results**—Lymphocytic gastritis was found in seven cases. Positive cases had a mean of 32.1 intraepithelial lymphocytes/100 columnar cells, compared with a mean of 13.9 in negative cases, and 5.15 in non-coeliac controls. No differences were found for age, sex, gastric corpus or antrum, or degree of inflammation in the gastric lamina propria. All intraepithelial lymphocytes were of T cell lineage. Cases not showing lymphocytic gastritis did however show significantly increased gastric intraepithelial lymphocytes compared with non-coeliac controls. Eighteen of 70 cases were positive for *Helicobacter pylori*, and four of seven cases of lymphocytic gastritis were *H pylori* positive; no significant difference was observed between *H pylori* positive and negative patients. Three cases had concomitant ulcerative enteritis, of which none showed lymphocytic gastritis, while five cases had concomitant enteropathy associated T cell lymphoma, of which one showed lymphocytic gastritis.

**Conclusions**—Lymphocytic gastritis occurred in 10% of patients with coeliac disease. Cases without lymphocytic gastritis nevertheless showed increased gastric intraepithelial lymphocytes. Coeliac disease may on occasion be a diffuse lymphocytic enteropathy occurring in response to gluten. Lymphocytic gastritis outside coeliac disease may involve an immune response to luminal antigens, such as *H pylori*, not unlike the response to gluten in patients with coeliac disease.

(J Clin Pathol 1998;51:207-210)

**Keywords:** lymphocytic gastritis; coeliac disease; ulcerative enteritis; enteropathy associated T cell lymphoma; *Helicobacter pylori*

Coeliac disease is a permanent condition of gluten intolerance in which exposure to gluten results in characteristic pathological changes in the gastrointestinal tract, most notably in the small intestine, where the histological features include villous atrophy, crypt hyperplasia, mononuclear cell infiltration of the lamina pro-

pria, and a pronounced intraepithelial lymphocytosis. The condition shows a particular predilection for the west of Ireland, where the prevalence of 1/300 population is one of the highest in the world.<sup>1</sup> Lymphocytic gastritis is a histological entity characterised by severe intraepithelial lymphocytosis of the gastric mucosa. The condition is said to be present when mature intraepithelial lymphocytes number more than 25/100 gastric columnar epithelial cells. This may or may not be associated with mononuclear inflammatory cell infiltration of the lamina propria. The condition is frequently recognised endoscopically as “vari-oliform gastritis”<sup>2</sup> characterised by aphthous erosions, nodularity, and hypertrophic gastropathy, not unlike that seen in Menetrier’s disease. The essential cause of lymphocytic infiltration of the gastric epithelium is not known, but lymphocytic gastritis has previously been described in association with coeliac disease,<sup>3-6</sup> where the prevalence has been reported to be as high as 45%. It has also been described in association with *Helicobacter pylori* infection,<sup>7,8</sup> gastric adenocarcinoma,<sup>9</sup> and primary gastric lymphoma.<sup>10</sup>

This study investigated 70 patients with coeliac disease, in whom both gastric and small intestinal histology were available, and assessed the prevalence of lymphocytic gastritis in this group.

## Methods

Gastric and small intestinal biopsy specimens from 70 patients with coeliac disease were recovered from the files of the department of pathology, University College Hospital, Galway. Gastric corpus and antrum specimens were available in 15 cases, corpus only in 16 cases, and antrum only in 39 cases. All small intestinal specimens were from the second part of the duodenum. Three of 70 cases had concomitant histologically proved ulcerative enteritis, while five had concomitant enteropathy associated T cell lymphoma (table 1). Haematoxylin and eosin stained sections were viewed by an experienced pathologist (KF) and the number of intraepithelial lymphocytes/100 gastric and duodenal columnar epithelial cells were counted manually. At least five high power fields (×400) were viewed randomly. Lymphocytes were recognised by their basophilic nuclear chromatin pattern, irregular nuclear outline, and clear perinuclear halo. In addition, sections from all specimens were immunostained with the pan T cell marker, anti-CD3 (Dako, High Wycombe, Bucks, UK) at 1/50 dilution, after pretreatment with enzyme digestion. *H pylori* was recognised in

Department of Pathology, University College Hospital, Galway, Ireland  
K M Feeley

Department of Gastroenterology, University College Hospital  
M A Heneghan  
F M Stevens  
C F McCarthy

Correspondence to:  
Dr K M Feeley, Department of Pathology, Royal Hallamshire Hospital, Glossop Road, Sheffield S10 2JF, UK.

Accepted for publication  
9 December 1997

Table 1 Intraepithelial lymphocytes (IEL) per 100 epithelial cells in patients with coeliac disease (CD) with or without lymphocytic gastritis (LG) and *Helicobacter pylori* infection, and control cases

	Number of patients	Mean (SD) IEL count (per 100 epithelial cells; gastric unless stated)
CD patients	70	25.7 (5.92)*
CD patients with LG	7	32.1 (7.53)*
CD patients with LG (antrum)	6	33.2 (8.74)
CD patients with LG (corpus)	6	30.8 (6.89)†
CD patients with LG; <i>H pylori</i> positive	4	31.7 (7.22)
CD patients with LG; <i>H pylori</i> negative	3	32.8 (8.39)‡
CD patients with UE	3	11.3 (5.11)§
CD patients with EATL	5	14.3 (8.32)§
CD patients without LG	63	13.9 (8.39)¶
CD patients without LG; moderate IELs	8	19.9 (3.28)¶
CD patients without LG; mild IELs	46	10.1 (2.23)¶
CD patients with LG; duodenal IELs	7	36.6 (4.89)**
CD patients without LG; duodenal IELs	63	32.9 (19.5)**
Controls	70	5.15 (4.34)
Controls; <i>H pylori</i> positive	38	6.6 (5.08)
Controls; <i>H pylori</i> negative	32	3.7 (2.04)††
Controls; duodenal IELs	70	2.5 (1.94)

\* $p < 0.0001$  compared with controls; † $p > 0.05$  compared with values from antrum; ‡ $p > 0.05$  compared with values from *H pylori* positive patients; § $p > 0.05$  compared with other CD patients in study population; ¶ $p < 0.0001$  compared with controls; \*\* $p < 0.0001$  compared with duodenal IELs in controls; †† $p > 0.05$  compared with *H pylori* positive controls. UE, ulcerative enteritis; EATL, enteropathy associated T cell lymphoma.

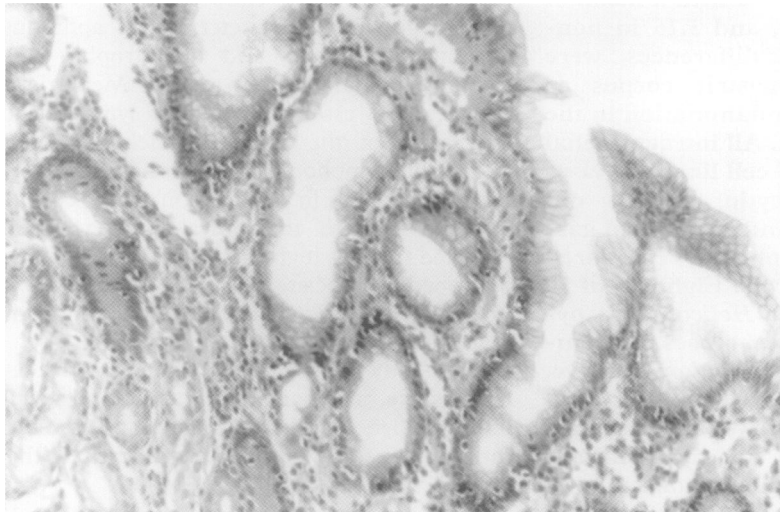


Figure 1 Lymphocytic gastritis in a patient with coeliac disease characterised by numerous lymphocytes in the gastric surface and pit epithelium (haematoxylin and eosin, original magnification  $\times 100$ ).

gastric specimens on haematoxylin and eosin sections; a Giemsa stain was performed on cases showing active neutrophilic gastritis where *H pylori* was not seen on haematoxylin and eosin stains. Gastric and duodenal biopsies from 70 age and sex matched non-coeliac patients were selected as controls. Statistical analysis was performed using the Mann-Whitney U test.

### Results

Lymphocytic gastritis was diagnosed if 25 or more intraepithelial lymphocytes were present for each 100 gastric columnar epithelial cells (fig 1); on this basis, seven cases (10%) displayed lymphocytic gastritis. These had a mean of 32.1 intraepithelial lymphocytes/100 columnar cells, compared with a mean of 13.9 in non-lymphocytic gastritis cases ( $p < 0.0001$ ), and with a mean of 5.15 in non-coeliac controls ( $p < 0.0001$ ) (table 1). On reviewing clinical records, three of these seven cases were newly diagnosed coeliac patients, while the remaining four reported poor adher-

ence to gluten free diet, and were symptomatic at the time of biopsy. The typical endoscopic appearances of varioliform gastritis were not observed in any of the cases, although antral aphthous erosions were noted in two cases. The ages of lymphocytic gastritis patients ranged from 43 to 68 years (mean 52.3), compared with 26 to 71 years (mean 48.8) in the study population as a whole. No sex difference was observed; four of seven cases were women, compared with 43 of 70 in the study population as a whole. Four of seven lymphocytic gastritis cases had *H pylori* infection in the gastric antrum; the mean intraepithelial lymphocyte count of *H pylori* positive lymphocytic gastritis cases was 31.7, compared with 32.8 in *H pylori* negative lymphocytic gastritis cases ( $p > 0.05$ ) (table 1). All four *H pylori* positive cases had active neutrophilic gastritis in addition to lymphocytic gastritis. Five of seven cases had lymphocytic gastritis co-existing in the gastric antrum and corpus; antrum only was available in one case, and corpus only in another case. The mean intraepithelial lymphocyte count was 33.2 in the antrum, and 30.8 in the corpus ( $p > 0.05$ ). All seven cases had villous atrophy of the small intestine, where the mean duodenal intraepithelial lymphocyte count was 36.6. CD3 staining confirmed that virtually all intraepithelial lymphocytes ( $> 98.5\%$ ) were of T cell lineage. Three of seven cases had repeat biopsies over intervals ranging from 14 to 54 months, and all three had persistence of lymphocytic gastritis, with a mean intraepithelial lymphocyte count of 34.1 on repeat biopsy, compared with 32.6 initially. In two of these three cases, adherence to the gluten free diet was reported as remaining poor.

Of the 63 cases which did not have lymphocytic gastritis, eight (11.4%) had moderately increased numbers of gastric intraepithelial lymphocytes, defined as 15–25 intraepithelial lymphocytes/100 columnar cells, with a mean of 19.9. A mild increase in numbers of gastric intraepithelial lymphocytes, defined as 5–15 intraepithelial lymphocytes/100 columnar cells, was seen in 46 (65.7%) cases, with a mean of 10.1. These compared with a mean of 5.15 in the non-coeliac control group ( $p < 0.001$ ). The mean intraepithelial lymphocyte count in the small intestine of the non-lymphocytic gastritis group was 32.9, compared with 2.5 in the non-coeliac controls ( $p < 0.0001$ ) (table 1). Fourteen of 63 non-lymphocytic gastritis cases were *H pylori* positive; the mean gastric intraepithelial lymphocyte count in this group was 13.4, compared with 11.2 in the *H pylori* negative, non-lymphocytic gastritis group ( $p > 0.05$ ).

Occasional complications of coeliac disease include ulcerative enteritis and enteropathy associated T cell lymphoma. Of the three cases included that had concomitant histologically proven ulcerative enteritis, none had lymphocytic gastritis; the mean gastric intraepithelial lymphocyte count was 11.3. Of the five with proven enteropathy associated T cell lymphoma, one had lymphocytic gastritis; the mean intraepithelial lymphocyte count overall in this group of five was 14.3 (table 1).

Of 70 non-coeliac control cases, none showed lymphocytic gastritis; the mean gastric intraepithelial lymphocyte count was 5.15. Thirty eight of these 70 cases had *H pylori* infection; the mean intraepithelial lymphocyte count in this group was 6.6, compared with 3.7 in the *H pylori* negative, non-coeliac control group ( $p > 0.05$ ) (table 1).

### Discussion

Our results confirm an association between coeliac disease and lymphocytic gastritis, with 10% of the patients with coeliac disease having lymphocytic gastritis. All of these occurred in the setting of untreated, symptomatic coeliac disease, either newly diagnosed or where adherence to the gluten free diet was poor, and villous atrophy of the small intestine was present in all cases. No evidence of the endoscopic entity varioliform gastritis was found in any case, although two cases did have aphthous erosions. In patients who underwent further endoscopies, and on whom further histology was available, we found that lymphocytic gastritis was persistent over time, although these patients did tend to have continuing poor adherence to gluten free diet. The persistence of lymphocytic gastritis over time has been noted in previous studies.<sup>8-11</sup> We found that *H pylori* infection in the setting of coeliac disease conferred no increased risk of lymphocytic gastritis. In addition, we found that cases of coeliac disease complicated by ulcerative enteritis and enteropathy associated T cell lymphoma had no increased prevalence of lymphocytic gastritis. It should be noted that the duodenal intraepithelial lymphocyte counts in patients without typical lymphocytic gastritis were high, and did not differ significantly from those of the patients positive for lymphocytic gastritis. This may indicate a selection bias, in that patients presenting with active symptoms of coeliac disease may be more likely to have a gastric biopsy in addition to a duodenal biopsy, than patients presenting for routine coeliac follow up who may only have a duodenal biopsy. However, lymphocytic gastritis was seen only in patients with unequivocal duodenal villous atrophy; it was not found in any patients who had a normal duodenal villous pattern.

Our results also show that in coeliac patients not exhibiting florid intraepithelial lymphocytosis, the gastric epithelium nevertheless contained significantly increased numbers of lymphocytes compared with controls, indicating a more minor degree of intraepithelial lymphocytosis, not quite meeting the criteria for typical lymphocytic gastritis. Similar findings were noted in a study by Alsaigh *et al*, who looked at the intraepithelial lymphocytic response in the stomach and oesophagus in children with coeliac disease.<sup>6</sup> Other studies have shown an association between colonic lymphocytosis, or "lymphocytic colitis", and coeliac disease,<sup>12</sup> and it has been suggested that at least a subset of cases of coeliac disease may involve a diffuse T cell lymphocytic enteropathy occurring in response to gluten. Our work supports this hypothesis.

It is interesting that none of our seven cases of lymphocytic gastritis had the typical endoscopic appearance of varioliform gastritis. Karttunen and colleagues<sup>3</sup> and Wolber and colleagues<sup>4</sup> both found a positive association between coeliac disease and lymphocytic gastritis, but neither showed a specific correlation with varioliform gastritis. However, lymphocytic gastritis has been shown to occur outside coeliac disease, and in up to 70% of such cases varioliform gastritis has been reported at endoscopy.<sup>2,13</sup> Various aetiological factors including *H pylori* have been implicated in these cases. The endoscopic similarity of varioliform gastritis to Menetrier's disease has been noted, and Wolfsen and colleagues<sup>14</sup> recommended that patients with enlarged gastric folds should be viewed as two distinct groups; one with massive foveolar hypertrophy with minimal or no inflammation to be designated true Menetrier's disease, and the other with foveolar hypertrophy with severe intraepithelial lymphocytic inflammation to be designated hypertrophic lymphocytic gastritis. Various studies have shown an association between hypertrophic lymphocytic gastritis and protein malabsorption,<sup>15-17</sup> while Lynch *et al* showed that lymphocytic gastritis in the absence of histological evidence of villous atrophy is associated with abnormal permeability of the small intestine, and suggested that lymphocytic gastritis per se is associated with impaired small bowel function.<sup>11</sup> It is tempting to speculate that lymphocytic gastritis outside of coeliac disease may be an immune response to luminal antigens, such as *H pylori*, not unlike the response to gluten seen in coeliac disease. This response might be most noticeable in the stomach, with consequent foveolar hypertrophy and endoscopic varioliform gastritis, and a less florid response might be seen elsewhere in the gastrointestinal tract. Furthermore, coeliac associated lymphocytic gastritis might be the less florid gastric equivalent of the small intestinal response to gluten. It is worth noting in this regard that the gastric epithelium of our non-coeliac control patients did contain lymphocytes, albeit very few, and that the figures were slightly, although not significantly, higher for *H pylori* positive than for *H pylori* negative patients. Finally, it should be noted that our finding of a 10% prevalence of lymphocytic gastritis in coeliac disease is significantly lower than that reported previously, where two studies have found a prevalence of 45%<sup>4</sup> and 36%.<sup>5</sup> While this could simply be sampling error, the coeliac population of western Ireland is thought to be similar and comparable to coeliac populations elsewhere, and the difference might also be caused by over diagnosis in the past. It may be true that lymphocytic gastritis in the setting of coeliac disease is not a distinct entity but, rather, an inconsistent reflection of the true pathology of the condition, which is to be found in the small intestine. Recent work has shown the likelihood of linkage of non-human leucocyte (HLA) loci to coeliac disease,<sup>18</sup> in addition to the well described HLA haplotypes A1, B8, DR3, DQ2. Further studies correlating the HLA and

non-HLA profile of patients with lymphocytic gastritis and coeliac disease with the antigen responsiveness of gastrointestinal lymphocytes in these patients would serve to clarify the relations between the two conditions.

Thanks are extended to Drs M P G Little, C E Connolly, J Callaghan, and G Mortimer, consultant pathologists at University College Hospital, Galway, upon whose diagnostic material the above work was based.

- 1 Mylotte M, Egan-Mitchell B, McCarthy CF, et al. Incidence of coeliac disease in the West of Ireland. *BMJ* 1973;i:703-5.
- 2 Haot J, Hamichi L, Wallez L, et al. Lymphocytic gastritis: a newly described entity: a retrospective endoscopic and histological study. *Gut* 1988;29:1258-64.
- 3 Karttunen T, Niemala S. Lymphocytic gastritis and coeliac disease. *J Clin Pathol* 1990;43:436-7.
- 4 Wolber R, Owen D, del Buono L, et al. Lymphocytic gastritis in patients with coeliac sprue or sprue like intestinal disease. *Gastroenterology* 1990;98:310-15.
- 5 De Giacomo C, Gianatti A, Negrini R, et al. Lymphocytic gastritis: a positive relationship with coeliac disease. *J Pathol* 1994;124:57-62.
- 6 Alsaigh N, Odze R, Goldman H, et al. Gastric and esophageal intraepithelial lymphocytes in pediatric coeliac disease. *Am J Surg Pathol* 1996;20:865-70.
- 7 Dixon MF, Wyatt JI, Burke DA, et al. Lymphocytic gastritis—relationship to *Campylobacter pylori* infection. *J Pathol* 1988;154:125-32.
- 8 Niemala S, Karttunen T, Kerola T, et al. Ten year follow up study of lymphocytic gastritis: further evidence on *Helicobacter pylori* as a cause of lymphocytic gastritis and corpus gastritis. *J Clin Pathol* 1995;48:1111-16.
- 9 Griffiths AP, Wyatt JI, Jack AS, et al. Lymphocytic gastritis, gastric adenocarcinoma, and primary gastric lymphoma. *J Clin Pathol* 1994;47:1123-4.
- 10 Miettinen A, Karttunen T, Alavaikko M. Lymphocytic gastritis and *Helicobacter pylori* infection in gastric lymphoma. *Gut* 1995;37:471-6.
- 11 Lynch DA, Sobala GM, Dixon MF, et al. Lymphocytic gastritis and associated small bowel disease: a diffuse lymphocytic enteropathy? *J Clin Pathol* 1995;48:939-45.
- 12 Wolber R, Owen D, Freeman H. Colonic lymphocytosis in patients with coeliac sprue. *Hum Pathol* 1990;21:1092-6.
- 13 Haot J, Jouret A, Willette M, et al. Lymphocytic gastritis—prospective study of its relationship with varioliform gastritis. *Gut* 1990;31:282-5.
- 14 Wolfsen H, Carpenter H, Talley N. Menetrier's disease: a form of hypertrophic gastropathy or gastritis? *Gastroenterology* 1993;104:1310-19.
- 15 Crampton JR, Hunter JO, Neale G, et al. Chronic lymphocytic gastritis and protein losing enteropathy. *Gut* 1989;30:71-4.
- 16 Wolber RA, Owen DA, Anderson FH, et al. Lymphocytic gastritis and giant gastric folds associated with gastrointestinal protein loss. *Mod Pathol* 1991;4:13-15.
- 17 Farahat K, Hainaut P, Jamar F, et al. Lymphocytic gastritis: an unusual cause of hypoproteinaemia. *J Intern Med* 1993;234:95-100.
- 18 Zhong F, McCombs CC, Olson JM, et al. An autosomal screen for genes that predispose to coeliac disease in the Western counties of Ireland. *Nat Genet* 1996;14:329-33.