

Short reports

Granulocytic sarcoma with expression of CD30

Martin Fickers, Paul Theunissen

Abstract

A case of a young man with a spinal epidural tumour, initially diagnosed as large cell anaplastic malignant lymphoma, is reported. The tumour consisted of poorly differentiated cells showing immunoreactivity with antibodies directed against CD30 and CD45. Ten months later the patient developed acute myeloid leukaemia. The histological slides of the epidural tumour were reviewed, including additional enzymochemical and immunocytochemical stains. As the tumour showed immunoreactivity for myeloperoxidase and chloroacetate esterase, it was reclassified as a granulocytic sarcoma.

(*J Clin Pathol* 1996;49:762-763)

Keywords: granulocytic sarcoma, acute myeloid leukaemia, CD30 immunoreactivity.

antigen. A group of CD30 positive, large cell anaplastic lymphomas (LCAL) have been recognised as a separate entity among non-Hodgkin's lymphomas. Most of these lymphomas are of T cell origin, while the remaining are either of B cell origin or fail to express any lineage markers (null cell type). Epithelial membrane antigen (EMA), typically a marker for epithelial cells, is expressed in over 50% of these tumours.^{3,4} Extranodal involvement in this group of neoplasms is not unusual.³ Later, it became clear that Ki-1 is not a cell lineage specific antigen but that it also occurred in non-lymphocytic cell lines, such as the K562 and HL-60 cell lines derived from chronic myelogenous leukaemia (CML)⁵ and acute myeloid leukaemia (AML),^{5,6} respectively, and even in some non-haemopoietic cells and tumours—for example, embryonal carcinoma.⁷

Case report

A 28 year old man was admitted to hospital because of back pain, sensory loss in both legs and disturbances of gait. General examination revealed obesity. Enlargement of lymph nodes was not present. Peripheral blood counts were normal.

Magnetic resonance imaging (MRI) showed an epidural tumour at T9. Neurosurgical decompression of the spinal cord was performed. Histological examination of a biopsy specimen showed a poorly differentiated CD45 + CD30 + tumour (Ber-H2; Dako, Glostrup, Denmark) (fig 1). Tumour cells did not express EMA, or T or B cell markers (CD3, CD20). Electron microscopy was not performed. The tumour was classified as a Ki-1 positive LCAL, null cell type. A computed tomography scan of the chest and the abdomen did not reveal the presence of tumour metastases. There was no tumour infiltration of the bone marrow. However, tumour cells were detected in the cerebrospinal fluid (CSF).

Chemotherapeutic treatment was initiated with CHOP (cyclophosphamide, doxorubicin, vincristine, prednisolone) and intrathecal administration of methotrexate. The tumour cells disappeared from the CSF, but both the erythrocyte sedimentation rate (ESR) and the lactate dehydrogenase (LDH) concentration increased. After switching CHOP to DHAP (dexamethasone, high-dose Ara-C, platinum) chemotherapy, the ESR and LDH concentra-

Department of Internal Medicine, De Wever Hospital, PO Box 4446, 6401 CX Heerlen, The Netherlands
M Fickers

Department of Pathology
P Theunissen

Correspondence to:
Dr Martin Fickers.

Accepted for publication
7 May 1996

The Ki-1 monoclonal antibody was originally raised in 1981 against the Hodgkin's disease derived cell line L428.¹ The antibody showed a modest affinity for the Ki-1 antigen (later renamed CD30 antigen, a membrane bound 105 kilodalton molecule) on acetone fixed cryostat sections but was unreactive in routinely processed histological material. In 1989 a new monoclonal antibody, Ber-H2, was prepared by Schwarting *et al*² against a different, formaldehyde resistant epitope of the same

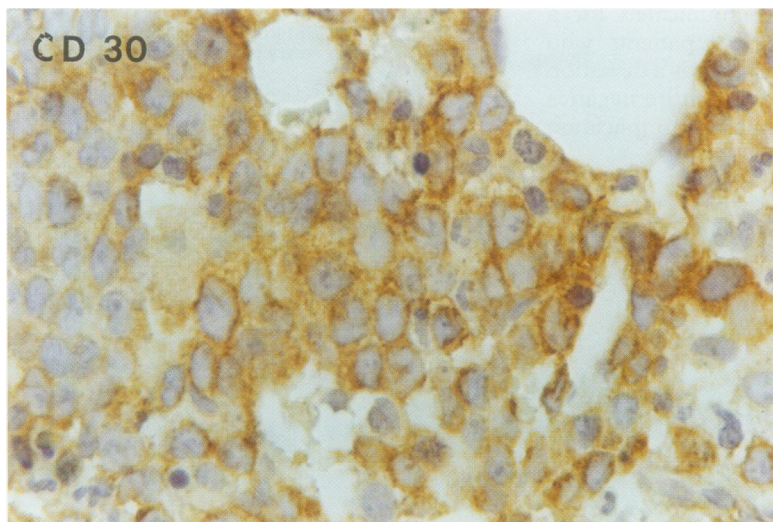


Figure 1 Spinal tumour stained with antibody directed against CD30 (immunoperoxidase technique; clone Ber-H2; original magnification $\times 400$).

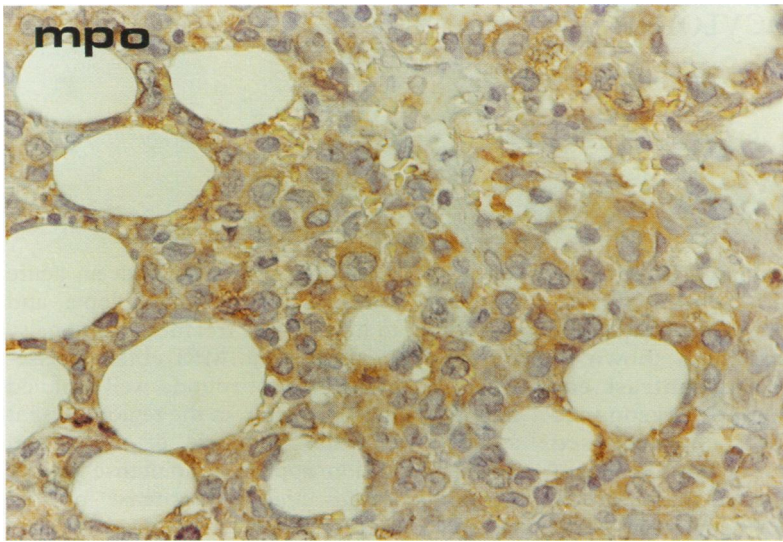


Figure 2 Spinal tumour stained with antibody directed against MPO (immunoperoxidase technique; polyclonal; original magnification $\times 250$).

tion decreased, but on MRI residual tumour was still present with some intravertrebral extension. Local radiotherapy was started. A few weeks after completing a second course of radiotherapy for spinal relapse from T1 to T7, an enlarged cervical lymph node and pleural effusion were found. Fine needle aspiration revealed tumour cells at both sites. CD30 positive tumour cells were detected in the bone marrow. After starting chemotherapy with DHAP and later ICE (ifosfamide, carboplatin, etoposide), tumour cells were found in the CSF and in the peripheral blood. Some of the tumour cells in the peripheral blood had azurophilic granules in the cytoplasm and FACS analysis showed expression of myeloperoxidase (MPO; 98%), CD13 (86%), CD33 (94%), CD34 (93%), and CD45 (100%). There was no expression of CD3 or CD20. CD30 expression was not examined. A diagnosis of AML was established. The patient was discharged from hospital and received further supportive therapy until his death 13 months after the first admission.

The histological slides of the epidural tumour were reviewed and additional immunohistochemical stains were applied. Most of the tumour cells showed weak immunoreactivity for MPO (Dako) (fig 2). Less than 5% of the tumour cells were positive on staining with chloroacetate esterase (CAE). Retrospectively, the tumour was classified as poorly differentiated granulocytic sarcoma.

Discussion

Granulocytic sarcoma (chloroma, extramedullary myeloid cell tumour or EMT) has been defined as a "localized tumour mass composed of immature cells of the granulocytic series". It can occur in association with CML and AML⁸ or precede AML.⁹ Involvement of the spine, as in the present case, has been described previously.⁹ In the series reported by Meis *et al*⁹ 12 (75%) of 16 cases were misdiagnosed initially, most frequently as large cell lymphoma, as in the present case. The poorly differentiated (predominantly myeloblastic) cases were all misdiagnosed initially.

Nevertheless, these authors claim that the growth pattern, the nuclear morphological features and often the cytoplasmic features in granulocytic sarcoma are different from those of large cell lymphoma. Granulocytic sarcoma infiltrates tissue with preservation of the tissue architecture, whereas LCAL is often associated with tissue destruction and coagulation necrosis. Cells in granulocytic sarcoma have round to oval, reniform, or many lobed nuclei with rather small nucleoli, a thin nuclear membrane and a delicate chromatin pattern. Cells in large cell lymphomas have large nucleoli, a thick nuclear membrane and coarsely clumped chromatin. In more mature granulocytic sarcoma tumour cells there is a moderate amount of eosinophilic and granular cytoplasm, in contrast to the lesser amount of amphophilic cytoplasm seen in LCAL. However, the morphological heterogeneity (including nuclear characteristics) in LCAL is emphasised in a study by Penny *et al*¹⁰ who found that only eight of 24 cases of LCAL had prototypic cytological features.

A new finding in the present case was the fact that tumour cells of granulocytic sarcoma and AML can express CD30 in vivo. In an immunohistochemical study of 28 cases of extramedullary myeloid cell tumours by Traweek *et al*¹⁰ none of the formalin fixed tumours showed CD30 (Ber-H2; Dako) reactivity. CD30 immunoreactivity has, however, been detected in cell lines derived from CML and AML.^{5,6} In a pilot study on archival material we found that tumour cells from three of nine patients with AML expressed CD30.

The present case report again stresses the fact that CD30 is not a cell line specific marker. In all cases of LCAL, especially of the so-called null cell type and in all atypical lymphoid cell infiltrates, a granulocytic sarcoma or leukaemic infiltration should be excluded by appropriate stains, including anti-MPO, a lineage specific marker for myeloid cells.

- Stein H, Gerdes J, Schwab U, Lemke H, Mason DY, Ziegler A, *et al*. Identification of Hodgkin and Sternberg-Reed cells as a unique cell type derived from a newly-detected small-cell population. *Int J Cancer* 1982;30:445-59.
- Schwartz R, Gerdes J, Dürkop H, Falini B, Pileri S, Stein H, Ber-H2: a new anti Ki-1 (CD30) monoclonal antibody directed at a formalin-resistant epitope. *Blood* 1989; 74:1678-89.
- Penny RJ, Blaustein JC, Longtine JA, Pinkus GS. Ki-1-positive large cell lymphomas, a heterogeneous group of neoplasms. *Cancer* 1991;68:362-73.
- Chott A, Kaserer K, Augustin I, Vesely M, Heinz R, Oehlinger W, *et al*. Ki-1 positive large cell lymphoma. A clinicopathologic study of 41 cases. *Am J Surg Pathol* 1990;14:439-48.
- Andreesen R, Osterholz J, Löhr GW, Bross KJ. Hodgkin cell-specific antigen is expressed on a subset of auto- and alloactivated T (helper) lymphoblasts. *Blood* 1984; 63:1299-302.
- Dalton WT, Ahearn MJ, McCredie KB, Freireich EJ, Stass SA, Trujillo JM. HL-60 cell line was derived from a patient with FAB-M2 and not FAB-M3. *Blood* 1988;71:242-7.
- Pallesen G, Hamilton-Dutoit SJ. Ki-1 (CD30) antigen is regularly expressed by tumor cells of embryonal carcinoma. *Am J Pathol* 1988;133:446-50.
- Neiman RS, Barcos M, Berard C, Mann R, Rydell RE, Bennett JM. Granulocytic sarcoma: a clinicopathologic study of 61 biopsied cases. *Cancer* 1981;48:1426-37.
- Meis JM, Butler JJ, Osborne BM, Manning JT. Granulocytic sarcoma in nonleukemic patients. *Cancer* 1986;58:2697-709.
- Traweek ST, Arber DA, Rappaport H, Brynes RK. Extramedullary myeloid cell tumors. An immunohistochemical and morphologic study of 28 cases. *Am J Surg Pathol* 1993;17:1011-19.