

# Villous adenoma arising in Meckel's diverticulum

Corrado Minimo, Aleksander Talerman

## Abstract

**The first well documented case of villous adenoma arising in a Meckel's diverticulum not associated with a carcinoma is reported. A 21 year old man with long history of medically treated ulcerative colitis was admitted to hospital with severe pain and bleeding. Total abdominal colectomy and ileo-anal anastomosis was performed and during this procedure Meckel's diverticulum containing a villous adenoma showing minimal dysplasia was found and resected. The diverticulum was lined partly by ileal and partly by gastric epithelium, and the villous adenoma originated from the gastric mucosa.**

(J Clin Pathol 1998;51:485-486)

Keywords: Meckel's diverticulum; villous adenoma; gastric mucosa

Neoplasms arising from Meckel's diverticulum are rare, and malignant tumours are reported much more often than benign.<sup>1-3</sup> Among the malignant tumours the most common are insular or midgut carcinoids, closely followed by leiomyosarcomas, and less often by adenocarcinomas.<sup>1-3</sup> Among the benign tumours, leiomyomas are the most frequent, followed by fibromas, neurofibromas, angiomas, lipomas, and adenomas.<sup>1-3</sup> We could find only one well documented case of an adenoma, which was associated with an adenocarcinoma reported previously.<sup>4</sup> An adenoma was also included in a review of adenocarcinomas arising from Meckel's diverticulum, but no details of the patient's symptoms and outcome were provided and it appears that the case mentioned was probably the one mentioned above.<sup>5</sup> We report here the incidental finding of a villous adenoma arising in Meckel's diverticulum in a patient who underwent surgery for extensive ulcerative colitis. To the best of our knowledge, this is the first case of a villous adenoma unassociated with adenocarcinoma that has been reported.

## Case report

A 21 year old man with a long history of ulcerative colitis treated with steroids presented with symptoms of severe intermittent cramping and bleeding. Since the disease did not respond satisfactorily to the treatment, the patient underwent a total abdominal colectomy with J pouch and ileo-anal anastomosis. During surgery, after the creation of a loop ileostomy, a Meckel's diverticulum was found and resected. The postoperative course was uneventful; the patient did well and was discharged on the seventh postoperative day. He is well 18 months after surgery.

The excised specimen consisted of 160 cm of colon and adjacent terminal ileum which contained a Meckel's diverticulum measuring 4 × 2.5 × 1.0 cm. The colonic mucosa showed changes of severe long standing ulcerative colitis. Upon opening the Meckel's diverticulum the mucosa showed a small punctuate 0.1 cm haemorrhagic spot and small villous projections in the fundic region. Histological examination confirmed that the colon was affected by severe ulcerative colitis. The Meckel's diverticulum was found to be partly lined by small intestinal ileal mucosa and partly by gastric mucosa and contained a villous adenoma measuring 0.8 cm and rising 0.2 cm above the surface of the lining mucosa. The villous adenoma was found to be arising from the gastric mucosa (fig 1). The adenoma showed a fine papillary pattern with delicate fibrovascular cores. Mitotic activity was present in the epithelial lining but there was only minimal dysplasia (fig 2). Oxyntic cells and the other cellular components of gastric epithelium were present in the gastric mucosa (fig 3). The ileal mucosa was normal.

## Discussion

Meckel's diverticulum represents the remnant of the proximal portion of the stalk of the yolk sac. It appears as a finger-like pouch ranging from two to eight centimetres in length, and is

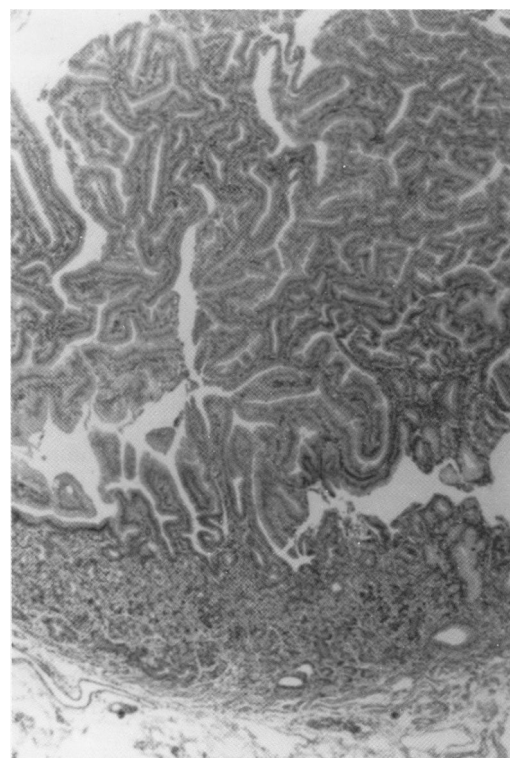


Figure 1 Villous adenoma arising from a Meckel's diverticulum. The neoplasm arises in the metaplastic gastric portion. (Haematoxylin and eosin ×129.)

Department of Pathology, Cell Biology and Anatomy, Thomas Jefferson University, Philadelphia, Pennsylvania, USA  
C Minimo  
A Talerman

Correspondence to: Professor A Talerman, Department of Pathology, Thomas Jefferson University, Room 285Q, 11th and Walnut Street, Philadelphia, PA 19107-5244, USA.

Accepted for publication 5 March 1998

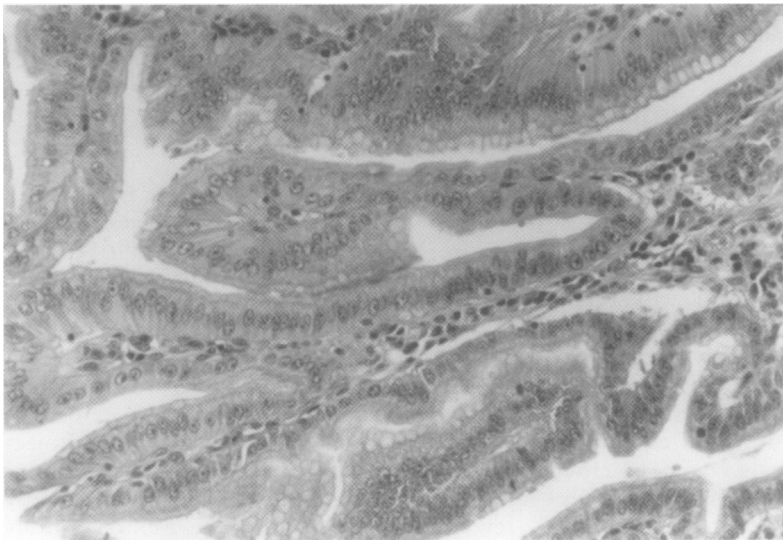


Figure 2 Villous adenoma arising from a Meckel's diverticulum: note the fine papillary pattern with delicate fibrovascular cores. Mitoses are present in the epithelial lining and there is minimal dysplasia. (Haematoxylin and eosin  $\times 289$ .)

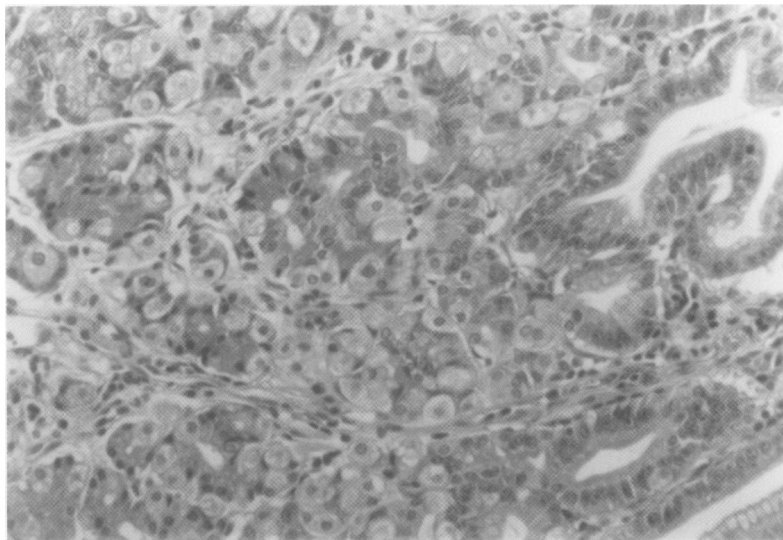


Figure 3 Metaplastic gastric mucosa in Meckel's diverticulum from which the villous adenoma had arisen. (Haematoxylin and eosin  $\times 289$ .)

located on the antimesenteric border of the ileum, at 30 cm proximal to the ileocecal valve in the infant and at 90 cm in the adult, but these distances tend to vary in different individuals. Meckel's diverticulum is the most common malformation of the gastrointestinal tract, with an incidence from 0.5% to 2% in necropsy series and a male to female ratio of approximately 3:2.<sup>6-8</sup> It is usually lined by small intestinal mucosa, but ectopic tissues are frequent findings, the most common being gastric epithelium with parietal peptic and oxyntic cells. Duodenal and large intestinal epithelium and pancreatic tissue are not uncommon. Most often Meckel's diverticulum is found incidentally during necropsy or laparotomy. Less often (8–22% of cases) it is symptomatic, with inflammation and intestinal obstruction being more frequent in adults and haemorrhage in the paediatric age group.<sup>2,6</sup>

Neoplasms arising in a Meckel's diverticulum are uncommon and are usually malignant, consisting most often of insular carcinoids and leiomyosarcomas. Adenocarcinomas are the second most common epithelial malignant neoplasms arising in Meckel's diverticulum, after carcinoid tumour, and are associated with morbidity and mortality.<sup>5</sup> Although a single case of adenoma was mentioned in a review of adenocarcinomas arising in Meckel's diverticulum,<sup>5</sup> the only well documented case of an adenoma arising in Meckel's diverticulum was reported by Abdel-Bari and was associated with an adenocarcinoma.<sup>4</sup> The patient was a 64 year old male, who was operated for carcinoma of the cecum and a Meckel's diverticulum lined by ileal mucosa and containing a tumour was found incidentally. The tumour which measured 2.5 cm was a villous adenoma rising 0.8 cm above the lining mucosa. A focal adenocarcinoma arising from the proximal end of the adenoma infiltrating the submucosa and muscular wall of the diverticulum was also found.<sup>4</sup>

The present case differs from Abdel-Bari's in several respects. The tumour showed only minimal dysplasia, it had arisen from gastric epithelium, and the patient was much younger. The latter finding is of interest and one can perhaps speculate that the adenoma, if left in situ, may have progressed to an adenocarcinoma over the years. In the only case of Meckel's diverticulum which showed transformation or progression of an adenoma to carcinoma, the tumour had arisen from ileal mucosa,<sup>4</sup> while in the present case the adenoma originated from gastric epithelium. Although the majority of adenocarcinomas of Meckel's diverticulum are said to arise from small intestinal mucosa, whether the origin of the neoplasm is from small intestinal mucosa or intestinal metaplasia within gastric mucosa cannot be determined with certainty. Since adenomas of the intestines are much more common than carcinomas, a search for nodules or papillary areas in Meckel's diverticula might be rewarding and is recommended.

- Weinstein EC, Dockerty MB, Waugh JM. Neoplasms of Meckel's diverticulum. *Int Abstr Surg* 1963;116:103–11.
- Kusumoto H, Yoshida M, Takahashi I, et al. Complications and diagnosis of Meckel's diverticulum in 776 patients. *Am J Surg* 1992;164:382–3.
- Niv Y, Abu-Avid S, Kopelman C, et al. Torsion of leiomyosarcoma of Meckel's diverticulum. *Am J Gastroenterol* 1986;81:288–91.
- Abdel-Bari W. Villous adenoma with focal adenocarcinoma in a Meckel's diverticulum. *Am J Clin Pathol* 1967;48:183–6.
- Kusumoto H, Yoshitake H, Mochida K, et al. Adenocarcinoma in Meckel's diverticulum: report of a case and review of 30 cases in the English and Japanese literature. *Am J Gastroenterol* 1992;87:910–13.
- Mackey WC, Dineen P. A fifty year experience with Meckel's diverticulum. *Surg Gynecol Obstet* 1983;156:56–64.
- Haber JJ. Meckel's diverticulum. A review of literature and analytical study of twenty-three cases with particular emphasis on bowel obstruction. *Am J Surg* 1947;73:468–85.
- Jay GD, Margulis RR, McGraw AB, et al. Meckel's diverticulum. A survey of 103 cases. *Arch Surg* 1950;61:158–69.