

Short reports

Not everything acid fast is *Mycobacterium tuberculosis*—a case report

St Bartholomew's Hospital, London EC1, UK:

Department of Medical Microbiology

E S Olson
A J H Simpson
S S Das

Department of Histopathology
A J Norton

Correspondence to:
Dr S S Das,
St Bartholomew's Hospital,
West Smithfield, London
EC1A 7BE, UK; email:
s.s.das@mds.qmw.ac.uk

Accepted for publication
16 April 1998

E S Olson, A J H Simpson, A J Norton, S S Das

Abstract

The Ziehl-Neelsen (ZN) stain is important in identifying organisms that are acid fast, principally *Mycobacterium tuberculosis*. However, decolorisation with a weaker acid concentration (for example 1% hydrochloric acid), often used in ZN staining in histology, can result in a wider variety of organisms appearing acid fast and can be a cause of misidentification. To illustrate this point, a patient is described with

pulmonary nocardiosis who was misdiagnosed as having tuberculous empyema on pleural biopsy.

(J Clin Pathol 1998;51:535-536)

Keywords: Ziehl-Neelsen stain; acid fast organisms; *Mycobacterium tuberculosis*; *Nocardia asteroides*

Case report

A 73 year old Hungarian woman with known aortic valve disease was admitted to hospital with symptoms and signs suggestive of increasing congestive cardiac failure and a superadded chest infection. Her white blood cell count (33×10^9 /litre with 90% neutrophils) and erythrocyte sedimentation rate (110 mm/hour) were very high and she also had anaemia (haemoglobin 8 g/dl) and mild renal impairment (blood urea 7.3 mmol/litre, creatinine 120 µmol/litre). She was started on intravenous cefuroxime, switching to oral cephadrine after five days. However, her symptoms persisted and the ESR and white cell count remained very high. Review of her x rays showed old left basal shadowing (presumed to be secondary to pulmonary embolism) and a new soft tissue mass at the left apex associated with pleural effusion. A diagnosis of tuberculosis was considered, and a pleural biopsy of the lesion in the left apex and aspiration of the pleural effusion were performed together with chest drain insertion.

The pleural biopsy showed large amounts of necrotic inflammatory debris, mostly pyogenic in origin, and some loose collections of histiocytes but no well formed granuloma. Ziehl-Neelsen (ZN) staining revealed scanty acid fast bacilli within the inflammatory exudate (fig 1) and it was concluded that she had a tuberculous empyema. She was started on isoniazid, rifampicin, and pyrazinamide. The chest drain was removed and she was discharged home four weeks after admission. Two weeks later she presented again with purulent and blood stained fluid discharging from the old drain site. At this point an organism presumed to be a *Nocardia* was isolated from a pleural fluid sample, on the Lowenstein-Jensen slopes, after four weeks. A further four pleural aspirate specimens grew the same organism after three days of incubation on blood agar. The isolate was subsequently identified as *Nocardia asteroides*. Acid fast bacilli were not seen in any

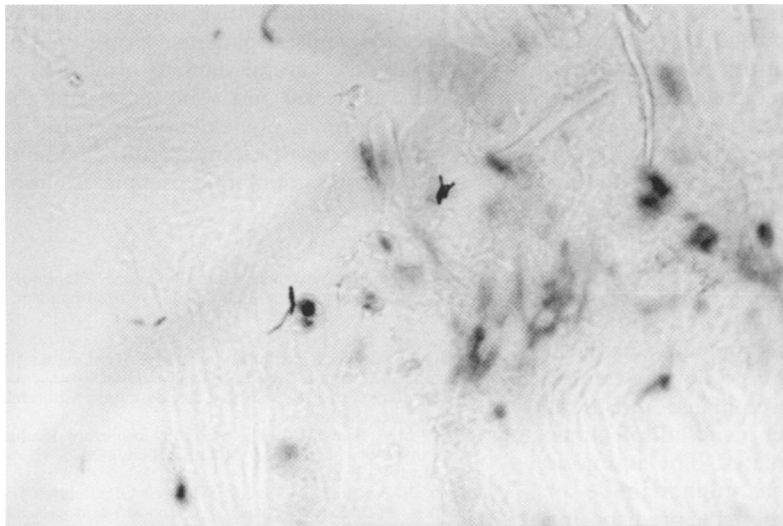


Figure 1 Pleural biopsy showing scanty acid fast bacilli (Ziehl-Neelsen stain).

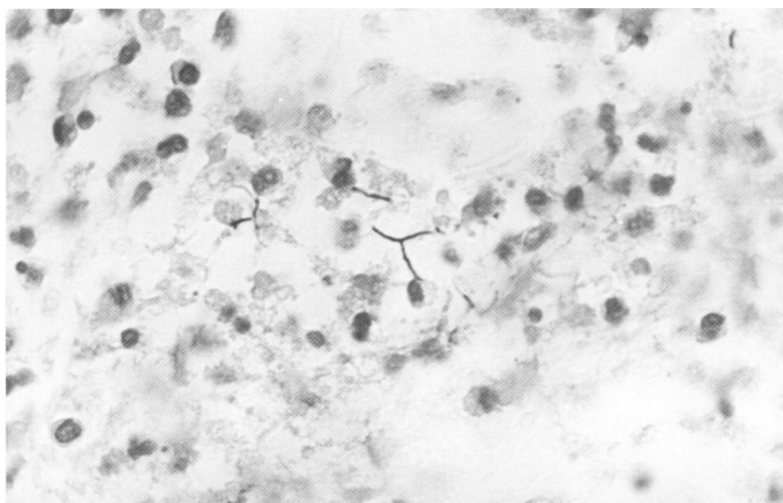


Figure 2 The same specimen as in fig 1 but Gram stained. Large amounts of necrotic inflammatory debris containing branching filamentous Gram positive bacteria are seen.

specimens processed in the microbiology laboratory, using auramine-phenol staining and fluorescence microscopy, and it was suggested that high dose co-trimoxazole treatment should be added pending a review of the histological findings. This review, including Gram staining (fig 2), showed filamentous Gram positive organisms (some acid fast), consistent with a nocardial infection. Antituberculous treatment was stopped. The chest wall continued to discharge for a further fortnight. Co-trimoxazole was stopped after 10 weeks and the patient remained well three months later, with no recurrence of the infection.

Discussion

Nocardia asteroides is a Gram positive branching filamentous bacterium which is weakly acid fast but not acid-alcohol fast, that is it resists decolorisation with 1% (but not 3%) hydrochloric acid. The standard microbiology ZN staining method uses 3% hydrochloric acid in 95% ethanol.¹ The histological ZN stain used 1% hydrochloric acid in 70% ethanol as the decolorising agent. Unfortunately, no pleural biopsy specimen was received for microbiological examination so a direct comparison of the two methods was not possible. However, the use of stronger acid decolorising solutions may distort tissue sections and hence 1% hydrochloric acid in alcohol is used as standard in histology laboratories. It must be remembered that this may result in the detection of weakly acid fast organisms such as *Nocardia* in addition to mycobacteria in tissue sections.

Nocardia species are widespread in the environment.^{2,3} Nocardial infections are often associated with some degree of immunocompromise. In these patients, *Nocardia* may cause invasive pulmonary infections (probably after inhalation of the organisms) or become disseminated. In immunocompetent patients, chronic cutaneous infections following trauma are more common. Disseminated infections have a poor prognosis, but localised infections may be relatively easily treated. The antibiotic treatment of choice is a sulphonamide or co-trimoxazole. The only possible predisposing factor in this patient was mild renal impair-

ment which was felt not to warrant aggressive investigation in view of the patient's age.

This case illustrates the importance of submitting material for both histological and microbiological examination in the investigation of cases of possible tuberculosis, and of always considering the possibility of non-mycobacterial species when acid fast organisms are observed in specimens, particularly when a modified ZN stain is used. It must be stressed that culture is the gold standard for identifying *M. tuberculosis*. In the absence of this or while culture results are awaited, it would be prudent for histopathologists and microbiologists to consult and review jointly "AFB" positive sections, especially when a weaker acid concentration is used in ZN staining. Routine use of a panel of histological stains, including ZN, silver, and Gram, could also aid correct diagnosis when infections are being sought. In the absence of such information histopathologists may wish to advise more cautious reporting, for example, "tuberculous empyema must be considered" rather than "conclusion—tuberculous empyema". Microbiologists should not only process respiratory tract specimens such as pleural biopsy and aspirate for mycobacteria but also should be alert to the fact that rare organisms such as nocardia may cause pleuropulmonary infections, especially in immunocompromised patients. However, nocardia may take several days to grow, sometimes several weeks, and some cases may be missed if culture is not extended beyond 48 hours, particularly if characteristic filaments are not seen on initial microscopic examination.

We thank the PHLS Mycobacterium Reference Laboratory, Dulwich, for their assistance in identification of this organism.

- 1 JP Duguid. Staining methods. In: Collee JG, Duguid JP, Fraser AG, Marmion BP, eds. *Mackie and McCartney practical medical microbiology*, 13th ed. Edinburgh: Churchill Livingstone, 1989:46-9.
- 2 McNeil MM, Brown JM. The medically important aerobic actinomycetes: epidemiology and microbiology. *Clin Microbiol Rev* 1994;7:357-417.
- 3 Lerner PI. *Nocardia* species. In: Mandell GL, Bennett JE, Dolin R, eds. *Mandell, Douglas and Bennett's principles and practice of infectious diseases*, 4th ed. New York: Churchill Livingstone, 1995:2273-80.