

# Unusual aetiology of persistent back pain in a patient with multiple myeloma: infectious discitis

C H Burton, S A Fairham, B Millet, R DasGupta, M Sivakumaran

## Abstract

**A 47 year old man with multiple myeloma presented with persistent back pain caused by infectious discitis. Aspiration of the affected vertebral disc space was carried out, guided by computed tomography, and microbiological examination of the aspirate revealed *Staphylococcus aureus* and *Mycobacterium tuberculosis*. Antituberculous and antistaphylococcal antibiotic treatment resulted in a dramatic clinical response with complete resolution of the vertebral abscess. Detailed radiological and microbiological investigations are necessary to diagnose unusual causes of chronic bone pain such as discitis or infectious bone disease in patients with multiple myeloma.**

(J Clin Pathol 1998;51:633-634)

Keywords: multiple myeloma; discitis; tuberculosis; *Staphylococcus aureus*

Pain is a common clinical manifestation of multiple myeloma and is usually caused by bone damage from the disease. Skeletal involvement occurs in three quarters of patients initially and bone pain, typically in the back or chest and less often in the extremities, is present at diagnosis in more than two thirds.<sup>1</sup> In some cases, pain is a result of nerve or spinal cord damage from direct compression by the tumour, or it may be secondary to peripheral neuropathies caused by amyloid deposition or ill defined non-metastatic manifestations of malignancy.<sup>1,2</sup>

Another common complication of multiple myeloma is the increased susceptibility to infection. This immunodeficiency arises as a result of the impaired antibody response secondary to the cellular abnormalities of both the B and the T cell series, suppression of normal immunoglobulin synthesis resulting in deficient normal immunoglobulins, impaired serum opsonic activity, and neutrophil dysfunction. The propensity to infection is further increased by neutropenia, owing to bone marrow infiltration, and chemotherapy induced myelosuppression. The cell mediated and humoral immune deficiency of multiple myeloma also predisposes to infections with atypical microbes including mycobacteria.<sup>1,2</sup>

We report a patient who presented with one of the commonest symptoms of multiple myeloma, persistent back pain, but of an unusual aetiology: infective discitis. This case highlights the importance of detailed investigations to identify the cause of persistent pain which proves unresponsive to standard treatments in patients with multiple myeloma.

## Case report

A 47 year old white man was diagnosed as having multiple myeloma in November 1995 when he presented with a normochromic normocytic anaemia (Hb 90.0 g/l), high erythrocyte sedimentation rate (ESR > 150), and bone marrow infiltration with abnormal plasma cells (42% of the nucleated bone marrow cells). The peripheral blood total white cell count was  $4.1 \times 10^9/l$ , with an absolute neutrophil count of  $2.0 \times 10^9/l$ . Platelet count was normal. Serum immunoglobulin electrophoresis showed a monoclonal IgA paraprotein band (57 g/l) with reduced levels of normal IgG and IgM immunoglobulins (3.5 g/l and 0.16 g/l, respectively). The skeletal survey showed no myelomatous bone lesions at presentation. He was started on combination chemotherapy (VAD regimen consisting vincristine, doxorubicin, and high dose dexamethasone). A few months later he developed worsening lower back pain. Initially this was attributed to myelomatous deposits in the spine but it remained refractory to radiotherapy, morphine based analgesia, and physiotherapy. Over the next few weeks he continued to complain of persistent lower back pain, but with no evidence of neurological impairment. In view of his pain a repeat radiological examination of his lumbar spine was performed. This showed loss of definition of the adjacent L2-3 vertebral end plates, with some loss of height of the intervening disc consistent with discitis (fig 1A). A CT scan of the lumbar spine, including the L2-3 disc space showed destruction of the adjacent L2-3 vertebral end plates, with a thin rim of surrounding soft tissue material (fig 1B). These appearances were compatible with discitis. Soft tissue material overlapping the boundaries of the vertebral bodies was also noted, which was felt to be either a concentrically bulging annulus or a localised infected collection. Aspiration of this lumbar disc space was performed. Microbiological examination of the aspirate revealed *Staphylococcus aureus* and *Mycobacterium tuberculosis*. In view of these findings the patient was started on standard antituberculous treatment of pyrazinamide 1.5 g once daily and Rifinah (combined rifampicin and isoniazid) 600 mg once daily, as well as flucloxacillin (500 mg four times a day) and fucidin (500 mg three times a day). On further questioning the patient gave no past medical or family history of tuberculosis. Radiological and microbiological examination showed no evidence of tuberculous infection elsewhere.

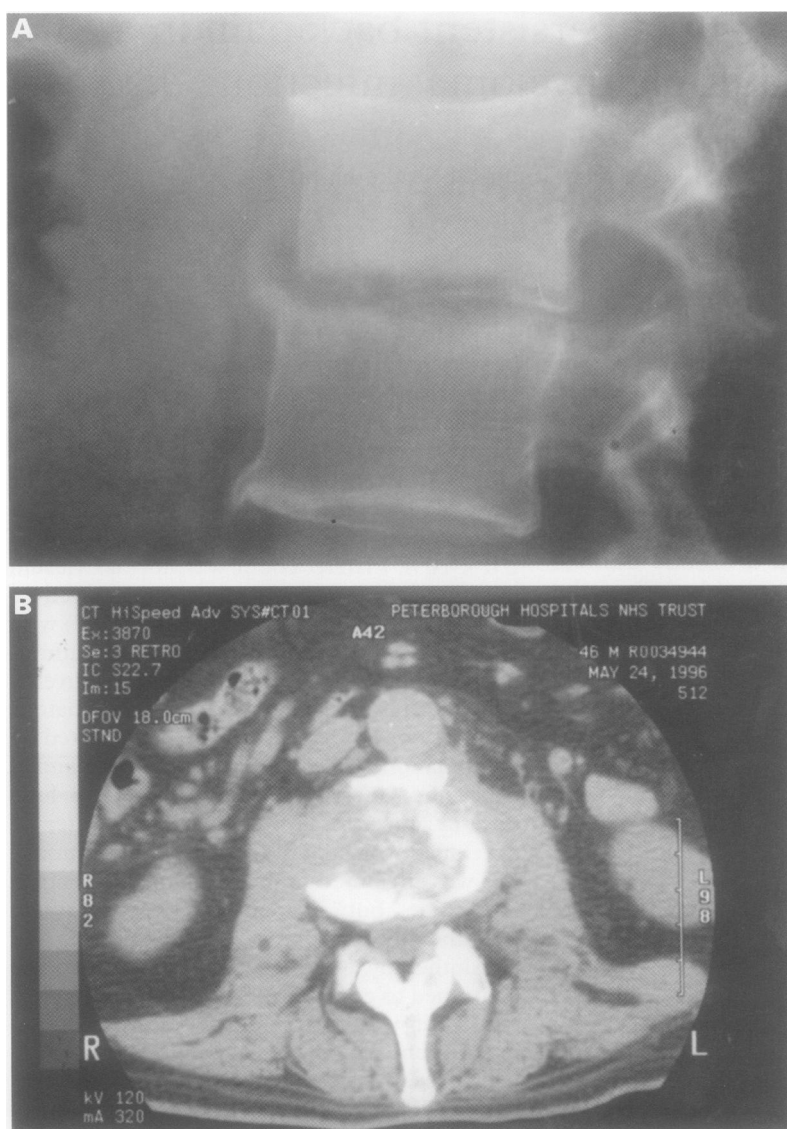
The patient showed remarkable response to the treatment, with resolution of his symptoms. His pyrazinamide was discontinued two months later but treatment was continued with Rifinah

District Hospital,  
Peterborough, UK:  
Department of  
Haematology  
C H Burton  
R DasGupta  
S A Fairham  
M Sivakumaran

Department of  
Radiology  
B Millet

Correspondence to:  
Dr M Sivakumaran,  
consultant haematologist,  
Department of Haematology,  
District Hospital,  
Peterborough PE3 6LA, UK.

Accepted for publication  
20 April 1998



**Figure 1** (A) Radiograph of lumbar spine showing loss of definition of the adjacent L2-3 vertebral end plates with some loss of height of the intervening disc. (B) Computed tomography of the lumbar spine including the L2-3 space showing destruction of the adjacent L2-3 disc vertebral end plates with a thin rim of surrounding soft tissue material. Soft tissue material overlapping the boundaries of the vertebral bodies is also noted.

and antibiotics. He continued to improve significantly over the next few months. Repeated computed tomography of his lumbar spine carried out 12 months later showed complete resolution of the abscess and slight loss of height of the left side of L2 spine, consistent with fusion following discitis.

The patient subsequently received an autologous peripheral blood stem cell transplant and is currently in remission on a treatment regimen of interferon and clodronate. He remains well with no skeletal symptoms.

### Discussion

Spontaneous infective discitis—primary infection within the disc space with or without involvement of contiguous vertebral end plates—is an uncommon but recognised cause of back pain in adults.<sup>3,4</sup> The condition appears to be more common in patients with immunosuppression, for example leukaemia, cytotoxic chemotherapy, long term steroid treatment, organ transplantation, and diabetes mellitus.<sup>3-7</sup> However, a detailed search of published reports

using a Datastar cross database program has failed to identify any previous description of spontaneous infective discitis occurring in association with multiple myeloma, although a case of epiduritis without discitis complicating multiple myeloma has been reported.<sup>8</sup> In contrast to postoperative patients, in whom the infecting organism is most frequently *S aureus* or *S epidermidis*, patients with spontaneous discitis show a wide variety of Gram positive, Gram negative, mycobacterial, and fungal organisms.<sup>3-7</sup> The common presenting features of spontaneous infective discitis are persistent backache, fever, and raised ESR. Although confirmation of the diagnosis relies on isolation of the causative organism or on histological evidence, radiological investigations including plain x ray of the spine, technetium or gallium scan, computed tomography, and magnetic resonance imaging may prove valuable in aiding the diagnostic process and facilitating needle aspiration and biopsy. It has been suggested that magnetic resonance imaging is more sensitive and specific than other imaging methods in the diagnosis of discitis.<sup>9</sup> While early diagnosis and appropriate antimicrobial treatment usually lead to resolution of the disease, delayed diagnosis may result in severe vertebral bone damage and neurological complications including paraplegia.

In view of the similarities in the clinical features of infective discitis and myeloma bone disease (chronic pain and high ESR with or without fever), diagnosis of spontaneous infective discitis in a patient with multiple myeloma may be difficult. A high index of clinical suspicion and detailed radiological imaging may facilitate early diagnosis of spontaneous infective discitis in these patients, thus permitting appropriate treatment.

In conclusion, this case illustrates the importance of detailed radiological and microbiological investigations to diagnose unusual causes of chronic bone pain such as discitis or infectious bone disease (for example osteomyelitis) in patients with multiple myeloma. The common practice of attributing any skeletal complications to myelomatous lytic lesions and microfractures should be discouraged.

- 1 Schey SA, Linch DC. Myeloma and related disorders. In: Ludlam CA, ed. *Clinical haematology*. Edinburgh: Churchill Livingstone, 1990:183-95.
- 2 Kyle RA. Multiple myeloma and other plasma cell disorders. In: Hoffman R, Benz EJ, Shattil SJ, et al, eds. *Hematology: basic principles and practice*. Edinburgh: Churchill Livingstone, 1995:1354-74.
- 3 Honan M, White GW, Eisenberg GM. Spontaneous infectious discitis in adults. *Am J Med* 1996;100:85-9.
- 4 Perronne C, Saba J, Behloul D, et al. Pyogenic and tuberculous spondylodiskitis (vertebral osteomyelitis) in 80 adult patients. *Clin Infect Dis* 1994;19:46-50.
- 5 Lafont A, Olive M, Gelman J, et al. *Candida albicans* spondylodiskitis and vertebral osteomyelitis in patients with intravenous heroin drug addiction. Report of 3 new cases. *J Rheumatol* 1994;21:953-6.
- 6 Cortet B, Richard R, Deprez X, et al. Aspergillus spondylodiskitis: successful conservative treatment in 9 cases. *J Rheumatol* 1994;21:1287-91.
- 7 D'Antonio D, Piccolomini R, Fioritoni G, et al. Osteomyelitis and intervertebral discitis caused by *Blastoschizomyces capitatus* in a patient with acute leukaemia. *J Clin Microbiol* 1994;32:224-7.
- 8 Soubrier M, Demarquilly F, Urošević K, et al. Cervical epidural infection. *Rev Rhum Engl Ed* 1995;62:29-34.
- 9 Modic MT, Pavlicek W, Weinstein MA, et al. Magnetic resonance imaging of intervertebral disk disease: clinical and pulse sequence considerations. *Radiology* 1984;152:103-11.