

Association of pure red cell aplasia with T large granular lymphocyte leukaemia

Y L Kwong, K F Wong

Abstract

Aim—To define the relation between T large granular lymphocyte (T-LGL) leukaemia and pure red cell aplasia in Chinese patients.

Methods—Patients with T-LGL leukaemia were identified from a consecutive series of Chinese patients with chronic lymphoproliferative disorders. The diagnosis of T-LGL leukaemia was based on typical morphological and immunophenotypical features, and confirmed by the detection of clonal T cell receptor gene rearrangement. The clinicopathological features, response to treatment, and long term follow up were also examined.

Results—Five patients were identified as having T-LGL leukaemia from a consecutive series of 33 Chinese patients with chronic lymphoproliferative disorders. The median follow up time was 45 months. An obvious lymphocytosis was present in only two cases, although an increase in large granular lymphocytes in the peripheral blood was found in four. In one case, the LGL count was within the normal range. Epstein-Barr virus encoded early nuclear RNA was negative in all the cases. There was no evidence of rheumatoid arthritis, and none of the patients presented with recurrent infections. On follow up, pure red cell aplasia occurred at some stage of the disease in all the patients. This responded to treatment with cyclosporin A in two and with antithymocyte globulin in one. Two patients remained transfusion dependent.

Conclusions—In contrast to Western patients, Chinese patients with T-LGL leukaemia do not appear to suffer from rheumatoid arthritis and recurrent infections, but pure red cell aplasia is a major cause of morbidity in this ethnic group.

(J Clin Pathol 1998;51:672-675)

Keywords: pure red cell aplasia; large granular lymphocyte leukaemia

T large granular lymphocyte (T-LGL) leukaemia is a rare chronic lymphoproliferative disorder of T cells characterised by anaemia, neutropenia, and a persistent increase in large granular lymphocytes, which are large lymphocytes with a low nucleus to cytoplasm ratio and abundant cytoplasm with azurophilic granules.¹⁻³ T-LGL leukaemia is an uncommon haematological disorder in the West, accounting for 2-5% of all chronic lymphoid leukaemias.⁴ Common clinical associations

include rheumatoid arthritis and granulocytopenia; autoimmune cytopenias also occur, but less commonly, while pure red cell aplasia is a rare association.⁴

On the other hand, T-LGL leukaemia is apparently more common in the East. In one Chinese series it accounted for 9% of all chronic lymphoproliferative disorders.⁵ It is also thought to be relatively common in the Japanese,⁶ although the exact incidence remains undefined. Oriental patients with this condition tend to present with different features from occidental patients—for example, rheumatoid arthritis is very rare but pure red cell aplasia appears to be much more common.⁵⁻⁸

We present the clinicopathological features of five consecutive Chinese patients with T-LGL leukaemia and report a high frequency of pure red cell aplasia in this population.

Methods

PATIENTS

All the patients were ethnic Chinese. The diagnosis of T-LGL leukaemia was based on the presence of large granular lymphocytes in the peripheral blood and confirmed by immunophenotyping. Clonal rearrangement of the T cell receptor γ (TCR γ) gene must also be demonstrable. The diagnosis of pure red cell aplasia was based on anaemia, reticulocytopenia (< 0.1%), and selective erythroid hypoplasia/aplasia in a normocellular marrow with normal myeloid and megakaryocytic cell lines.⁸ Vitamin B-12 and folate deficiencies were excluded. A remission of the pure red cell aplasia was defined as an untransfused haemoglobin of > 10 g/dl and the return of a normal reticulocyte count. The clinical features of cases 1 to 3 had been reported briefly elsewhere.⁸

IMMUNOPHENOTYPING, TCR γ GENE

REARRANGEMENT, AND IN SITU HYBRIDISATION

Immunophenotyping was performed on peripheral blood or bone marrow mononuclear cells by the biotin-streptavidin method. The mononuclear cells in the peripheral blood or bone marrow were concentrated by Ficoll density gradient sedimentation. Cytospin slides were prepared from the mononuclear cell suspension. Membrane staining was interpreted together with cellular morphology, while one of the cytospin slides was simultaneously Giemsa stained and examined. The polymerase chain reaction (PCR) was used to demonstrate a clonally rearranged TCR γ gene, according to McCarthy *et al.*⁹ Two pairs of V γ primers (V $_1$: 5'-TCT GG(G/A) GTC TAT TAC TGT GC-3'; V $_2$: 5'-CTC ACA CTC (C/T)CA CTT C-3', complementary to consensus sequences

University
Department of
Medicine, Queen Mary
Hospital, Hong Kong
Y L Kwong

Department of
Pathology, Queen
Elizabeth Hospital,
Hong Kong
K F Wong

Correspondence to Dr Y L Kwong, University Department of Medicine, Professorial Block, Queen Mary Hospital, Pokfulam Road, Hong Kong.

Accepted for publication
13 May 1998

Table 1 Clinicopathological features on presentation and treatment outcome in five Chinese patients with T large granular lymphocyte (LGL) leukaemia

Case	Sex/age	Hb	WBC (%LGL)	Platelet count ($\times 10^9/l$)	Marrow LGL (%)	Immuno- phenotype of LGL	EBV EBER	Associated disease (months from diagnosis)	Response of PRCA to treatment (months or courses given)					Follow up (months)
									Steroids†	HDM	CsA	ATG	Others	
1	M/47	6.5	15.0 (65)	145	37	CD2+CD3+ CD4-CD8+ CD56-	-ve	PRCA (6)	NR (4)	NR (1)	NR (6)	R (1)	Myleran‡ NR (6)	Transfusion independent (45)
2	M/48	6.0	20.0 (58)	360	45	CD2+CD3+ CD4-CD8+ CD56-	-ve	PRCA (26)	NR (4)	NR (1)	NR (6)	NR (1)	Myleran‡ NR (6), CTX NR (3), DCF NR (7)	Transfusion dependent (55)
3	F/73	5.8	4.0 (2)	150	Not incr	CD3+CD4- CD8+	-ve	PRCA (P)	NR (6)	NR (1)	NR (3)	NR (1)	IVIg NR (1)	Transfusion dependent (49)
4	M/51	4.7	2.5 (27)	161	30	CD2+CD3+ CD4-CD8+ CD56-	-ve	PRCA (P)	-	-	R (9)	-	-	Transfusion independent (12)
5	M/50	13.9	4.1 (54)	225	25	CD2+CD3+ CD4-CD8+ CD56-	-ve	PRCA (10), peripheral neuropathy (P)	-	-	R (3)	-	-	Transfusion independent (24)

ATG, antithymocyte globulin (Atgam, Upjohn; 25 mg/kg/d \times 5); CsA, cyclosporin (8 mg/kg/d); CTX, cyclophosphamide (100 mg/d); DCF, deoxycoformycin (4 mg/kg/course); EBV EBER, Epstein-Barr virus encoded early RNA; Hb, haemoglobin (g/dl); HDM, high dose methylprednisolone (1 g/d \times 3, then 0.5 g/d \times 3); IVIg, intravenous immunoglobulin (40 mg/kg/d \times 5); incr, increased; NR, non-remission, transfusion dependent; P, on presentation; PRCA, pure red cell aplasia; R, remission (Hb > 10 g/dl, transfusion independent); WBC, white blood cell count ($\times 10^9/l$).

†Prednisone 1 mg/kg/d.
‡Myleran dose 4-6 mg/d.

of V-I and V-II/IV families of the TCR γ gene, respectively) and two pairs of J γ primers (J γ_1 : 5'-CAA GTG TTG TTC CAC TGC C-3'; J γ_2 : 5'-GTT ACT ATG AGC (T/C)TA GTC C-3', complementary to consensus sequences of J $\gamma_{1/2}$ and J $\gamma_{1/2}$ of the TCR γ gene, respectively) were used to amplify the rearranged TCR γ gene. These primer combinations would be expected to generate bands of about the size range 75 to 95 base pairs for the V $_1$ /V $_2$ J γ_1 primer pairs, and 80 to 110 base pairs for the V $_1$ /V $_2$ J γ_2 primer pairs.⁹ In situ hybridisation for Epstein-Barr virus encoded early RNA (EBER) was performed on paraffin embedded marrow biopsies or peripheral blood mononuclear cell cytospin preparations as previously described.¹⁰

Results

CLINICOPATHOLOGICAL FEATURES

Four male patients and one female were diagnosed as having T-LGL leukaemia among 33 consecutive unselected patients with

chronic lymphoproliferative diseases who presented in a six year period (1991 to 1996). The clinicopathological features of these patients are shown in table 1. The median age at presentation was 51 years (range 47 to 73).

The initial symptoms were anaemia in four cases and peripheral neuropathy in one. Recurrent infection was not observed in any patient. Neither clinical nor serological evidence of rheumatoid arthritis was present in any of the cases. At presentation, an increase in the percentage of large granular lymphocytes was found in four cases, the absolute LGL count ranging from 0.68 to 11.6 $\times 10^9/l$. These cells showed considerable variation in size and morphology (fig 1). Bone marrow examination of these patients showed a variable infiltration by large granular lymphocytes, ranging from to 25% to 45%. The direct antiglobulin test was negative. Pure red cell aplasia was present in two cases at presentation. Case 3 did not have an increase in LGL count in the peripheral blood and marrow at any stage of her disease, and this accounted for the original diagnosis of idiopathic pure red cell aplasia. T-LGL leukaemia was suspected three years after presentation because of the presence of LGL cells of atypical morphology (fig 1). In the other three cases, pure red cell aplasia developed six, 10, and 26 months after presentation.

IMMUNOPHENOTYPING, TCR γ GENE REARRANGEMENT, AND IN SITU HYBRIDISATION

Immunophenotypic studies showed that the large granular lymphocytes expressed the immunophenotype CD2+CD3+CD4-CD8+CD56- in all cases. PCR for the TCR γ gene showed clonal rearrangements in all (fig 2). In cases 3 and 4, two bands were amplified consistently with the biallelic TCR γ gene rearrangements that occur in about 40% of T cell malignancies.⁹ In case 3, PCR was performed retrospectively on the marrow obtained initially at the diagnosis of pure red cell aplasia, and showed that a clonal population of T cells

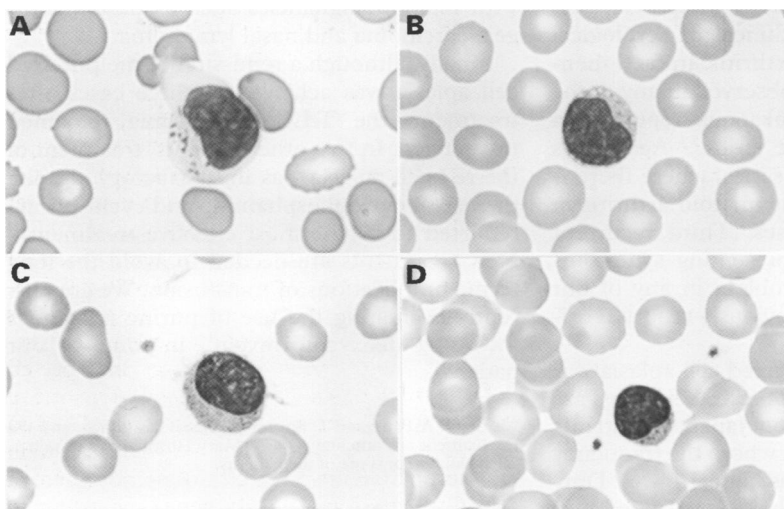


Figure 1 Morphological variation of cells in T large granular lymphocyte (T-LGL) leukaemia. (A) Typical LGL with voluminous pale cytoplasm containing coarse granules; (B) LGL with pale vacuolated cytoplasm containing very fine granules; (C) LGL showing numerous cytoplasmic villi; (D) small LGL with a central nuclear cleft, easily mistaken as an ordinary small lymphocyte unless examined under high power. (Wright stain, $\times 867$.)

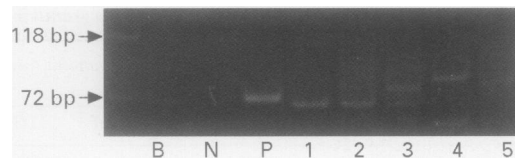


Figure 2 Polymerase chain reaction (PCR) for T cell receptor γ gene rearrangement. Lanes B, N, and P: reagent blank, normal control, and positive control of a case of T cell acute lymphoblastic leukaemia; lanes 1–5: DNA from patients 1–5 respectively. The expected band sizes of clonally rearranged T cell receptor γ gene are roughly between 70 and 110 base pairs.

already existed despite the absence of an increase in large granular lymphocytes. In situ hybridisation for EBV EBER was negative in all the cases.

TREATMENT OUTCOME

In three patients who presented with pure red cell aplasia, the initial treatment was corticosteroids followed by a variety of other agents including high dose steroids, cyclophosphamide, cyclosporin A, intravenous immunoglobulin, and antithymocyte globulin (table 1). Two were refractory to treatment, but one responded to antithymocyte globulin and became transfusion independent. In two other patients, the initial treatment was cyclosporin A, starting at 8 mg/kg/day in two divided doses. Both achieved a remission. The LGL count in cases 1 and 2 decreased to less than $2 \times 10^9/l$ with treatment, while in cases 3–5 it remained stable.

Discussion

This series illustrates several clinicopathological differences between oriental patients with T-LGL leukaemia and their occidental counterparts. First, the overall frequency of T-LGL leukaemia was 15% in this series from a single tertiary referral centre, which is higher than that reported in our previous multicentre study of Chinese patients with chronic lymphoproliferative disorders (9%).⁵ This might be attributable to a difference in referral patterns. However, both frequencies are higher than the figure of 2–5% in Western series.⁴ Second, none of our cases had clinical or serological evidence of rheumatoid arthritis. In fact, rheumatoid arthritis was not observed in any of the patients with T-LGL leukaemia reported in two Japanese and Chinese series.^{5,6} Again, this is in contrast to Western series, where there is serological evidence of rheumatoid arthritis in as many as 30–50% of cases.⁴ Third, recurrent infections were not the presenting symptoms and were not a major problem in any of our cases, nor in any of the previously reported oriental patients.^{5,6}

On the other hand, pure red cell aplasia was observed in all our patients. These findings are in agreement with data on Japanese patients with T-LGL leukaemia, in whom the frequency of pure red cell aplasia is as high as 64%.⁶ During our study period, another four cases of pure red cell aplasia were seen (one was idiopathic, the others secondary to myeloma, B chronic lymphocytic leukaemia, and myelodysplasia; unpublished observations). Therefore, nearly

half of all our patients with pure red cell aplasia had T-LGL leukaemia. These findings indicate a close association between T-LGL leukaemia and pure red cell aplasia in oriental patients. This association is thought to be very uncommon in occidental ethnic groups.^{4,11–13} However, a recent report on cases of pure red cell aplasia studied for TCR gene rearrangement in occidental patients showed that 19% had T-LGL leukaemia, suggesting a more common association than was previously recognised.¹⁴ Furthermore, as only some of the patients had been investigated by molecular methods in that study, the actual frequency might be higher.¹⁵ The importance of this observation is that in oriental patients, and perhaps also in occidental patients, an underlying T-LGL leukaemia should be excluded in the diagnostic evaluation of pure red cell aplasia.

Two of our cases had only modest increases in LGL counts, making the diagnosis of T-LGL leukaemia difficult. This is illustrated in case 3 who had no increase in LGL count, although a clonal T cell proliferation was already demonstrable by PCR in the initial diagnostic marrow sample. In these cases, abnormal morphology of the large granular lymphocytes and nuclear atypia might be a clue, but the definitive diagnosis depended on the demonstration of a clonal expansion of T cells. It is therefore important to recognise that lymphocytosis may not be obvious in patients with T-LGL leukaemia, and unless the blood film is examined carefully and periodically the diagnosis may be overlooked, as about 8% of cases of T-LGL leukaemia have an LGL count of less than $1 \times 10^9/l$.⁴ Furthermore, molecular studies for clonal T cell proliferation should be performed in clinical situations where T-LGL leukaemia is a diagnostic possibility.

No evidence of EBV infection was demonstrable in any of our cases, consistent with the observations from other reports.¹⁶ This suggests that EBV is not involved in the pathogenesis of T-LGL leukaemia, even in a population like ours where EBV is known to be associated with many malignancies such as nasopharyngeal carcinoma and nasal lymphoma.¹⁷

Finally, although a remission of the pure red cell aplasia was achieved in three cases after treatment, the T-LGL leukaemia remained unchanged. In two other patients, treatment of the red cell aplasia was unsatisfactory, despite the use of cyclophosphamide and cyclosporin—reported to be the most effective treatment.¹⁴ New treatments are needed to avoid the long term complications of transfusion. We are currently evaluating the use of purine analogues including deoxycoformycin¹⁸ in some of our patients.

We thank A Pang and L Siu for technical assistance, and the Department of Pathology, Queen Mary Hospital, for histological evaluation of some of the patients.

- 1 Brouet JC, Flandrin G, Sasportes M, *et al*. Chronic lymphocytic leukemia of T-cell origin: immunological and clinical evaluation in eleven patients. *Lancet* 1975;ii:890–3.
- 2 Reynolds CW, Foon KA. T-lymphoproliferative disease and related disorders in humans and experimental animals: a review of the clinical, cellular, and functional characteristics. *Blood* 1984;64:1146–58.

- 3 Loughran TP, Starkebaum G. Large granular lymphocyte leukemia: report of 38 cases and review of the literature. *Medicine* 1987;66:397-405.
- 4 Loughran TP. Clonal disease of large granular lymphocytes. *Blood* 1993;82:1-14.
- 5 Kwong YL, Wong KF, Chan LC, *et al.* The spectrum of chronic lymphoproliferative disorders in Chinese people—an analysis of 64 cases. *Cancer* 1994;74:174-81.
- 6 Oshimi K, Yamada O, Kaneko T, *et al.* Laboratory findings and clinical courses of 33 patients with granular lymphocyte-proliferative disorders. *Leukemia* 1993;7:782-8.
- 7 Kwong YL, Wong KF, Chan LC, *et al.* Large granular lymphocyte leukemia—a study of nine cases in a Chinese population. *Am J Clin Pathol* 1995;103:76-81.
- 8 Kwong YL, Wong KF, Liang RHS, *et al.* Pure red cell aplasia: clinical features and treatment results in 16 cases. *Ann Hematol* 1996;72:137-40.
- 9 McCarthy KP, Sloane JP, Kabarowski JH, *et al.* A simplified method of detection of clonal rearrangements of the T-cell receptor-gamma chain gene. *Diagn Mol Pathol* 1992;1:173-9.
- 10 Wong KF, Chan JKC, Lo ESF, *et al.* A study of the possible etiologic association of Epstein Barr virus with reactive hemophagocytic syndrome in Hong Kong. *Hum Pathol* 1996;27:1239-42.
- 11 Chan WC, Link S, Mawle A, *et al.* Heterogeneity of large granular lymphocyte proliferation : delineation of two major subtypes. *Blood* 1986;68:1142-53.
- 12 Semenzato G, Pandolfi F, Chisesi T, *et al.* The lymphoproliferative disease of granular lymphocytes. A heterogeneous disorder ranging from indolent to aggressive conditions. *Cancer* 1987;60:2971-8.
- 13 Pandolfi F, Loughran TP, Starkebaum G, *et al.* Clinical course and prognosis of the lymphoproliferative disease of granular lymphocytes. A multicenter study. *Cancer* 1990;65:341-8.
- 14 Lacy MQ, Kurtin PJ, Tefferi A. Pure red cell aplasia: association with large granular lymphocyte leukemia and the prognostic value of cytogenetic abnormalities. *Blood* 1996;87:3000-6.
- 15 Tefferi A, Lacy MQ, Kurtin PJ. Pure red blood cell aplasia: association with large granular lymphocyte leukemia and the prognostic value of cytogenetic abnormalities. *Blood* 1996;88:3245-6.
- 16 Loughran TP, Zambello R, Ashley R, *et al.* Failure to detect Epstein-Barr virus DNA in peripheral blood mononuclear cells of most patients with large granular lymphocyte leukemia. *Blood* 1993;81:2723-7.
- 17 Jaffe ES, Chan JKC, Su IJ, *et al.* Report of the workshop on nasal and related extranodal angiocentric T/natural killer cell lymphomas. *Am J Surg Pathol* 1996;20:103-11.
- 18 Mercieca J, Matutes E, Dearden C, *et al.* The role of pentostatin in the treatment of T-cell malignancies: analysis of response rate in 145 patients according to disease subtype. *J Clin Oncol* 1994;12:2588-93.