

Vitamin D receptor expression in colorectal cancer

M G Thomas, P A Sylvester, P Newcomb, R J Longman

Abstract

Aims—To determine whether the vitamin D receptor is expressed in colorectal cancer, and its relation to stage of disease.

Methods—Paraffin embedded sections of colorectal cancer from 30 patients who had undergone surgery were studied. Immunohistochemistry using the specific monoclonal antibody 9A7 γ directed against the nuclear vitamin D receptor was used to identify receptors for the active metabolite of vitamin D₃ (1,25-dihydroxyvitamin D₃).

Results—Microscopically normal human colorectal epithelium showed vitamin D receptor expression predominantly in the mid and upper crypts. All the colorectal cancer tissue studied showed vitamin D receptor expression, with a median of 25.3 (range 10.1 to 43.7) cells/graticule field ($\times 400$). Although vitamin D receptor staining was heterogeneous within the individual cancers, neither Dukes stage nor the degree of differentiation appeared to influence expression of the receptor.

Conclusions—Colorectal cancer tissue expresses the nuclear vitamin D receptor and this could act as a potential therapeutic target for synthetic vitamin D₃ differentiating agents.

(J Clin Pathol 1999;52:181-183)

Keywords: vitamin D₃ receptor; colorectal carcinoma; immunohistochemistry

The physiologically active form of vitamin D₃, 1 α ,25-dihydroxyvitamin D₃, is a potent inducer of cell differentiation in several isolated and established cancer cell lines.^{1,2} In addition, epidemiological studies suggest that vitamin D₃ protects against the development of colon cancer.^{1,3} In vitro studies using human colorectal epithelial explants indicate that colonic tissue can respond to the active metabolite of vitamin D₃.⁴ The clinical use of 1 α ,25-dihydroxyvitamin D₃ is limited by its profound effects on calcium metabolism.^{4,5} Synthetic vitamin D₃ analogues with a more favourable therapeutic ratio than 1 α ,25-dihydroxyvitamin D₃ have recently been developed.⁶ Calcipotriol (a synthetic analogue) retains potent cell cycle regulatory properties with reduction of hypercalcaemic and hypercalciuric side effects.⁷ Calcipotriol is an effective topical treatment for psoriasis and also reduces human colorectal epithelial cell proliferation in vitro.^{8,9} This agent, however, is not suitable for systemic use because of its short half life, with rapid elimination from the body and the formation of metabolites with low biological activity.¹⁰ In

contrast, the analogue EB1089 is a potent anti-proliferative agent following systemic administration in animal models.¹¹

Vitamin D₃ analogues appear to bind to a specific high affinity nuclear receptor protein which belongs to the superfamily of steroid receptors.^{12,13} Receptor-hormone complexes bind to vitamin D response elements in the promoter regions of the primary vitamin D response genes, leading to activation or suppression of gene transcription.¹³⁻¹⁵ Vitamin D receptor appears to bind to response elements either as a homodimer or as a heterodimer with other nuclear receptors such as retinoid X, retinoic acid, and the thyroid hormone receptors.^{15,16}

Receptor binding studies have demonstrated the presence of the vitamin D receptor in human colorectal cancer tissue, although the level of expression is disputed.^{16,17} We have used a monoclonal antibody to study vitamin D receptor expression in human colorectal cancer tissue to determine if receptor expression is influenced by the Dukes' stage of tumour or the degree of cellular differentiation.

Methods

We selected an unbiased cohort of paraffin embedded archival tissue from 30 patients with primary colorectal carcinoma. The degree of differentiation was reported as well differentiated (G₁) in three, moderately well differentiated (G₂) in 19, and poorly differentiated (G₃) in eight of these tumours. Tissues were also classified according to stage of disease: Dukes' A (n = 10), Dukes' B (n = 11), and Dukes' C (n = 9). Sections (3 μ m thick) were dewaxed in xylene and rehydrated through decreasing concentrations of alcohol. Endogenous peroxidase activity was blocked with 0.3% H₂O₂ in methanol and the tissue was hydrolysed in 2 M HCl at 37°C for 30 minutes. Non-specific antibody binding was blocked with normal goat serum for 20 minutes.

The primary 9A7 IgG_{2b} monoclonal antibody directed against the vitamin D receptor (Chemicon International) was added using a 1:50 solution in Tris buffered saline (TBS) for two hours at room temperature.¹⁸ The second layer was a biotinylated goat IgG antibody (Biogenex) at a concentration of 1:20 in TBS. The third layer was horseradish peroxidase labelled streptavidin (Biogenex) at a concentration of 1:20 in TBS.

Slides were developed with diaminobenzidine (250 μ g with 0.037% H₂O₂) to demonstrate peroxidase activity, and counterstained with haematoxylin. Breast and kidney tissue are known to express vitamin D receptors and were therefore used as positive controls.¹⁹⁻²¹ TBS

Academic Department of Surgery, Bristol Royal Infirmary, Bristol BS2 8HW, UK
M G Thomas
P A Sylvester
P Newcomb
R J Longman

Correspondence to: Dr Thomas.

Accepted for publication 2 November 1998

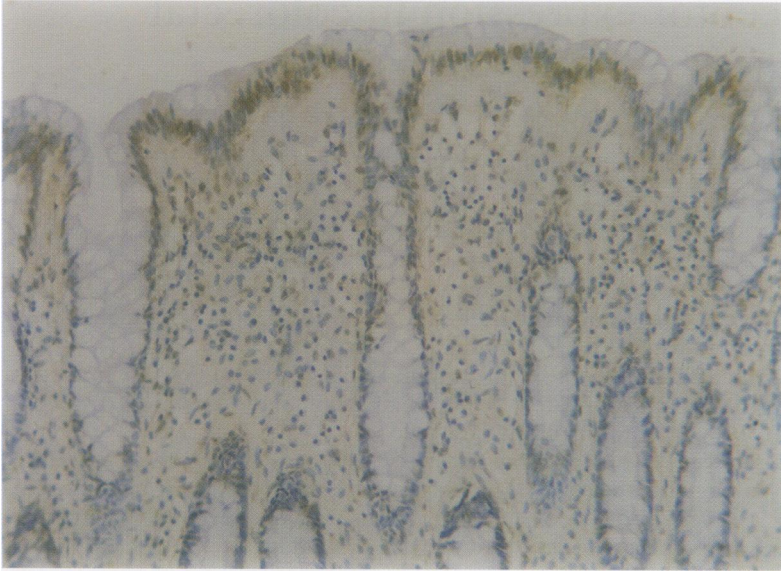


Figure 1 Vitamin D receptor staining in normal colorectal mucosa showing perinuclear localisation in the upper and mid zones of crypts: magnification $\times 235$ (original magnification $\times 400$); haematoxylin counterstain.

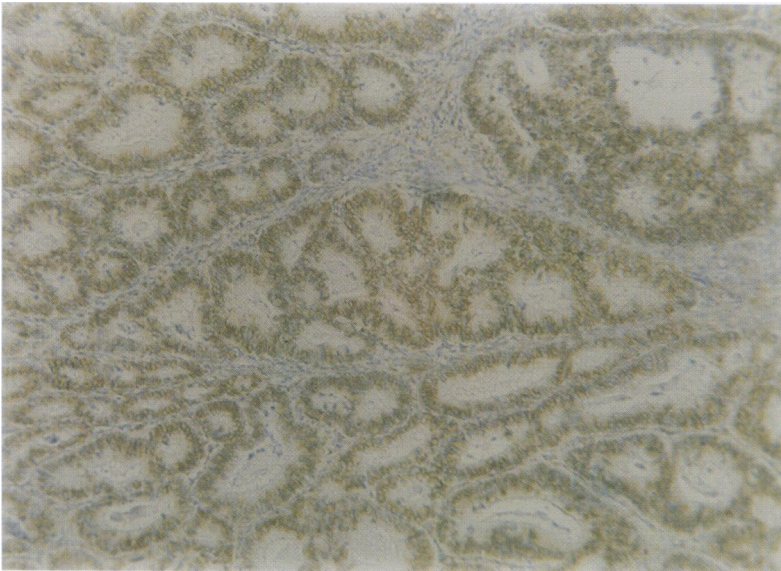


Figure 2 Vitamin D receptor staining in a moderately well differentiated colorectal adenocarcinoma showing perinuclear localisation throughout the epithelium: magnification $\times 118$ (original magnification $\times 200$); haematoxylin counterstain.

buffer was substituted for the primary antibody as a negative control. An avidin/biotin complex blocking kit (Vector Laboratories) was used with the blocking serum and primary antibody to block endogenous avidin and biotin. Specificity of the staining reaction was verified by substituting rat IgG for the monoclonal antibody on the control slides.

Immunohistochemical staining was assessed semiquantitatively by two independent observers and the mean number of cells showing strong nuclear staining was determined per graticule square at $\times 400$ magnification in 20 separate fields. The means of the median and range of scores for nuclear staining were calculated for each tissue section, and compared between groups of patients with Dukes' stage and degree of differentiation.

Results

Vitamin D receptor staining was located predominantly in the nuclei of positively reacting

cells, with very little cytoplasmic staining (fig 1). A striking gradation in immunoreactivity was seen in microscopically normal colonic crypts, the immunoreactivity being predominantly in the mid and upper crypts only. Colorectal cancer tissue from all 30 patients showed vitamin D receptor expression, with a median of 25.3 (range 10.1 to 43.7) cells/graticule (fig 2). Although vitamin D receptor staining was heterogeneous within the individual cancers it was not influenced by Dukes' staging: Dukes' A, median 29.5 (range 12.2 to 43.7); Dukes' B, 23.4 (10.1 to 43.7); Dukes' C, 26.7 (14.7 to 34.9); or by the degree of differentiation: G₁, median 39.8 (range 35.7 to 43.6); G₂, 24.5 (10.1 to 43.7); G₃, 27.0 (19.9 to 34.9).

Discussion

We have shown that nuclear vitamin D receptor expression can be demonstrated in paraffin embedded colorectal cancer tissue using immunohistochemistry. Radioligand binding studies suggest a reduction of vitamin D receptor expression in colorectal tumours,²² whereas northern blot analysis suggests that vitamin D receptor mRNA expression in normal, premalignant, and malignant epithelia is not influenced by the degree of tumour cell differentiation or Dukes' stage.¹⁶ Immunohistochemistry appears to confirm the observation that vitamin D receptor expression in colorectal cancer is not influenced by cellular differentiation or disease stage. Thus vitamin D receptor expression is unlikely to be a useful prognostic indicator of clinical outcome. The demonstration of vitamin D receptor expression in all colorectal cancer tissue might, however, suggest a potential use of synthetic vitamin D₃ analogues to induce differentiation or apoptosis in patients with large bowel cancer.

- 1 Eisman JA, Koga M, Sutherland RL, et al. 1,25-Dihydroxyvitamin D₃ and the regulator of human cancer cell replications. *Proc Soc Exp Biol Med* 1989;191:221-6.
- 2 Reichel M, Koefler HP, Norman AW. The role of vitamin D endocrine system in health and disease. *N Engl J Med* 1989;320:980-91.
- 3 Garland C, Barrett-Conner ER, Shekelle RB, et al. Dietary vitamin D and calcium and risk of colorectal cancer. *Lancet* 1985;i:307-9.
- 4 Thomas MG, Tebbutt S, Williamson RCN. Vitamin D and its metabolites inhibit cell proliferation in human rectal mucosa and a colon cancer cell line. *Gut* 1992;33:1660-3.
- 5 Thomas MG. Luminal and humoral influences on human rectal epithelial cytokinetics. *Ann R Coll Surg Engl* 1995;77:85-9.
- 6 Binderup L, Latini S, Binderup E, et al. 20-epi-Vitamin D₃ analogues: a novel class of potential regulators of cell growth and immune responses. *Biochem Pharmacol* 1991;42:1569-75.
- 7 Binderup L, Bramm E. Effects of a novel vitamin D analogue MC-903 on cell proliferation and differentiation in vitro and calcium metabolism in vivo. *Biochem Pharmacol* 1988;37:889-95.
- 8 Kragballe K, Gjertsen B, DeHoop D, et al. Double-blind, right/left comparison of calcipotriol and betamethasone valerate in treatment of psoriasis vulgaris. *Lancet* 1991;337:193-6.
- 9 Thomas MG, Brown GR, Alison MR, et al. Divergent effects of epidermal growth factor and calcipotriol on human rectal cell proliferation. *Gut* 1994;35:1742-6.
- 10 Kissmeyer A-M, Binderup L. Calcipotriol (MC 903): pharmacokinetics in rats and biological activities of metabolites. *Biochem Pharmacol* 1991;41:1601-6.
- 11 Akhter J, Chen X, Bowrey P, et al. Vitamin D₃ analog, EB1089, inhibits growth of subcutaneous xenografts of the human colon cancer cell line, LoVo, in a nude mouse model. *Dis Colon Rectum* 1997;40:317-21.
- 12 DeMay MB, Gerardi JM, DeLucci MP, et al. DNA sequences in the rat osteocalcin gene that bind the 1,25-dihydroxy vitamin D₃ receptor and confer responsiveness to 1,25-dihydroxy vitamin D₃. *Proc Natl Acad Sci USA* 1990;87:369-73.

- 13 Whitfield GK, Hsien JGC, Jurutka PW, *et al.* Genomic actions of 1,25-dihydroxy vitamin D₃. *J Nutr* 1995;215:16905-45.
- 14 Hannah SS, Norman AW. 1 α ,25-(OH)₂ Vitamin D₃-regulated expression of the eukaryotic genome. *Nutr Rev* 1994;52:376-82.
- 15 Carlberg C. Mechanism of nuclear signaling by vitamin D₃. Interplay with retinoid and thyroid hormone signaling. *Eur J Biochem* 1995;231:517-27.
- 16 Kane KF, Longman MJS, Williams GR. 1,25-Dihydroxy vitamin D₃ and retinoid receptor expression in human colorectal neoplasms. *Gut* 1995;36:255-9.
- 17 Lointier P, Meggough F, Pezet D, *et al.* 1,25-Dihydroxy vitamin D₃ receptors and human colon adenocarcinoma. *Br J Surg* 1991;78:435-9.
- 18 Colston KW, Mackay AG, Finlayson C, *et al.* Localisation of vitamin D receptor in normal human duodenum and in patients with coeliac disease. *Gut* 1994;35:1219-25.
- 19 Reichel H, Koeffler HP, Norman AW. The role of the vitamin D endocrine system in health and disease. *N Engl J Med* 1989;320:980-91.
- 20 Colston KW, Berger U, Coombes RC. Possible role for vitamin D in controlling breast cancer cell proliferation. *Lancet* 1989;i:188-91.
- 21 Eisman JA, MacIntyre I, Martin RJ, *et al.* Normal and malignant breast tissue is a target organ for 1,25-(OH)₂ vitamin D₃. *Clin Endocrinol* 1980;13:267-72.
- 22 Meggough F, Lointier P, Saez S. Sex steroid and 1,25-dihydroxy vitamin D₃ receptors in human colorectal adenocarcinoma and normal mucosa. *Cancer Res* 1991;5:1227-30.

The Royal College of Pathologists "The Best" of the College Symposia

Academic activities, Continuing Professional Development, and Blackwell Healthcare Communications are publishing a CD-ROM containing highlights of past College Symposia.

This CD-ROM is approved for CPD credits and is of general interest to pathologists. It covers a wide range of topical issues, with lectures entitled:

- Allergy and asthma
- Peanut allergy
- A practical approach to unexpected infant death
- Vitamin K prophylaxis: can we ever reach a consensus?
- Epidemiology of adverse effects of "designer drugs"
- Multi-drug resistance modifiers: an alternative approach
- Idiopathic myelofibrosis: pathogenesis to treatment
- Adhesion molecules in pathology
- Chromosomal changes and cancer
- Interpretation of injury in road traffic accidents
- Reporting of cervical biopsies in the context of the cervical screening programmes
- The metastatic process: its biological basis
- Human papilloma virus infection
- The hepatitis virus
- Alcoholic liver disease

The CD-ROM will cost you £30 for a personal copy or £120 for an institutional copy with multiple user licence. To order a copy, call 0171 930 5862.