

Needle tract implantation of thymoma after transthoracic needle biopsy

T Nagasaka, N Nakashima, H Nunome

Abstract

A 73 year old woman was admitted to hospital because of an anterior mediastinal mass. For definite diagnosis, needle biopsy was performed under fluoroscopic observation. The histopathological diagnosis was thymoma and combination chemotherapy was given. The tumour almost completely disappeared and the patient was discharged. But the tumour recurred in the left anterior chest wall four months later. It is suggested that the thymoma tissue had been implanted in the needle tract.

(J Clin Pathol 1993;46:278-279)

Transthoracic needle biopsy under fluoroscopic or computed tomographic observation has been increasingly performed as a diagnostic method for mediastinal tumour,^{1,2} and the diagnostic rate achieved by this method is high. Although few complications are believed to be associated with this method, we encountered a case of a patient with a thymoma that recurred subcutaneously at the puncture site of needle biopsy.

Case report

A 73 year old woman visiting Tokai Central Hospital for a follow up examination after operation for colon cancer (16 years previously) and cholelithiasis two years previously, was found to have abnormalities on chest x ray picture. She was admitted for further examinations. Her general condition was good, body temperature was normal, and pulse was regular; there were no findings of hepatosplenomegaly, swelling of superficial lymph nodes, anaemia or icterus. Although serum lactate dehydrogenase activity was slightly increased (492 IU/l), other laboratory data showed no abnormalities. There were no increases in tumour markers such as CEA (carcinoembryonic antigen), NSE (neuron-specific enolase), AFP (α -fetoprotein), HCG (human chorionic gonadotropin), CA19-9, SCC. A computed tomogram revealed a distinctly demarcated left anterosuperior mediastinal mass (fig 1A). To make a definite diagnosis, a percutaneous transthoracic needle biopsy was performed using a Trucut needle (18-gauge) through the left anterior chest under fluoroscopic observation. The patient was diagnosed as having thymoma by histo-

logical and cytological examination. Removal of the tumour was considered inappropriate because the tumour was too large. Instead, the patient was treated by combination chemotherapy (cyclophosphamide, cisplatin, bleomycin, vinblastine and epirubicin). The tumour disappeared almost completely as a result (fig 1B). Treatment lasted about six months (13 courses), and the patient was discharged. About four months after completion of treatment, however, a small mass developed subcutaneously in the left anterior chest, at the puncture site of the needle biopsy. The mass was excised and diagnosed histopathologically as thymoma.

Pathological findings

The biopsied tissue was composed of oval or polygonal tumour cells with oval nuclei and relatively distinct nucleoli, admixed with small lymphocytes. These findings were consistent with the lymphoepithelial type of

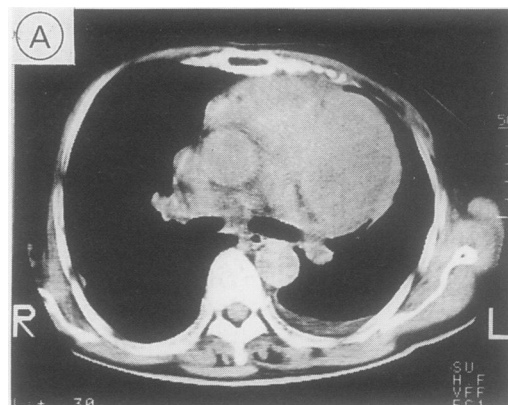


Figure 1A Computed tomogram showing a large, demarcated mass lesion located in the left anterior mediastinum.

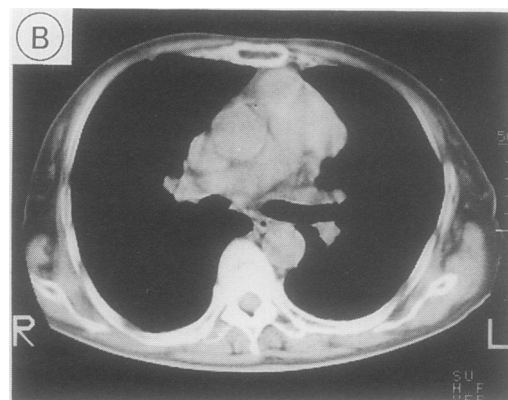

Figure 1B The tumour has almost completely disappeared after treatment

Division of Pathology,
Clinical Laboratory,
Nagoya University
Hospital

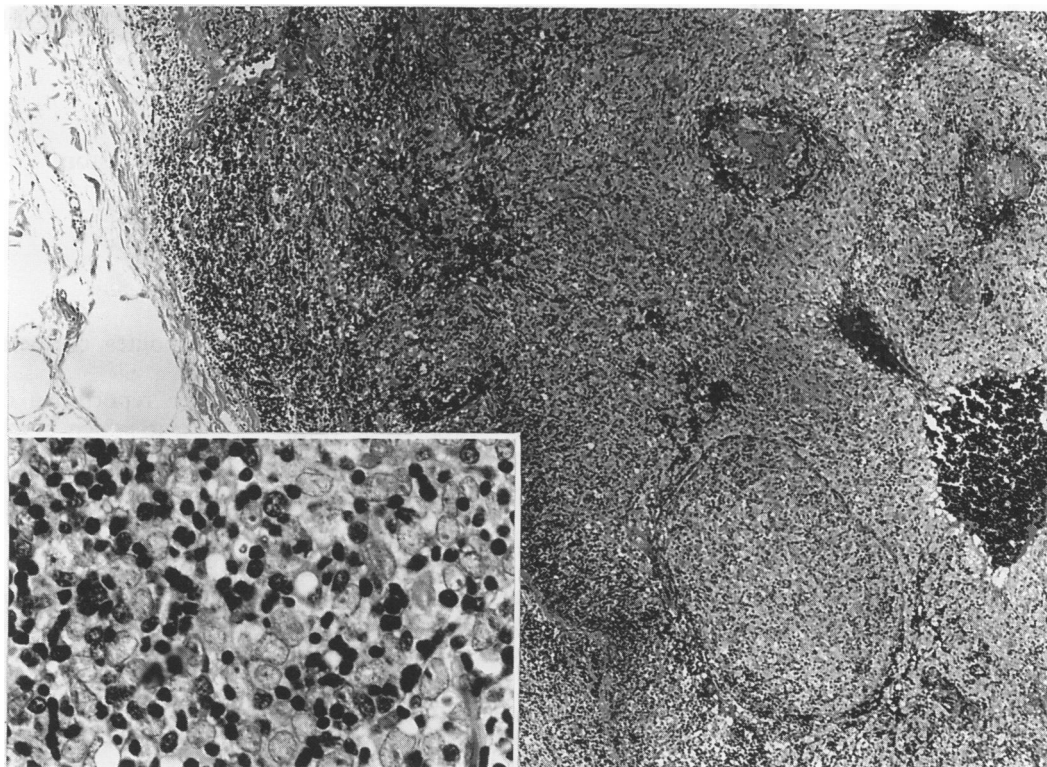
T Nagasaka,
N Nakashima

Department of
Surgery, Tokai
Central Hospital
H Nunome

Correspondence to:
Dr T Nagasaka, Division of
Pathology, Clinical
Laboratory, Nagoya
University Hospital,
Tsurumai-cho 65,
Showaku, Nagoya,
Japan 466

Accepted for publication
21 October 1992

Figure 2 Subcutaneously implanted thymoma tissue surrounded by fat tissue: round or polygonal shaped neoplastic epithelial cells have proliferated with small lymphocytes (inset). (haematoxylin and eosin).



thymoma. In imprint cytology specimens oval or polygonal shaped tumour cells with oval nuclei and distinct nucleoli showed dissociated arrangement, or formed a sheet-like pattern with small lymphocytes. Nodular proliferation of thymoma, the same histology as obtained at the time of needle biopsy, surrounded by subcutaneous fat tissue was observed in subcutaneously recurring tumour tissue (fig 2).

Discussion

The plan for treatment of a mediastinal tumour has conventionally been decided by image analysis using chest x ray picture and computed tomography, because tumour specimens for histological diagnosis have been difficult to obtain non-invasively, and the histological type of the tumour is generally assumed from its location to some extent. However, histological or cytological diagnosis is essential for accurate diagnosis. For this purpose, mediastinoscopic biopsy, needle biopsy under fluoroscopic observation or computed tomography guidance, and aspiration biopsy cytology³ have been increasingly performed, and favorable diagnostic results have been reported. Complications of needle biopsy for intrathoracic lesions include subcutaneous haematoma, haemothorax and pneumothorax, all of which are traumatic. Tumour dissemination or implantation is another complication that should also be borne in mind. Malignant tumours generally known to be susceptible to tumour metastasis or implantation, which occur due to needle biopsy, include pancreatic cancer,⁴ hepatocellular carcinoma,⁵ lung cancer⁶ and prostate cancer.⁷ Benign tumours which may be disseminated or implanted during a surgical procedure include pleomorphic adenoma of the

salivary gland⁸ and parathyroid adenoma.⁹ Thymoma may also recur as a solitary mass or as small mediastinal and pleural implants.¹⁰

To our knowledge, this is the first reported case of thymoma which has been implanted in the needle tract. Although dissemination or implantation of tumour may be caused by the use of a thick gauge needle (a Trucut needle in this case), thymoma tissue itself may have a high tendency to implant. We could not explain why the tumour recurred solely in subcutaneous tissue while the combination chemotherapy was very effective and the mediastinal tumour almost completely disappeared. The recurring tumour probably grew out of the residual mass along the needle tract because it recurred at the puncture site of the needle biopsy. Clinicians need to be alerted to the fact that thymoma can be implanted by needle biopsy using a thick gauge needle.

- 1 Jereb M, Us-Krasovec M. Transthoracic needle biopsy of mediastinal and hilar lesions. *Cancer* 1977;4:1354-7.
- 2 Sonnenberg VE, Casola G, Ho M, et al. Difficult thoracic lesions: CT-guided biopsy experience in 150 cases. *Radiology* 1988;167:457-61.
- 3 Sterrett G, Whitaker D, Shilkin KB, et al. The fine needle aspiration cytology of mediastinal lesions. *Cancer* 1983; 51:127-35.
- 4 Ferrucci JT, Wittenberg J, Margolies MN, et al. Malignant seeding of the tract after thin-needle aspiration biopsy. *Radiology* 1979;130:345-6.
- 5 Sakurai M, Seki K, Okamura J, Kuroda C. Needle tract implantation of hepatocellular carcinoma after percutaneous liver biopsy. *Am J Surg Pathol* 1983;7:191-5.
- 6 Berger RL, Dargan EL, Haung BL. Dissemination of cancer cells by needle biopsy. *J Thorac Cardiovasc Surg* 1972;63:430-2.
- 7 Labardini M, Nesbit RM. Perineal extension of adenocarcinoma of the prostate gland after punch biopsy. *J Urol* 1952;67:891-63.
- 8 Malett KJ, Harrison MS. The recurrence of salivary gland tumours. *J Laryngol Otol* 1971;85:439-48.
- 9 Rattner DW, Marrone GC, Kasdon E, Silen W. Recurrent hyperparathyroidism due to implantation of parathyroid tissue. *Am J Surg* 1980;149:745-8.
- 10 Fechner RE. Recurrence of noninvasive thymomas. Report of four cases and review of the literature. *Cancer* 1969;23:1423-7.