

## Prion protein preamyloid and amyloid deposits in Gerstmann–Sträussler–Scheinker disease, Indiana kindred

GIORGIO GIACCONE\*, LAURA VERGA\*, ORSO BUGIANI\*, BLAS FRANGIONE†, DAN SERBAN‡, STANLEY B. PRUSINER‡§, MARTIN R. FARLOW¶, BERNARDINO GHETTI||, AND FABRIZIO TAGLIAVINI\*,\*\*

\*Istituto Neurologico Carlo Besta, 20133 Milan, Italy; †Department of Pathology, New York University Medical Center, New York, NY 10016; Departments of ‡Neurology and §Biochemistry and Biophysics, University of California, San Francisco, CA 94143-0518; and Departments of ¶Neurology and ||Pathology, Indiana University School of Medicine, Indianapolis, IN 46202-5120

Communicated by Dominick P. Purpura, June 25, 1992

**ABSTRACT** Gerstmann–Sträussler–Scheinker disease (GSS) is a familial neurological disorder pathologically characterized by amyloid deposition in the cerebrum and cerebellum. In GSS, the amyloid is immunoreactive to antisera raised against the prion protein (PrP) 27–30, a proteinase K-resistant peptide of 27–30 kDa that is derived by limited proteolysis from an abnormal isoform of a neuronal sialoglycoprotein of 33–35 kDa designated PrP<sup>Sc</sup>. Polyclonal antibodies raised against synthetic peptides homologous to residues 15–40 (P2), 90–102 (P1), and 220–232 (P3) of the amino acid sequence deduced from hamster PrP cDNA were used to investigate immunohistochemically the distribution of PrP and PrP fragments in the brains of two patients from the Indiana kindred of GSS. Two types of anti-PrP-immunoreactive deposits were found: (i) amyloid deposits, which were exclusively labeled by anti-P1 antiserum to residues 90–102 of PrP, and (ii) preamyloid deposits, which were labeled by all anti-PrP antisera but did not exhibit the tinctorial and optical properties of amyloid. The latter appeared as diffuse immunostaining of the neuropil that targeted to areas in which amyloid deposits were most abundant. They were partially resistant to proteinase K digestion and consisted ultrastructurally of amorphous, flaky, electron-dense material. These findings substantiate our previous observation that the major amyloid component in the GSS Indiana kindred is an internal fragment of PrP and indicate that full-length abnormal isoforms of PrP and/or large PrP fragments accumulate in brain regions most affected by amyloid deposition. These findings support the view that in the GSS Indiana kindred a stepwise degradation of PrP occurs *in situ* in the process of amyloid fibril formation.

Gerstmann–Sträussler–Scheinker disease (GSS) is a familial neurological disorder pathologically characterized by amyloid deposition in the cerebrum and cerebellum (1–3). In GSS, the amyloid is immunoreactive to antisera raised against the prion protein (PrP) 27–30 (4–7), a proteinase K-resistant peptide of 27–30 kDa that is derived by limited proteolysis from an abnormal isoform of a neuronal sialoglycoprotein of 33–35 kDa designated PrP<sup>Sc</sup> (8–12). The normal homologue of human PrP (PrP<sup>C</sup>) consists of 253 amino acids (12). By analogy with hamster PrP, it is likely that 22 amino acids are cleaved from the N terminus as the signal peptide is removed and that 23 amino acids are removed from the C terminus upon addition of a glycoinositol phospholipid anchor (13, 14).

PrP 27–30 has been detected only in animals and humans with prion diseases (e.g., natural and experimental scrapie, and Creutzfeldt–Jacob disease) (8, 15, 16) and is a major component of amyloid fibrils isolated from scrapie-infected brains (17–19). The pathologic process leading to conversion of PrP<sup>C</sup> to PrP<sup>Sc</sup> and to formation of an amyloidogenic peptide is unknown. Recent investigations have shown that missense

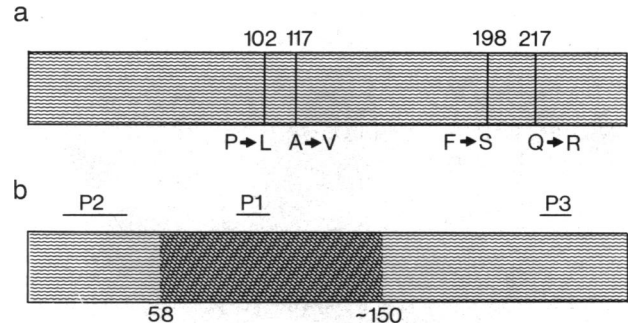


FIG. 1. (a) Human PrP mutations associated with GSS. Codon numbers and amino acid substitutions are indicated at the top and at the bottom, respectively. The mutation in the Indiana kindred is at codon 198 and results in substitution of serine for phenylalanine. (b) Map of anti-PrP antisera used for study (P2, P1, and P3) and of the amyloid protein isolated from GSS brains of the Indiana kindred (dark area). Codon numbers corresponding to the N and C termini of the amyloid protein, respectively, are indicated at the bottom.

mutations are present in the *PRNP* gene of GSS patients. To date, four mutations have been identified in different families at codons 102, 117, 198, and 217 (Fig. 1a) (20–26). The mutation in the Indiana kindred of GSS is at codon 198 and results in substitution of serine for phenylalanine (22, 27). This family differs from most GSS kindreds because Alzheimer-type neurofibrillary tangles are present in the cerebral cortex and subcortical nuclei (6, 7, 28).

In a previous study it was found that the major component of amyloid fibrils isolated from patients of the Indiana kindred of GSS is an 11-kDa fragment of PrP, whose N terminus corresponds to residue 58 of the amino acid sequence deduced from the human PrP cDNA (Fig. 1b) (29). In addition, amyloid fractions contained larger PrP fragments with apparently intact N termini. On this basis we hypothesized that in the Indiana kindred of GSS a stepwise degradation of the precursor protein occurs in the process of amyloid protein formation (29). This scenario would parallel that proposed for Alzheimer disease, in which preamyloid deposits made up of non-fibrillary precursors precede the formation of  $\beta$ -amyloid fibrils (30–33). To explore this hypothesis, we carried out an immunohistochemical, light and electron microscopic study on brains of patients from the Indiana kindred of GSS, using antibodies to different domains of the PrP molecule.

### MATERIAL AND METHODS

Blocks of frontal and temporal lobes and cerebellum obtained from two GSS patients (age at death, 47 and 58 years) were

Abbreviations: GSS, Gerstmann–Sträussler–Scheinker disease; PrP, prion protein.

\*\*To whom reprint requests should be addressed at: Istituto Neurologico Carlo Besta, via Celoria 11, 20133 Milan, Italy.

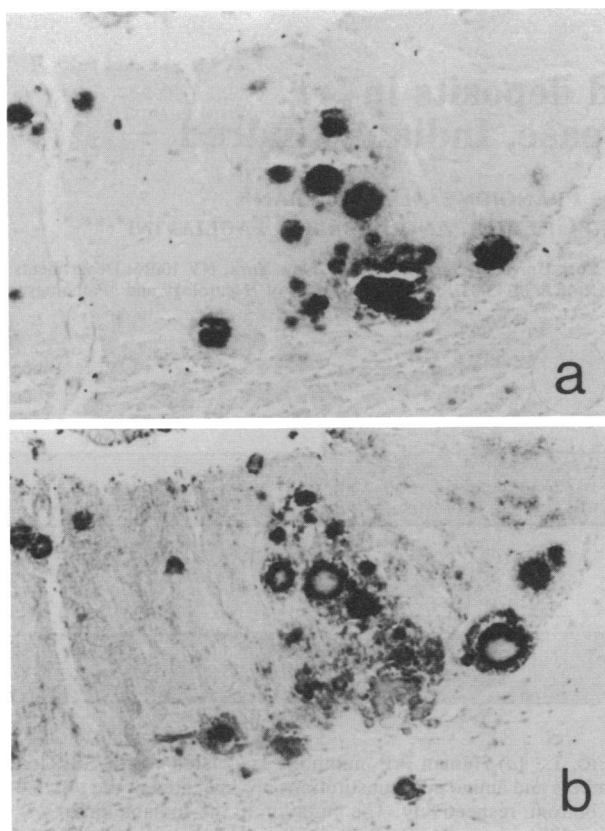


FIG. 2. Cerebellum of the 58-year-old GSS patient of the Indiana kindred. Anti-P1 antiserum (*a*) labels amyloid cores, whereas anti-P2 (*b*) and anti-P3 (data not shown) antisera stain the periphery of amyloid deposits rather than the center. (*a* and *b* are adjacent sections.) ( $\times 95$ .)

fixed in 4% formaldehyde, or periodate/lysine/paraformaldehyde, or Carnoy solution, and embedded in Paraplast. For

light microscopy, 7- $\mu$ m-thick serial sections were stained with Congo red and thioflavine S or incubated with antisera raised in rabbits to synthetic peptides corresponding to residues 15–40 (P2), 90–102 (P1), and 220–232 (P3) of the cDNA-deduced amino acid sequence of hamster PrP (Fig. 1*b*). The antisera, which have been characterized previously (34), were used at a dilution of 1:200 and were detected by the peroxidase–antiperoxidase (PAP) method with swine anti-rabbit immunoglobulins, PAP complex (DAKO, Carpinteria, CA), and 3,3'-diaminobenzidine as chromogen. Before immunostaining, some sections were digested with proteinase K (25  $\mu$ g/ml) for 10 min at 37°C, or treated with 98% formic acid for 30 min at room temperature, or subjected to both proteinase K digestion and formic acid treatment. For electron microscopy, 50- $\mu$ m-thick Paraplast-embedded sections of cerebral cortex were deparaffinized in xylene and rehydrated through graded ethanol solutions. Immunogold labeling with anti-P1, anti-P2, and anti-P3 antisera (1:20) was performed by means of goat anti-rabbit immunoglobulins conjugated with 10-nm colloidal gold particles (1:20; Biocell Laboratories), following a pre-embedding procedure described in detail elsewhere (33). Specificity of immunoreactions was checked by using normal rabbit serum as primary antibody or by peptide absorption. Each antiserum was incubated with the relevant peptide (10 mM) for 1 hr at 37°C and then overnight at 4°C. After centrifugation at  $10,000 \times g$ , the supernatants were used as primary antibodies. As a control, brain specimens from three patients with late-onset Alzheimer disease (age at death, 75, 78, and 86 years) and three nondemented individuals (age at death, 49, 62, and 66 years) were processed following the same protocol.

## RESULTS

Two types of anti-PrP-immunoreactive deposits were detected in the neuropil of GSS patients of the Indiana kindred: (*i*) amyloid deposits and (*ii*) deposits without tinctorial and optical properties of amyloid.

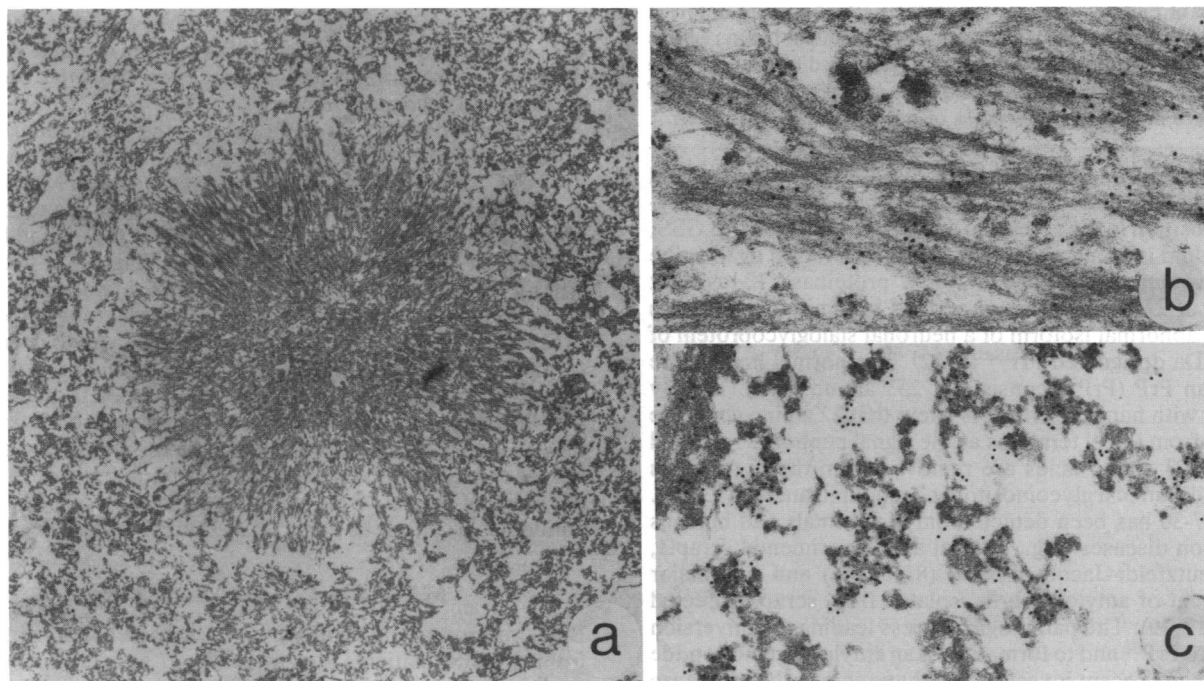


FIG. 3. Cerebellum of the 58-year-old GSS patient of the Indiana kindred. At the electron microscopic level, amyloid deposits are composed of bundles of radially oriented filaments and are surrounded by amorphous material (*a*). Immunogold electron microscopy shows that 8- to 10-nm fibrils in the amyloid cores are labeled by anti-P1 (*b*), whereas amorphous material at the periphery of amyloid deposits is labeled by anti-P2 (*c*) and anti-P3 (data not shown). (*a*,  $\times 6000$ ; *b* and *c*,  $\times 33,000$ .)

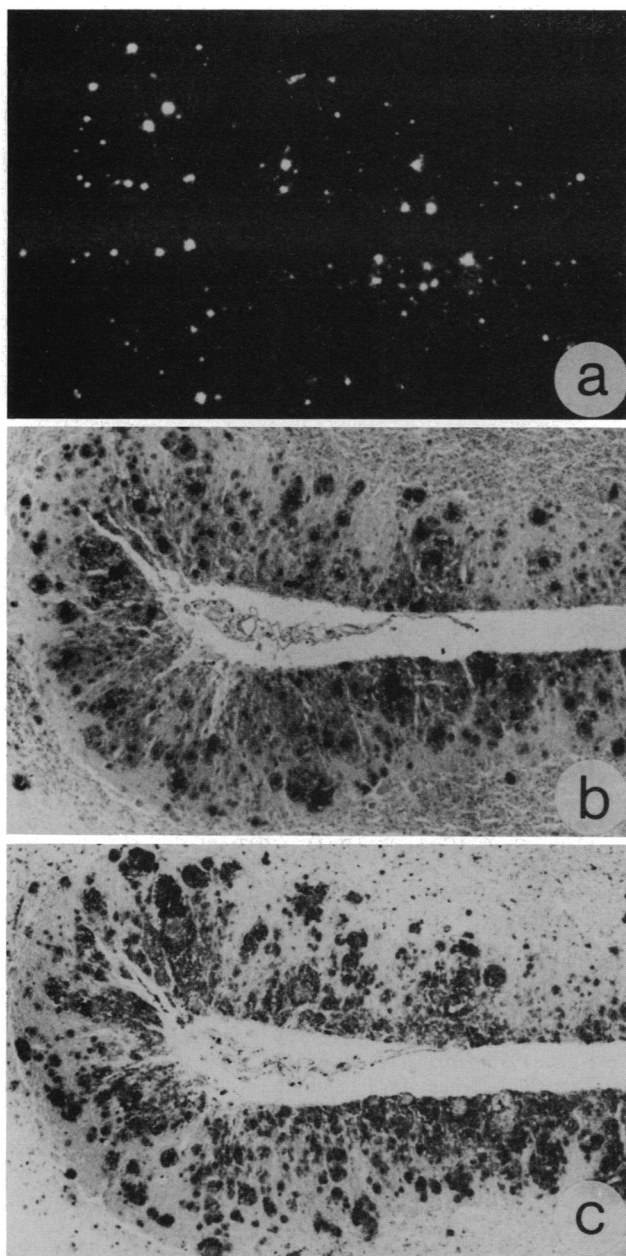


FIG. 4. PrP amyloid and preamyloid deposits in the cerebellum of the 58-year-old GSS patient of the Indiana kindred. Thioflavine S (*a*) and anti-P1 immunoperoxidase (*b*) reveal PrP amyloid deposits. Following proteinase K digestion and formic acid treatment, anti-P1 antiserum (*b*) also immunostains large areas of neuropil that are non-fluorescent after thioflavine S treatment. The same areas are labeled by anti-P2 (data not shown) and anti-P3 (*c*) antisera on adjacent sections, and are indicated as PrP preamyloid deposits. (*a*, *b*, and *c* are adjacent sections.) ( $\times 65$ .)

**PrP Amyloid Deposits.** All amyloid deposits revealed by Congo red and thioflavine S were labeled by anti-P1 antiserum, which is directed to residues 90–102 of hamster PrP (Fig. 2*a*). When sections were either digested with proteinase K or treated with formic acid, the antiserum decorated strongly the amyloid cores and faintly the surrounding tissue. A different outcome occurred with anti-P2 and anti-P3, the antisera to N- and C-terminal domains of hamster PrP. These antibodies labeled the periphery of amyloid deposits and the surrounding neuropil rather than the center. In many instances, unstained cores were contoured by a sharply defined ring of intense immunoreactivity (Fig. 2*b*). Proteinase K

digestion decreased significantly the immunoreactivity of anti-P2 but did not modify the immunoreactivity of anti-P3.

By electron microscopy, anti-P1 antiserum decorated 8- to 10-nm fibrils in the amyloid cores, whereas anti-P2 and anti-P3 mostly labeled amorphous material at the periphery of the cores (Fig. 3).

**PrP Deposits Without Tinctorial and Optical Properties of Amyloid.** In regions where the amyloid deposits were most abundant (i.e., molecular layer of cerebellar cortex and lower layers of cerebral cortex) anti-P1, anti-P2, and anti-P3 antisera diffusely immunostained large areas of neuropil that encompassed unlabeled neurons, glial cells, and small vessels (Fig. 4*b* and *c*). These areas were nonbirefringent after Congo red and nonfluorescent after thioflavine S (Fig. 4*a*). The immunoreactivity of these diffuse areas with anti-P1 antiserum was observed only when sections were subjected to both proteinase K digestion and formic acid treatment (Fig. 4*b*). Conversely, the immunostaining with anti-P2 and anti-P3 was present without pretreatments (Fig. 4*c*). Proteinase K digestion decreased significantly the immunoreactivity of anti-P2 but did not modify the immunoreactivity of anti-P3. At the electron microscopic level, the immunolabeling corresponded to extracellular flaky, amorphous, electron-dense material.

Immunostaining with anti-P1, anti-P2, and anti-P3 was abolished by absorption of the antisera with the corresponding peptides. Immunostaining was absent when normal rabbit serum was used as primary antibody. No immunostaining with anti-P1, anti-P2, or anti-P3 was obtained in the brains of Alzheimer patients and nondemented individuals.

## DISCUSSION

These findings substantiate our previous observation that the major amyloid component in the Indiana family of GSS is an internal fragment of the PrP molecule (29). In fact, fibrils in the amyloid cores were immunoreactive with anti-P1, which recognizes a PrP region included in the 11-kDa amyloid protein purified from GSS brains from the Indiana kindred, whereas they were not immunolabeled by anti-P2 and anti-P3, which are directed to N- and C-terminal domains of PrP, respectively (Fig. 1*b*). On the other hand, anti-P2 antiserum decorated the periphery of amyloid deposits, in accordance with immunohistochemical data obtained by Kitamoto *et al.* (35) with an antibody to a synthetic peptide homologous to residues 25–49 of PrP. In addition, we found that the antiserum to the C terminus of PrP (i.e., anti-P3) yielded the same pattern of immunoreactivity, which corresponded ultrastructurally to flaky, amorphous, electron-dense material.

A striking feature of GSS brains from the Indiana kindred was the diffuse accumulation of anti-PrP-immunoreactive material in large areas of the neuropil in regions most affected by amyloid deposition. This material was labeled by antisera spanning the PrP molecule from N to C terminus, was undetectable with Congo red and thioflavine S, and was largely non-fibrillary when examined by electron microscopy. Moreover, proteinase K digestion did not modify the immunoreactivity with anti-P1 and anti-P3 antisera, whereas it decreased significantly the immunoreactivity with anti-P2 antiserum. On these grounds, we suggest that this widespread immunostaining in the neuropil corresponds to deposition of either full-length abnormal isoforms of PrP or large PrP fragments that eventually may be converted into amyloid protein by further proteolysis. Since fractions purified from GSS brains of the Indiana kindred contained PrP fragments of different molecular mass in addition to the 11-kDa amyloid protein (29), it is likely that a stepwise degradation of the precursor protein occurs in the process of amyloid formation.

Genetic mutations leading to amino acid substitutions at residues 102, 117, 198, and 217 of PrP have been detected in different GSS families (20–26). The role of these mutations in

amyloidogenesis is unknown. However, changes in the primary structure of PrP might increase the inherent fibrillogenic properties of the molecule or modify its posttranslational processing and degradation and therefore may be important in the genesis of these deposits. In this regard, it has been shown that transgenic mice expressing both Syrian hamster and mouse PrP genes produce cerebral amyloid deposits when inoculated with Syrian hamster PrP<sup>Sc</sup> but not when injected with mouse PrP<sup>Sc</sup>, suggesting that the amino acid sequence of the abnormal isoforms of PrP is an important determinant for the formation of an amyloidogenic peptide (36). On the other hand, it seems unlikely that accumulation of PrP molecules throughout the neuropil in GSS patients is due to overexpression of PrP, since PrP mRNA levels do not change during the course of scrapie infection (11, 13).

Extracellular accumulations of amyloid fibril precursors have been observed in other types of amyloidosis. In Alzheimer disease, non-congophilic lesions labeled by antibodies to the amyloid  $\beta$ -protein precede amyloid formation and have been consequently designated as preamyloid deposits (30–33). In light-chain deposition disease, which is regarded as an early stage of light-chain amyloidosis, non-congophilic, non-fibrillary deposits containing both intact light chains and light-chain fragments of various molecular weights accumulate in several tissues (37, 38). Accordingly, non-congophilic areas immunoreactive with antibodies to different domains of PrP in GSS brains of the Indiana kindred could be indicated as PrP preamyloid deposits. Similar lesions have been found in the terminal stages of experimental scrapie by means of monoclonal and polyclonal antibodies to PrP 27–30 purified from scrapie-infected hamster and mouse brains (39–41). It is noteworthy, in this regard, that PrP preamyloid deposits target to areas in which the major pathologic hallmark of the disease—amyloid deposits in GSS or spongiform changes in scrapie (39, 40)—is most severe. This suggests that accumulation of abnormal isoforms of PrP can play a role in the development of tissue pathology of prion diseases.

In conclusion, in the Indiana kindred of GSS, cerebral and cerebellar amyloid deposits are associated with PrP-immunoreactive deposits that lack tinctorial, optical, and ultrastructural characteristics of amyloid and have been therefore designated as PrP amyloid deposits. Our data suggest that PrP preamyloid deposits contain either full-length PrP molecules or large N- and C-terminal fragments of PrP that may be further processed *in situ* to produce the 11-kDa amyloid subunit that polymerizes into insoluble fibrils.

We are grateful to Mr. L. Frigerio, Ms. R. Funkhouser, and Ms. C. J. Alyea for skillful technical assistance. This work was supported in part by the Italian Ministry of Health, Department of Social Services, by the U.S. Public Health Service (Grant NS29822 to B.G.), and by funds provided to B.G. by Alzheimer's Disease Research, a program of the American Health Assistance Foundation (Rockville, MD).

- Gerstmann, J., Strüssler, E. & Scheinker, I. (1936) *Z. Gesamte Neurol. Psychiatr.* **154**, 736–762.
- Masters, C. L., Gajdusek, D. C. & Gibbs, C. J., Jr. (1981) *Brain* **104**, 559–588.
- Farlow, M. R., Tagliavini, F., Bugiani, O. & Ghetti, B. (1991) in *Handbook of Clinical Neurology: Hereditary Neuropathies and Spinocerebellar Atrophies*, ed. de Jong, J. M. B. V. (Elsevier, Amsterdam), Vol. 60, pp. 619–633.
- Kitamoto, T., Tateishi, J., Tashima, T., Takeshita, I., Barry, R. A., DeArmond, S. J. & Prusiner, S. B. (1986) *Ann. Neurol.* **20**, 204–208.
- Kitamoto, T., Tateishi, J. & Sato, Y. (1988) *Ann. Neurol.* **24**, 537–542.
- Ghetti, B., Tagliavini, F., Masters, C. L., Beyreuther, K., Giaccone, G., Verga, L., Farlow, M. R., Conneally, P. M., Dlouhy, S. R., Azzarelli, B. & Bugiani, O. (1989) *Neurology* **39**, 1453–1461.
- Giaccone, G., Tagliavini, F., Verga, L., Frangione, B., Farlow, M. R., Bugiani, O. & Ghetti, B. (1990) *Brain Res.* **530**, 325–329.
- Bolton, D. C., McKinley, M. P. & Prusiner, S. B. (1982) *Science* **218**, 1309–1311.
- McKinley, M. P., Bolton, D. C. & Prusiner, S. B. (1983) *Cell* **35**, 57–62.
- Prusiner, S. B., Grooth, D. F., Bolton, D. C., Kent, S. B. & Hood, L. E. (1984) *Cell* **38**, 127–134.
- Oesch, B., Westaway, D., Wälchli, M., McKinley, M. P., Kent, S. B. H., Aebersold, R., Barry, R. A., Tempst, P., Teplov, D. B., Hood, L. E., Prusiner, S. B. & Weissmann, C. (1985) *Cell* **40**, 745–746.
- Kretzschmar, H. A., Stowring, L. E., Westaway, D., Stubblebine, W. H., Prusiner, S. B. & DeArmond, S. J. (1986) *DNA* **5**, 315–324.
- Basler, K., Oesch, B., Scott, M., Westaway, D., Wälchli, M., Groth, D. F., McKinley, M. P., Prusiner, S. B. & Weissmann, C. (1986) *Cell* **46**, 417–428.
- Stahl, N., Borchelt, D. R., Hsiao, K. & Prusiner, S. B. (1987) *Cell* **51**, 229–240.
- Bockman, J. M., Kingsbury, D. T., McKinley, M. P., Bendheim, P. E. & Prusiner, S. B. (1985) *N. Engl. J. Med.* **312**, 73–78.
- Brown, P., Coker-Vann, M., Pomeroy, K., Franko, M., Asher, D. M., Gibbs, C. J. & Gajdusek, D. C. (1986) *N. Engl. J. Med.* **314**, 547–551.
- Prusiner, S. B., Bolton, D. C., Grooth, D. F., Bowman, K. A., Cochran, S. P. & McKinley, M. P. (1982) *Biochemistry* **21**, 6942–6950.
- Prusiner, S. B., McKinley, M. P., Bowman, K. A., Bolton, D. C., Bendheim, P. E., Grooth, D. F. & Glenner, G. G. (1983) *Cell* **35**, 349–358.
- Diringer, H., Gelderblom, H., Hilmert, H., Oezel, M., Edelbluth, C. & Kimberlin, R. H. (1983) *Nature (London)* **306**, 476–478.
- Hsiao, K., Baker, H. F., Crow, T. J., Poulter, M., Owen, F., Terwilliger, J. D., Westaway, D., Ott, J. & Prusiner, S. B. (1989) *Nature (London)* **338**, 342–345.
- Doh-ura, K., Tateishi, J., Sasaki, H., Kitamoto, T. & Sakaki, Y. (1989) *Biochem. Biophys. Res. Commun.* **163**, 974–979.
- Hsiao, K., Dlouhy, S. R., Farlow, M. R., Cass, C., DaCosta, M., Conneally, P. M., Hodes, M. E., Ghetti, B. & Prusiner, S. B. (1992) *Nat. Genet.* **1**, 68–71.
- Tateishi, J., Kitamoto, T., Doh-ura, K., Sakaki, Y., Steinmetz, G., Tranchant, C., Warter, J. M. & Heldt, N. (1990) *Neurology* **40**, 1578–1581.
- Brown, P., Goldfarb, L. G., Brown, W. T., Goldgaber, D., Rubenstein, R., Kascsak, R. J., Guiryo, D. C., Piccardo, P., Boellard, J. W. & Gajdusek, D. C. (1991) *Neurology* **41**, 375–379.
- Tranchant, C., Doh-ura, K., Steinmetz, G., Chevalier, Y., Kitamoto, T., Tateishi, J. & Warter, J. M. (1991) *Rev. Neurol.* **147**, 274–278.
- Kretzschmar, H., Honold, G., Seitelberger, F., Feucht, M., Wessely, P., Mehraein, P. & Budka, H. (1991) *Lancet* **337**, 1160.
- Dlouhy, S. R., Hsiao, K., Farlow, M. R., Foroud, T., Conneally, P. M., Johnson, P., Prusiner, S. B., Hodes, M. E. & Ghetti, B. (1992) *Nat. Genet.* **1**, 64–67.
- Ghetti, B., Tagliavini, F., Hsiao, K., Dlouhy, S. R., Yee, R. D., Giaccone, G., Conneally, P. M., Hodes, M. E., Bugiani, O., Prusiner, S. B., Frangione, B. & Farlow, M. R. (1992) in *Prion Diseases of Humans and Animals*, eds. Prusiner, S. B., Collinge, J., Powell, B. & Anderton, B. (Ellis Horwood, London), in press.
- Tagliavini, F., Prelli, F., Ghiso, J., Bugiani, O., Serban, D., Prusiner, S. B., Farlow, M. R., Ghetti, B. & Frangione, B. (1991) *EMBO J.* **10**, 513–519.
- Tagliavini, F., Giaccone, G., Frangione, B. & Bugiani, O. (1988) *Neurosci. Lett.* **93**, 191–196.
- Giaccone, G., Tagliavini, F., Linoli, G., Bouras, C., Frigerio, L., Frangione, B. & Bugiani, O. (1989) *Neurosci. Lett.* **97**, 232–238.
- Bugiani, O., Giaccone, G., Frangione, B., Ghetti, B. & Tagliavini, F. (1989) *Neurosci. Lett.* **103**, 263–268.
- Verga, L., Frangione, B., Tagliavini, F., Giaccone, G., Migheli, A. & Bugiani, O. (1989) *Neurosci. Lett.* **105**, 294–299.

34. Barry, R. A., Vincent, M. T., Kent, S. B. H., Hood, L. E. & Prusiner, S. B. (1988) *J. Immunol.* **140**, 1188–1193.
35. Kitamoto, T., Muramoto, T., Hilbich, C., Beyreuther, K. & Tateishi, J. (1990) *Brain Res.* **545**, 319–321.
36. Prusiner, S. B., Scott, M., Foster, D., Pan, K. M., Groth, D., Mirenda, C., Torchia, M., Yang, S. L., Serban, D., Carlson, G. A., Hoppe, P. C., Westaway, D. & DeArmond, J. (1990) *Cell* **63**, 673–686.
37. Picken, M. M., Frangione, B., Barlogie, B., Luna, M. & Gallo, G. (1989) *Am. J. Pathol.* **134**, 749–754.
38. Yang, G. C. H. & Gallo, G. (1990) *Am. J. Pathol.* **137**, 1223–1231.
39. DeArmond, S. J., Mobley, W. C., DeMott, D. L., Barry, R. A., Beckstead, J. H. & Prusiner, S. B. (1987) *Neurology* **37**, 1271–1280.
40. Bruce, M. E., McBride, P. A. & Farquhar, C. F. (1989) *Neurosci. Lett.* **102**, 1–6.
41. Diedrich, J. F., Bendheim, P. E., Kim, Y. S., Carp, R. I. & Haase, A. T. (1991) *Proc. Natl. Acad. Sci. USA* **88**, 375–379.