

Fungemia due to *Kodamaea ohmeri* in a young infant and review of the literature



Rosalba Vivas^{a,*}, Claudia Beltran^a, Maria Isabel Munera^b, Monica Trujillo^{a,b}, Andrea Restrepo^{a,b}, Carlos Garcés^{b,c}

^a CES University, Medellin, Antioquia 050035, Colombia

^b Hospital Pablo Tobon Uribe, Medellin, Antioquia, Colombia

^c Antioquia University, Medellin, Antioquia, Colombia

ARTICLE INFO

Article history:

Received 9 May 2016

Received in revised form

8 June 2016

Accepted 20 June 2016

Available online 20 June 2016

Keywords:

Kodamaea ohmeri

Fungemia

Infant

Yeast

Liposomal amphotericin B

ABSTRACT

Fungal infections have become an important cause of morbidity and mortality in hospitalized children due to many complicating and underlying conditions. We present the case of a newborn infant with fungemia due to *Kodamaea ohmeri* who had a good outcome of the infection after using the combination of antifungal treatment and central venous catheter removal.

© 2016 The Authors. International Society for Human and Animal Mycology. Published by Elsevier B.V.

This is an open access article under the CC BY-NC-ND license

(<http://creativecommons.org/licenses/by-nc-nd/4.0/>).

1. Introduction

Invasive candidiasis is the most common fungal infection reported in healthcare-associated infections. Depending on the series, *Candida albicans* is the 3rd or 4th cause of catheter-associated blood stream infections in children. In recent years, non-albicans species have been more frequently isolated, including *Candida parapsilosis* in neonates and others such as, *C. glabrata*, *C. krusei*, *C. guilliermondii* all of these important because of their resistance to azoles [1,2].

Kodamaea ohmeri, formerly named *Pichia ohmeri*, corresponds to the teleomorphic (sexual) state of *Candida guilliermondii* var. *membranaefaciens* belonging to the class Ascomycetiae and Saccharomycetaceae family [3]. It is a yeast which was initially isolated in cucumber salts used in the food industry for the fermentation of pickled foods, tree barks and fruits. It has also been isolated from environmental sources such as, pools, sand, floors and sea water [3]. In the past, *Kodamaea ohmeri*, was considered a contaminant, but at present some species are recognized as emerging opportunistic pathogens which can cause infection in patients with special underlying conditions including prematurity, immunosuppression, prolonged hospitalizations, prosthetic valves,

CVL's or other medical devices such as peritoneal catheters [4].

2. Case

A male infant 54 days old, developed fever, tachycardia, leukocytosis, high reactive C protein and thrombocytopenia while he was hospitalized since 21 days ago because diarrhoea, respiratory distress and hypovolemic shock that needed NICU admission, with diagnosis of acute necrotizing enterocolitis (NEC).

He was born at 35 weeks, delivered at home and small for gestational age. During the hospitalization he had required mechanical ventilation and treatment with ampicillin, vancomycin, meropenem and fluconazole for 9 days because suspect of fungemia and had also bacteremia by *S. epidermidis*, multilobar pneumonia and Cytomegalovirus pneumonitis treated with ganciclovir.

At time of clinical worsening, yeasts were isolated from peripheral and central line blood cultures, caspofungin was started and CVL was removal. Further identification of the yeast by the automatic system Vitek-2 (YST bioMérieux, Marcy-l'Etoile, France) was *Kodamaea ohmeri* (*Pichia ohmeri*). Subsequently, it was subcultured in sabouraud dextrose agar in which white, rugged colonies were observed, which did not grow in mycosel culture media. In addition, it was also plated in CHROMagar media for

* Corresponding author.

E-mail address: rossyviv@hotmail.com (R. Vivas).

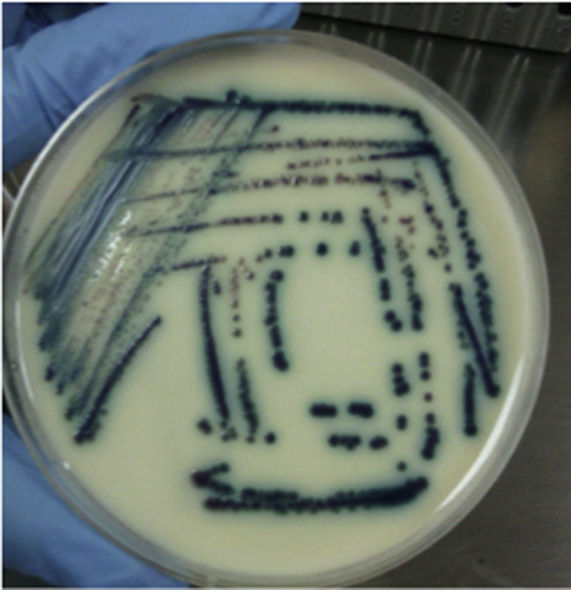


Fig. 1. *Kodamaea ohmeri* colonies in CHROMagar Candida. Pink colonies that change to blue colonies in 48 h. (For interpretation of the references to color in this figure legend, the reader is referred to the web version of this article.)

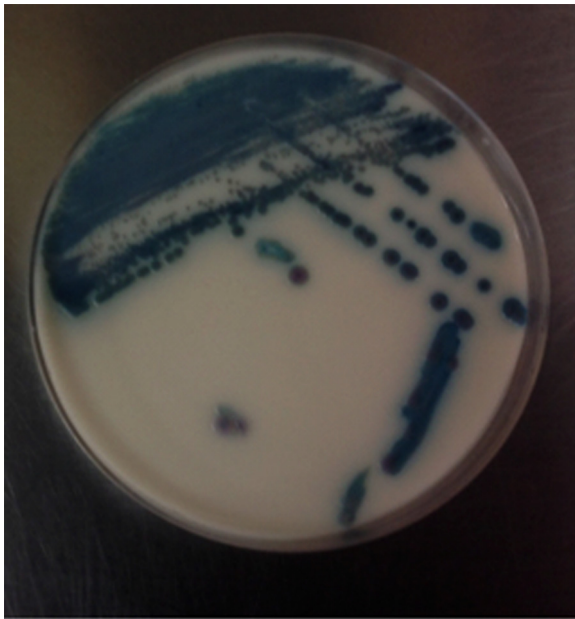


Fig. 2. *K. ohmeri* colonies in CHROMagar Candida. Pink colonies that change to blue colonies in 48 h. (For interpretation of the references to color in this figure legend, the reader is referred to the web version of this article.)

Candida with growth of pink colonies that later turned to a blue-green color (Figs. 1 and 2). Finally, API20C was done which confirmed the isolate as *Kodamaea ohmeri*.

Susceptibility testing revealed resistance to fluconazole with the following minimal inhibitory concentrations (MIC's): Fluconazole = 8 µg/dl, Amphotericin B = 0.5 µg/mL and voriconazole < = 0.12 µg/mL (see Table 1). Treatment with amphotericin B deoxycolate (AMB-Doc) IV at a dose of 1 mg/kg/day was started along with good clinical response. Follow up blood cultures on the 5th day of treatment were negative and antifungal treatment was continued for a total of 14 days since the first negative blood culture. The patient had a full recovery and was discharged at 3 months of age.

Table 1

Minimal inhibitory concentrations (MIC's) of the *K. ohmeri* isolate of our patient.

Antifungal	MIC (µg/mL)	Classification
Fluconazole	8	Resistant
Amphotericin B	0.5	Susceptible
Caspofungin	< = 0.12	Susceptible

3. Discussion

The first clinical isolate of *Kodamaea ohmeri* was reported in 1984 from a pleural fluid sample but at that time it was considered a contaminant. That same year, fungemia in a 48 year old diabetic patient with immunosuppression due renal transplantation was reported, who subsequently died from the infection [5]. Since then, more infections with this yeast have been reported considering it a true clinical pathogen, especially in patients with underlying immunosuppression.

The most of those case reports are from Asia (Korea, Turkey, India). There are a few from North America [5], some from Brazil [6] and none from Colombia. The largest series reported in the same site included 38 patients from a tertiary care hospital in North India, with 78.9% of these cases corresponding to neonates in intensive care units. In that series, the attributed mortality from this infection was 31.8%, but there are other reports of mortality as high as 50% in the pediatric population [3,7,8].

Of the 5 species recognized in the *Kodamaea* genus, only *K. ohmeri* has the capacity to grow at 37 °C and cause human disease. The clinical relevance of the other species of *Kodamaea* (*K. anthropila*, *K. kakaduensis*, *K. laetipori*, *K. nitidulidarum*) has not been established [9].

One of the methods currently available for identification is the API 20C test for carbohydrate fermentation, which is considered the gold standard for identification of yeasts. In this test, *K. ohmeri* is able to assimilate raphinose but not D-xylose. This method can have false positive results identifying some species of *C. haemulonii* or *C. parapsilosis* as *K. ohmeri*. Another method is the Vitek 2 ID-YST system which identifies with more accuracy this species of *Candida*, although there have been some missed identifications with *C. haemulonii*. [7].

The CHROMagar Candida (BBL, Beckton Dickinson, Sparks, MD) method allows species identification according to the color changes of the colonies in the agar, in which *K. ohmeri* changes from pink to blue in a period of 48 h, as was observed in our case. (Fig. 1).

At present, molecular diagnosis is available through the amplification and sequencing of the ITS2 region localized on the rRNA gene of the 5.8S and 28S subunit. It can also be typed through restriction endonucleases by pulsed field gel electrophoresis for analysis of genomic DNA. The latter is one of the most reliable methods for the correct identification of this yeast but only available in research laboratories or for epidemiological purposes [7].

Dominguez et al. [10], reported the identification of *K. ohmeri* by MALDI-TOF with an accuracy comparable to PCR but better than the one obtained through API20C. These isolates had been misidentified as *C. haemulonii* by the API20C method [10].

K. ohmeri has been described as causing fungemias, catheter associated infections, phlebitis [10], wound infections, peritonitis [11], endocarditis [12] as well as outbreaks in intensive care units [8] Table 2.

ALL: acute lymphoblastic leukemia, NEC: necrotizing enterocolitis, CVL: central venous line, TPN: total parenteral nutrition, AMB: amphotericin B, FCZ: fluconazole.

Risk factors reported in children are: prematurity, low birth

Table 2
Reported cases of fungemia due to *K. ohmeri* in children.

Country, year of report	Number of cases, Ref.	Age/gender	Risk factors	Treatment	Outcome
Houston, USA 2004	1 case Ref. [5]	14 yrs, M	ALL, chemotherapy, CVL	FCZ, removal of CVL	Survived
Turkey, 2005	2 cases Ref. [8]	8 mos-M 10 yrs-M	Encephalitis, ALL, chemotherapy, neutropenia, CVL	FCZ AMB	Died Survived
Qatar 2006	1 case, Ref. [13]	Neonate 13 days old	Pretérn 25 wks, 680 gr (quadruples), NEC	AMB+FCZ	Survived
South Corea 2007	3 cases, Ref. [7]	11y-M 12yrs- M 4 yrs- F	Burkitt's lymphoma, Neutropenia Tetralogy of Fallot,	FCZ 2 AMB + FCZ 1	2 and 3 died
South Corea 2007	1 case, Ref. [7]	Neonate	Prematurity, umbilical catheter	Removal of CVL, no antifungal treatment	Survived
USA 2007	1 case Ref. [4]	5 mos-M	Short gut Hepatic failure CVL	FCZ+ AMB Removal of CVL	Survived
India 2009	1 case Ref. [14]	Neonate-M	Prematurity, 1300 gr, antibiotics, Umbilical catheters	FCZ+ AMB	Died
Brazil 2009	1 case, Ref. [6]	3 yrs-F	Ascariasis, peritonitis, Antibiotics CVL	AMB-Liposomal	Survived
Kuwait 2011	1 case, Ref. [15]	Neonate-F	Preterm, 1280 gr	AMB	Survived
India 2013	38 cases, Ref. [3]	Neonates Young infants Median age 87 days	Prolonged hospital stay CVL, surgery Oro-traqueal intubation Prolonged antibiotic use	FCZ in 23/38 cases Caspofungin in 4/38 Removal of CVL's in all	19/38 (50%) died
China, 2013	6 cases Ref. [16]	Young infants, premature	Prolonged antibiotic courses Mechanical ventilation CVL	Caspofungin 5/6 FCZ 1/6 (relapse) Removal of CVL	100% survived
Colombia, 2015	Present case	Young infant-M	Antibiotics, CVL, TPN prolonged hospital stay	AMB	Survived

weight, prolonged ICU stay, use of medical devices, prosthetic valves, use of broad spectrum antibiotics, total parenteral nutrition, immunosuppression (leukemias, lymphomas) and neutropenia [17]. Therefore, *K. ohmeri* can be considered an opportunistic pathogen that can cause severe infections in patients with underlying conditions. To date, there is only one case reported of infection in a previously healthy child with no predisposing conditions except for encephalitis [8].

Other risk factors reported in adults are: diabetes, malignancies, intravenous drug use, cardiac prosthetic valves and chronic renal disorders [17].

No intrinsic resistance of *K. ohmeri* to antifungals has been reported to date. There have been several reports of fluconazole resistance, some reports of echinocandin resistance and only one report of an isolate with high MIC's to amphotericin B. Therefore, antifungal treatment should be adjusted according to susceptibility reports of the clinical isolates.

Treatment of infections caused by *K. ohmeri* is similar to fungemias due to *Candida* spp. and other yeasts. Removal of CVL's or other medical devices is mandatory, as well as, treatment with parenteral antifungals adjusted to fungal susceptibility reports. *K. ohmeri*, is frequently resistant to fluconazole, therefore, it should not be used for empirical therapy due to the risk of clinical failure [18]. Amphotericin B is the treatment of choice, with echinocandins as second line therapy. In cases with dose-dependent susceptibility to fluconazole, treatment may be successful using high doses of fluconazole.

Clinical and Laboratory Standards Institute (CLSI) has defined that fungal susceptibility break points for this yeast are the same as those for *C. albicans* isolates: Fluconazole MIC ≤ 2 $\mu\text{g/L}$ susceptible, 4 $\mu\text{g/mL}$ dose-dependent susceptibility, and ≥ 8 $\mu\text{g/L}$ resistant. For Amphotericin B, MIC ≤ 1 $\mu\text{g/mL}$ susceptible and > 1 $\mu\text{g/mL}$ resistant. For caspofungin $< = 0.25$ $\mu\text{g/mL}$ susceptible, 0.5 $\mu\text{g/mL}$ intermediate and $> = 1$ $\mu\text{g/mL}$ resistant, with no category for dose-dependent susceptibility.

In the study reported by Lee et al. [7], all isolates were susceptible to Amphotericin B, voriconazole, micafungin and caspofungin. Eventhough, susceptibility data to equinocandins is scarce, it seems that micafungin and anidulafungin are good treatment options in patients with isolates that are resistant to azoles and in whom treatment with amphotericin B is contraindicated [15]. There are reports of clinical failures with fluconazole, in which

case therapy has been continued with amphotericin B or caspofungin [14,19].

Chakrabarti et al. [3], describes the largest pediatric series to date from a hospital in North India. This series included 38 isolates of *K. ohmeri* of which 37 were susceptible to azoles with MIC's between 0.5 and 32 (according to break points available at that time), and only one resistant isolate with an MIC of 64 mg/mL. All the isolates were also susceptible to caspofungin with MIC's between 0.12 and 1 mg/mL. Interestingly, 86.8% of the isolates had high MIC's to amphotericin B (MIC 1 mg/mL), in contrast to most of the other cases reported in the literature to date.

4. Conclusion

Catheter-associated fungemias are an important cause of morbidity and mortality in neonates and critically ill children. *Kodamaea ohmeri* is a yeast that belongs to the species of *Candida guilliermondi* which is an infrequent cause of infections in children, but the mortality associated with these infections can be as high as 50%. High rates of resistance to azoles has been reported, therefore, empirical treatment with amphotericin B or echinocandins should be started and adjusted according to antifungal susceptibility tests. Removal of central venous catheters or medical devices must be considered in all cases.

Declaration of interest

The authors declare that they have no conflict of interest. The authors alone are responsible for the content and writing of the paper.

Ethical approval

This case report was aproval for Ethical Committee fo the Hospital.

Acknowledgements

We thank Pablo Tobon Uribe hospital and laboratory services that enabled this publication.

References

- [1] D.J. Weber, W.A. Rutala, Central line associated bloodstream infections: prevention and management, *Infect. Dis. Clin. North Am.* 25 (2011) 77–102.
- [2] A.I. Hidron, J.R. Edwards, J. Patela, T.C. Horana, D.M. Sievert, D.A. Pollock, et al., Antimicrobial-resistant pathogens associated with healthcare-associated infections, *Infect. Control Hosp. Epidemiol.* 29 (2008) 996–1011.
- [3] A. Chakrabarti, et al., Epidemiological study of a large cluster of fungaemia cases due to *Kodamaea ohmeri* in an Indian tertiary care centre, *Clin. Microbiol. Infect.* 20 (2014) O83–O89.
- [4] E.E. Ezeanolue, K. Piggott, *Pichia ohmeri* infection in a pediatric patient: a case report, *J. Invest. Med.* 55 (2007) S146.
- [5] X.Y. Han, J.J. Tarrand, E. Escudero, *Eur. J. Clin. Microbiol. Infect. Dis.* 23 (2004) 127–130.
- [6] J. Duque de Barros, et al., *Kodamaea (Pichia) ohmeri* fungemia in a pediatric patient admitted in a public hospital, *Med. Mycol.* 47 (2009) 775–779.
- [7] J.S. Lee, J.G. Shin, Mi-Na Kim, et al., *J. Clin. Microbiol.* (2007) 1005–1010.
- [8] F. Otag, N. Kuyucu, Z. Erturan, S. Sen, G. Emekdas, T. Sugita, An outbreak of *Pichia ohmeri* infection in the paediatric intensive care unit: case reports and review of the literature, *Mycoses* 48 (2005) 265–269.
- [9] C.P. Kurtzman, J.W. Fell, T. Boekhout, *The Yeasts: A taxonomic Study*, 5th edn., Elsevier, Amsterdam, 2011.
- [10] M. Dominguez Muro, F. de Araújo Motta, M. Burger, A.S. de Azevedo Melo, L. M. Dalla-Costa, Echinocandin resistance in two *Candida haemulonii* isolates from pediatric patients, *J. Clin. Microbiol.* 50 (11) (2012) 3783–3785.
- [11] N.A. Bokhary, I.B. Hussain, *Kodamaea (Pichia) ohmeri* peritonitis in a nine-year-old child in Saudi Arabia treated with Caspofungin, 2015, *J. Taibah Univ. Med. Sci.*, pp. 1–4.
- [12] Y. Xiao, et al., *Kodamaea ohmeri* as an emerging pathogen in Mainland China: 3 case reports and literature review, *Lab. Med. Spring Suppl.* (2013), e1–e8.
- [13] S.J. Taj-Aldeen, S.H. Doiphode, X.Y. Han, *Kodamaea (Pichia) ohmeri* fungaemia in a premature neonate, *J. Med. Microbiol.* 55 (2006) 237–239.
- [14] A. Poojary, G. Sapre, *Kodamaea ohmeri* Infection in a Neonate, *Indian Pediatr.* (2009) 46.
- [15] N.A. Sweih, et al., *Kodamaea ohmeri* as an emerging pathogen: a case report and review of the literature, *Med. Mycol.* 49 (2011) 766–770.
- [16] C.X. Liu, J.H. Yang, L. Dong, J.Y. Mai, L. Zhang, J.H. Zhu, Clinical features and homological analysis of *Pichia ohmeri*-caused hospital-acquired fungemia in premature infants, *Zhonghua Yi Xue Za Zhi* 93 (4) (2013) 285–288.
- [17] S.T. Shang, J.S. Lin, S.J. Ho, Y.S. Yang, F.Y. Chang, N.C. Wang, The emerging life-threatening opportunistic fungal pathogen *Kodamaea ohmeri*: optimal treatment and literature review, *J. Microbiol. Immunol. Infect.* 43 (3) (2010) 200–206.
- [18] Yang Bing-Heng, Peng Ming-Yieh, Hou Shu-Jin, Sun Jun-Ren, Lee Shih-Yi, Lu Jang-Jih, Fluconazole-resistant *Kodamaea ohmeri* fungemia associated with cellulitis: case report and review of the literature, *Int. J. Infect. Dis.* 13 (2009) e493–e497.
- [19] C.H. Chiu, Y.C. Wang, S.T. Shang, F.Y. Chang, *Kodamaea ohmeri* fungaemia successfully treated with caspofungin, *Int. J. Antimicrob. Agents* 35 (2010) 98–99.