



Contents lists available at ScienceDirect

## International Journal of Surgery Case Reports

journal homepage: [www.casereports.com](http://www.casereports.com)

## Importance of perioperative management for emergency carotid artery stenting within 24 h after intravenous thrombolysis for acute ischemic stroke: Case report



Akihiro Inoue (MD, PhD)<sup>a,\*</sup>, Kanehisa Kohno (MD, PhD)<sup>a</sup>, Shinya Fukumoto (MD, PhD)<sup>a</sup>, Saya Ozaki (MD)<sup>a</sup>, Satoko Ninomiya (MD)<sup>b</sup>, Hitomi Tomita (MD, PhD)<sup>b</sup>, Kenji Kamogawa (MD, PhD)<sup>b</sup>, Kensho Okamoto (MD)<sup>b</sup>, Haruhisa Ichikawa (MD, PhD)<sup>a</sup>, Shinji Onoue (MD, PhD)<sup>a</sup>, Hajime Miyazaki (MD)<sup>a</sup>, Bungo Okuda (MD, PhD)<sup>b</sup>, Shinji Iwata (MD, PhD)<sup>a</sup>

<sup>a</sup> Departments of Neurosurgery, Ehime Prefectural Central Hospital, Japan

<sup>b</sup> Departments of Neurology, Ehime Prefectural Central Hospital, Japan

## ARTICLE INFO

## Article history:

Received 20 April 2016

Received in revised form 23 July 2016

Accepted 23 July 2016

Available online 27 July 2016

## Keywords:

Recombinant tissue plasminogen activator

Penumbra System

Emergency carotid artery stenting

Hyperperfusion syndrome

Subacute

Thrombosis

Dexmedetomidine

## ABSTRACT

**INTRODUCTION:** We report a patient treated successfully via endovascular surgery within 24 h after intravenous thrombolysis using recombinant tissue plasminogen activator for acute cervical internal carotid artery occlusion.

**PRESENTATION OF CASE:** A 68-year-old man was admitted to our hospital. Neurological examination revealed severe left-sided motor weakness. Magnetic resonance imaging showed no cerebral infarction, but magnetic resonance angiography revealed complete occlusion of the right internal carotid artery. Systemic intravenous injection of recombinant tissue plasminogen activator was performed within 4 h after the onset. But, magnetic resonance angiography still revealed complete occlusion. Revascularization of the right cervical internal carotid artery was performed via endovascular surgery. The occluded artery was successfully recanalized using the Penumbra System<sup>®</sup> and stent placement at the origin of the internal carotid artery. Immediately after surgery, dual antiplatelet therapy (aspirin and clopidogrel) was initiated, and then cilostazol was added on the following day. Carotid ultrasonography and three-dimensional computed tomographic angiography at 14 days revealed no further obstruction to flow.

**DISCUSSION:** When trying to perform emergency carotid artery stenting within 24 h after intravenous recombinant tissue plasminogen activator administration, several issues require attention, such as the decisions regarding the type of stent and embolic protection device, the selection of antiplatelet therapy and the methods of preventing hyperperfusion syndrome.

**CONCLUSION:** Emergency carotid artery stenting for the acute internal carotid artery occlusion may be considered a safe procedure in preventing early stroke recurrence in selected patients.

© 2016 The Authors. Published by Elsevier Ltd on behalf of IJS Publishing Group Ltd. This is an open access article under the CC BY-NC-ND license (<http://creativecommons.org/licenses/by-nc-nd/4.0/>).

**Abbreviations:** IV, intravenous; rt-PA, recombinant tissue plasminogen activator; ICA, internal carotid artery; MCA, middle cerebral artery; HPS, hyperperfusion syndrome; CAS, carotid artery stenting; MRI, magnetic resonance imaging; MRA, magnetic resonance angiography; CCA, common carotid artery; PTA, percutaneous transluminal angioplasty; TICl, thrombolysis in cerebral infarction; SPECT, single photon emission tomography; EPD, embolic protection device.

\* Corresponding author at: Departments of Neurosurgery, Ehime Prefectural Central Hospital, 83 Kasugamachi, Matsuyama, Ehime Prefecture 790-0024, Japan.

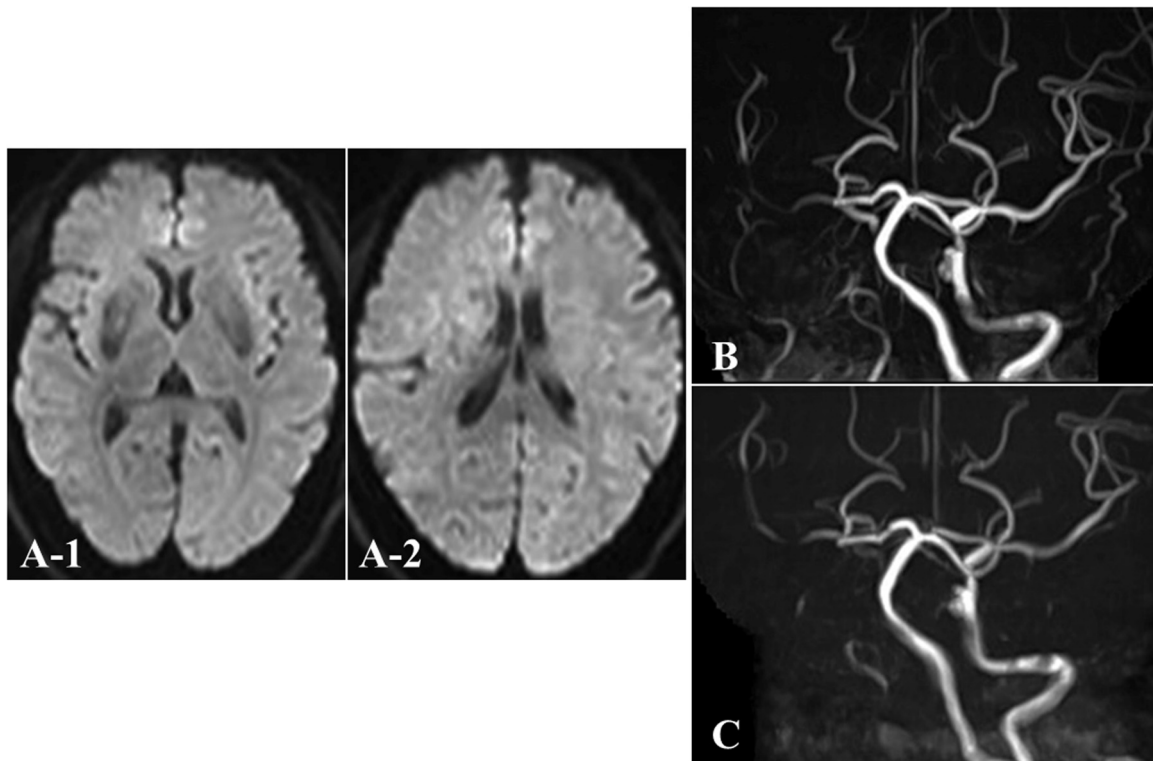
E-mail address: [iakihiro3@gmail.com](mailto:iakihiro3@gmail.com) (A. Inoue).

### 1. Introduction

Generally, in patients with acute ischemic strokes, intravenous (IV) thrombolysis with recombinant tissue plasminogen activator (rt-PA) is employed to recanalize thrombosed intracranial vessels (such as the internal carotid artery (ICA) and the middle cerebral artery (MCA) and its branches) within 4.5 h [1–3]. In addition, various reports have been published that a combination of IV thrombolysis and early carotid revascularization via endovascular technique might be a more effective secondary stroke prevention strategy. On the other hand, during the first 24 h after IV rt-PA administration, the risk of intracranial hemorrhage associated with early reperfusion might be increased because of hyperperfusion

<http://dx.doi.org/10.1016/j.ijscr.2016.07.027>

2210-2612/© 2016 The Authors. Published by Elsevier Ltd on behalf of IJS Publishing Group Ltd. This is an open access article under the CC BY-NC-ND license (<http://creativecommons.org/licenses/by-nc-nd/4.0/>).



**Fig. 1.** Magnetic resonance imaging (MRI) and MR angiography (MRA) findings. (A, B) MRI/diffusion-weighted imaging (DWI) at the time of initial presentation shows no acute cerebral infarction, but MRA reveals complete occlusion of the right internal carotid artery (ICA). (C) After intravenous injection of recombinant tissue plasminogen activator (rt-PA), cervical MRA demonstrates that the right ICA is still occluded.

syndrome (HPS) and the use of anticoagulant drugs or antiplatelet agents [3–7]. Here, we present a case of acute ICA occlusion treated successfully by use of the Penumbra System<sup>®</sup> and carotid artery stenting (CAS) within 24 h after IV thrombolysis using rt-PA.

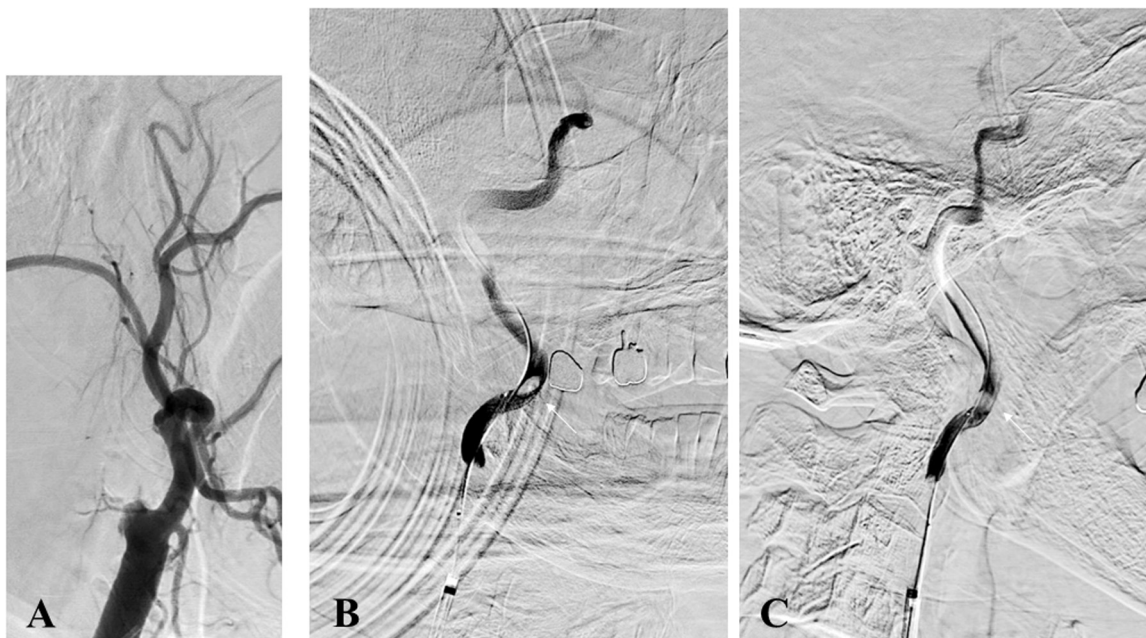
## 2. Case report

A 68-year-old man with a history of hypertension, hyperlipidemia and diabetes mellitus was admitted to our hospital. Neurological examination on admission revealed disturbance of consciousness and severe left-sided motor weakness (16 on the National Institutes of Health Stroke Scale). Blood biochemistry findings revealed no evidence of inflammation or coagulation system abnormalities. Electrocardiography indicated a sinus rhythm at 70 beats/min. Diffusion-weighted magnetic resonance imaging (MRI) showed no acute cerebral infarction (Fig. 1A), but magnetic resonance angiography (MRA) revealed occlusion of the right ICA (Fig. 1B). We made a diagnosis of acute cerebral ischemia, then a systemic IV injection of rt-PA was performed 4 h after onset. However, neurological symptoms did not improve for 1 h. In addition, repeated MRA (Fig. 1C) and cerebral angiography still revealed complete occlusion of the right cervical ICA at its origin (Fig. 2A). As collateral blood flow from the contralateral anterior and posterior circulation was poor, revascularization of the right cervical ICA was performed using an endovascular technique.

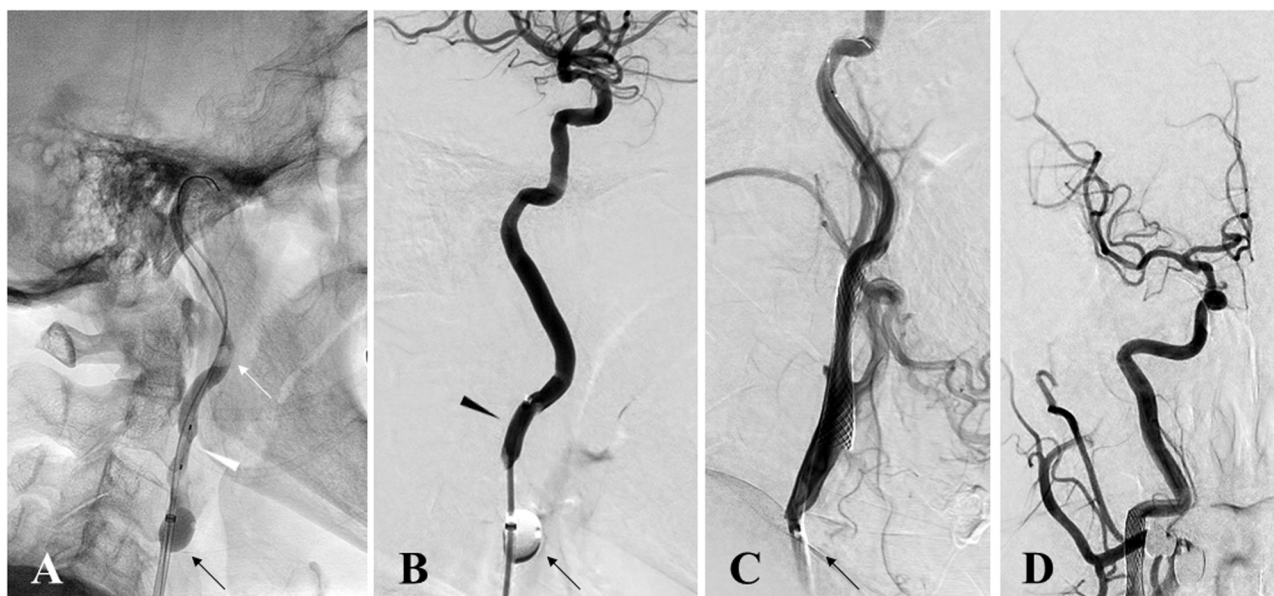
We performed all procedures under local anesthesia. An OPTIMO balloon-tipped guiding catheter (Tokai Medical Products, Kasugai, Japan) was inserted into the right femoral artery and advanced until the tip reached the right common carotid artery (CCA). After blockage of the proximal blood flow in the right CCA, an Excelsior SL-10<sup>®</sup> Microcatheter (Stryker Neurovascular, Fremont, CA, USA) was inserted to the right ICA segment distal to the occlusion area. Imaging study performed from the

Excelsior SL-10<sup>®</sup> Microcatheter demonstrated obvious floating clot in the cervical right ICA (Fig. 2B and C). Transluminal balloon angioplasty was performed with a 3.0-mm Gateway<sup>®</sup> Monorail<sup>™</sup> percutaneous transluminal angioplasty (PTA) Balloon Catheter (Stryker Neurovascular) for the occluded area within the ICA (Fig. 3A) and a Penumbra aspiration catheter 5MAX<sup>™</sup> ACE (Penumbra, Alameda, CA, USA) was passed distal to the position. Then, we performed a direct aspiration of the floating clot using this Penumbra aspiration catheter (Fig. 3B). After recanalization of the right ICA, a GuardWire<sup>®</sup> Temporary Occlusion & Aspiration System (Medtronic, Minneapolis, MN, USA) was passed through the stenotic portion into the distal right ICA. Transluminal balloon angioplasty was performed with a 3.5-mm Sterling PTA balloon catheter (Boston Scientific, Natick, MA, USA). Next, a 10 × 24-mm Carotid Wallstent Monorail<sup>®</sup> (Boston Scientific) was deployed (Fig. 3C), and post-dilatation was performed using a 4.5-mm Sterling PTA balloon catheter (Boston Scientific). Subsequent angiography confirmed successful recanalization of the right ICA (thrombolysis in cerebral infarction (TICI) grade 3) at 7 h post-onset (Fig. 3D).

Immediately after these procedures, we started treatment with dual-agent antiplatelet therapy (aspirin 100 mg/day and clopidogrel 75 mg/day) and cilostazol 200 mg/day was added on the following day. The patient was restless with neurological abnormalities, and <sup>123</sup>I IMP-single photon emission tomography (SPECT) (Fig. 4A) and INVOS-3100 revealed hyperperfusion in the territory of the right ICA. Strict control of blood pressure under dexmedetomidine anesthesia allowed effective prevention of HPS. Carotid ultrasonography and three-dimensional computed tomographic angiography at 14 days (Fig. 4B and C) revealed no further obstruction to flow, and the patient was discharged 3 weeks after surgery with mild left motor weakness.



**Fig. 2.** (A) Preoperative right common carotid angiography (CAG) revealing complete occlusion of the right internal carotid artery (ICA) at the origin; (B, C) Right internal carotid angiography (ICAG) from Excelsior SL-10® demonstrating obvious floating clot (white arrow) in the cervical ICA (B: anteroposterior view; C: lateral view).



**Fig. 3.** Intraoperative angiography; (A) OPTIMO (black arrow) is placed at the right common carotid artery (CCA). Balloons placed in the CCA are inflated; then a transluminal balloon angioplasty was performed with a 3.0-mm Gateway™ PTA balloon catheter (white arrowhead) for the occluded area of the internal carotid artery (ICA). (B) Penumbra aspiration catheter, 5 MAX™ ACE (black arrowhead), is passed distal to the position, allowing suctioning of the floating clot (white arrow) using this aspiration system. (C) A carotid wall stent was deployed and revascularization was recognized. (D) Postoperative angiography confirmed successful recanalization of the right ICA (thrombolysis in cerebral infarction (TICI) grade 3).

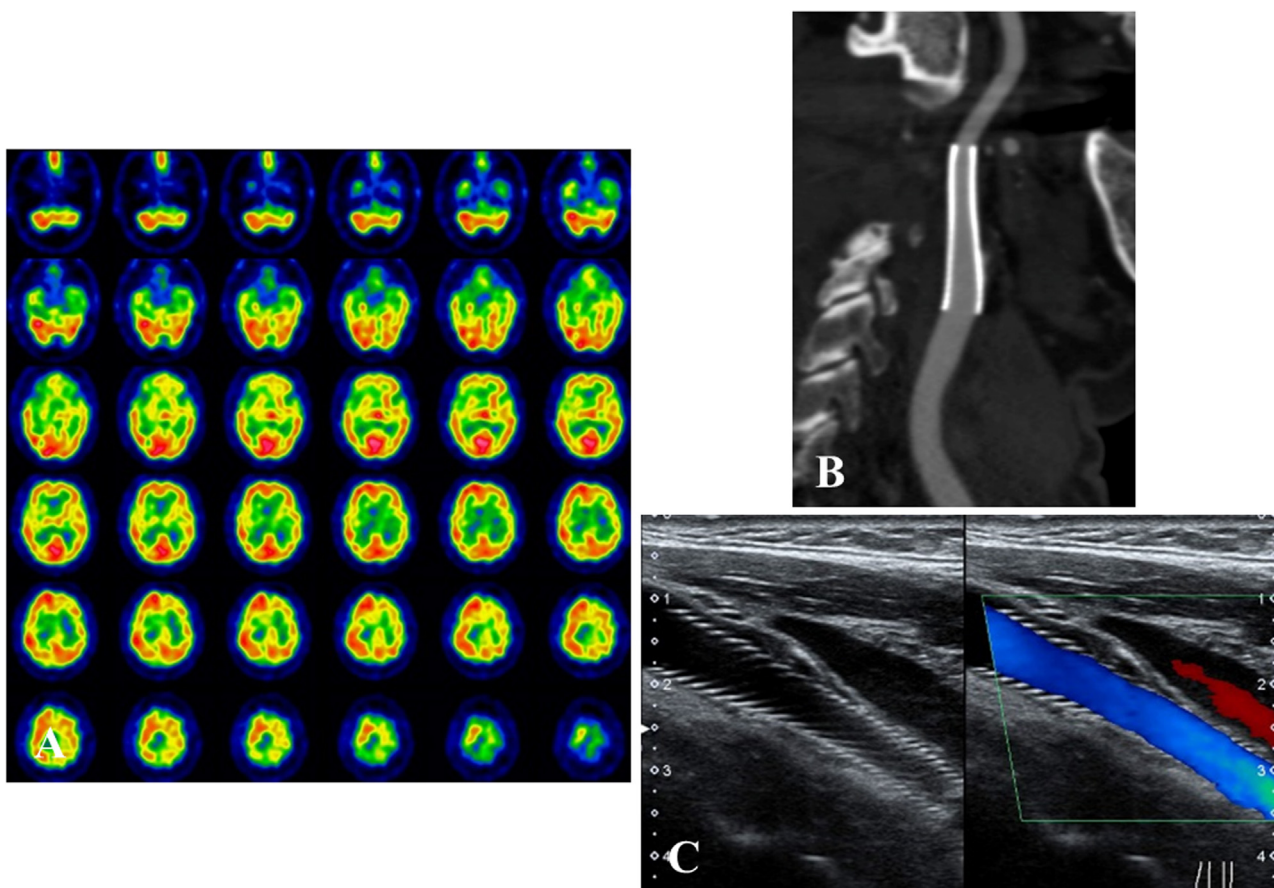
### 3. Discussion

In patients with acute cerebral infarction due to severe stenosis or occlusion of the ICA, IV rt-PA alone has been reported to be less effective, and its morbidity and mortality are higher than conventional therapy [8,9]. In addition, acute ischemic stroke associated with cervical carotid occlusion at the origin is relatively rare, so its management has not been studied extensively, and therapeutic approaches, in particular how to choose of antiplatelet agents within 24 h after IV rt-PA, remain unclear. A combination of IV thrombolysis using rt-PA and early carotid revascularization

by endovascular surgery might result in more effective secondary stroke prevention. Several publications and studies have proposed that recanalization via aggressive endovascular treatment of acute cervical ICA occlusion at the origin may be successful with high rates of favorable outcomes [7,10]. However, at least in the first 24 h after IV rt-PA administration, the risk of intracranial hemorrhage associated with early reperfusion of ischemic brain tissue might be increased [11,12].

When trying to perform emergency CAS within 24 h after IV rt-PA administration, several issues require attention, such as the decisions regarding the type of stent and embolic protection device





**Fig. 4.** Single photon emission computed tomography (SPECT), three-dimensional computed tomographic angiography (3D-CTA) and carotid ultrasonography. (A) PAO-SPECT (1 day after endovascular surgery) reveals increased cerebral blood flow in the right cerebral hemisphere. (B, C) 3D-CTA (B) and carotid ultrasonography (C) shows sufficient patency 14 days postoperatively.

(EPD), the selection of antiplatelet therapy and the methods of preventing HPS. At first, with respect to emergency CAS, the selection of type of stent and EPD is very important [3,6]. In the present case, although we were unable to evaluate the nature of the carotid plaques because of the need for emergency treatment, we strongly suspected that the plaque was vulnerable because of the sudden onset of symptoms. Because an open-cell stent often elicits embolic complications due to plaque protrusion, we selected a self-expandable closed-cell stent, and we were careful to avoid over-dilating the lesion. In addition, we also blocked the blood flow in the proximal CCA only when doing PTA and advancing the balloon-design EPD through the stenotic lesion to prevent scattering of the carotid plaque.

The second important point is the choice of perioperative antiplatelet agents. Antithrombotic therapy becomes required after the CAS enforcement. Generally, the double antiplatelet regimen is highly recommended before and after CAS in order to prevent subacute stent occlusion [3,6]. However, it is a generally accepted principle that the administration of any anticoagulant drugs within 24 h after IV rt-PA therapy is contraindicated because of the risk of bleeding complications [2]. Furthermore, in the case of an emergency CAS procedure, the administration of several antiplatelet agents is particularly dangerous from the perspective of HPS [11–14]. On the other hand, Fabrizio et al. and Inoue et al. demonstrated dual antiplatelet therapy, for example, the combination of aspirin (100 mg/day) and clopidogrel (75 mg/day) begun during the emergency CAS procedure within 24 h after IV rt-PA therapy over the 6 weeks after stent placement, resulting in good outcomes without serious hemorrhagic complications [15,16]. Therefore, in our

case, we administered aspirin and clopidogrel in the doses mentioned above for the prevention of subacute thrombosis, and we also obtained a good result.

Finally, the risk of intracranial hemorrhage due to hyperperfusion is potentially high in patients with acute stroke receiving emergency CAS because anticoagulation and antiplatelet medications must be administered during or after the procedure [16,17]. However, the development of HPS may be avoided by strict blood pressure control [16–18]. Dexmedetomidine is a central alpha<sub>2</sub> adrenoceptor agonist. Recently, this drug was shown to be a safe and acceptable sedative agent for patients requiring sedation after brain surgery including preventing hyperperfusion syndrome after carotid endarterectomy [16,18]. In fact, although anticoagulation and antiplatelet therapy were added immediately after the CAS procedure in our case, careful control of blood pressure under dexmedetomidine anesthesia enabled effective management of the resulting HPS and there was no intracranial hemorrhage.

This present case suggests that early treatment with CAS for acute ischemic stroke due to ICA occlusion at the origin may be considered a safe and feasible alternative modality to carotid endarterectomy in selected patients at high risk of stroke recurrence, even if within 24 h after IV rt-PA administration.

#### 4. Conclusion

We have described a case of cervical ICA occlusion treated successfully with the Penumbra System<sup>®</sup> and emergency CAS within 24 h after injection of rt-PA thrombolysis. If we can make the appropriate perioperative management, emergency CAS for the acute

ICA occlusion at the origin may be considered a safe procedure in preventing early stroke recurrence in selected patients.

### Conflict of interest

None of the authors have any commercial or financial involvement in connection with this study that represents or appears to represent any conflicts of interest.

### Funding

This research received no specific grant from any funding agency in the public, commercial or not-for-profit sectors.

### Ethical approval

None.

### Consent

Written informed consent was obtained from the patient's family for publication of this case report and any accompanying images. A copy of the written consent is available for review by Editor-in-Chief of this journal on request.

### Author contributions

All authors in this manuscript contributed to the interpretation of data, and drafting and writing of this manuscript. AI is first and corresponding author of this paper. He and SF performed the operation, conceived and designed the study and drafted the manuscript. AI, SF, SO, SN, HT, KK, KO, HI, SO, HM and SI were engaged in patient's care in his hospital course including surgery under the supervision of KK and BO. All the authors read and approved the final manuscript.

### Guarantor

Kanehisa Kohno, MD, PhD.

### Acknowledgements

The authors would like to express their gratitude to Isao Kawamata, Atsushi Kyoshita, Shinichi Utsunomiya, Shotaro Kubo and Yosuke Orikiawa, Department of Neurological Center, Ehime Prefectural Central Hospital, Japan for their helpful information regarding radiological image acquisition.

### References

- [1] G.J. Del Zoppo, J.L. Saver, E.C. Jauch, H.P. Adams Jr., American Heart Association Stroke Council, Expansion of the time window for treatment of acute ischemic stroke with intravenous tissue plasminogen activator: a science advisory from the American Heart Association/American Stroke Association, *Stroke* 40 (2009) 2945–2948.
- [2] W. Hacke, M. Kaste, E. Bluhmki, M. Brozman, A. Dávalos, D. Guidetti, et al., Thrombolysis with alteplase 3 to 4.5 hours after acute ischemic stroke, *N. Engl. J. Med.* 359 (2008) 1317–1329.
- [3] H.A. Bazan, N. Zea, B. Jennings, T.A. Smith, G. Vidal, W.C. Sternbergh 3rd, Urgent carotid intervention is safe after thrombolysis for minor to moderate acute ischemic stroke, *J. Vasc. Surg.* 62 (2015) 1529–1538.
- [4] L.R. Wechsler, Intravenous thrombolytic therapy for acute ischemic stroke, *N. Engl. J. Med.* 364 (2011) 2138–2146.
- [5] A.R. Naylor, Thrombolysis and expedited carotid revascularization, *J. Cardiovasc. Surg. (Torino)* 56 (2015) 159–164.
- [6] L. Koraen-Smith, T. Troëng, M. Björck, B. Kragsterman, C.M. Wahlgren, Swedish Vascular Registry and the Riks-Stroke Collaboration, Urgent carotid surgery and stenting may be safe after systemic thrombolysis for stroke, *Stroke* 45 (2014) 776–780.
- [7] L. Ratanaprasatporn, J.A. Grossberg, H.S. Spader, M.V. Jayaraman, Endovascular treatment of acute carotid occlusion, *Clin. Neurol. Neurosurg.* 115 (2013) 2521–2523.
- [8] J.H. Rha, J.L. Saver, The impact of recanalization on ischemic stroke outcome: a meta-analysis, *Stroke* 38 (2007) 967–973.
- [9] K. Kimura, Y. Iguchi, K. Shibazaki, J. Aoki, J. Uemura, Early recanalization rate of major occluded brain arteries after intravenous tissue plasminogen activator therapy using serial magnetic resonance angiography studies, *Eur. Neurol.* 62 (2009) 287–292.
- [10] R. Rahme, T.A. Abruzzo, A.J. Ringer, Acute ischemic stroke in the setting of cervical carotid occlusion: a proposed management strategy, *World Neurosurg.* 76 (2011) 60–65.
- [11] M. Ning, K.L. Furie, W.J. Koroshetz, H. Lee, M. Barron, M. Lederer, et al., Association between tPA therapy and raised early matrix metalloproteinase-9 in acute stroke, *Neurology* 66 (2006) 1550–1555.
- [12] Y.F. Wang, S.E. Tsirka, S. Strickland, P.E. Stieg, S.G. Soriano, S.A. Lipton, Tissue plasminogen activator (tPA) increases neuronal damage after focal cerebral ischemia in wild-type and tPA-deficient mice, *Nat. Med.* 4 (1998) 228–231.
- [13] K. Imai, T. Mori, H. Izumoto, M. Watanabe, K. Majima, Emergency carotid artery stent placement in patients with acute ischemic stroke, *AJNR Am. J. Neuroradiol.* 26 (2005) 1249–1258.
- [14] O.O. Zaidat, M.J. Alexander, J.I. Suarez, R.W. Tarr, W.R. Selman, D.S. Enterline, et al., Early carotid artery stenting and angioplasty in patients with acute ischemic stroke, *Neurosurgery* 55 (2004) 1237–1242.
- [15] F. Sallustio, G. Koch, A. Rocco, C. Rossi, E. Pampana, R. Gandini, et al., Safety of early carotid artery stenting after systemic thrombolysis: a single center experience, *Stroke Res. Treat.* 10 (2012) 1155–1159.
- [16] A. Inoue, M. Tagawa, M. Nishikawa, Y. Kumon, H. Watanabe, T. Ohnishi, Emergency carotid artery stenting within 24 hours after intravenous thrombolysis for acute ischemic stroke: a case report, *No Shinkei Geka* 41 (2013) 609–617.
- [17] P. Papanagiotou, C. Roth, S. Walter, S. Behnke, I.Q. Grunwald, J. Viera, et al., Carotid artery stenting in acute stroke, *J. Am. Coll. Cardiol.* 58 (2011) 2363–2369.
- [18] S. Suehiro, K. Kohno, A. Inoue, D. Yamashita, N. Tei, T. Matsushige, et al., Two cases of cervical carotid artery stenosis with high risk post-operative hyperperfusion treated with dexmedetomidine after carotid endarterectomy, *No Shinkei Geka* 38 (2010) 731–738.

### Open Access

This article is published Open Access at [sciedirect.com](http://sciedirect.com). It is distributed under the [IJSCR Supplemental terms and conditions](#), which permits unrestricted non commercial use, distribution, and reproduction in any medium, provided the original authors and source are credited.