

Immunohistochemical detection of inhibitor of DNA binding 3 mutational variants in mature aggressive B-cell lymphoma

In addition to the hallmark translocations involving the *MYC* oncogene and immunoglobulin loci,¹ Burkitt lymphomas (BL) frequently carry mutations in the *inhibitor of DNA binding 3 (ID3)* gene.^{2,3} Genetic aberrations of *ID3* in BL comprise a spectrum of mono- and bi-allelic structural and point mutations.³ *ID3* acts as negative transcriptional regulator by sequestering transcription factors with basic helix-loop-helix motifs. Mutated *ID3* attenuates this regulatory interaction.^{4,5} *ID3* and its interaction partner, TCF3, are involved in controlling cell cycle progression and survival pathways through tonic B-cell signaling.^{6,7}

ID3 mutations occur in 34-68% of BL but are rare in diffuse large B-cell lymphomas (DLBCL).^{2,3,7} Interestingly, the incidence of *ID3* mutations was reported to be higher in B-cell lymphomas, unclassifiable, with features intermediate between DLBCL and BL,⁸ than in DLBCL. However, in the quoted study a molecular diagnosis was not available and the diagnosis of an "intermediate" lymphoma was based on histopathological features only.^{8,9}

Mutation-specific immunohistochemistry is a valuable diagnostic tool,¹⁰ and we used it to test six anti-*ID3* antibodies for their ability to detect *ID3* mutational variants in molecularly defined BL (mBL), "intermediate" lymphomas and non-mBL lymphomas¹¹ (Online Supplementary Table S1).

First, we tested all six antibodies on formalin-fixed and paraffin-embedded tonsil tissue using immunohistochemistry. *ID3* has been reported to be strongly expressed in the dark zone and less intensively in the light zone of germinal centers.¹² The expected staining pattern was only observed with clone 17-3 (BioCheck Inc., Foster City, USA) (Figure 1), but not for the other antibodies tested (Online Supplementary Figure S1). To determine whether clone 17-3 shows a mutation-specific staining pattern, selected wild-type (wt) and point-mutated *ID3* cell lines and lymphoma specimens were tested by immunohistochemistry (Online Supplementary Figure S1) and by western blotting (Online Supplementary Figure S2). As expected, clone 17-3 showed no reactivity in BL cell lines or mBL biopsies with homozygous loss of *ID3* (Figure 1; Online Supplementary Figures S1 and S2; Online Supplementary Table S2). The other five antibodies positively stained cell lines and/or biopsies by immunohistochemistry despite a homozygous deletion of the *ID3* locus and were not, therefore, used further (Online Supplementary Figure S1; Online Supplementary Table S2).

The Online Supplementary Data contains more detailed information on the materials and methods, cell lines and cases.

Mutation-sensitive *ID3* immunohistochemistry using clone 17-3 was performed on 89 formalin-fixed, paraffin-embedded lymphoma biopsies. The conventionally assigned diagnoses based on histomorphological and immunophenotypic features according to the current World Health Organization classification⁸ were as follows: BL (23/89), Burkitt leukemia (1/89), atypical BL (15/89), DLBCL (27/89), high-grade B-cell non-Hodgkin lymphoma (3/89), B-cell lymphomas, unclassifiable (2/89), follicular lymphoma grade 1-3a (10/89), transformed follicular lymphoma grade 3a/b/DLBCL (4/89), primary mediastinal B-cell lymphoma (2/89), primary central nervous system DLBCL (1/89), and post-transplant lymphoproliferative disease with features of DLBCL (1/89) (Online Supplementary Table S3). All cases were molecularly studied in either the MMML (n=41) or ICGC MMML-Seq (n=43) projects or

both (n=5). Thus, the molecular classification based on gene expression analysis as well as the *ID3* mutation status based on whole genome and/or Sanger sequencing were available.^{3,11,13,14} In detail, according to a defined gene expression signature, the so-called mBL signature index, which reflects the probability that a case resembles a BL, all cases were assigned their specific molecular diagnosis. In accordance with Hummel *et al.*¹¹ cases with a mBL signature index score higher than 0.95 were classified as mBL (38/89), cases with an intermediate mBL signature index score between 0.05 and 0.95 as "intermediate" lymphomas (14/89), and cases with a mBL signature index score lower than 0.05 as non-mBL (36/89); one nodal manifestation of BL leukemia was not assigned a molecular diagnosis (Online Supplementary Table S3; Online Supplementary Methods).

ID3 expression in mBL showed a biphasic pattern. Almost all BL displayed either high *ID3* expression scores (>50% positive lymphoma cells) or no expression (Figure 1h and Online Supplementary Table S3). mBL with wt, monoallelic point or monoallelic structural *ID3* mutations (deletions, insertions or frameshifts) displayed *ID3* immunoreactivity by immunohistochemistry (27/27, 100%; interpretable staining failed in 2 mBL). All mBL in our series with lack of *ID3* immunoreactivity (10/10, 100%) harbored complex biallelic structural *ID3* mutations (e.g. biallelic frameshifts). Sequence analyses predicted a loss of the C-terminal *ID3* epitope of clone 17-3 (Figure 1; Online Supplementary Table S3).

We detected a broad spectrum of *ID3* immunoreactivity in non-mBL, ranging from no expression to high expression (Figure 1h and Online Supplementary Table S3). However, a high level of *ID3* expression (>50% positive lymphoma cells) was rare in non-mBL (6/36, 17%). *ID3* expression in non-mBL seems to be independent of the mutational status, since none of the *ID3*-negative non-mBL harbored biallelic structural *ID3* variants (0/8, 0%). Monoallelic mutations of *ID3* were detected in only two cases of non-mBL (2/36, 6%) and neither of these lymphomas showed *ID3* immunoreactivity (Online Supplementary Table S3).

Like non-mBL, molecularly defined "intermediate" lymphomas showed a broad spectrum of *ID3* expression (Figure 1 and Online Supplementary Table S3). High *ID3* immunoreactivity (>50% positive lymphoma cells) was as frequent as in mBL (9/14, 64% versus 27/37, 73%, respectively) and more frequent than in non-mBL (6/36, 17%). Complete lack of *ID3* immunoreactivity was observed in only 2/14 "intermediate" lymphomas which both harbored *ID3* structural mutations. One was a pediatric case with a biallelic *ID3* frameshift insertion and a splice site alteration. Unfortunately, we were not able to assess whether the lesion is biallelic in the second case (Online Supplementary Table S3). Interestingly, none of the four double- or triple-hit lymphomas with *MYC* and either *BCL2* and/or *BCL6* translocations in our series had mutated *ID3* nor lacked *ID3* immunoreactivity (Online Supplementary Table S3).

Here we describe an anti-*ID3* antibody which was the only one of six antibodies tested with high specificity for *ID3* in immunohistochemistry and western blots. Clone 17-3 showed highly specific immunoreactivity for wt and point-mutated *ID3* in mature aggressive B-cell lymphomas. We found that *ID3* is highly expressed in mBL and the "intermediate" group of lymphomas, whereas it is not expressed, or only moderately expressed in non-mBL. Furthermore, both mBL and "intermediate" lymphomas are characterized by a high frequency of *ID3* mutations whereas non-mBL are not. Moreover, mBL and "intermediate" lymphomas,¹¹ mainly resembling BL, atypical BL and B-cell lymphomas, unclassifiable,⁸ show a complete lack of *ID3* staining only when biallelic structural aberrations causing a

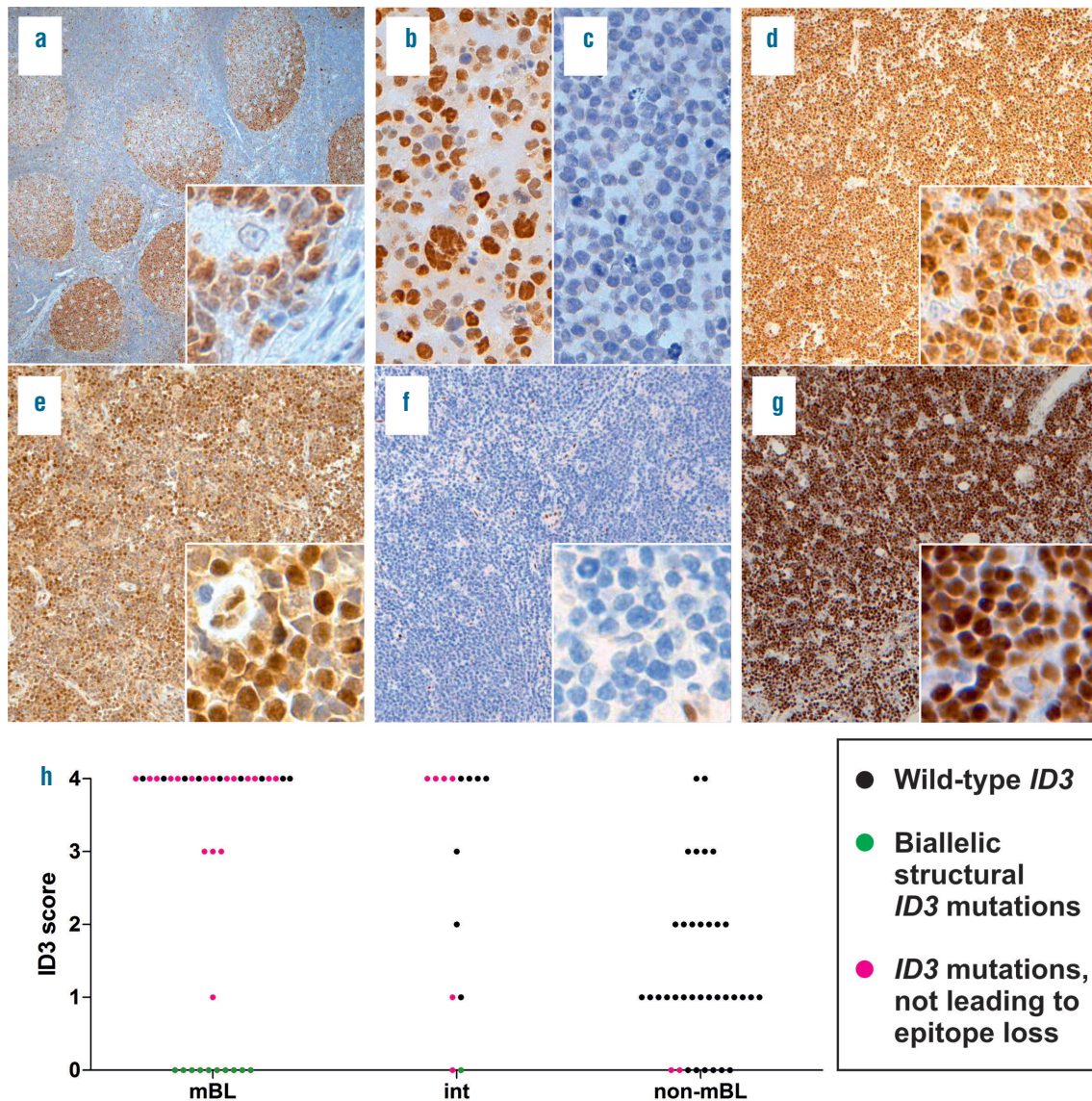


Figure 1. Immunohistochemistry for ID3 and ID3 mutation distribution among mBL, “intermediate” lymphomas, and non-mBL. (a-g). ID3 immunohistochemistry of formalin-fixed, paraffin-embedded sections of tonsil, BL and BL cell lines; original magnification of tonsil 50x, inlet 400x, cell lines 400x, cases 100x, inlets 400x. (a-g) were stained with clone 17-3. (a) Reactive tonsil, pronounced ID3 distribution in the dark zone of germinal centers; (b) BL cell line EB-1, wt ID3; (c) BL cell line BL-41, biallelic stop gain, loss of ID3 amino acids 69-109; (d) case 34, mBL, wt ID3; (e) case 17; mBL, two ID3 point mutations; (f) case 2, mBL, homozygous loss of ID3 C-terminal domains; (g) case 15, mBL, stop gain and splice site mutation, the latter without structural consequences; (h) Scatter plot of the ID3 immunohistochemical scoring based on percentages of ID3-positive tumor cells: 0=0%, 1=1-25%, 2=26-50%, 3=51-75%, and 4=76-100%. Each point is a case and the color codes illustrate the mutational status of ID3. Interpretable ID3 staining failed in two cases which are not included in the plot. BL: Burkitt lymphoma; int: intermediate; mBL: molecular Burkitt lymphoma; non-mBL: non-molecular Burkitt lymphoma; wt: wild-type.

loss of C-terminal domains of ID3 are present. In contrast, none of the non-mBL cases in this study, mainly resembling DLBCL, harbored biallelic structural ID3 mutations. ID3-negative non-mBL had either wt ID3 or harbored monoallelic ID3 locus deletions, so the lack of ID3 expression was not associated with a genetic loss of ID3 domains but probably due to transcriptional regulation. Thus, lack of ID3 staining in a mature aggressive B-cell lymphoma with features of BL can be regarded as an indicator of biallelic loss of ID3. Since lack of ID3 immunoreactivity also occurs in a small subset of non-mBL with wt or monoallelic structural ID3 aberrations, staining for ID3 currently seems to be of limited value in the differential diagnosis of lymphoma. A

potential use in combination with other biomarkers needs to be determined in future studies.

Monika Szczepanowski,^{1*} Neus Masqué-Soler,¹ Matthias Schlesner,² Andrea Haake,³ Julia Richter,³ Rabea Wagener,³ Birgit Burkhardt,⁴ Markus Kreuz,⁵ Reiner Siebert,³ ICGC MMML-Seq Consortium,[#] and Wolfram Klapper^{1*}

¹Institute of Pathology, Hematopathology Section and Lymph Node Registry, University Hospital Schleswig-Holstein Campus Kiel, Christian-Albrechts University Kiel; ²Division of Theoretical Bioinformatics, Deutsches Krebsforschungszentrum Heidelberg (DKFZ); ³Institute of Human Genetics, University Hospital Schleswig-

Holstein, Campus Kiel, Christian-Albrechts University Kiel; ⁴NHL-BFM Study Center and Department of Pediatric Hematology and Oncology, University Children's Hospital, Münster; and ⁵Institute for Medical Informatics, Statistics and Epidemiology, University of Leipzig, Germany

*There is a full list of all authors and affiliations in the Online Supplementary Data.

Funding: this research was supported by Deutsche Krebshilfe in the framework of the joint project Molecular Mechanisms in Malignant Lymphoma (MMML, 70-3473-Tr3) and the German Ministry for Education and Science (BMBF) in the framework of the International Cancer Genome Consortium MMML by Sequencing (ICGC MMML-Seq, 01KU1002A-J). RS and WK were supported by the BMBF within the framework of e:Bio Molecular Mechanisms in Malignant Lymphoma with MYC Deregulation project (MMML-MYC-SYS, 0316166B) and the BMBF within the framework of e:Med Molecular Mechanisms in Malignant Lymphoma – Demonstrator of the Personalized Medicine (MMML Demonstrator, 031A428D). RS and WK were also supported by the KinderKrebsInitiative (KKI), Buchholz, Holm-Seppensen e.V. RW is a recipient of a Christoph-Schubert-Award of the KKI, Buchholz, Holm-Seppensen. JR is supported by the Dr. Werner Jackstädt Foundation in the framework of a Junior Excellence Research Group (S134 - 10.100).

Acknowledgments: the authors gratefully acknowledge O. Batic, C. Botz-von Drathen, T. Engel, C. Becher, and U. Schnaidt for their excellent technical assistance.

Correspondence: m.szczepanowski@path.uni-kiel.de/wklapper@path.uni-kiel.de
doi:10.3324/haematol.2015.138701

Key words: molecular Burkitt lymphoma, diffuse large B-cell lymphoma, anti-ID3 antibody, mutation, immunohistochemistry

Information on authorship, contributions, and financial & other disclosures was provided by the authors and is available with the online version of this article at www.haematologica.org.

References

1. Dalla-Favera R, Bregni M, Erikson J, Patterson D, Gallo RC, Croce CM. Human c-myc onc gene is located on the region of chromosome 8 that is translocated in Burkitt lymphoma cells. *Proc Natl Acad Sci USA*. 1982;79(24):7824-7827.
2. Schmitz R, Young RM, Ceribelli M, et al. Burkitt lymphoma pathogenesis and therapeutic targets from structural and functional genomics. *Nature*. 2012;490(7418):116-120.
3. Richter J, Schlesner M, Hoffmann S, et al. Recurrent mutation of the ID3 gene in Burkitt lymphoma identified by integrated genome, exome and transcriptome sequencing. *Nat Genet*. 2012;44(12):1316-1320.
4. Murre C, McCaw PS, Vaessin H, et al. Interactions between heterologous helix-loop-helix proteins generate complexes that bind specifically to a common DNA sequence. *Cell*. 1989;58(3):537-544.
5. Benezra R, Davis RL, Lassar A, et al. Id: a negative regulator of helix-loop-helix DNA binding proteins. Control of terminal myogenic differentiation. *Ann N Y Acad Sci*. 1990;599:1-11.
6. Dave SS, Fu K, Wright GW, et al. Molecular diagnosis of Burkitt's lymphoma. *N Engl J Med*. 2006;354(23):2431-2442.
7. Love C, Sun Z, Jima D, et al. The genetic landscape of mutations in Burkitt lymphoma. *Nat Genet*. 2012;44(12):1321-1325.
8. Swerdlow SH. WHO classification of tumours of haematopoietic and lymphoid tissues. 4th ed. World Health Organization classification of tumours. Lyon, France: International Agency for Research on Cancer; 2008.
9. Momose S, Weißbach S, Pischmarov J, et al. The diagnostic gray zone between Burkitt lymphoma and diffuse large B-cell lymphoma is also a gray zone of the mutational spectrum. *Leukemia*. 2015;29(8):1789-1791.
10. Capper D, Preusser M, Habel A, et al. Assessment of BRAF V600E mutation status by immunohistochemistry with a mutation-specific monoclonal antibody. *Acta Neuropathol*. 2011;122(1):11-19.
11. Hummel M, Bentink S, Berger H, et al. A biologic definition of Burkitt's lymphoma from transcriptional and genomic profiling. *N Engl J Med*. 2006;354(23):2419-2430.
12. Schmitz R, Ceribelli M, Pittaluga S, Wright G, Staudt LM. Oncogenic mechanisms in Burkitt lymphoma. *Cold Spring Harb Perspect Med*. 2014;4(2).
13. Alexandrov LB, Nik-Zainal S, Wedge DC, et al. Signatures of mutational processes in human cancer. *Nature*. 2013;500(7463):415-421.
14. Kretzmer H, Bernhart SH, Wang W, et al. DNA methylome analysis in Burkitt and follicular lymphomas identifies differentially methylated regions linked to somatic mutation and transcriptional control. *Nat Genet*. 2015;47(11):1316-1325.