

Aztreonam agar is especially useful in the primary isolation of *S aureus* from the sputum of patients with cystic fibrosis and is now part of our standard protocol for such patients.

We thank Gillian Aggasild, Dennis Golder, and Sheila Mackay and all the other MLSOs for their help with this study.

- 1 Hill JH, White EC. Sodium chloride media for the separation of certain Gram positive cocci and Gram negative bacilli. *J Bacteriol* 1929;18:43-57.
- 2 Barker M, Kuper SWA. Identification of *Staphylococcus pyogenes* by the phosphatase reaction. *J Pathol Bacteriol* 1951;63:65-8.
- 3 Collee JG, Duguid JP, Fraser AG, Marmion BP, eds. In: Mackie and McCartney—*Practical medical microbiology*. 13th ed. Edinburgh: Churchill Livingstone, 1989:323.
- 4 Lowbury EJ, Kidson A, Lilly HA. New selective blood agar medium for *Streptococcus pyogenes* and other haemolytic streptococci. *J Clin Pathol* 1964;17:231-5.
- 5 Kucers A, Bennett N McK. *The use of antibiotics, a comprehensive review with clinical emphasis* 4th edn. London: William Heinemann, 1987:543-54.

J Clin Pathol 1993;46:771-772

Pseudotumoral amyloidosis of β_2 -microglobulin origin in the buttock of a patient receiving long term haemodialysis

J Fernández-Alonso, C Rios-Camacho, A Valenzuela-Castaño, J L Rocha-Castilla

Abstract

A 52 year old man who had been receiving haemodialysis for 13 years, with a history of renal tuberculosis, right ischial tuberculous osteomyelitis, and dialysis arthropathy, developed a soft tissue tumour in his left buttock. Histological analysis, immunohistological staining, and electron microscopic examination of the surgically removed tumour showed massive deposits of β_2 -microglobulin (β_2 -M) amyloid. This case shows the expanding clinical spectrum of this type of amyloidosis, and it is suggested that amyloid infiltration should be considered in the differential diagnosis of gluteal tumours in these patients.

(*J Clin Pathol* 1993;46:771-772)

Joint and tenosynovial deposits of β_2 -microglobulin (β_2 -M) amyloid are common in patients receiving long term haemodialysis. In some, amyloid deposits give rise to tumours in and around joints.¹⁻³ Deposition of β_2 -M in viscera and other organs is less common; it is much less abundant than in affected joints and seems to be especially common in the vessel walls.⁴⁻⁶ Deposits of β_2 -M amyloid in soft tissue have been described in a few patients receiving haemodialysis.⁷⁻¹⁰ We report a patient who had been receiving haemodialysis for 13 years, with a soft tissue tumour in the gluteal region, which proved to be massive localised deposits of β_2 -M amyloid.

Case report

A 52 year old man had been receiving haemodialysis since 1977 for end stage renal disease, caused by renal tuberculosis. In 1985 he sustained a cerebral vascular accident with

left hemiparesis. In 1986 he developed a right ischial tuberculous osteomyelitis with gluteal abscess, which spontaneously drained through the popliteal space, and was successfully treated with antituberculous drugs for nine months.

In 1989 he was diagnosed as having amyloid arthropathy, which affected his right knee with relapsing joint effusions, and an osteolytic lesion in the left acetabulum. A synovial fluid aspirate from the right knee showed amyloid deposition. A subcutaneous fat biopsy specimen at this time did not show such deposits.

In 1990 he received right sided carpal tunnel decompression for carpal tunnel syndrome. Histological evidence of β_2 -M amyloid was found in the resected tenosynovial tissue. During the same year he complained of pain in the left buttock on sitting. Examination showed a subcutaneous mass measuring about 5 cm in diameter in the left gluteal region. During surgery a firm hourglass-shaped, greyish tumour in the subcutaneous tissue without encapsulation was found. The surgically removed mass contained neither bony nor cartilaginous tissue.

Light microscopic examination of the formaldehyde fixed, paraffin wax embedded mass from this patient showed multiple nodular areas of amorphous eosinophilic material, which stained with Congo red and showed dichroism under polarised light. Amyloid was deposited among collagen bundles and some small nodules were surrounded by multinucleated cells. Calcification foci, necrotic areas, thrombotic lesions, acute and chronic inflammatory cells and granulomatous inflammation were absent. Ziehl-Neelsen stains were negative.

Immunohistochemical studies using the avidin-biotin-complex technique, with monoclonal antibodies anti-A amyloid, and poly-

Department of Pathology

J Fernández-Alonso

Service of Nephrology

C Rios-Camacho

J L Rocha-Castilla

Service of Rheumatology

A Valenzuela-Castaño

Hospital Universitario Virgen del Rocío, Sevilla, Spain

Correspondence to:

J Fernández-Alonso
Anatomía Patológica,
Hospital Universitario
Virgen del Rocío, Avda.
Manuel Siurot s/n 41013-
Sevilla, Spain

Accepted for publication
17 February 1993

clonal anti- β_2 -M, anti- χ , anti- λ , and anti-prealbumin (Dako) showed an intense and specific staining of the material with anti- β_2 -M (figure). No reaction was observed with the other antibodies.

Electron microscopic examination of the formaldehyde fixed tissue showed bundles of curvilinear non-branching fibrils among collagen fibres and occasionally in the cytoplasm of fibrohistiocytic cells, of the length and diameter characteristic of amyloid.¹

Discussion

The results of the histological, immunohistochemical, and ultrastructural examinations proved that the soft tissue tumour of this patient comprised β_2 -M amyloid, and allowed us to preclude other diagnostic possibilities connected with his medical history, such as a new tuberculous abscess or an unusual manifestation of AA amyloidosis.

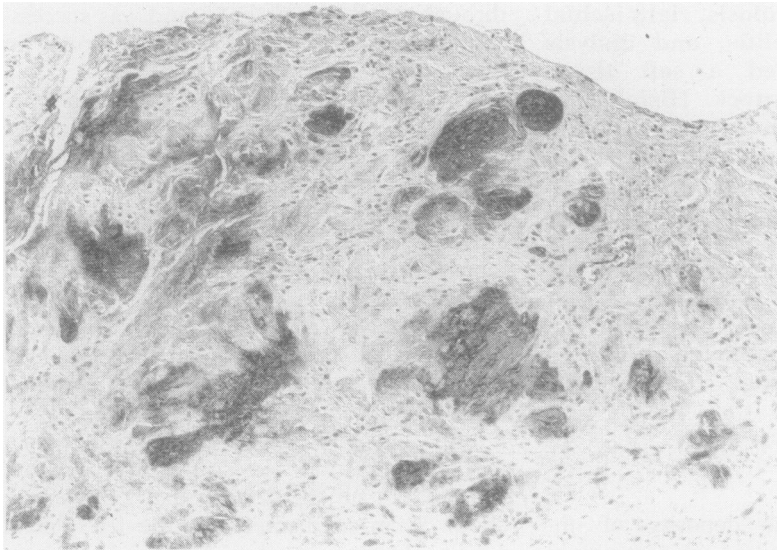
Patients receiving long term haemodialysis are at risk of developing β_2 -M amyloid deposits, particularly in the osteoarticular system. In some instances these deposits present as soft tumours close to joints (Baker's cysts)

or tendons.²⁻³ Soft tissue tumours of β_2 -M amyloid in such patients, however, are an unusual location for this protein, and as far as we know, only four cases have been reported so far.⁷⁻¹⁰ An age older than 40, more than 10 years of dialysis, and previous amyloid arthropathy were the features which our case had in common with four other cases, suggesting that this complication occurs late in treatment.

Tissue changes as a result of chronic trauma could lead to favourable local conditions for deposition of β_2 -M amyloid, as suggested by the gluteal location of amyloid deposits in the cases described by Floege, Sethi, and ourselves.

In summary, this new case of soft tissue tumoral amyloidosis highlights the ever growing list of clinical manifestations of dialysis associated amyloidosis and suggests that amyloidosis should be included in the differential diagnosis of gluteal tumours in these patients.

We thank Mr Hermida for kindly performing the immunohistochemical techniques.



Amyloid masses of the gluteal pseudotumour positively stained with anti- β_2 -microglobulin.

- 1 Casey TT, Stone WJ, DiRaimondo CR, *et al.* Tumoral amyloidosis of bone of β_2 -microglobulin origin in association with long-term hemodialysis. A new type of amyloid disease. *Hum Pathol* 1986;17:731-8.
- 2 Brancaccio D, Gallieni M, Padovese P, Anelli A, Coggi G, Uslenghi C. Dialysis amyloidosis with massive popliteal deposition of β_2 -microglobulin amyloid. *Lancet* 1988; ii:802.
- 3 Lusenti T, Borgatti PP, Anelli A, Brancaccio D. Multiple tendineal tumoral amyloid masses in a patient on long-term dialysis. *Nephron* 1991;57:243-4.
- 4 Campistol JM, Casas A, Torras A, *et al.* Visceral involvement of dialysis amyloidosis. *Am J Nephrol* 1987;7: 390-3.
- 5 Noël LH, Zingraff J, Bardin T, Atienza C, Kuntz D, Drüeke T. Tissue distribution of dialysis amyloidosis. *Clin Nephrol* 1987;27:175-8.
- 6 Ogawa H, Saito A, Hirabayashi N, Hara K. Amyloid deposition in systemic organs in long-term hemodialysis patients. *Clin Nephrol* 1987;28:199-204.
- 7 Theaker JM, Raine AEG, Rainey AJ, Heryet A, Clark A, Oliver DO. Systemic amyloidosis of β_2 -microglobulin type: a complication of long term haemodialysis. *J Clin Pathol* 1987;40:1247-51.
- 8 Floege J, Brandis A, Nonnast-Daniel B, *et al.* Subcutaneous amyloid-tumor of β_2 -microglobulin origin in a long-term hemodialysis patient. *Nephron* 1989;53: 73-5.
- 9 Sethi D, Hutchison AJ, Cary NRB, Curtis JR, Woodrow DF, Gower PE. Macroglossia and amyloidoma of the buttock: evidence of systemic involvement in dialysis amyloid. *Nephron* 1990;55:312-5.
- 10 Athanasou NA, Chaplin AJ, Oliver DO. Subcutaneous deposition of beta₂-microglobulin amyloid in a long-term haemodialysis patient. *Nephrol Dial Transplant* 1990;5:878-81.