

Role of Imaging in the Staging and Response Assessment of Lymphoma: Consensus of the International Conference on Malignant Lymphomas Imaging Working Group

Sally F. Barrington, N. George Mikhaeel, Lale Kostakoglu, Michel Meignan, Martin Hutchings, Stefan P. Müller, Lawrence H. Schwartz, Emanuele Zucca, Richard I. Fisher, Judith Trotman, Otto S. Hoekstra, Rodney J. Hicks, Michael J. O'Doherty, Roland Hustinx, Alberto Biggi, and Bruce D. Cheson

See accompanying article on page 3059

Sally F. Barrington and Michael J. O'Doherty, King's College London; N. George Mikhaeel, Guy's and St Thomas' National Health Service Foundation Trust, London, United Kingdom; Lale Kostakoglu, Mount Sinai Medical Center; Lawrence H. Schwartz, Columbia University Medical Center, New York, NY; Michel Meignan, Centre Universitaire Hospitalier Henri Mondor, Paris, France; Martin Hutchings, Rigshospitalet, Copenhagen University Hospital, Copenhagen, Denmark; Stefan P. Müller, Klinik für Nuklearmedizin, Universitätsklinikum Essen, Germany; Emanuele Zucca, Oncology Institute of Southern Switzerland, Ospedale San Giovanni, Bellinzona, Switzerland; Richard I. Fisher, Fox Chase Cancer Center, Philadelphia, PA; Judith Trotman, Concord Hospital and University of Sydney, Sydney, New South Wales; Rodney J. Hicks, Peter MacCallum Cancer Centre and University of Melbourne, Melbourne, Victoria, Australia; Otto S. Hoekstra, Vrije Universiteit Medical Center, Amsterdam, the Netherlands; Roland Hustinx, University of Liège, Liège, Belgium; Alberto Biggi, Azienda Ospedaliera S. Croce e Carle, Cuneo, Italy; and Bruce D. Cheson, Lombardi Comprehensive Cancer Center, Georgetown University Hospital, Washington, DC.

Published online ahead of print at www.jco.org on August 11, 2014.



Processed as a Rapid Communications manuscript.

Authors' disclosures of potential conflicts of interest and author contributions are found at the end of this article.

Corresponding author: Sally F. Barrington, MBBS, MSc, FRCP, FRCR, MD, Reader in Nuclear Medicine, PET Imaging Centre at St Thomas', Westminster Bridge Rd, London SE1 7EH, United Kingdom; e-mail: sally.barrington@kcl.ac.uk.

© 2014 by American Society of Clinical Oncology

0732-183X/14/3227w-3048w/\$20.00

DOI: 10.1200/JCO.2013.53.5229

A B S T R A C T

Purpose

Recent advances in imaging, use of prognostic indices, and molecular profiling techniques have the potential to improve disease characterization and outcomes in lymphoma. International trials are under way to test image-based response-adapted treatment guided by early interim positron emission tomography (PET)–computed tomography (CT). Progress in imaging is influencing trial design and affecting clinical practice. In particular, a five-point scale to grade response using PET-CT, which can be adapted to suit requirements for early- and late-response assessment with good interobserver agreement, is becoming widely used both in practice- and response-adapted trials. A workshop held at the 11th International Conference on Malignant Lymphomas (ICML) in 2011 concluded that revision to current staging and response criteria was timely.

Methods

An imaging working group composed of representatives from major international cooperative groups was asked to review the literature, share knowledge about research in progress, and identify key areas for research pertaining to imaging and lymphoma.

Results

A working paper was circulated for comment and presented at the Fourth International Workshop on PET in Lymphoma in Menton, France, and the 12th ICML in Lugano, Switzerland, to update the International Harmonisation Project guidance regarding PET. Recommendations were made to optimize the use of PET-CT in staging and response assessment of lymphoma, including qualitative and quantitative methods.

Conclusion

This article comprises the consensus reached to update guidance on the use of PET-CT for staging and response assessment for [¹⁸F]fluorodeoxyglucose-avid lymphomas in clinical practice and late-phase trials.

J Clin Oncol 32:3048-3058. © 2014 by American Society of Clinical Oncology

INTRODUCTION

Advances in staging and response assessment of lymphomas have occurred with the introduction of prognostic indices,¹⁻⁴ molecular profiling,⁵ and more accurate imaging,⁶ with the potential to improve disease characterization and treatment selection. The International Harmonisation Project (IHP) first published guidelines about the application of positron emission tomography (PET) using [¹⁸F]fluorodeoxyglucose (FDG) in lymphoma⁷ in 2007, and PET was integrated in revised response criteria.⁸

The field has continued to evolve. PET combined with computed tomography (CT) has re-

placed PET alone. Mounting evidence supports the central role of PET-CT in staging⁹⁻¹⁸ and response assessment in Hodgkin (HL)¹⁹⁻²⁷ and non-Hodgkin lymphomas (NHL).²⁸⁻³⁴ Multiple international studies are under way to investigate whether PET-CT response can be used to guide therapy to improve patient outcomes.^{35,36} Concerted efforts have been made to standardize PET-CT methods³⁷⁻⁴¹ and interpretation in the context of trials.⁴² A five-point scale (5-PS), suited to assess differing degrees of response at mid- and end of treatment, has been developed to score images.⁴³ This scale was recommended as the standard reporting tool at the First International Workshop on PET in Lymphoma in Deauville, France, in 2009,

Table 1. Summary of Recommendations

Recommendations
<p>Section 1: Interpretation of PET-CT scans</p> <ol style="list-style-type: none"> 1. Staging of FDG-avid lymphomas is recommended using visual assessment, with PET-CT images scaled to fixed SUV display and color table; focal uptake in HL and aggressive NHL is sensitive for bone marrow involvement and may obviate need for biopsy; MRI is modality of choice for suspected CNS lymphoma (type 1) 2. Five-point scale is recommended for reporting PET-CT; results should be interpreted in context of anticipated prognosis, clinical findings, and other markers of response; scores 1 and 2 represent CMR; score 3 also probably represents CMR in patients receiving standard treatment (type 1) 3. Score 4 or 5 with reduced uptake from baseline likely represents partial metabolic response, but at end of treatment represents residual metabolic disease; increase in FDG uptake to score 5, score 5 with no decrease in uptake, and new FDG-avid foci consistent with lymphoma represent treatment failure and/or progression (type 2)
<p>Section 2: Role of PET-CT for staging</p> <ol style="list-style-type: none"> 1. PET-CT should be used for staging in clinical practice and clinical trials but is not routinely recommended in lymphomas with low FDG avidity; PET-CT may be used to select best site to biopsy (type 1) 2. Contrast-enhanced CT when used at staging or restaging should ideally occur during single visit combined with PET-CT, if not already performed; baseline findings will determine whether contrast-enhanced PET-CT or lower-dose unenhanced PET-CT will suffice for additional imaging examinations (type 2) 3. Bulk remains an important prognostic factor in some lymphomas; volumetric measurement of tumor bulk and total tumor burden, including methods combining metabolic activity and anatomical size or volume, should be explored as potential prognosticators (type 3)
<p>Section 3: Role of interim PET</p> <ol style="list-style-type: none"> 1. If midtherapy imaging is performed, PET-CT is superior to CT alone to assess early response; trials are evaluating role of PET response-adapted therapy; currently, it is not recommended to change treatment solely on basis of interim PET-CT unless there is clear evidence of progression (type 1) 2. Standardization of PET methods is mandatory for use of quantitative approaches and desirable for routine clinical practice (type 1) 3. Data suggest that quantitative measures (eg, ΔSUVmax) could be used to improve on visual analysis for response assessment in DLBCL, but this requires further validation in clinical trials (type 2)
<p>Section 4: Role of PET at end of treatment</p> <ol style="list-style-type: none"> 1. PET-CT is standard of care for remission assessment in FDG-avid lymphoma; in presence of residual metabolically active tissue, where salvage treatment is being considered, biopsy is recommended (type 1) 2. Investigation of significance of PET-negative residual masses should be collected prospectively in clinical trials; residual mass size and location should be recorded on end-of-treatment PET-CT reports where possible (type 3) 3. Emerging data support use of PET-CT after rituximab-containing chemotherapy in high-tumor burden FL; studies are warranted to confirm this finding in patients receiving maintenance therapy (type 2) 4. Assessment with PET-CT could be used to guide decisions before high-dose chemotherapy and ASCT, but additional studies are warranted (type 3)
<p>Abbreviations: ASCT, autologous stem-cell transplantation; CMR, complete metabolic response; CT, computed tomography; DLBCL, diffuse large B-cell lymphoma; FDG, [¹⁸F]fluorodeoxyglucose; FL, follicular lymphoma; HL, Hodgkin lymphoma; MRI, magnetic resonance imaging; NHL, non-Hodgkin lymphoma; PET, positron emission tomography; SUV, standardized uptake value; ΔSUVmax, change in maximum SUV.</p>

and these so-called Deauville criteria have been widely applied in trials in preference to earlier criteria.⁴⁴⁻⁴⁹ Quantitative applications of FDG-PET are also recognized as objective tools for response monitoring,⁵⁰ although accurate measurement relies on consistent methods for acquisition and processing and rigorous quality assurance of equipment for widespread application.^{39,51-54}

In response to changing requirements for PET-CT, to accommodate assessments at staging and during and after treatment, especially for response-adapted trials, a workshop was convened at the International Conference on Malignant Lymphoma (ICML) in 2011, attended by representatives from major cooperative groups. ICML working groups were established to update guidelines. The imaging group reported to colleagues at follow-up workshops at the Fourth International Workshop on PET in Lymphoma in Menton, France, in 2012 and the 12th ICML in Lugano, Switzerland, in 2013. This article represents the consensus reached regarding the use of PET-CT in lymphoma in clinical practice and late-phase trials.

METHODS

The following areas, pertinent to imaging, were identified as requiring updating at the 2011 workshop:

- Relevance of existing imaging staging, including the influence of bulk and assessment of bone marrow involvement

- Use of early or interim PET-CT and requirements for standardization of methods, including reporting
- Potential prognostic value of quantitative analyses using PET and CT

Experts in nuclear medicine and radiology applied to lymphoma undertook a literature review and shared knowledge about research in progress. Recommendations were formulated as follows (Table 1):

- Based on established current knowledge (type 1)
- To identify emerging applications (type 2)
- To highlight key areas requiring further research (type 3)

Recommendations were presented at the Fourth International Workshop on PET in Lymphoma, and a working paper was circulated for comment and updated after presentation at the 12th ICML.

RECOMMENDATIONS

Interpretation of PET-CT Scans

PET-CT is increasingly used for staging and response assessment in lymphoma,⁶ both for early assessment during treatment,^{19,20,22-25,28,29,31,55-59} commonly referred to as interim PET-CT (iPET),⁴³ and for remission assessment at the end of treatment.^{26,27,30,32-34,60,61} Almost all lymphomas are FDG avid⁶²⁻⁶⁴ (Table 2), but most published data are related to the use of PET in HL, diffuse large B-cell lymphoma (DLBCL), and follicular lymphoma (FL). PET scans are usually reported using visual assessment,⁴³ noting the location of increased focal uptake in nodal and extranodal sites,

Table 2. FDG Avidity According to WHO Classification

Histology	No. of Patients	FDG Avid (%)
HL	489	97-100
DLBCL	446	97-100
FL	622	91-100
Mantle-cell lymphoma	83	100
Burkitt's lymphoma	24	100
Marginal zone lymphoma, nodal	14	100
Lymphoblastic lymphoma	6	100
Anaplastic large T-cell lymphoma	37	94-100*
NK/T-cell lymphoma	80	83-100
Angioimmunoblastic T-cell lymphoma	31	78-100
Peripheral T-cell lymphoma	93	86-98
MALT marginal zone lymphoma	227	54-81
Small lymphocytic lymphoma	49	47-83
Enteropathy-type T-cell lymphoma	20	67-100
Marginal zone lymphoma, splenic	13	53-67
Marginal zone lymphoma, unspecified	12	67
Mycosis fungoides	24	83-100
Sezary syndrome	8	100†
Primary cutaneous anaplastic large T-cell lymphoma	14	40-60
Lymphomatoid papulosis	2	50
Subcutaneous panniculitis-like T-cell lymphoma	7	71
Cutaneous B-cell lymphoma	2	0

NOTE. Data adapted,⁶⁴ with additional updates.^{18,33,34,65-67}
Abbreviations: DLBCL, diffuse large B-cell lymphoma; FDG, [¹⁸F]fluorodeoxyglucose; FL, follicular lymphoma; HL, Hodgkin lymphoma; MALT, mucosa-associated lymphoid tissue; NK, natural killer.
*Only 27% of cutaneous sites.
†Only 62% of cutaneous sites.

which is distinguished from physiologic uptake and other patterns of disease with increased FDG uptake including infection and inflammation,^{68,69} according to distribution and/or CT characteristics.

Focal FDG uptake within the bone or bone marrow, liver, and spleen is highly sensitive for involvement in HL⁷⁰⁻⁷³ and aggressive NHL⁷⁴⁻⁷⁷ and may obviate the need for bone marrow biopsy.^{70,78,79}

Diffuse increased uptake may occur with abnormal focal uptake, but in HL, diffuse uptake without focal activity often represents reactive hyperplasia^{70,80} and should not be confused with lymphomatous involvement. PET-CT can miss low-volume involvement, typically < 20% of the marrow,^{79,80} and coexistent low-grade lymphoma^{77,81} in DLBCL, although this rarely affects management.⁷⁹ The sensitivity of PET for diffuse marrow involvement is limited in FL,¹⁸ mantle-cell lymphoma, and most indolent lymphomas,^{77,82} where biopsy is required for staging.

High physiologic FDG uptake occurs in the brain, and although intracerebral lymphoma often shows intense uptake,⁸³ leptomeningeal disease, which may be diffuse and of low volume, may be missed. Magnetic resonance imaging (MRI) is preferred to assess suspected CNS involvement.

PET scans are best reported using a fixed display and color table scaled to the standardized uptake value (SUV)⁸⁴ to assist with consistency of reporting, for serial scans, and to reduce the effect of patient size. The SUV is the radioactivity most commonly corrected for patient weight and administered activity.

Recommendation. Staging of FDG-avid lymphomas is recommended using visual assessment, with PET-CT images scaled to a fixed

SUV display and color table. Focal uptake in HL and aggressive NHL is sensitive for bone marrow involvement and may obviate the need for biopsy. MRI is the modality of choice for suspected CNS lymphoma (type 1).

Resolution of uptake at sites of initial disease indicates metabolic response.⁸ Reduction of uptake may also indicate satisfactory response, but the degree of uptake that is indicative of response⁴³ is dependent on the timing of the scan during treatment^{85,86} and the clinical context, including prognosis, lymphoma subtype,^{21,30,60} and treatment regimen.^{22,56} The availability of a baseline scan is considered optimal for the accuracy of subsequent response assessment.^{40,43,87,88}

The IHP criteria⁷ specified that uptake should be \leq the mediastinal blood pool for lesions \geq 2 cm or the adjacent background for smaller lesions to define metabolic response at the end of treatment. In early-response assessment, treatment is incomplete, so the emphasis is on the degree of response and a continuous or close-to-continuous scale is desirable rather than positive or negative response categories.⁴³ Early attempts to address this used three response groups (ie, negative, minimal residual uptake, and positive).^{19,57,89,90} Further refinement led to the development of the 5-PS,⁴² which better represents different grades of uptake.

The 5-PS was intended as a simple, reproducible scoring method, with the flexibility to change the threshold between good or poor response according to the clinical context and/or treatment strategy.⁴² For example, a lower level of FDG uptake might be preferred to define a so-called negative result in a clinical trial exploring de-escalation to avoid undertreatment. A higher level of uptake might be preferred to define a so-called positive result in a trial exploring escalation to avoid overtreatment. The 5-PS has been validated for use at interim^{25,28,34,44,58,91-93} and the end of treatment^{34,94} and was adopted as the preferred reporting method at the First International Workshop on PET in Lymphoma in Deauville, France (ie, Deauville criteria),⁴³ and in several international trials.^{42,44,46-49,95-97}

The 5-PS scores the most intense uptake in a site of initial disease, if present, as follows:

- 1. No uptake
- 2. Uptake \leq mediastinum
- 3. Uptake > mediastinum but \leq liver
- 4. Uptake moderately higher than liver
- 5. Uptake markedly higher than liver and/or new lesions
- X. New areas of uptake unlikely to be related to lymphoma

Good interobserver agreement has been reported in HL,^{42,92,98} DLBCL,⁹³ and FL.³⁴

The UK RAPID (Response Adapted Therapy Using Positron Emission Tomography in Early-Stage Hodgkin Lymphoma) study used the 5-PS in patients with early HL. iPET remained an independent predictor of 3-year progression-free survival (PFS) on multivariable analysis, despite use of a response-adapted design.⁴⁴ Conservative scoring was used, with a score of 1 or 2 regarded as complete metabolic response (CMR); patients with CMR after three cycles of ABVD (doxorubicin, bleomycin, vinblastine, and dacarbazine) were randomly assigned to radiotherapy (RT) or no further treatment. Retrospective analysis of an international cohort of 260 patients with advanced HL using scores 1, 2, and 3 to define CMR after two ABVD cycles reported a negative predictive value (NPV) of 94% and positive predictive value (PPV) of 73% for 3-year PFS.²⁵ iPET and end-of-treatment PET using scores 1, 2, and 3 for CMR were both independent predictors of 2-year

PFS in a recent prospective study in FL.³⁴ Other studies in HL and NHL have reported that increasing the threshold to define CMR improved the PPV while maintaining a high NPV.^{28,34,91,92,94}

Scores 1 and 2 are therefore considered to represent CMR. Score 3 also likely represents CMR at interim²⁵ and good prognosis at completion of standard treatment.^{34,94,99} However, in trials where de-escalation is based on PET response, it may be preferable to consider score 3 as inadequate response to avoid undertreatment.⁴²

Recommendation. The 5-PS is recommended for reporting PET-CT. Results should be interpreted in the context of the anticipated prognosis, clinical findings, and other markers of response. Scores 1 and 2 represent CMR. Score 3 also probably represents CMR in patients receiving standard treatment (type 1).

The terms moderately and markedly were not defined initially, because there were insufficient data to define scores quantitatively.⁴³ Meanwhile, it is suggested according to published data^{25,34,100} that score 4 be applied to uptake > the maximum SUV in a large region of normal liver and score 5 to uptake 2× to 3× > the maximum SUV in the liver. It is acknowledged that mean liver SUV may be less influenced by image noise than maximum SUV, but reproducibility is more dependent on standardizing the location and size of the region of interest.¹⁰¹ Work is ongoing to assess optimal tumor and liver metrics.¹⁰² The liver is also affected by insulin levels, and patient preparation is important with respect to fasting and timing of insulin administration in diabetics.¹⁰³ It is recognized that in Waldeyer's ring or extranodal sites with high physiologic uptake or with activation within spleen or marrow (eg, with chemotherapy or granulocyte colony-stimulating factor [G-CSF]), FDG uptake may be > normal mediastinum and/or liver. In this circumstance, CMR may be inferred if uptake at sites of initial involvement is no greater than surrounding normal tissue, even if the tissue has high physiologic uptake.

Recommendation. Scores 4 and 5 with reduced uptake from baseline likely represent partial metabolic response, but at the end of treatment, they represent residual metabolic disease. An increase in FDG uptake to a score of 5, score 5 with no decrease in uptake, and new FDG-avid foci consistent with lymphoma represent treatment failure and/or progression (type 2).

Nonspecific FDG uptake may occur with treatment-related inflammation. Patients should be scanned as long after the previous chemotherapy administration as possible for interim assessment. A minimum of 3 weeks, but preferably 6 to 8 weeks, after completion of the last chemotherapy cycle,⁷ 2 weeks after G-CSF treatment, or 3 months after RT is recommended.³⁹

Role of PET-CT for Staging

Previous clinical trials have used the Ann Arbor staging system to select patients and report outcomes.¹⁰⁴ Currently, prognostic indices are mostly used to risk stratify patients at diagnosis to inform therapy, but most include stage as a factor,^{1-3,105} so imaging-determined stage remains relevant.

PET-CT using FDG is more accurate than CT for staging in HL^{9,10,106-111} and NHL,^{11-13,18,112,113} with increased sensitivity, particularly for extranodal disease.⁶ Upstaging occurs more often than downstaging, with management alterations in some patients (Table 3). Management change after upstaging is more common in FL^{14,15} than other lymphomas, especially for patients with limited disease on CT.^{16,17}

The intensity of FDG uptake is higher in aggressive than indolent lymphomas, and FDG PET-CT may be used to target biopsy in patients with suspected transformation.^{65,114,115}

Recommendation. PET-CT should be used for staging in clinical practice and clinical trials, but it is not routinely recommended in

Table 3. Studies Comparing PET or PET-CT With CT Alone for Staging of Lymphomas

Study	Year	PET or PET-CT	No. of Patients	Disease	Upstaging (%)	Downstaging (%)	Management Change (%)
Bangerter et al ¹⁰⁶	1998	PET	44	HL	12	2	14
Partridge et al ¹⁰⁷	2000	PET	44	HL	41	7	25
Jerusalem et al ¹⁰⁸	2001	PET	33	HL	10	10	3
Weihrauch et al ¹⁰⁹	2002	PET	22	HL	18	0	5
Munker et al ¹¹⁰	2004	PET	73	HL	29	3	NS
Naumann et al ¹¹¹	2004	PET	88	HL	13	8	20
Hutchings et al ⁹	2006	Mostly PET-CT	99	HL	19	5	9
Rigacci et al ¹⁰	2007	Mostly PET	186	HL	14	1	6
Buchmann et al ¹¹²	2001	PET	52	HL (n = 27), NHL (n = 25)	8	0	8
Wirth et al ¹¹³	2002	PET	50	HL (n = 19), NHL (n = 31)	14	0	18
Raanani et al ¹¹	2006	PET-CT	103	HL (n = 32), NHL (n = 68)	31	1	25
Elstrom et al ¹²	2008	PET-CT	61	HL and NHL	18	0	5
Pelosi et al ¹³	2008	PET	65	HL (n = 30), NHL (n = 35)	11	5*	8
Karam et al ¹⁴	2006	PET	17	FL	41	0	29
Janikova et al ¹⁵	2008	Mostly PET	82	FL	NS	NS	18
Wirth et al ¹⁶	2008	PET	42	FL stages I-II on CT	29	0	45
Le Dortz et al ¹⁷	2010	PET-CT	45	FL	8	0	18
Luminari et al ¹⁸	2013	PET-CT	142	FL	11	1	NS

Abbreviations: CT, computed tomography; FL, follicular lymphoma; HL, Hodgkin lymphoma; NHL, non-Hodgkin lymphoma; NS, not stated; PET, positron emission tomography.

*False negative.

lymphomas with low FDG avidity. PET-CT may be used to select the best site to biopsy (type 1).

Role of Contrast-Enhanced CT

The CT part of a PET-CT scan may be performed with contrast enhancement (ceCT) at full dose to obtain a high-quality CT examination or without contrast using a lower dose. Lower-dose CT is used to correct for the attenuation of radioactivity within the patient and to localize abnormalities seen on PET, with less radiation than a full diagnostic examination.⁸⁴ Whichever protocol is used, CT must be acquired during shallow breathing or end of expiration to avoid misregistration and artifacts.

Direct comparison of unenhanced lower-dose PET-CT and cePET-CT suggests management is rarely altered by ceCT, although ceCT may identify additional findings^{11,12,116-119} and improve detection of abdominal or pelvic disease.^{11,116,117} However, full-dose ceCT involves additional radiation, which should be considered when deciding which examination to perform. ceCT is desirable for RT planning performed in the treatment position¹²⁰ and is required for accurate nodal measurements for trial purposes.

Small errors in the measurement of FDG uptake in tumor may occur with contrast media¹²¹ because of an effect on attenuation correction; these errors are unlikely to be clinically important.¹²² However, contrast may cause errors in comparison of uptake between tumor and reference sites by causing FDG uptake to be overestimated in the mediastinum and liver by 10% to 15%.¹²¹ Several organizations (eg, European Association Nuclear Medicine, Society Nuclear Medicine, and Radiological Society North America) recommend that a low-dose CT scan with normal breathing be performed before a PET scan, followed by full diagnostic high-dose ceCT with repositioning of the arms and breath hold, if quantitative measures and ceCT are required.

In practice, many patients undergo separate ceCT before PET-CT. If baseline ceCT demonstrates no additional relevant findings, lower-dose CT during PET-CT examination will be sufficient for response assessment.

Recommendation. ceCT when used at staging or restaging should ideally occur during a single visit in combination with PET-CT, if not already performed. The baseline findings will determine whether cePET-CT or lower-dose unenhanced PET-CT will suffice for additional imaging examinations (type 2).

Relevance of Initial Disease Bulk

The presence of bulky disease is a negative prognostic factor in some lymphomas.^{1-3,105} Bulk is considered an adverse factor in early-stage HL¹²³ but not in advanced HL.¹⁰⁵ In DLBCL, bulk is predictive of inferior survival in favorable-prognosis disease^{124,125} but not in poor-prognosis disease, probably because its influence is superseded by other factors reflecting disease burden.¹²⁶ The longest diameter of the largest involved node is included in the FL International Prognostic Index 2.¹²⁷ Unidimensional measurements are used for bulk, but these do not assess total tumor burden. Newer methods of contouring are being developed for CT^{128,129} and PET^{130,131} to measure the total tumor volume. The prognostic value of these methods remains to be evaluated.

Recommendation. Bulk remains an important prognostic factor in some lymphomas. Volumetric measurement of tumor bulk and total tumor burden, including methods combining metabolic activity

and anatomic size or volume, should be explored as potential prognosticators (type 3).

Role of iPET

Interim imaging is frequently performed in clinical practice and trials and is recommended by some international guidelines.¹²³ The purpose is to ensure the effectiveness of treatment and exclude the possibility of progression. PET-CT shows metabolic response earlier than anatomic response and has the potential to replace CT. Studies have shown that iPET is a strong prognostic indicator in HL^{19-25,132} and aggressive NHL,^{28,29,31,55,57,59,133} outperforming the International Prognostic Score²² and International Prognostic Index.⁵⁷ These findings highlight the potential of using iPET to tailor treatment according to individual response. However, it is important to emphasize that there is no conclusive evidence that changing treatment according to iPET improves outcome,^{6,35} a question currently being addressed in clinical trials worldwide.³⁵

There is a preponderance of data reporting the predictive value of iPET, most often after two cycles in HL^{20,22-25} (Appendix Table A1, online only). In DLBCL, early indication of poor response is especially important because salvage treatment of progressive or relapsed disease is less effective in the rituximab era.¹³⁴ However, although early data favored iPET,^{55,57,59} more recent data have suggested iPET is less predictive for response with immunochemotherapy^{30-32,58,135,136} (Appendix Table A2, online only), and end-of-treatment PET is a better predictor.

Visual assessment with iPET in HL results in consistently high NPV, with ≥ 2 -year PFS of approximately 95%, and acceptable PPV, with PFS between 13% and 27%,^{19,22,24,92} for advanced disease treated with ABVD. Initial reports using visual analysis for iPET in DLBCL were favorable,^{55,57,59} but more recent studies have demonstrated good NPV, with ≥ 2 -year PFS rates of 73% to 86% for patients with so-called negative scans, but more variable PPV. PFS for PET-positive patients in recent studies has ranged from 18% to 74%.^{28-32,93,135-137} The drop in PPV may be related to improved outcomes with rituximab or better supportive care^{126,138} or may possibly occur because so-called false-positive metabolic activity is more frequent with immunotherapy.³⁰ A different cutoff or combination of factors may be required for modern management of DLBCL.

Recommendation. If midtherapy imaging is performed, PET-CT is superior to CT alone to assess early response. Trials are evaluating the role of PET response-adapted therapy. Currently, changing treatment solely on the basis of iPET-CT is not recommended, unless there is clear evidence of progression (type 1).

The use of quantitation to improve on visual assessment has been explored in DLBCL. Change in the maximum SUV (δ SUVmax) in tumor before and after treatment has been evaluated as a measure of response. Receiver operator curve analysis in 92 patients with DLBCL scanned after two cycles and 80 patients scanned after four identified optimum thresholds for percentage change in SUVmax for predicting event-free survival (EFS).^{85,86} A retrospective analysis applied to a trial where treatment was adapted according to visual assessment with iPET reported that δ SUVmax at two and four cycles was predictive of PFS, whereas visual analysis was not.¹³⁹ Other groups have also reported that δ SUVmax predicts response, but with thresholds ranging from 66% to 91%,^{58,91,137,139} suggesting that consistency in scanning protocols, matching conditions for serial scans, and proper calibration and scanner maintenance are mandatory for

general application.^{38,39,41,51-53,121,140} The optimum cutoff is also likely influenced by timing, with a tendency for a higher cutoff later during treatment.⁸⁶ Although the goal of quantitation is more objective assessment, it remains necessary to integrate with clinical information to exclude confounding variables.³⁹

The δ SUVmax analysis is being prospectively applied in the PETAL (Positron Emission Tomography Guided Therapy of Aggressive Non-Hodgkin's Lymphomas) and GAINED (GA in Newly Diagnosed Diffuse Large B Cell Lymphoma) studies exploring response-adapted treatment with immunochemotherapy.⁵⁰ Combining δ SUVmax with CT metrics in early nonbulky HL¹⁴¹ and with age-adjusted International Prognostic Index in DLBCL has been reported to improve response prediction.⁵⁸ Another measure proposed is SUVpeak, a 1-cm³ volume containing the hottest area of tumor,¹⁰² which may be less sensitive to noise and resolution and possibly more reproducible. Changes in the metabolic tumor volume (MTV) and total lesion glycolysis (TLG) calculated as MTV \times SUVmean are additional exploratory measures.¹⁰² However, preliminary reports have suggested changes in MTV and TLG are not predictive in DLBCL.^{131,142} The results of the UK National Cancer Research Institute PET R-CHOP (rituximab plus cyclophosphamide, doxorubicin, vincristine, and prednisone) substudy measuring PFS in 200 patients with DLBCL where clinicians were blinded to iPET are awaited.^{40,143} This and other studies may provide insight into whether quantitation will improve the performance of iPET in DLBCL.¹³⁹

Recommendation. Standardization of PET methods is mandatory for the use of quantitative approaches and desirable for routine clinical practice (type 1). Data suggest that quantitative measures (eg, δ SUVmax) could be used to improve on visual analysis for response assessment in DLBCL, but this requires further validation in clinical trials (type 2).

Role of PET at the End of Treatment

End-of-treatment remission assessment is more accurate with PET-CT than CT alone in patients with HL,^{26,60} DLBCL,^{30,32} and high-tumor burden FL^{33,34} (Appendix Table A3, online only). High accuracy for PET-CT has been reported in patients after treatment with ABVD²⁶ and BEACOPP (bleomycin, etoposide, doxorubicin, cyclophosphamide, vincristine, procarbazine, and prednisone)²⁷ for advanced HL. In a study where PET was used to guide RT, patients treated with BEACOPP (but no RT) with a PET-negative positive response had PFS equivalent to that of patients with complete response (CR) or unconfirmed CR.²⁷ In aggressive NHL, studies involving > 300 patients have reported consistently high NPV of 80% to 100% but more variable PPV of 50% to 100%.^{30,32,61,135,144,145} In the presence of residual metabolically active tissue, if salvage treatment is being considered, a biopsy may be required. If residual disease is considered unlikely, the scan could be repeated later.

Recommendation. PET-CT is the standard of care for remission assessment in FDG-avid lymphoma. For HL and DLBCL, in the presence of residual metabolically active tissue, where salvage treatment is being considered, a biopsy is recommended (type 1).

The significance of a residual mass if CMR is achieved is unclear, with some reports suggesting improved outcomes when CMR is associated with a radiologic CR in HL and DLBCL,¹⁴⁶⁻¹⁴⁹ whereas others suggest outcomes are unaffected by the presence of a residual mass.^{23,27,150} It is proposed that the size of the residual mass be re-

corded where possible, and if relapse occurs, it should be documented whether this occurred within the residual mass.

Recommendation. Investigation of the significance of PET-negative residual masses should be collected prospectively in clinical trials. Residual mass size and location should be recorded on end-of-treatment PET-CT reports where possible (type 3).

In FL, PET predicts inferior outcomes in patients with high tumor burden who remain PET positive after first-line immunochemotherapy.^{33,34} Post-treatment PET seems to be a better predictor than iPET.³⁴ Currently, data are insufficient regarding assessment after maintenance therapy.¹⁵¹ This suggests a potential role for PET in evaluating new approaches in response-adapted studies in FL after first-line treatment with rituximab-containing chemotherapy.¹⁵¹

Recommendation. Emerging data support the use of PET-CT after rituximab-containing chemotherapy in high-tumor burden FL. Studies are warranted to confirm this finding in patients receiving maintenance therapy (type 2).

Assessment Before High-Dose Chemotherapy and Autologous Stem-Cell Transplantation

Various studies have reported that PET-CT using FDG is prognostic in patients with relapsed or refractory HL or DLBCL after salvage chemotherapy before high-dose chemotherapy and autologous stem-cell transplantation (ASCT)¹⁵²⁻¹⁵⁷ and is superior to CT alone.¹⁵⁸ Three-year PFS and EFS rates of 31% to 41% have been reported for patients with PET-positive scans, compared with 75% to 82% for patients with PET-negative scans.¹⁵²⁻¹⁵⁷

PET may have a role in selecting patients for high-dose chemotherapy and ASCT after salvage treatment¹⁵⁹ and in identifying patients with poor prognosis who could benefit from alternative regimens or consolidation.¹⁶⁰ PET could also be used as a surrogate end point to test the addition of novel therapies to current reinduction regimens.¹⁶¹

Recommendation. Assessment with PET-CT could be used to guide decisions before high-dose chemotherapy and ASCT, but additional studies are warranted (type 3).

PET-CT in Subtypes Other Than HL, DLBCL, and FL

Small retrospective studies have suggested that post-treatment scans can predict survival in treatment of mantle-cell lymphoma.⁶⁵ In primary mediastinal B-cell lymphoma, a recent prospective study reported that 54 (47%) of 115 patients achieved CMR after first-line chemotherapy,⁹⁴ and a PET response-adapted approach is currently being tested (IELSG-37 [International Extranodal Lymphoma Study Group]).⁴⁸ However, another study involving 51 patients treated with dose-adjusted EPOCH (etoposide, prednisone, vincristine, cyclophosphamide, and doxorubicin) plus rituximab reported that 10 of 15 patients had FDG uptake 6 weeks after treatment, which later diminished or stabilized, suggesting treatment-related inflammation with this regimen.¹⁶² There are limited data regarding T-cell lymphomas, with higher uptake reported in more aggressive subtypes and lower uptake in cutaneous lymphomas.¹⁶³ In mycosis fungoides, higher uptake has been reported in the presence of large-cell transformation^{66,163} and extracutaneous disease, which adversely affects prognosis.^{66,164} There are few data on response assessment; one report in noncutaneous mature natural killer/T-cell lymphoma suggested iPET was predictive of response,¹⁶⁵ whereas another found that neither

interim nor end-of-treatment PET were predictive.⁶⁷ Prospective studies are warranted.

DISCUSSION

In response to developments involving PET-CT, recommendations from the ICML imaging group have been made to update practice. These include guidance on reporting of PET-CT for staging and response assessment of HL, DLBCL, and aggressive FL using the 5-PS. PET-CT is recommended for midtreatment assessment in place of CT alone, if imaging is clinically indicated, and for remission assessment. Quantitative imaging parameters for assessing disease burden and response should be explored as potential prognosticators. The standardization of PET-CT methods is mandatory for quantitative analysis and desirable for best clinical practice.

AUTHORS' DISCLOSURES OF POTENTIAL CONFLICTS OF INTEREST

Although all authors completed the disclosure declaration, the following author(s) and/or an author's immediate family member(s) indicated a financial or other interest that is relevant to the subject matter under consideration in this article. Certain relationships marked with a "U" are those for which no compensation was received; those relationships marked

with a "C" were compensated. For a detailed description of the disclosure categories, or for more information about ASCO's conflict of interest policy, please refer to the Author Disclosure Declaration and the Disclosures of Potential Conflicts of Interest section in Information for Contributors.

Employment or Leadership Position: None **Consultant or Advisory Role:** None **Stock Ownership:** None **Honoraria:** Lawrence H. Schwartz, Pfizer **Research Funding:** None **Expert Testimony:** None **Patents, Royalties, and Licenses:** None **Other Remuneration:** Lawrence H. Schwartz, Roche; Richard I. Fisher, Johnson & Johnson, Gilead Sciences, Coherus Bioscience

AUTHOR CONTRIBUTIONS

Conception and design: Sally F. Barrington, N. George Mikhaeel, Lale Kostakoglu, Michel Meignan, Martin Hutchings, Stefan P. Müller, Lawrence H. Schwartz, Emanuele Zucca, Richard I. Fisher, Rodney J. Hicks, Michael J. O'Doherty, Alberto Biggi, Bruce D. Cheson

Collection and assembly of data: Sally F. Barrington, N. George Mikhaeel, Lale Kostakoglu, Michel Meignan, Martin Hutchings, Stefan P. Müller, Lawrence H. Schwartz

Data analysis and interpretation: Sally F. Barrington, N. George Mikhaeel, Lale Kostakoglu, Michel Meignan, Martin Hutchings, Stefan P. Müller, Lawrence H. Schwartz, Judith Trotman, Otto S. Hoekstra, Roland Hustinx

Manuscript writing: All authors

Final approval of manuscript: All authors

REFERENCES

1. A predictive model for aggressive non-Hodgkin's lymphoma: The International Non-Hodgkin's Lymphoma Prognostic Factors Project. *N Engl J Med* 329:987-994, 1993
2. Solal-Céligny P, Roy P, Colombat P, et al: Follicular lymphoma international prognostic index. *Blood* 104:1258-1265, 2004
3. Hoster E, Dreyling M, Klapper W, et al: A new prognostic index (MIPI) for patients with advanced-stage mantle cell lymphoma. *Blood* 111:558-565, 2008
4. Younes A: Early-stage Hodgkin's lymphoma: In pursuit of perfection. *J Clin Oncol* 30:895-896, 2012
5. Rosenwald A, Wright G, Chan WC, et al: The use of molecular profiling to predict survival after chemotherapy for diffuse large-B-cell lymphoma. *N Engl J Med* 346:1937-1947, 2002
6. Cheson BD: Role of functional imaging in the management of lymphoma. *J Clin Oncol* 29:1844-1854, 2011
7. Juweid ME, Stroobants S, Hoekstra OS, et al: Use of positron emission tomography for response assessment of lymphoma: Consensus of the Imaging Subcommittee of International Harmonization Project in Lymphoma. *J Clin Oncol* 25:571-578, 2007
8. Cheson BD, Pfistner B, Juweid ME, et al: Revised response criteria for malignant lymphoma. *J Clin Oncol* 25:579-586, 2007
9. Hutchings M, Loft A, Hansen M, et al: Position emission tomography with or without computed tomography in the primary staging of Hodgkin's lymphoma. *Haematologica* 91:482-489, 2006
10. Rigacci L, Vitolo U, Nassi L, et al: Positron emission tomography in the staging of patients with Hodgkin's lymphoma: A prospective multicentric

study by the Intergruppo Italiano Linfomi. *Ann Hematol* 86:897-903, 2007

11. Raanani P, Shasha Y, Perry C, et al: Is CT scan still necessary for staging in Hodgkin and non-Hodgkin lymphoma patients in the PET/CT era? *Ann Oncol* 17:117-122, 2006

12. Elstrom R, Leonard JP, Coleman M, et al: Combined PET and low-dose, noncontrast CT scanning obviates the need for additional diagnostic contrast-enhanced CT scans in patients undergoing staging or restaging for lymphoma. *Ann Oncol* 19:1770-1773, 2008

13. Pelosi E, Pregno P, Penna D, et al: Role of whole-body [18F] fluorodeoxyglucose positron emission tomography/computed tomography (FDG-PET/CT) and conventional techniques in the staging of patients with Hodgkin and aggressive non Hodgkin lymphoma [in English, Italian]. *Radiol Med* 113:578-590, 2008

14. Karam M, Novak L, Cyriac J, et al: Role of fluorine-18 fluoro-deoxyglucose positron emission tomography scan in the evaluation and follow-up of patients with low-grade lymphomas. *Cancer* 107:175-183, 2006

15. Janikova A, Bolcak K, Pavlik T, et al: Value of [18F]fluorodeoxyglucose positron emission tomography in the management of follicular lymphoma: The end of a dilemma? *Clin Lymphoma Myeloma* 8:287-293, 2008

16. Wirth A, Foo M, Seymour JF, et al: Impact of [18F] fluorodeoxyglucose positron emission tomography on staging and management of early-stage follicular non-hodgkin lymphoma. *Int J Radiat Oncol Biol Phys* 71:213-219, 2008

17. Le Dortz L, De Guibert S, Bayat S, et al: Diagnostic and prognostic impact of 18F-FDG PET/CT in follicular lymphoma. *Eur J Nucl Med Mol Imaging* 37:2307-2314, 2010

18. Luminari S, Biasoli I, Arcaini L, et al: The use of FDG-PET in the initial staging of 142 patients with follicular lymphoma: A retrospective study from the

FOLL05 randomized trial of the Fondazione Italiana Linfomi. *Ann Oncol* 24:2108-2112, 2013

19. Hutchings M, Mikhaeel NG, Fields PA, et al: Prognostic value of interim FDG-PET after two or three cycles of chemotherapy in Hodgkin lymphoma. *Ann Oncol* 16:1160-1168, 2005

20. Hutchings M, Loft A, Hansen M, et al: FDG-PET after two cycles of chemotherapy predicts treatment failure and progression-free survival in Hodgkin lymphoma. *Blood* 107:52-59, 2006

21. Gallamini A, Rigacci L, Merli F, et al: The predictive value of positron emission tomography scanning performed after two courses of standard therapy on treatment outcome in advanced stage Hodgkin's disease. *Haematologica* 91:475-481, 2006

22. Gallamini A, Hutchings M, Rigacci L, et al: Early interim 2-[18F]fluoro-2-deoxy-D-glucose positron emission tomography is prognostically superior to international prognostic score in advanced-stage Hodgkin's lymphoma: A report from a joint Italian-Danish study. *J Clin Oncol* 25:3746-3752, 2007

23. Cerci JJ, Pracchia LF, Linardi CC, et al: 18F-FDG PET after 2 cycles of ABVD predicts event-free survival in early and advanced Hodgkin lymphoma. *J Nucl Med* 51:1337-1343, 2010

24. Zinzani PL, Rigacci L, Stefoni V, et al: Early interim 18F-FDG PET in Hodgkin's lymphoma: Evaluation on 304 patients. *Eur J Nucl Med Mol Imaging* 39:4-12, 2012

25. Biggi A, Gallamini A, Chauvie S, et al: International validation study for interim PET in ABVD-treated, advanced-stage Hodgkin lymphoma: Interpretation criteria and concordance rate among reviewers. *J Nucl Med* 54:683-690, 2013

26. Cerci JJ, Trindade E, Pracchia LF, et al: Cost effectiveness of positron emission tomography in patients with Hodgkin's lymphoma in unconfirmed complete remission or partial remission

- after first-line therapy. *J Clin Oncol* 28:1415-1421, 2010
27. Engert A, Haverkamp H, Kobe C, et al: Reduced-intensity chemotherapy and PET-guided radiotherapy in patients with advanced stage Hodgkin's lymphoma (HD15 trial): A randomised, open-label, phase 3 non-inferiority trial. *Lancet* 379:1791-1799, 2012
28. Yang DH, Min JJ, Song HC, et al: Prognostic significance of interim (18)F-FDG PET/CT after three or four cycles of R-CHOP chemotherapy in the treatment of diffuse large B-cell lymphoma. *Eur J Cancer* 47:1312-1318, 2011
29. Zinzani PL, Gandolfi L, Broccoli A, et al: Midtreatment 18F-fluorodeoxyglucose positron-emission tomography in aggressive non-Hodgkin lymphoma. *Cancer* 117:1010-1018, 2011
30. Pregno P, Chiappella A, Bello M, et al: Interim 18-FDG-PET/CT failed to predict the outcome in diffuse large B-cell lymphoma patients treated at the diagnosis with rituximab-CHOP. *Blood* 119:2066-2073, 2012
31. Safar V, Dupuis J, Itti E, et al: Interim [¹⁸F]fluorodeoxyglucose positron emission tomography scan in diffuse large B-cell lymphoma treated with anthracycline-based chemotherapy plus rituximab. *J Clin Oncol* 30:184-190, 2012
32. Micalef IN, Maurer MJ, Wiseman GA, et al: Epratuzumab with rituximab, cyclophosphamide, doxorubicin, vincristine, and prednisone chemotherapy in patients with previously untreated diffuse large B-cell lymphoma. *Blood* 118:4053-4061, 2011
33. Trotman J, Fournier M, Lamy T, et al: Positron emission tomography-computed tomography (PET-CT) after induction therapy is highly predictive of patient outcome in follicular lymphoma: Analysis of PET-CT in a subset of PRIMA trial participants. *J Clin Oncol* 29:3194-3200, 2011
34. Dupuis J, Berriolo-Riedinger A, Julian A, et al: Impact of [¹⁸F]fluorodeoxyglucose positron emission tomography response evaluation in patients with high-tumor burden follicular lymphoma treated with immunochemotherapy: A prospective study from the Groupe d'Etudes des Lymphomes de l'Adulte and GOELAMS. *J Clin Oncol* 30:4317-4322, 2012
35. Hutchings M, Barrington SF: PET/CT for therapy response assessment in lymphoma. *J Nucl Med* 50:21S-30S, 2009 (suppl 1)
36. Kostakoglu L, Gallamini A: Interim 18F-FDG PET in Hodgkin lymphoma: Would PET-adapted clinical trials lead to a paradigm shift? *J Nucl Med* 54:1082-1093, 2013
37. Shankar LK, Hoffman JM, Bacharach S, et al: Consensus recommendations for the use of F-18-FDG PET as an indicator of therapeutic response in patients in national cancer institute trials. *J Nucl Med* 47:1059-1066, 2006
38. Scheuermann JS, Saffer JR, Karp JS, et al: Qualification of PET scanners for use in multicenter cancer clinical trials: The American College of Radiology Imaging Network experience. *J Nucl Med* 50:1187-1193, 2009
39. Boellaard R, O'Doherty MJ, Weber WA, et al: FDG PET and PET/CT: EANM procedure guidelines for tumour PET imaging: Version 1.0. *Eur J Nucl Med Mol Imaging* 37:181-200, 2010
40. Barrington SF, MacKewn JE, Schleyer P, et al: Establishment of a UK-wide network to facilitate the acquisition of quality assured FDG-PET data for clinical trials in lymphoma. *Ann Oncol* 22:739-745, 2011
41. Boellaard R, Oyen WJ, Hoekstra CJ, et al: The Netherlands protocol for standardisation and quantification of FDG whole body PET studies in multi-centre trials. *Eur J Nucl Med Mol Imaging* 35:2320-2333, 2008
42. Barrington SF, Qian W, Somer EJ, et al: Concordance between four European centres of PET reporting criteria designed for use in multicentre trials in Hodgkin lymphoma. *Eur J Nucl Med Mol Imaging* 37:1824-1833, 2010
43. Meignan M, Gallamini A, Haioun C: Report on the First International Workshop on Interim-PET-Scan in Lymphoma. *Leuk Lymphoma* 50:1257-1260, 2009
44. Radford J, Barrington S, Counsell N, et al: Involved field radiotherapy versus no further treatment in patients with clinical stages IA and IIA Hodgkin lymphoma and a "negative" PET scan after 3 cycles ABVD: Results of the UK NCRI RAPID trial. *Blood* 120, 2012 (abstr 547)
45. Johnson P, Federico M, Fossa A, et al: Responses and chemotherapy dose adjustment determined by PET-CT imaging: First results from the International Response Adapted Therapy in Advanced Hodgkin Lymphoma (RATHL) study. *Hematol Oncol* 31:96-150, 2013 (abstr 126)
46. Gallamini A, Rossi A, Patti C, et al: Early treatment intensification in advanced-stage high-risk Hodgkin lymphoma (HL) patients with a positive FDG-PET scan after two ABVD courses: First interim analysis of the GITIL/FIL HD0607 clinical trial. *Blood* 120, 2012 (abstr 550)
47. Southwest Oncology Group: Fluorodeoxyglucose F 18-PET/CT imaging and combination chemotherapy with or without additional chemotherapy and G-CSF in treating patients with stage III or stage IV Hodgkin lymphoma: 02/12 update. <http://clinicaltrials.gov/ct2/show/NCT00822120>
48. International Extranodal Lymphoma Study Group (IELSG): A randomized, open-label two-arm phase III comparative study assessing the role of involved mediastinal radiotherapy after rituximab containing chemotherapy regimens to patients with newly diagnosed primary mediastinal large B-cell lymphoma: 03/2013. <http://clinicaltrials.gov/ct2/show/NCT01599559>
49. Millennium Pharmaceuticals: A randomized, open-label, phase 3 trial of A + AVD versus ABVD as frontline therapy in patients with advanced classical Hodgkin lymphoma: 08/13 update. <http://clinicaltrials.gov/ct2/show/NCT01712490>
50. Dührsen U, Hüttmann A, Jöckel KH, et al: Positron emission tomography guided therapy of aggressive non-Hodgkin lymphomas: The PETAL trial. *Leuk Lymphoma* 50:1757-1760, 2009
51. Young H, Baum R, Cremerius U, et al: Measurement of clinical and subclinical tumour response using [¹⁸F]fluorodeoxyglucose and positron emission tomography: Review and 1999 EORTC recommendations—European Organisation for Research and Treatment of Cancer (EORTC) PET Study Group. *Eur J Cancer* 35:1773-1782, 1999
52. Bourguet P, Blanc-Vincent MP, Boneu A, et al: Summary of the standards, options and recommendations for the use of positron emission tomography with 2-[¹⁸F]fluoro-2-deoxy-D-glucose (FDG-PET scanning) in oncology. *Br J Cancer* 89:S84-S91, 2003 (suppl 1)
53. Coleman RE, Delbeke D, Guibertau MJ, et al: Concurrent PET/CT with an integrated imaging system: Intersociety dialogue from the joint working group of the American College of Radiology, the Society of Nuclear Medicine, and the Society of Computed Body Tomography and Magnetic Resonance. *J Nucl Med* 46:1225-1239, 2005
54. Boellaard R: Standards for PET image acquisition and quantitative data analysis. *J Nucl Med* 50:11S-20S, 2009 (suppl 1)
55. Haioun C, Itti E, Rahmouni A, et al: F-18 fluoro-2-deoxy-D-glucose positron emission tomography (FDG-PET) in aggressive lymphoma: An early prognostic tool for predicting patient outcome. *Blood* 106:1376-1381, 2005
56. Markova J, Kobe C, Skopalova M, et al: FDG-PET for assessment of early treatment response after four cycles of chemotherapy in patients with advanced-stage Hodgkin's lymphoma has a high negative predictive value. *Ann Oncol* 20:1270-1274, 2009
57. Mikhaeel NG, Hutchings M, Fields PA, et al: FDG-PET after two to three cycles of chemotherapy predicts progression-free and overall survival in high-grade non-Hodgkin lymphoma. *Ann Oncol* 16:1514-1523, 2005
58. Nols N, Mounier N, Bouazza S, et al: Quantitative and qualitative analysis of metabolic response at interim PET-scan combined with IPI is highly predictive of outcome in diffuse large B-cell lymphoma. *Leuk Lymphoma* 55:773-780, 2014
59. Spaepen K, Stroobants S, Dupont P, et al: Early restaging positron emission tomography with (18)F-fluorodeoxyglucose predicts outcome in patients with aggressive non-Hodgkin's lymphoma. *Ann Oncol* 13:1356-1363, 2002
60. Barnes JA, LaCasce AS, Zukotynski K, et al: End-of-treatment but not interim PET scan predicts outcome in nonbulky limited-stage Hodgkin's lymphoma. *Ann Oncol* 22:910-915, 2011
61. Spaepen K, Stroobants S, Dupont P, et al: Prognostic value of positron emission tomography (PET) with fluorine-18 fluorodeoxyglucose (¹⁸F]FDG) after first-line chemotherapy in non-Hodgkin's lymphoma: Is [¹⁸F]FDG-PET a valid alternative to conventional diagnostic methods? *J Clin Oncol* 19:414-419, 2001
62. Elstrom R, Guan L, Baker G, et al: Utility of FDG-PET scanning in lymphoma by WHO classification. *Blood* 101:3875-3876, 2003
63. Tsukamoto N, Kojima M, Hasegawa M, et al: The usefulness of (18)F-fluorodeoxyglucose positron emission tomography ((18)F-FDG-PET) and a comparison of (18)F-FDG-pet with (67)gallium scintigraphy in the evaluation of lymphoma: Relation to histologic subtypes based on the World Health Organization classification. *Cancer* 110:652-659, 2007
64. Weiler-Sagie M, Bushelev O, Epelbaum R, et al: (18)F-FDG avidity in lymphoma readdressed: A study of 766 patients. *J Nucl Med* 51:25-30, 2010
65. Bodet-Milin C, Touzeau C, Leux C, et al: Prognostic impact of 18F-fluoro-deoxyglucose positron emission tomography in untreated mantle cell lymphoma: A retrospective study from the GOELAMS group. *Eur J Nucl Med Mol Imaging* 37:1633-1642, 2010
66. Feeney J, Horwitz S, Gönen M, et al: Characterization of T-cell lymphomas by FDG PET/CT. *AJR Am J Roentgenol* 195:333-340, 2010
67. Cahu X, Bodet-Milin C, Brissot E, et al: 18F-fluorodeoxyglucose-positron emission tomography before, during and after treatment in mature T/NK lymphomas: A study from the GOELAMS group. *Ann Oncol* 22:705-711, 2011
68. Barrington SF, O'Doherty MJ: Limitations of PET for imaging lymphoma. *Eur J Nucl Med Mol Imaging* 30:S117-S127, 2003 (suppl 1)

69. Cook GJ, Wegner EA, Fogelman I: Pitfalls and artifacts in 18FDG PET and PET/CT oncologic imaging. *Semin Nucl Med* 34:122-133, 2004
70. El-Galaly TC, d'Amore F, Mylam KJ, et al: Routine bone marrow biopsy has little or no therapeutic consequence for positron emission tomography/computed tomography-staged treatment-naive patients with Hodgkin lymphoma. *J Clin Oncol* 30:4508-4514, 2012
71. Moulin-Romsee G, Hindié E, Cuenca X, et al: (18)F-FDG PET/CT bone/bone marrow findings in Hodgkin's lymphoma may circumvent the use of bone marrow trephine biopsy at diagnosis staging. *Eur J Nucl Med Mol Imaging* 37:1095-1105, 2010
72. Richardson SE, Sudak J, Warbey V, et al: Routine bone marrow biopsy is not necessary in the staging of patients with classical Hodgkin lymphoma in the 18F-fluoro-2-deoxyglucose positron emission tomography era. *Leuk Lymphoma* 53:381-385, 2012
73. Schaefer NG, Strobel K, Taverna C, et al: Bone involvement in patients with lymphoma: The role of FDG-PET/CT. *Eur J Nucl Med Mol Imaging* 34:60-67, 2007
74. Berthet L, Cochet A, Kanoun S, et al: In newly diagnosed diffuse large B-cell lymphoma, determination of bone marrow involvement with 18F-FDG PET/CT provides better diagnostic performance and prognostic stratification than does biopsy. *J Nucl Med* 54:1244-1250, 2013
75. Mittal BR, Manohar K, Malhotra P, et al: Can fluorodeoxyglucose positron emission tomography/computed tomography avoid negative iliac crest biopsies in evaluation of marrow involvement by lymphoma at time of initial staging? *Leuk Lymphoma* 52:2111-2116, 2011
76. Ngeow JY, Quek RH, Ng DC, et al: High SUV uptake on FDG-PET/CT predicts for an aggressive B-cell lymphoma in a prospective study of primary FDG-PET/CT staging in lymphoma. *Ann Oncol* 20:1543-1547, 2009
77. Pelosi E, Penna D, Douroukas A, et al: Bone marrow disease detection with FDG-PET/CT and bone marrow biopsy during the staging of malignant lymphoma: Results from a large multicentre study. *Q J Nucl Med Mol Imaging* 55:469-475, 2011
78. Cheson BD: Hodgkin lymphoma: Protecting the victims of our success. *J Clin Oncol* 30:4456-4457, 2012
79. Khan AB, Barrington SF, Mikhaeel NG, et al: PET-CT staging of DLBCL accurately identifies and provides new insight into the clinical significance of bone marrow involvement. *Blood* 122:61-67, 2013
80. Carr R, Barrington SF, Madan B, et al: Detection of lymphoma in bone marrow by whole-body positron emission tomography. *Blood* 91:3340-3346, 1998
81. Paone G, Itti E, Haioun C, et al: Bone marrow involvement in diffuse large B-cell lymphoma: Correlation between FDG-PET uptake and type of cellular infiltrate. *Eur J Nucl Med Mol Imaging* 36:745-750, 2009
82. Chen YK, Yeh CL, Tsui CC, et al: F-18 FDG PET for evaluation of bone marrow involvement in non-Hodgkin lymphoma: A meta-analysis. *Clin Nucl Med* 36:553-559, 2011
83. O'Doherty MJ, Barrington SF, Campbell M, et al: PET scanning and the human immunodeficiency virus-positive patient. *J Nucl Med* 38:1575-1583, 1997
84. Barrington SF, Mikhaeel NG: When should FDG-PET be used in the modern management of lymphoma? *Br J Haematol* 164:315-328, 2014
85. Lin C, Itti E, Haioun C, et al: Early 18F-FDG PET for prediction of prognosis in patients with diffuse large B-cell lymphoma: SUV-based assessment versus visual analysis. *J Nucl Med* 48:1626-1632, 2007
86. Itti E, Lin C, Dupuis J, et al: Prognostic value of interim 18F-FDG PET in patients with diffuse large B-cell lymphoma: SUV-based assessment at 4 cycles of chemotherapy. *J Nucl Med* 50:527-533, 2009
87. Quarles van Ufford H, Hoekstra O, de Haas M, et al: On the added value of baseline FDG-PET in malignant lymphoma. *Mol Imaging Biol* 12:225-232, 2010
88. Meignan M, Itti E, Bardet S, et al: Development and application of a real-time on-line blinded independent central review of interim PET scans to determine treatment allocation in lymphoma trials. *J Clin Oncol* 27:2739-2741, 2009
89. Mikhaeel NG, Timothy AR, O'Doherty MJ, et al: 18-FDG-PET as a prognostic indicator in the treatment of aggressive Non-Hodgkin's Lymphoma-comparison with CT. *Leuk Lymphoma* 39:543-553, 2000
90. Mikhaeel NG: Interim fluorodeoxyglucose positron emission tomography for early response assessment in diffuse large B cell lymphoma: Where are we now? *Leuk Lymphoma* 50:1931-1936, 2009
91. Fuertes S, Setoan X, Lopez-Guillermo A, et al: Interim FDG PET/CT as a prognostic factor in diffuse large B-cell lymphoma. *Eur J Nucl Med Mol Imaging* 40:496-504, 2013
92. Le Roux PY, Gastinne T, Le Gouill S, et al: Prognostic value of interim FDG PET/CT in Hodgkin's lymphoma patients treated with interim response-adapted strategy: Comparison of International Harmonization Project (IHP), Gallamini and London criteria. *Eur J Nucl Med Mol Imaging* 38:1064-1071, 2011
93. Itti E, Meignan M, Berriolo-Riedinger A, et al: An international confirmatory study of the prognostic value of early PET/CT in diffuse large B-cell lymphoma: Comparison between Deauville criteria and δ SUVmax. *Eur J Nucl Med Mol Imaging* 40:1312-1320, 2013
94. Martelli M, Ceriani L, Zucca E, et al: [18 F]Fluorodeoxyglucose positron emission tomography predicts survival after chemoimmunotherapy for primary mediastinal large B-cell lymphoma: Results of the International Extranodal Lymphoma Study Group IELSG-26 Study. *J Clin Oncol* [epub ahead of print on May 5, 2014]
95. Fondazione Italiana Linfomi: A multicenter, phase III, randomized study to evaluate the efficacy of a response-adapted strategy to define maintenance after standard chemoimmunotherapy in patients with advanced-stage follicular lymphoma: FIL FOLL12—Update 07/13. https://www.clinicaltrialsregister.eu/ctr-search/search?query=eudract_number:2012-003170-60
96. Spectrum Pharmaceuticals: Study of zevalin versus observation in patients at least 60 yrs old with newly diagnosed diffuse large B-cell lymphoma in PET-negative complete remission after R-CHOP or R-CHOP-like therapy: 11/13 update. <http://www.clinicaltrials.gov/ct2/show/NCT01510184>
97. Lymphoma Academic Research Organisation: Study evaluating the non-inferiority of a treatment adapted to the early response evaluated with 18F-FDG PET compared to a standard treatment, for patients aged from 18 to 80 years with low risk (aa IPI = 0) diffuse large B-cells non Hodgkin's lymphoma CD 20+: Update 10/13. <http://www.clinicaltrials.gov/ct2/show/NCT01285765>
98. Furth C, Amthauer H, Hautzel H, et al: Evaluation of interim PET response criteria in paediatric Hodgkin's lymphoma—results for dedicated assessment criteria in a blinded dual-centre read. *Ann Oncol* 22:1198-1203, 2011
99. Mamot C, Klingbiel D, Renner C, et al: Final results of a prospective evaluation of the predictive value of interim PET in patients with DLBCL under R-CHOP-14 (SAKK 38/07). *Hematol Oncol* 31:100-101, 2013 (suppl 1; abst 15)
100. Itti E, Berriolo-Riedinger A, Biggi A, et al: An international validation study of the prognostic role of interim FDG PET/CT in diffuse large B-cell lymphoma. *Eur J Nucl Med Mol Imaging* 40:1312-1320, 2013
101. de Langen AJ, Vincent A, Velasquez LM, et al: Repeatability of 18F-FDG uptake measurements in tumors: A metaanalysis. *J Nucl Med* 53:701-708, 2012
102. Wahl RL, Jacene H, Kasamon Y, et al: From RECIST to PERCIST: Evolving considerations for PET response criteria in solid tumors. *J Nucl Med* 50:122S-150S, 2009 (suppl 1)
103. Roy FN, Beaulieu S, Boucher L, et al: Impact of intravenous insulin on 18F-FDG PET in diabetic cancer patients. *J Nucl Med* 50:178-183, 2009
104. Lister TA, Crowther D, Sutcliffe SB, et al: Report of a committee convened to discuss the evaluation and staging of patients with Hodgkin's disease: Cotswolds meeting. *J Clin Oncol* 7:1630-1636, 1989
105. Hasenclever D, Diehl V: A prognostic score for advanced Hodgkin's disease: International Prognostic Factors Project on advanced Hodgkin's disease. *N Engl J Med* 339:1506-1514, 1998
106. Bangerter M, Moog F, Buchmann I, et al: Whole-body 2-[18F]fluoro-2-deoxy-D-glucose positron emission tomography (FDG-PET) for accurate staging of Hodgkin's disease. *Ann Oncol* 9:1117-1122, 1998
107. Partridge S, Timothy A, O'Doherty MJ, et al: 2-Fluorine-18-fluoro-2-deoxy-D glucose positron emission tomography in the pretreatment staging of Hodgkin's disease: Influence on patient management in a single institution. *Ann Oncol* 11:1273-1279, 2000
108. Jerusalem G, Beguin Y, Fassotte MF, et al: Whole-body positron emission tomography using 18F-fluorodeoxyglucose compared to standard procedures for staging patients with Hodgkin's disease. *Haematologica* 86:266-273, 2001
109. Wehrauch MR, Re D, Bischoff S, et al: Whole-body positron emission tomography using 18F-fluorodeoxyglucose for initial staging of patients with Hodgkin's disease. *Ann Hematol* 81:20-25, 2002
110. Munker R, Glass J, Griffith LK, et al: Contribution of PET imaging to the initial staging and prognosis of patients with Hodgkin's disease. *Ann Oncol* 15:1699-1704, 2004
111. Naumann R, Beuthien-Baumann B, Reiss A, et al: Substantial impact of FDG PET imaging on the therapy decision in patients with early-stage Hodgkin's lymphoma. *Br J Cancer* 90:620-625, 2004
112. Buchmann I, Reinhardt M, Elsner K, et al: 2-(fluorine-18)fluoro-2-deoxy-D-glucose positron emission tomography in the detection and staging of malignant lymphoma: A bicenter trial. *Cancer* 91:889-899, 2001
113. Wirth A, Seymour JF, Hicks RJ, et al: Fluorine-18 fluorodeoxyglucose positron emission

tomography, gallium-67 scintigraphy, and conventional staging for Hodgkin's disease and non-Hodgkin's lymphoma. *Am J Med* 112:262-268, 2002

114. Schöder H, Noy A, Gönen M, et al: Intensity of [18F]fluorodeoxyglucose uptake in positron emission tomography distinguishes between indolent and aggressive non-Hodgkin's lymphoma. *J Clin Oncol* 23:4643-4651, 2005

115. Watanabe R, Tomita N, Takeuchi K, et al: SUVmax in FDG-PET at the biopsy site correlates with the proliferation potential of tumor cells in non-Hodgkin lymphoma. *Leuk Lymphoma* 51:279-283, 2010

116. Schaefer NG, Hany TF, Taverna C, et al: Non-Hodgkin lymphoma and Hodgkin disease: Coregistered FDG PET and CT at staging and restaging—Do we need contrast-enhanced CT? *Radiology* 232:823-829, 2004

117. Gollub MJ, Hong R, Sarasohn DM, et al: Limitations of CT during PET/CT. *J Nucl Med* 48:1583-1591, 2007

118. Pinilla I, Gómez-León N, Del Campo-Del Val L, et al: Diagnostic value of CT, PET and combined PET/CT performed with low-dose unenhanced CT and full-dose enhanced CT in the initial staging of lymphoma. *Q J Nucl Med Mol Imaging* 55:567-575, 2011

119. Chalaye J, Luciani A, Enache C, et al: Clinical impact of contrast-enhanced computed tomography combined with low-dose 18F-fluorodeoxyglucose positron emission tomography/computed tomography on routine lymphoma patient management. *Leuk Lymphoma* [epub ahead of print on April 3, 2014]

120. Hoskin PJ, Díez P, Williams M, et al: Recommendations for the use of radiotherapy in nodal lymphoma. *Clin Oncol (R Coll Radiol)* 25:49-58, 2013

121. Vriens D, Visser EP, de Geus-Oei LF, et al: Methodological considerations in quantification of oncological FDG PET studies. *Eur J Nucl Med Mol Imaging* 37:1408-1425, 2010

122. Berthelsen AK, Holm S, Loft A, et al: PET/CT with intravenous contrast can be used for PET attenuation correction in cancer patients. *Eur J Nucl Med Mol Imaging* 32:1167-1175, 2005

123. Eichenauer DA, Engert A, Dreyling M: Hodgkin's lymphoma: ESMO Clinical Practice Guidelines for diagnosis, treatment and follow-up. *Ann Oncol* 22:vi55-vi58, 2011 (suppl 6)

124. Pfreundschuh M, Kuhnt E, Trümper L, et al: CHOP-like chemotherapy with or without rituximab in young patients with good-prognosis diffuse large-B-cell lymphoma: 6-year results of an open-label randomised study of the MabThera International Trial (MInT) Group. *Lancet Oncol* 12:1013-1022, 2011

125. Miller TP: The limits of limited stage lymphoma. *J Clin Oncol* 22:2982-2984, 2004

126. Coiffier B, Lepage E, Briere J, et al: CHOP chemotherapy plus rituximab compared with CHOP alone in elderly patients with diffuse large-B-cell lymphoma. *N Engl J Med* 346:235-242, 2002

127. Federico M, Bellei M, Marcheselli L, et al: Follicular Lymphoma International Prognostic Index 2: A new prognostic index for follicular lymphoma developed by the International Follicular Lymphoma Prognostic Factor Project. *J Clin Oncol* 27:4555-4562, 2009

128. Yan J, Zhao B, Wang L, et al: Marker-controlled watershed for lymphoma segmentation in sequential CT images. *Med Phys* 33:2452-2460, 2006

129. Yan J, Zhuang TG, Zhao B, et al: Lymph node segmentation from CT images using fast marching

method. *Comput Med Imaging Graph* 28:33-38, 2004

130. Manohar K, Mittal BR, Bhattacharya A, et al: Prognostic value of quantitative parameters derived on initial staging 18F-fluorodeoxyglucose positron emission tomography/computed tomography in patients with high-grade non-Hodgkin's lymphoma. *Nucl Med Commun* 33:974-981, 2012

131. Kim TM, Paeng JC, Chun IK, et al: Total lesion glycolysis in positron emission tomography is a better predictor of outcome than the International Prognostic Index for patients with diffuse large B cell lymphoma. *Cancer* 119:1195-1202, 2013

132. Kostakoglu L, Goldsmith SJ, Leonard JP, et al: FDG-PET after 1 cycle of therapy predicts outcome in diffuse large cell lymphoma and classic Hodgkin disease. *Cancer* 107:2678-2687, 2006

133. Terasawa T, Lau J, Bardet S, et al: Fluorine-18-fluorodeoxyglucose positron emission tomography for interim response assessment of advanced-stage Hodgkin's lymphoma and diffuse large B-cell lymphoma: A systematic review. *J Clin Oncol* 27:1906-1914, 2009

134. Hagberg H, Gisselbrecht C: Randomised phase III study of R-ICE versus R-DHAP in relapsed patients with CD20 diffuse large B-cell lymphoma (DLBCL) followed by high-dose therapy and a second randomisation to maintenance treatment with rituximab or not: An update of the CORAL study. *Ann Oncol* 17:iv31-iv32, 2006 (suppl 4)

135. Cashen AF, Dehdashti F, Luo J, et al: (18)F-FDG PET/CT for early response assessment in diffuse large B-cell lymphoma: Poor predictive value of International Harmonization Project interpretation. *J Nucl Med* 52:386-392, 2011

136. Yoo C, Lee DH, Kim JE, et al: Limited role of interim PET/CT in patients with diffuse large B-cell lymphoma treated with R-CHOP. *Ann Hematol* 90:797-802, 2011

137. Yang DH, Ahn JS, Byun BH, et al: Interim PET/CT-based prognostic model for the treatment of diffuse large B cell lymphoma in the post-rituximab era. *Ann Hematol* 92:471-479, 2013

138. Sehn LH, Donaldson J, Chhanabhai M, et al: Introduction of combined CHOP plus rituximab therapy dramatically improved outcome of diffuse large B-cell lymphoma in British Columbia. *J Clin Oncol* 23:5027-5033, 2005

139. Casanovas RO, Meignan M, Berriolo-Riedinger A, et al: SUVmax reduction improves early prognostic value of interim positron emission tomography scans in diffuse large B-cell lymphoma. *Blood* 118:37-43, 2011

140. Boellaard R: Need for standardization of 18F-FDG PET/CT for treatment response assessments. *J Nucl Med* 52:93S-100S, 2011 (suppl 2)

141. Kostakoglu L, Schöder H, Johnson JL, et al: Interim [(18)F]fluorodeoxyglucose positron emission tomography imaging in stage I-III non-bulky Hodgkin lymphoma: Would using combined positron emission tomography and computed tomography criteria better predict response than each test alone? *Leuk Lymphoma* 53:2143-2150, 2012

142. Song MK, Chung JS, Shin HJ, et al: Clinical significance of metabolic tumor volume by PET/CT in stages II and III of diffuse large B cell lymphoma without extranodal site involvement. *Ann Hematol* 91:697-703, 2012

143. UK Clinical Research Network: Blinded evaluation of prognostic value of FDG-PET after 2 cycles of chemotherapy in diffuse large B-cell non-Hodgkin's lymphoma: Update 09/12. <http://public.ukcrn.org.uk/search/StudyDetail.aspx?StudyID=1760>

144. Zijlstra JM, Lindauer-van der Werf G, Hoekstra OS, et al: F-18-fluoro-deoxyglucose positron emission tomography for post-treatment evaluation of malignant lymphoma: A systematic review. *Haematologica* 91:522-529, 2006

145. Mikhaeel NG, Timothy AR, Hain SF, et al: 18-FDG-PET for the assessment of residual masses on CT following treatment of lymphomas. *Ann Oncol* 11:147-150, 2000 (suppl 1)

146. Dupuis J, Itti E, Rahmouni A, et al: Response assessment after an inductive CHOP or CHOP-like regimen with or without rituximab in 103 patients with diffuse large B-cell lymphoma: Integrating (18)fluorodeoxyglucose positron emission tomography to the International Workshop Criteria. *Ann Oncol* 20:503-507, 2009

147. Reinhardt MJ, Herkel C, Althoefer C, et al: Computed tomography and 18F-FDG positron emission tomography for therapy control of Hodgkin's and non-Hodgkin's lymphoma patients: When do we really need FDG-PET? *Ann Oncol* 16:1524-1529, 2005

148. Magagnoli M, Marzo K, Balzarotti M, et al: Dimension of residual CT scan mass in Hodgkin's lymphoma (HL) is a negative prognostic factor in patients with PET negative after chemo +/- radiotherapy. *Blood* 118, 2011 (abstr 93)

149. Dabaja BS, Phan J, Mawlawi O, et al: Clinical implications of positron emission tomography-negative residual computed tomography masses after chemotherapy for diffuse large B-cell lymphoma. *Leuk Lymphoma* 54:2631-2638, 2013

150. Savage KJ, Connors JM, Klasa RJ, et al: The use of FDG-PET to guide consolidative radiotherapy in patients with advanced-stage Hodgkin lymphoma with residual abnormalities on CT scan following ABVD chemotherapy. *J Clin Oncol* 29:512s, 2011 (suppl; abstr 8034)

151. Barrington SF, Mikhaeel NG: Imaging follicular lymphoma using positron emission tomography with [(18)F]fluorodeoxyglucose: To what purpose? *J Clin Oncol* 30:4285-4287, 2012

152. Svoboda J, Andreadis C, Elstrom R, et al: Prognostic value of FDG-PET scan imaging in lymphoma patients undergoing autologous stem cell transplantation. *Bone Marrow Transplant* 38:211-216, 2006

153. Schot BW, Zijlstra JM, Sluiter WJ, et al: Early FDG-PET assessment in combination with clinical risk scores determines prognosis in recurring lymphoma. *Blood* 109:486-491, 2007

154. Jabbour E, Hosing C, Ayers G, et al: Pretransplant positive positron emission tomography/gallium scans predict poor outcome in patients with recurrent/refractory Hodgkin lymphoma. *Cancer* 109:2481-2489, 2007

155. Moskowitz AJ, Yahalom J, Kewalramani T, et al: Pretransplantation functional imaging predicts outcome following autologous stem cell transplantation for relapsed and refractory Hodgkin lymphoma. *Blood* 116:4934-4937, 2010

156. Smeltzer JP, Cashen AF, Zhang Q, et al: Prognostic significance of FDG-PET in relapsed or refractory classical Hodgkin lymphoma treated with standard salvage chemotherapy and autologous stem cell transplantation. *Biol Blood Marrow Transplant* 17:1646-1652, 2011

157. Sucak GT, Özkurt ZN, Suyani E, et al: Early post-transplantation positron emission tomography in patients with Hodgkin lymphoma is an independent prognostic factor with an impact on overall survival. *Ann Hematol* 90:1329-1336, 2011

158. Terasawa T, Dahabreh IJ, Nihashi T: Fluorine-18-fluorodeoxyglucose positron emission

tomography in response assessment before high-dose chemotherapy for lymphoma: A systematic review and meta-analysis. *Oncologist* 15:750-759, 2010

159. Thomson KJ, Kayani I, Ardeshta K, et al: A response-adjusted PET-based transplantation strategy in primary resistant and relapsed Hodgkin lymphoma. *Leukemia* 27:1419-1422, 2013

160. Moskowitz CH, Matasar MJ, Zelenetz AD, et al: Normalization of pre-ASCT, FDG-PET imag-

ing with second-line, non-cross-resistant, chemotherapy programs improves event-free survival in patients with Hodgkin lymphoma. *Blood* 119:1665-1670, 2012

161. Hutchings M: Pre-transplant positron emission tomography/computed tomography (PET/CT) in relapsed Hodgkin lymphoma: Time to shift gears for PET-positive patients? *Leuk Lymphoma* 52:1615-1616, 2011

162. Dunleavy K, Pittaluga S, Maeda LS, et al: Dose-adjusted EPOCH-rituximab therapy in primary

mediastinal B-cell lymphoma. *N Engl J Med* 368:1408-1416, 2013

163. Zinzani PL: PET in T-cell lymphoma. *Curr Hematol Malig Rep* 6:241-244, 2011

164. Otero HJ, Jagannathan JP, Prevedello LM, et al: CT and PET/CT findings of T-cell lymphoma. *AJR Am J Roentgenol* 193:349-358, 2009

165. Casulo C, Schöder H, Feeney J, et al: FDG-PET in the staging and prognosis of T cell lymphoma. *Leuk Lymphoma* 54:2163-2167, 2013



ASCO's Quality Assessment Tool for Community Research Programs

As part of ASCO's mission to ensure the highest quality of cancer care and research, the Community Research Forum has developed the **ASCO Research Program Quality Assessment Tool**. Access the tool today to learn about key components of an internal quality assessment program, conduct a quality assessment of your site, and use the checklist tool, templates, references, and resources.

Visit asco.org/communityresearchforum for more information.



Acknowledgment

Presented in part at the Fourth International Workshop on Positron Emission Tomography in Lymphoma, Menton, France, October 3-5, 2012, and 12th International Conference on Malignant Lymphomas, Lugano, Switzerland, June 19-22, 2013.

We thank R. Boellaard, D. Caballero, L. Ceriani, M. Coronado, F. Cicone, A. Gallamini, M. Greganin, E. Itti, T.A. Lister, C. Moskowitz, H. Schöder, and J. Zijlstra for their contributions to improve the manuscript; Paul Smith, tumor group lead (hematology and brain trials), Cancer Research United Kingdom and University College London Cancer Trials Centre, and the UK National Cancer Research Institute Lymphoma Clinical Study Group for assistance with funding the imaging task group meeting in London, United Kingdom, in 2012; and the European School of Oncology and European Society for Medical Oncology for their support of the workshops at the International Conference on Malignant Lymphoma in 2011 and 2013.

Appendix

Table A1. Studies Including ≥ 50 Patients With HL Reporting Outcomes According to Visual Assessment With Interim PET

Study	Year	No. of Patients	Disease Stage	Chemotherapy	No. of Cycles Before PET	No. PET Negative	PFS/EFS		
							At (years)	PET Negative (%)	PET Positive (%)
Hutchings et al ¹⁹	2005	85	I-IV	Mostly ABVD (n = 79)	2-3	72	5	92	39
Hutchings et al ^{20*}	2006	77	I-IV	Mostly ABVD (n = 70)	2	61	2	96	0
Gallamini et al ^{22*}	2007	260	IIB-IV	Mostly ABVD (n = 249)	2	210	2	96	6
Markova et al ⁵⁶	2009	50	IIB-IV	BEACOPP	4	36	2	97	86
Cerci et al ^{23*}	2010	104	I-IV	ABVD	2	74	3	90	53
Barnes et al ⁶⁰	2011	96	I-II (nonbulky)	ABVD	2-4	79	4	91	87
Zinzani et al ²⁴	2012	304	I-IIA (n = 147)	ABVD	2	128	9	95	31
			IIB-IV (n = 157)		2	123	9	89	29
Biggi et al ²⁵	2013	260	IIB-IV	ABVD	2	215	3	95	28

Abbreviation: ABVD, doxorubicin, bleomycin, vinblastine, and dacarbazine; BEACOPP, bleomycin, etoposide, doxorubicin, cyclophosphamide, vincristine, procarbazine, and prednisone; EFS, event-free survival; HL, Hodgkin lymphoma; PET, positron emission tomography; PFS, progression-free survival.

*Prospective study.

Table A2. Studies Including ≥ 50 Patients With Aggressive NHL Reporting Outcomes According to Visual Assessment With Interim PET

Study	Year	No. of Patients	Chemotherapy	No. of Cycles of Therapy	No. PET Negative	PFS/EFS		
						At (years)	PET Negative (%)	PET Positive (%)
Spaepen et al ⁵⁹	2002	70	Mostly CHOP (n = 56)	3-4	37	2	85	0
Haioun et al ⁵⁵	2005	90	CHOP or ACVBP/ACE (n = 53) plus rituximab (n = 37)	2	54	2	82	43
Mikhaeel et al ⁵⁷	2005	121	Mostly CHOP (n = 97)	2-3	69	5	89	16
Cashen et al ^{135*}	2011	50	R-CHOP	2-3	26	2	85	63
Micallef et al ^{32*}	2011	76	ER-CHOP	2	60	2	73	60
Yang et al ^{28*}	2011	159	R-CHOP	3-4	116	3	86	29
Yoo et al ¹³⁶	2011	155	R-CHOP	2-4	100	3	84	66
Zinzani et al ²⁹	2011	91	Mostly R-CHOP (n = 66), rituximab (n = 91)	Midtreatment	56	5	75	18
Safar et al ³¹	2012	112	R-CHOP (n = 81), R-ACVBP (n = 31)	2	70	3	84	47
Pregno et al ³⁰	2012	88	R-CHOP	2-4	66	2	85	72
Nols et al ⁵⁸	2013	73	R-CHOP (n = 48), R-miniCHOP (n = 8), ACVBP (n = 17), CHOP (n = 1)	3-4	53	2	84	47

Abbreviations: ACE, doxorubicin, cyclophosphamide, and etoposide; ACVBP, doxorubicin, cyclophosphamide, vincristine, bleomycin, and prednisone; CHOP, cyclophosphamide, doxorubicin, vincristine, and prednisone; E, etoposide; EFS, event-free survival; NHL, non-Hodgkin lymphoma; PET, positron emission tomography; PFS, progression-free survival; R, rituximab.

*Prospective study.

Table A3. Studies, Including ≥ 50 With Homogenous Patient Populations With HL or Aggressive NHL or FL, Reporting Outcomes According to Visual Assessment With End-of-Treatment PET

Study	Year	No. of Patients	Disease and Stage	No. PET Negative	NPV	PPV	FTF/PFS at (years)	PFS/EFS	
								PET Negative (%)	PET Positive (%)
Spaepen K et al: Br J Haematol 115:272-278, 2001	2001	60	IIA-IVB HL	55	100	91	2	91	0
Cerci et al ^{26*}	2010	50	I-IV HL (patients in CRu/PR on CT)	23	100	92	—	NS	NS
Engert et al ^{27*} †	2012	739	IIB-IV HL	548	95	NA	5	92	86†
Barnes et al ⁶⁰	2011	96	I-II nonbulky HL	83	94	46	4	94	54
Spaepen et al ⁶¹	2001	93	Aggressive NHL	50	100	70	—	NS	NS
Micallef et al ^{32*}	2011	69	DLBCL	61	90	50	2	78	50
Pregno et al ³⁰	2012	88	DLBCL	77	100	82	2	83	64
Trotman et al ³³	2011	122	High-tumor burden FL	90	NS	NS	3.5	71	33
Dupuis et al ^{34*}	2012	106	High-tumor burden FL	83	NS	NS	2	87	51

Abbreviations: CRu, unconfirmed complete response; CT, computed tomography; DLBCL, diffuse large B-cell lymphoma; EFS, event-free survival; FL, follicular lymphoma; FTF, freedom from treatment failure; HL, Hodgkin lymphoma; NA, not applicable; NHL, non-Hodgkin lymphoma; NPV, negative predictive value; NS, not stated; PET, positron emission tomography; PFS, progression-free survival; PPV, positive predictive value; PR, partial response.

*Prospective study.

†Treatment guided by end-of-treatment PET.

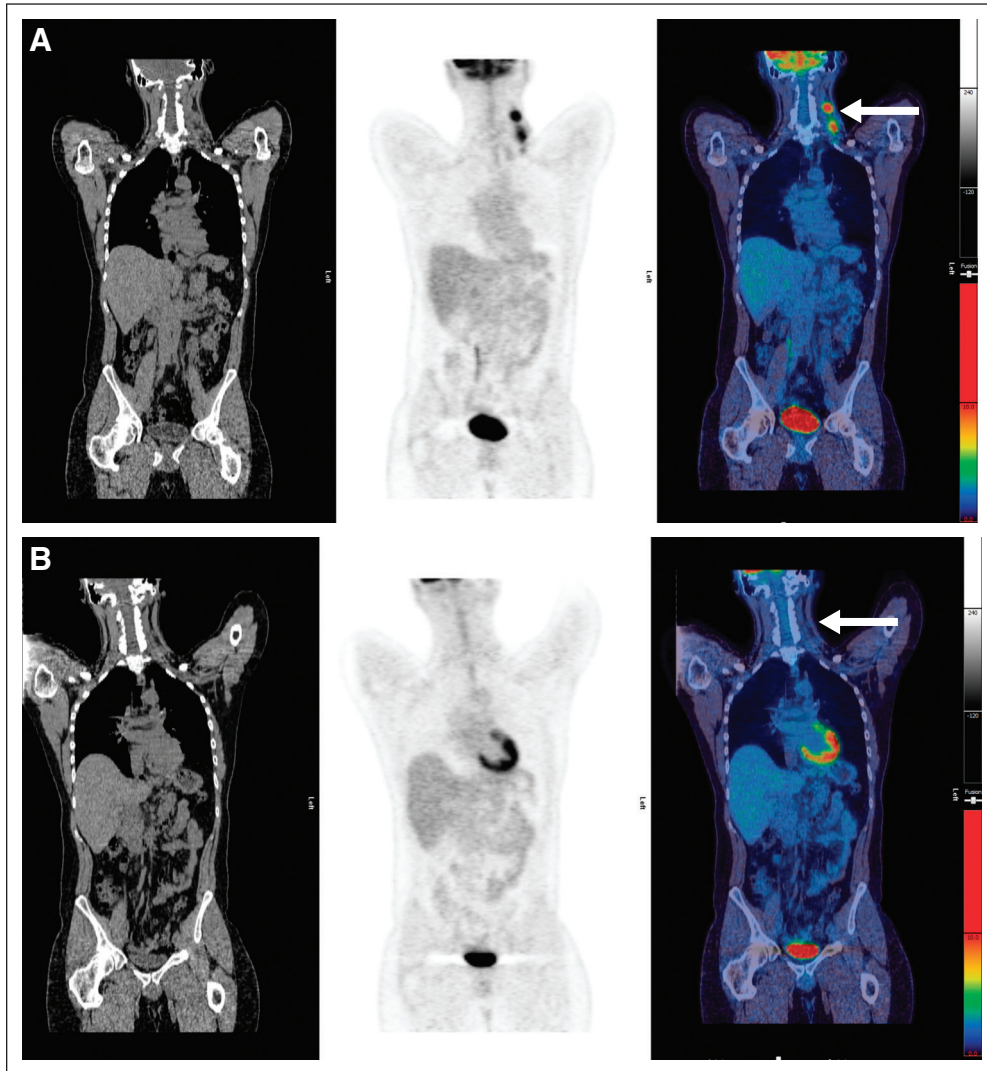


Fig A1. (A) Pretreatment scan: computed tomography, positron emission tomography, and fused images showing disease in left neck (arrow). (B) Example of score 1: complete metabolic response with no uptake in normal-size lymph nodes at site of initial disease in left neck (arrow).

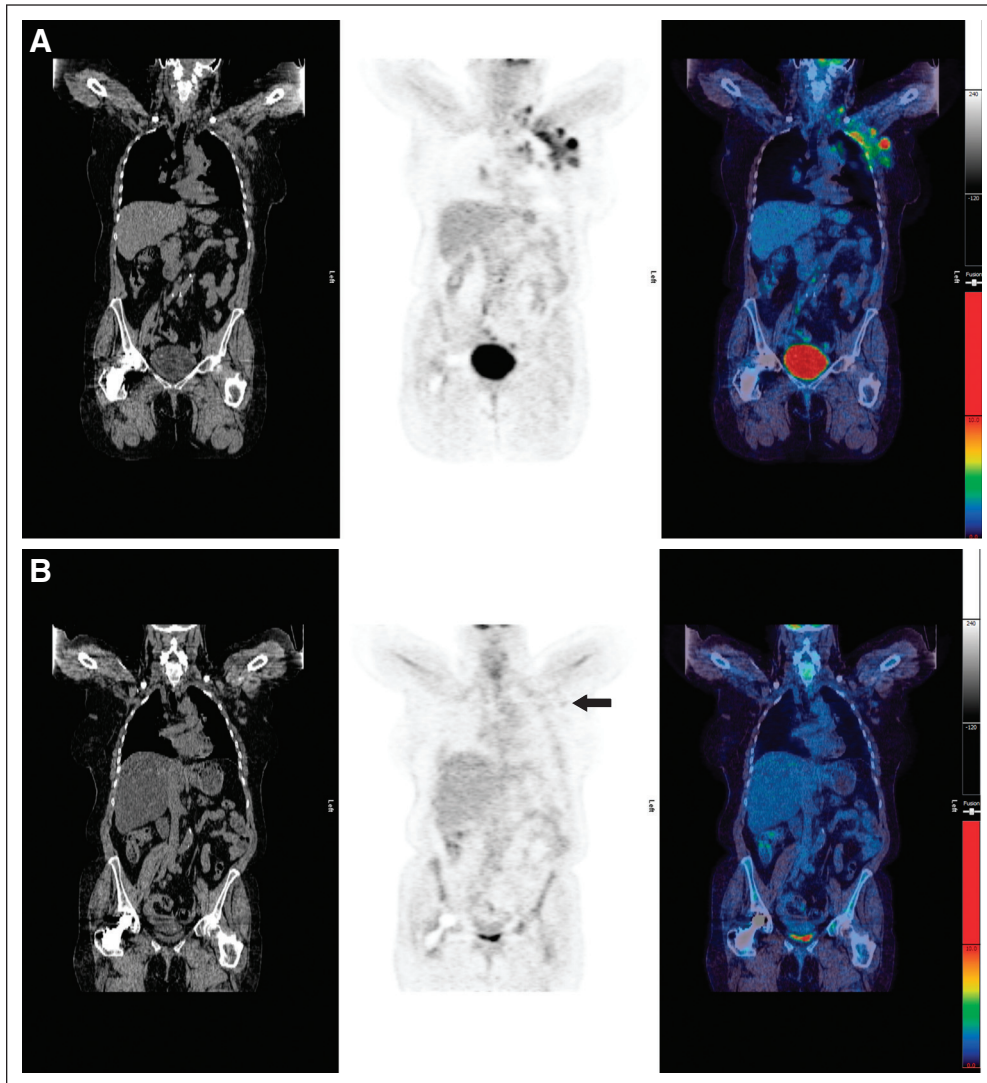


Fig A2. (A) Pretreatment scan: computed tomography, positron emission tomography, and fused images showing disease in left axilla. (B) Example of score 2: residual uptake of intensity < mediastinal blood pool in lymph nodes in left axilla (arrow). Maximum standardized uptake value (SUVmax) in lymph nodes was 1.2; SUVmax in mediastinal blood pool was 1.7.

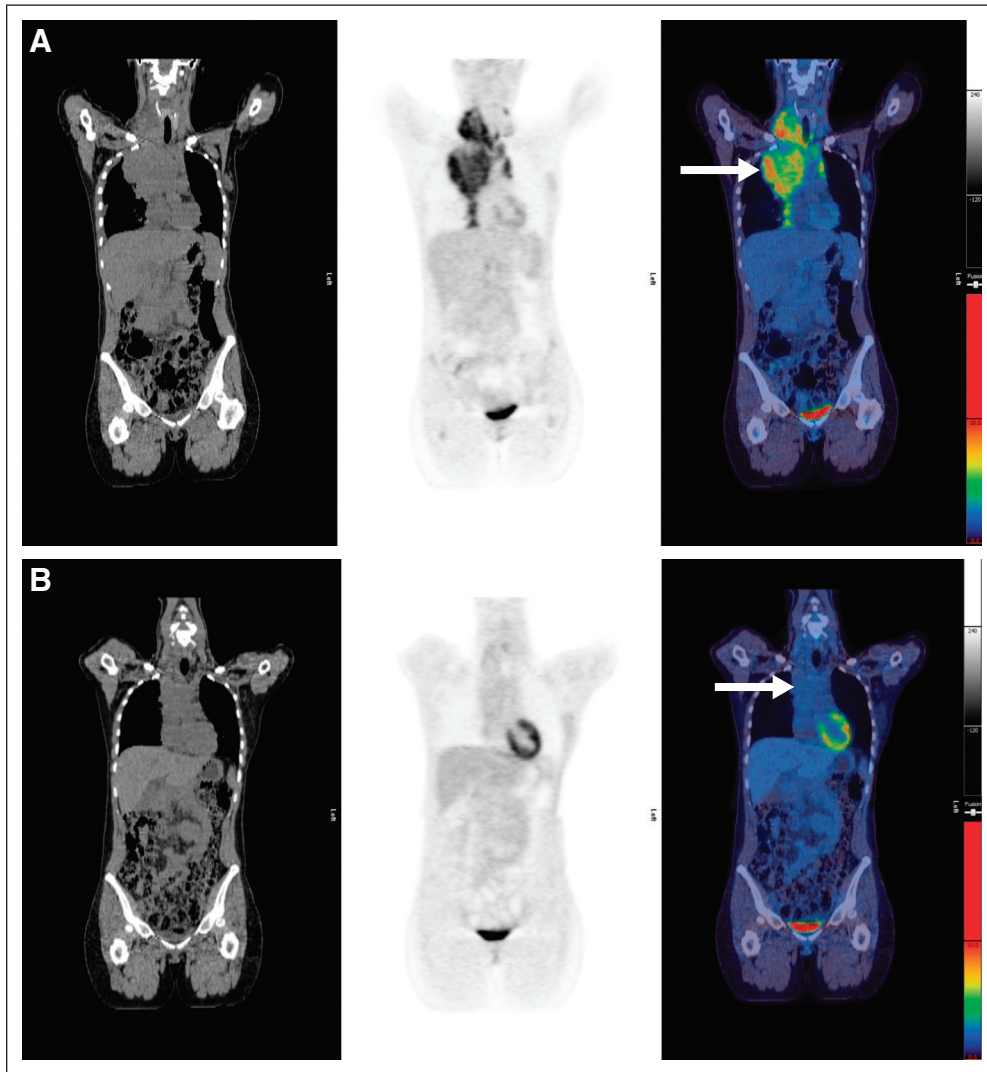


Fig A3. (A) Pretreatment scan: computed tomography, positron emission tomography, and fused images showing disease in right neck and mediastinum (arrow). (B) Example of score 3: residual uptake of intensity > mediastinal blood pool but < liver in residual mediastinal mass (arrow). Maximum standardized uptake value (SUVmax) in mass was 1.7; SUVmax in liver was 2.2.

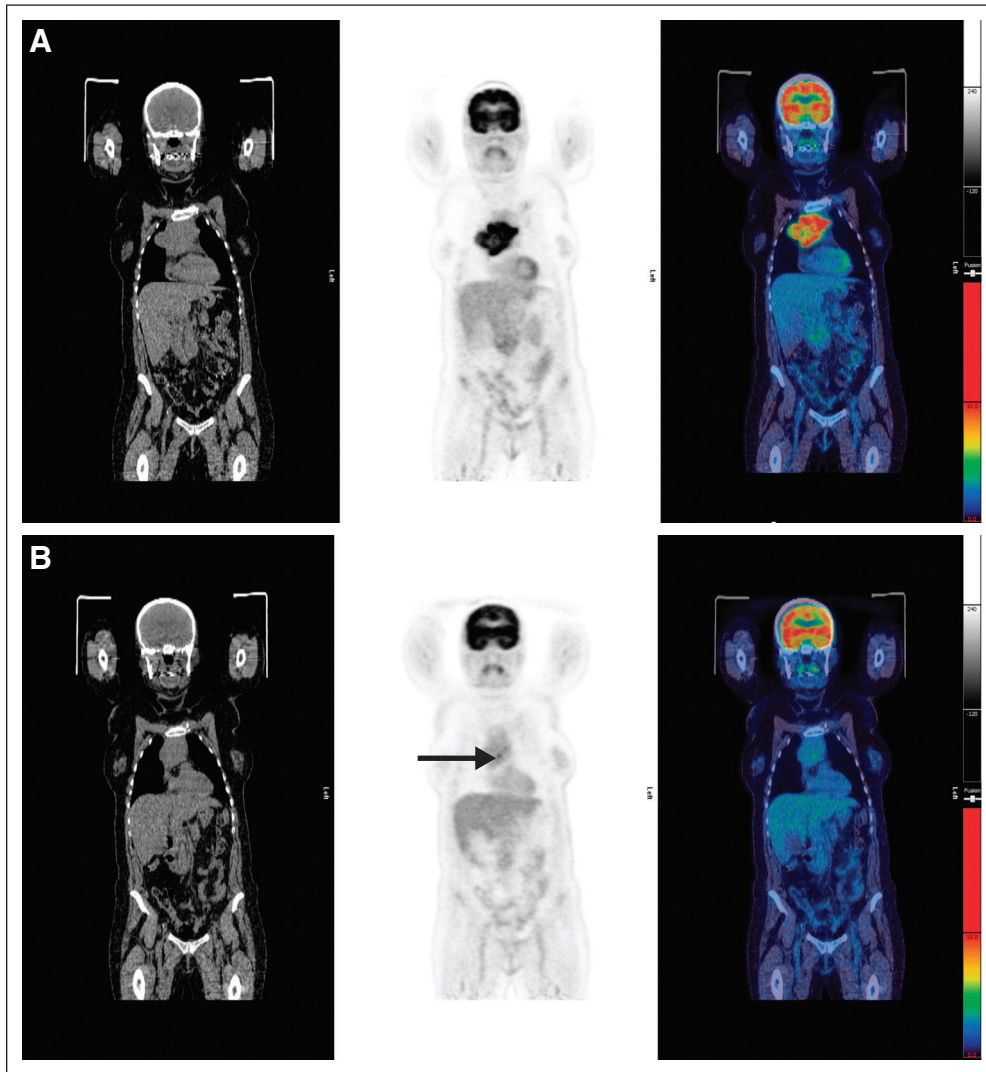


Fig A4. (A) Pretreatment scan: computed tomography, positron emission tomography, and fused images showing disease in mediastinum. (B) Example of score 4: residual uptake of intensity > liver in residual mediastinal mass (arrow). Maximum standardized uptake value (SUVmax) in mass was 4.5; SUVmax in liver was 3.2.

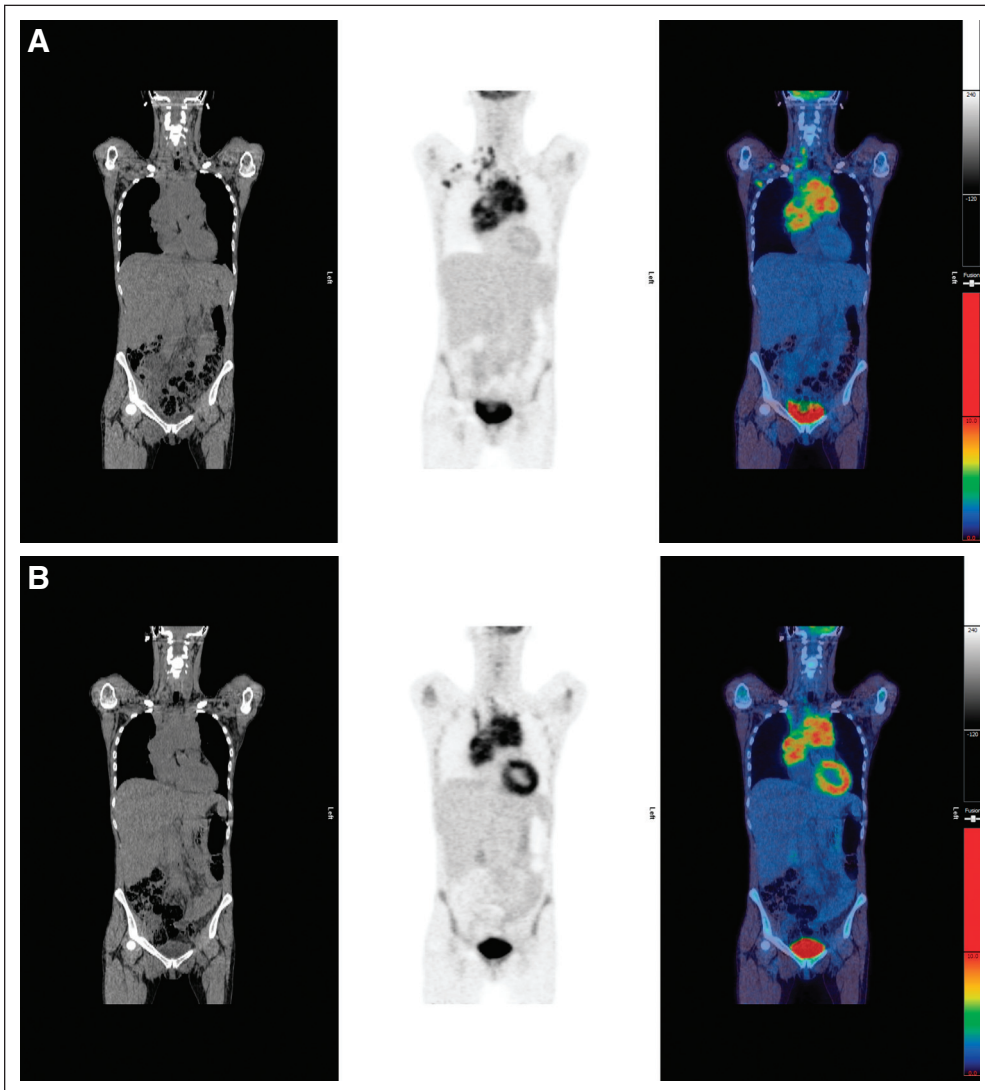


Fig A5. (A) Pretreatment scan: computed tomography, positron emission tomography, and fused images showing disease in right neck, mediastinum, and right axilla. (B) Example of score 5: residual uptake in mediastinum with intensity markedly higher than normal liver. Maximum standardized uptake value (SUVmax) in mass was 13.0; SUVmax in liver was 2.3.