

# Immunohistochemical study of thrombospondin and its receptors $\alpha\beta3$ and CD36 in normal thyroid and in thyroid tumours

M Patey, B Delemer, G Bellon, L Martiny, M Pluot, B Haye

## Abstract

**Aim**—To describe the pattern of distribution of thrombospondin (TSP1) and its receptors,  $\alpha\beta3$  integrin and CD36, in normal human thyroid tissue and to compare their expression in different benign and malignant thyroid conditions.

**Methods**—Immunohistochemistry was used to study TSP1 and its receptors in 40 surgical thyroidectomy specimens (normal parenchyma, 7; follicular adenoma, 4; multinodular goitre, 13; papillary carcinoma, 6; follicular carcinoma, 8; anaplastic carcinoma, 2).

**Results**—In the normal thyroid parenchyma, there was weak expression of TSP1 limited to the vessels with no staining of the extracellular matrix. In goitres, the expression of TSP1 was more pronounced in areas of fibrosis, with staining of  $\alpha\beta3$  on thyrocytes located in the vicinity. In thyroid adenomas, expression of TSP1 was slightly enhanced compared with normal tissue, located in the basement membrane of vessels. In papillary carcinomas, TSP1 was abundant in the desmoplastic stroma with a cytoplasmic distribution of  $\alpha\beta3$  integrin in thyrocytes. In follicular carcinomas, TSP1 was less abundant in the extracellular matrix, limited to the vessels of the stroma with a weaker expression of  $\alpha\beta3$  on thyrocytes than in papillary carcinomas. In anaplastic carcinomas, TSP1 was only present in the numerous capillaries of the stroma, with a marked positivity for  $\alpha\beta3$  in one case. No immunostaining of thyrocytes is observed with CD36.

**Conclusions**—These results suggest the importance of the interaction between  $\alpha\beta3$  integrin and TSP1 during remodeling of the matrix in fibrous goitres with areas of early sclerosis comparable with wound healing. In papillary carcinomas, the overexpression of TSP1 restricted to the stroma suggests protective effects against tumour progression.

(J Clin Pathol 1999;52:895-900)

**Keywords:** thyroid neoplasms; thrombospondin;  $\alpha\beta3$  receptor; immunohistochemistry

Thrombospondin (TSP) is a large trimeric modular glycoprotein that is a major component of platelet  $\alpha$  granules.<sup>1</sup> TSP possesses at least four adhesive domains or sequences including a heparin binding amino terminal, a CSVTCG-sequence (Cys-Ser-Val-Thr-Cys-Gly), an

RGD sequence (Arg-Gly-Asp), and a carboxy terminal domain.<sup>2,3</sup> The CSVTCG sequence is responsible for the interaction of TSP with CD36 (GP IV).<sup>4</sup>

CD36 was the first non-integrin receptor for TSP1 to be described. Expression of CD36 on cells is not always correlated with an increase in TSP1 binding as specific conformation of phosphorylation states of CD36 is required for the binding.<sup>5</sup>

The deduced amino acid sequence of TSP1 revealed the presence of an RGDA sequence immediately distal to the calcium binding region of the protein.<sup>6</sup> Lawler and colleagues have evaluated the effect of the RGD peptide on the interactions between TSP1 and its receptors in a variety of cells including human endothelial cells and platelets.<sup>7,8</sup> They observed that the interaction of cells with TSP is mediated by RGD as well as by calcium dependent mechanisms. They reported that TSP is specifically yielded on the receptor of vitronectin, the  $\alpha\beta3$  integrin. The  $\alpha\beta3$  is present in a variety of cells that bind TSP and serves as cellular receptor for this molecule.<sup>8</sup> Its expression has been directly related to the tumorigenicity of malignant cells.<sup>9</sup>

TSP1 is a modulator of angiogenesis, with complex pleiotropic effects on endothelial cells.<sup>10</sup> Tuszynski and Nicosia hypothesised that TSP1 promotes angiogenesis by stimulating myofibroblasts, which in turn produce angiogenic factors.<sup>10</sup> TSP1 promotes the adhesion and motility of a number of cell lines in vitro.<sup>11</sup>

TSP is synthesised and secreted by a variety of normal cells such as pneumocytes, endothelial cells, macrophages, fibroblasts, smooth muscle cells, chondrocytes, and mesangial cells, as well as by various tumour cell lines including melanomas and carcinomas.<sup>12-14</sup>

TSP1 is considered to be a component of the extracellular matrix in many human tissues<sup>15</sup> and is involved in a variety of pathophysiological processes such as wound healing,<sup>16,17</sup> angiogenesis,<sup>18</sup> tumorigenesis,<sup>19</sup> and tumour cell metastasis.<sup>20</sup> TSP1 has been shown to promote the attachment and spread of tumour cells in vitro and to potentiate tumour cell metastasis in mice.<sup>19</sup> In human breast cancer, TSP1 is present in the desmoplastic stroma<sup>21</sup> and also in the cytosol of malignant breast tissue.<sup>22</sup> Specific tissue localisation of TSP1 in thyroid tissue has not yet been identified.

## Methods

Forty cases were studied from surgical specimens of thyroidectomy. The material consisted of seven "normal" samples of thyroid paren-

Service d'Anatomie et de Cytologie Pathologiques, CHU Robert Debré, Université Reims Champagne Ardenne, 51092 Reims Cedex, France  
M Patey  
M Pluot

Service de Biochimie et CNRS UPRES-A-6021, IFR 53 "Biomolécules", Université Reims Champagne Ardenne, Reims, France  
G Bellon  
L Martiny  
B Haye

Service d'Endocrinologie, Hôpital Maison Blanche, Université Reims Champagne Ardenne, Reims, France  
B Delemer

Correspondence to: Dr Patey

Accepted for publication 21 July 1999

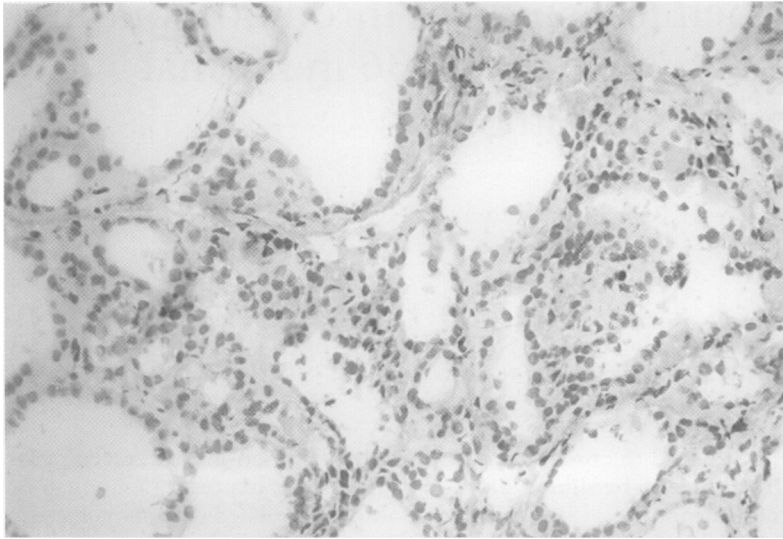


Figure 1 TSP1 Immunostaining of normal thyroid parenchyma showing no immunoreactivity in the extracellular matrix.

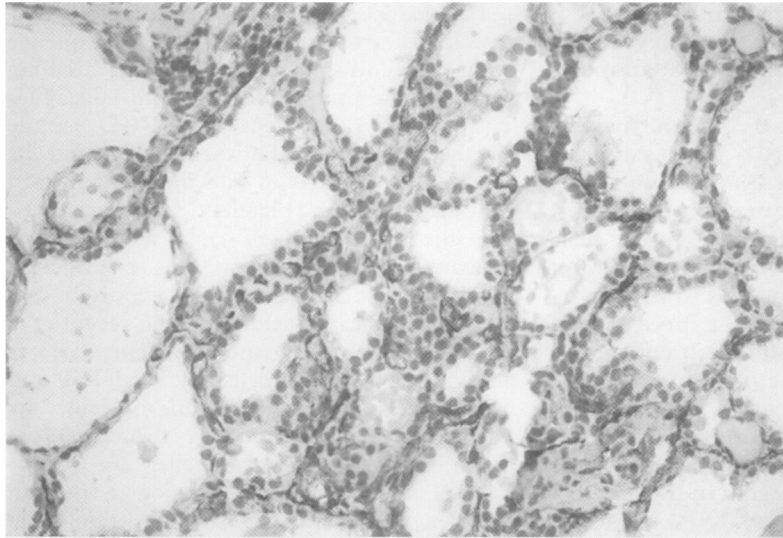


Figure 2 CD36 Immunostaining of the endothelial cells in the interstitium.

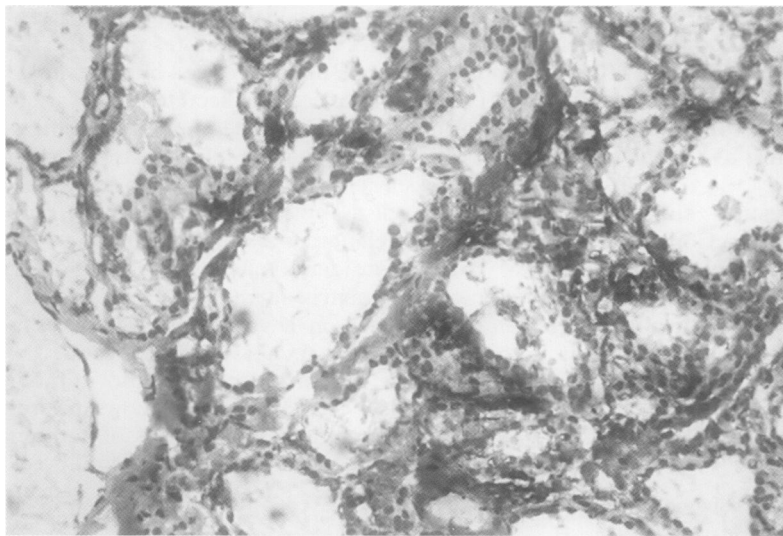


Figure 3 TSP1 Immunostaining in the area of fibrosis of goitres.

chyma adjacent to adenoma or carcinoma; four follicular adenomas including one micro- and macrofollicular variant, two oxyphilic variants, and one trabecular variant; 13 multinodular and adenomatoid goitres; six papillary carcinomas including one case with lymph node

metastases; eight follicular carcinomas; and two anaplastic carcinomas.

Representative fresh tissue samples were snap frozen in liquid nitrogen cooled isopentane and stored at  $-80^{\circ}\text{C}$ . They were cut in 7–8  $\mu\text{m}$  thick sections, fixed in acetone for 10 minutes, and air dried. The immunohistochemical investigations were performed using the labelled streptavidin–biotin method (LSAB kit, Dakopatts).

The antibodies were used at the following dilutions: thrombospondin (TSP1) monoclonal (Sigma): 1/1000; CD 36 monoclonal (Immunotech): 1/100;  $\beta_3$  integrin (CD61) monoclonal (Euromedex): 1/100;  $\alpha\nu$  integrin monoclonal (Chemicon): 1/100;  $\alpha\nu\beta_3$  integrin (CD51/CD61) monoclonal (Chemicon): 1/200.

For each sample, controls were performed using either normal or rabbit serum to substitute for the primary antibodies, and platelet concentrate smears for anti-TSP1 and  $\alpha\nu\beta_3$  integrin. Thyroid samples containing capillary blood vessels served as internal positive controls for CD36. In addition, controls were performed by blocking anti-TSP1 antibody with purified soluble TSP1.

The intensity of the staining was evaluated with a four point semiquantitative scoring: no immunostaining, 0; weak positivity, +; strong positivity, ++; very strong positivity, +++.

## Results

In normal thyroid parenchyma TSP1 was not found in the extracellular matrix (fig 1) but was limited to the wall of the vessels (arterioles and venules) with staining of smooth muscle and endothelial cells. CD36 was restricted to the endothelial cells of main vessels of all types (fig 2).  $\alpha\nu\beta_3$  Integrin was present in some vessels and focally in some thyroid cells in four cases where the staining was restricted to the basolateral cell membrane.

In goitres, TSP1 was revealed in areas of fibrosis, often richly vascularised, where the endothelial cells were also stained (fig 3). The thyrocytes and some endothelial cells expressed  $\alpha\nu\beta_3$  receptors in the vicinity of TSP1 staining (fig 4). CD36 was restricted to the endothelial cells of capillaries. In adenomas, TSP1 was contiguous to the basement membrane and more pronounced in oxyphilic adenomas.  $\alpha\nu\beta_3$  integrin was expressed in one case of follicular adenoma with a diffuse cytoplasmic expression and absent from thyrocytes of oxyphilic variants.

In thyroid carcinomas, the staining of TSP1 was enhanced in comparison with benign thyroid lesions (score +++). TSP1 was strongly expressed in papillary carcinomas with a desmoplastic stroma but thyrocytes were negative around these stromal areas (fig 5). The expression in the extracellular matrix was variable and correlated with the extent of the stroma. In the only case of lymph node metastasis studied was TSP1 staining observed in the stroma. When the tumour was less differentiated, the expression of TSP1 was scarce and focal. The expression of  $\alpha\nu\beta_3$  integrin by thyrocytes was correlated with that

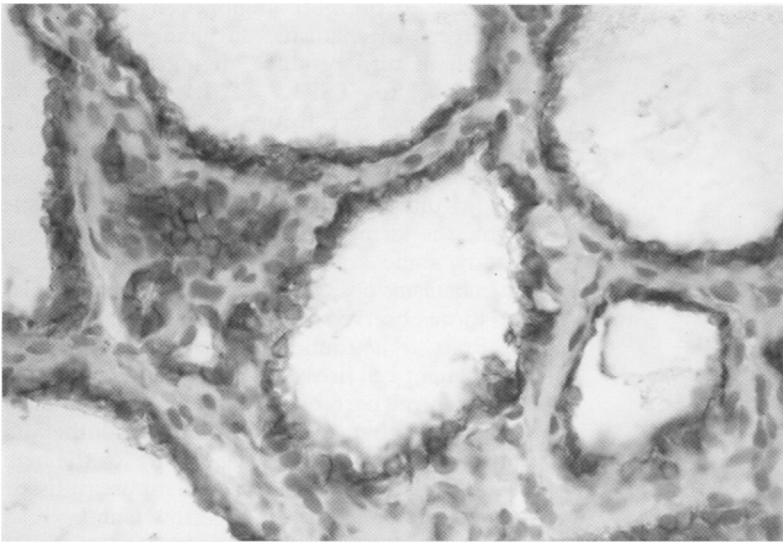


Figure 4  $\alpha v\beta 3$  Immunostaining of thyrocytes of the same specimen as in fig 3.

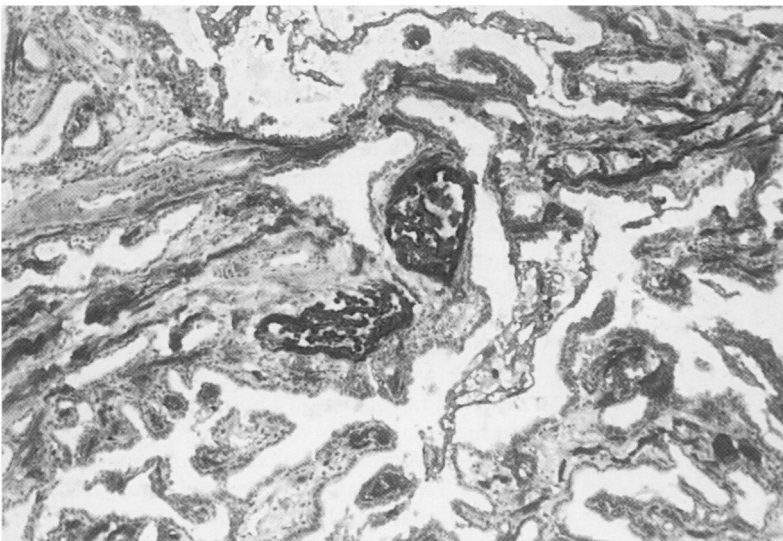


Figure 5 Intense TSP1 immunostaining in the stroma of papillary carcinoma.

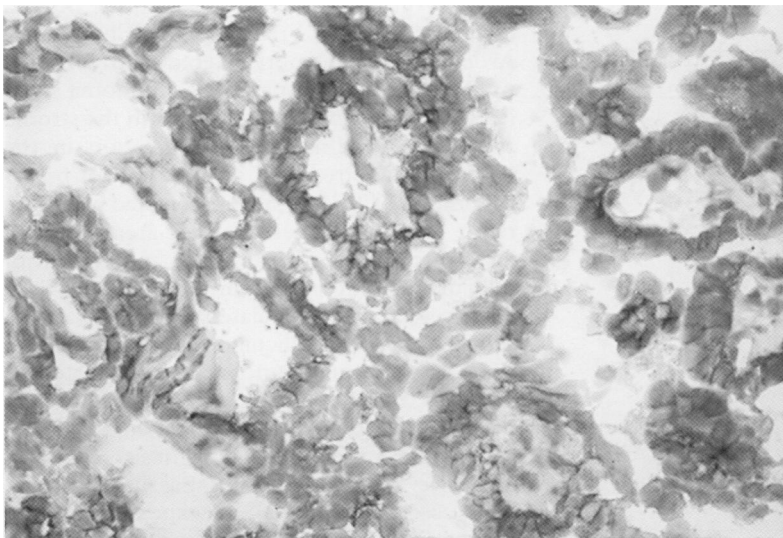


Figure 6  $\alpha v\beta 3$  Immunostaining of thyrocytes of the same specimen as in fig 5.

of TSP1 staining (fig 6). We observed a loss of cell polarity, with a cytoplasmic positivity. No immunostaining was seen with CD36. In follicular carcinomas, TSP1 was present locally in richly vascularised fibrous areas and in endothelial cells of the neighbouring capillary

vessels (fig 7). The expression of CD36 was restricted to the capillary vessels (fig 8). In contrast,  $\alpha v\beta 3$  integrin was focally expressed by the thyrocytes. In anaplastic carcinomas, TSP1 was negative on thyrocytes but was present in the numerous capillaries of the stroma. On the other hand  $\alpha v\beta 3$  integrin marked endothelial cells;  $\alpha v\beta 3$  integrin was present on thyrocytes in one of the two cases studied.

The distribution of  $\alpha v$  and  $\beta 3$  integrin subunits, as revealed with specific monoclonal antibodies, was similar to that obtained with anti- $\alpha v\beta 3$  (data not shown) except that the staining was more pronounced with anti- $\alpha v$  than anti- $\beta 3$  subunit integrin. The intensity of staining and the localisation of TSP1 and its receptors in normal thyroid and pathological conditions are summarised in table 1.

### Discussion

We have investigated the distribution of thrombospondin 1 and its receptors CD36 and  $\alpha v\beta 3$  integrin in normal thyroid and in benign and malignant thyroid tumours. To our knowledge no previous study has shown the presence of TSP1 in normal thyroid tissue, with different expression in various pathological conditions.

We have previously reported from the results of thyroid cell culture that *in vivo* TSP1 might play a role in the folliculogenesis and the differentiation of thyroid and epithelial cells, because TSP1 induced the disruption of follicles, caused cell migration, and inhibited protein iodination.<sup>23</sup> In addition, TSP1 expression was correlated with cell migration and proliferation.<sup>24</sup>

In the present study, we have shown that there is no expression of TSP1 in the extracellular matrix of the human normal thyroid tissue. These data corroborate the fact that, in culture, thyroid cells that are organised into follicular-like structures did not express TSP1.<sup>23 24</sup>

Several studies have implicated TSP1 in the angiogenic process.<sup>10 18 25</sup> For instance, increased expression of TSP1 has been shown immunohistochemically in newly formed vessels of healing wounds<sup>16</sup> and a transient expression of  $\alpha v\beta 3$  integrin on vascular cells has been found during wound repair,<sup>26</sup> suggesting that the transient expression of TSP1 and  $\alpha v\beta 3$  integrin are correlated in early events in wound healing.

In goitres, there is an ischaemic injury during enlargement (follicular hyperplasia) that induces rupture of follicles and vessels, followed by haemorrhage. This tissue destruction, with damage to both parenchymal cells and the stromal framework, is repaired by the replacement of the injured tissue by an extracellular matrix which in time accumulates and produces fibrosis. These scars include angiogenesis migration and proliferation of fibroblasts. These processes are controlled by integrins, especially  $\alpha v\beta 3$ , which is critical for the formation and maintenance of newly formed blood vessels,<sup>27</sup> and also by matricellular proteins including TSP1, Sparc (osteonectin), and

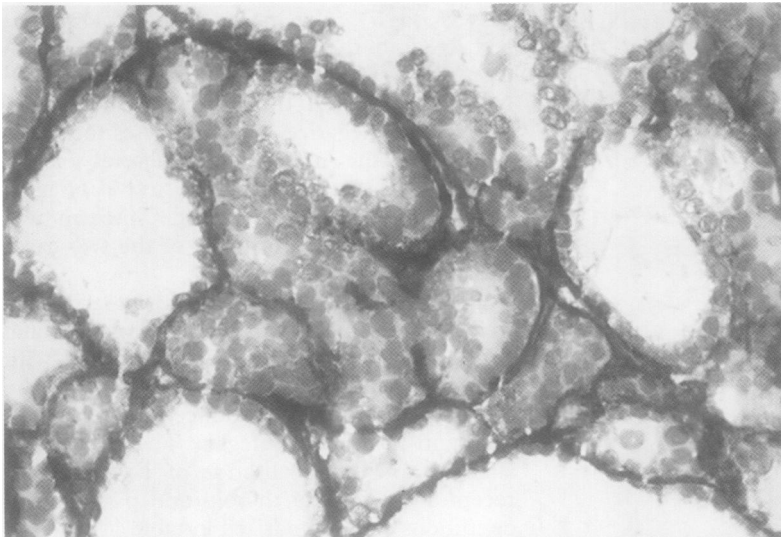


Figure 7 TSP1 Staining of the fine vascularised stroma of follicular carcinoma.

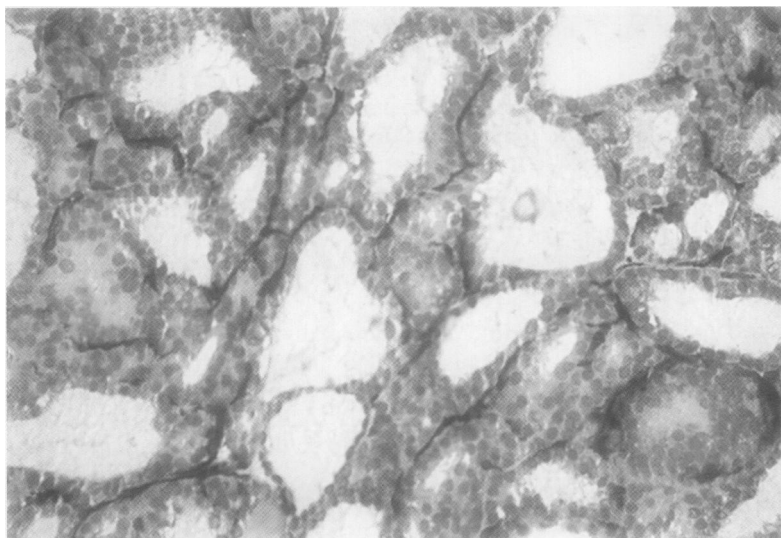


Figure 8 CD36 Staining of the same specimen as in fig 7.

Table 1 Immunolocalisation and semiquantitative evaluation of TSP1 and its receptors in normal thyroid and in thyroid tumours

	TSP1	CD36	$\beta 3$	$\alpha V$	$\alpha V\beta 3$
Normal thyroid (7 cases)	+ V	+ EC	+ V	TC+ V+	TC+ V+
Adenoma (4 cases)	0 to + V+	+ EC	TC 0 to + V	TC+ V+	TC+ V+
Goitre (13 cases)	+ to ++ V	+ EC	+ (focal) TC	TC+ V	TC+ V+
Papillary carcinoma (6 cases)	+++ V + EMC	+ EC	++ NC	+++ NC	NC++ V++
Lymph node metastasis (1 case)	+++ V + EMC	+ EC	+ NC	+++ NC	++ NC
Follicular carcinoma (8 cases)	+ (focal) V	+ EC	0 to + NC	0 to + NC	0 to + V+ NC+
Anaplastic carcinoma (2 cases)	+++ V	+ EC	0 to + V	+ V	0 to + V+ NC+

EC, endothelial cells; EMC, extracellular matrix; NC, neoplastic cells; TC, thyroid cells; V, vessels.

Tenascin C, which destabilise cell matrix interactions and therefore promote angiogenesis.<sup>28</sup>

The complex mechanism of angiogenesis needs proangiogenic and antiangiogenic factors. Among these, TSP1 has been shown to possess antiangiogenic activities,<sup>29 30</sup> but also to

be able to promote angiogenesis through an indirect mechanism involving fibroblasts, which in turn produce angiogenic factors in response to TSP1.<sup>18</sup> TSP1 may promote angiogenesis directly by stabilising neovessels.<sup>31</sup>

In goitres the presence of newly formed vessels expressing  $\alpha V\beta 3$  integrin in early fibrosis allows one to compare it with granulation tissue which is formed during wound repair. In our study, some aspects of the pathophysiological mechanisms observed in goitres are quite similar to those observed in wound healing.<sup>16</sup>

Pratt *et al* found high levels of TSP1 in malignant cell breast secretions and cytosols in the central part of the tumour mass.<sup>21</sup> They suggested that activation of the endothelium may be responsible at least in part for the high levels of TSP1 found in malignant breast tissue and could be a factor in the growth and spread of breast cancer. Excessive deposits of TSP1 are also present in the desmoplastic stroma of human breast carcinomas, whereas normal breast tissue shows no TSP1 staining.<sup>32</sup> More recently, Clezardin *et al* have found that invasive ductal carcinoma cells do not express TSP1.<sup>25</sup> In addition, TSP1 expression was found to be restricted to invasive lobular carcinoma cells, suggesting a different distribution between invasive ductal carcinoma and lobular carcinoma. In a more recent paper, these investigators have shown that the amount of TSP1 mRNA expression increased with the extent of the stroma and microvessel density.<sup>33</sup> Furthermore TSP1 modulates angiogenesis,<sup>34</sup> possibly through an indirect mechanism involving fibroblasts.<sup>35</sup> These observations are in agreement with our results showing that human thyroid papillary carcinomas express more TSP1 than other types of invasive thyroid carcinoma. Papillary thyroid carcinoma is the most common malignant tumour of the thyroid gland, with an excellent overall prognosis (98% 10 year survival).<sup>36</sup> Since 1966, all the thyroid carcinomas of the French region Champagne Ardenne have been registered and followed up.<sup>37</sup> All six cases of papillary carcinoma studied with high expression of TSP1 in the stroma are still alive. Like TSP1 expression in the desmoplastic stroma of invasive ductal breast carcinoma, TSP1 is also associated with the richly vascularised desmoplastic areas of papillary thyroid carcinoma. The prognosis of follicular carcinomas is worse than that of papillary carcinomas, correlated with the extent of the tumour.<sup>38</sup> In follicular carcinomas, TSP1 expression is less abundant and restricted to areas of richly vascularised stroma without desmoplasia. One of the eight patients died two years after the initial diagnosis with an extensive tumour invading the jugular vein. This case had focal TSP1 expression of the stroma and weak  $\alpha V\beta 3$  integrin expression. These observations suggest that TSP1 present in the desmoplastic stroma of papillary carcinoma and correlated with  $\alpha V\beta 3$  expression might be considered a protective factor against tumour progression. We propose, as suggested by Clezardin *et al*,<sup>25</sup> that TSP1 may possess a tumour inhibitory function through the regulation of tumour neovascularity. Direct evidence

of the tumour inhibitory effects of TSP1 comes from the transfection experiments in human breast carcinoma lines.<sup>39</sup> However, despite high levels of TSP1, angiogenesis is stimulated in papillary thyroid carcinomas, suggesting that other factors are involved in the regulation of this process.

We only studied two cases of anaplastic thyroid carcinoma. In one of these there was weak expression of TSP1 restricted to the endothelial cells of the capillaries in the stroma and in the other, weak expression of  $\alpha v\beta 3$  on thyrocytes. These two patients died five and six months, respectively, after the initial diagnosis.

Similarly, in bladder carcinomas, Grossfeld *et al* showed that TSP1 expression was associated with a lower probability of disease progression and an increased probability of survival.<sup>40</sup> In our study, despite the small number of cases, the association of TSP1 with desmoplasia in the stroma of papillary carcinomas seemed to be an indicator of good prognosis, in comparison with follicular and anaplastic carcinomas with a poor stroma.

TSP1 may act not only by interacting with its receptors but also with components of the extracellular matrix and by interfering with the urokinase mediated plasminogen activation (uPA) system.<sup>41</sup> In this respect, the differential expression of a truncated form of the urokinase type plasminogen activator receptor, uPA-R, in normal and tumour thyroid cells has recently been reported.<sup>42</sup>

Papillary carcinoma cells express large amounts of the truncated uPA-R form, whereas follicular carcinoma cells express the intact form. It was suggested that the tendency of tumour cells to invade blood vessels and to metastasise is correlated with the expression of the intact form of uPA-R and with its binding to both vitronectin and uPA, which amplifies extracellular proteolysis. The potential role of TSP1 as a modulator of this activation system and tumour progression is under investigation.

#### CONCLUSIONS

It has previously been reported that TSP1 is expressed in various tissues that are undergoing rapid change. Chronological and topographic restrictions are often observed. We show for the first time that this also occurs in early scars in goitres and in the process of active remodelling of the matrix in some thyroid carcinomas with desmoplastic and richly vascularised stroma, such as papillary carcinomas.

No definite conclusions can be drawn at present as to the diagnostic value of these findings in thyroid pathology, in particular in differentiating papillary from follicular carcinomas. This study suggests some distinctive features of the biological behaviour of papillary carcinomas in comparison with other thyroid carcinomas.

This work was supported by a grant from the Hospital Project for Clinical Research of Reims CHU. We thank E Pierson and N Belouard for their technical assistance and M Philippe for her assistance in the preparation of this manuscript.

1 Lawler J. The structural and functional properties of thrombospondin. *Blood* 1986;67:1197-209.

- 2 Tuszyński GP. The role of thrombospondin in tumor cell metastasis. In: Lahav J, ed. *Thrombospondin*. Boca Raton: CRC Press, 1993:209-25.
- 3 Mosher DF. Physiology of thrombospondin. *Annu Rev Med* 1990;41:85-97.
- 4 Asch AS, Silbirger S, Heimer E, *et al*. Thrombospondin sequence motive (CSVTCG) is responsible for CD36 binding. *Biochem Biophys Res Commun* 1992;182:1208-17.
- 5 Asch AS, Liu I, Briccetti FM, *et al*. Analysis of CD36 binding domains: ligand specificity controlled by dephosphorylation of an ectodomain. *Science* 1993;262:1436-40.
- 6 McPherson JH, Sage H, Bornstein P. Isolation and characterization of a glycoprotein secreted by aortic endothelial cells in culture. *J Biol Chem* 1981;256:11330-6.
- 7 Lawler J, Hynes RO. An integrin receptor on normal and thrombasthenic platelets that binds thrombospondin. *Blood* 1989;74:2022-7.
- 8 Lawler J, Weinstein R, Hynes RO. Cell attachment to thrombospondin: the role of Arg-Gly-Asp, calcium and integrin receptors. *J Cell Biol* 1988;107:2351-61.
- 9 Felding-Habermann B, Mueller BM, Romerdahl CA, *et al*. Involvement of integrin  $\alpha$  gene expression in human melanoma tumorigenicity. *J Clin Invest* 1992;89:2018-22.
- 10 Tuszyński GP, Nicosia RF. The role of thrombospondin-1 in tumor progression and angiogenesis. *BioEssays* 1996;18:71-6.
- 11 Incardona F, Lewalle JM, Morandi V, *et al*. Involvement of thrombospondin in the adherence of human breast adenocarcinoma cells: a possible role in the metastatic process. *Int J Cancer* 1993;55:471-7.
- 12 Prabhakaran D, Kim P, Kim KR, *et al*. Polarized secretion of thrombospondin is opposite to thyroglobulin in thyroid epithelial cells. *J Biol Chem* 1993;268:9041-8.
- 13 Varani J, Dixit VM, Fligiels SEG, *et al*. Thrombospondin induced attachment and spreading of human squamous carcinoma cells. *Exp Cell Res* 1986;167:376-90.
- 14 Varani J, Riser BL, Hughes LA, *et al*. Characterization of thrombospondin synthesis, secretion and cell surface expression by human tumor cells. *Clin Exp Metast* 1989;7:265-76.
- 15 Wight TN, Raugi GJ, Mumby SM, *et al*. Light microscopic immunolocalization of thrombospondin in human tissues. *J Histochem Cytochem* 1985;33:295-303.
- 16 Raugi GJ, Olerud JE, Gown AM. Thrombospondin in early human wound tissue. *J Invest Dermatol* 1987;89:551-4.
- 17 Reed MJ, Puolakkainen P, Lane TF, *et al*. Differential expression of SPARC and thrombospondin-1 in wound repair: immunolocalization and in situ hybridization. *J Histochem Cytochem* 1993;41:1467-77.
- 18 Nicosia R, Tuszyński GP. Matrix-bound thrombospondin promotes angiogenesis in vitro. *J Cell Biol* 1994;12:183-93.
- 19 Castle V, Varani J, Fligiel S, *et al*. Antisense-mediated reduction in thrombospondin reverses the malignant phenotype of a human squamous carcinoma. *J Clin Invest* 1991;87:1883-8.
- 20 Tuszyński GP, Gasic TB, Rothman VL, *et al*. Thrombospondin a potentiator of tumor cell metastasis. *Cancer Res* 1987;47:4130-3.
- 21 Pratt DA, Miller WR, Dawes J. Thrombospondin in malignant and non-malignant breast tissue. *Eur J Cancer Clin Oncol* 1989;25:343-50.
- 22 Dawes J, Clezardin P, Pratt DA. Thrombospondin in milk, other breast secretions and breast tissue. *Semin Thromb Haemost* 1987;13:378-84.
- 23 Bellon F, Chaqour B, Antonicelli F, *et al*. Differential expression of thrombospondin, collagen and thyroglobulin by TSH and tumor-promoting phorbol ester in porcine thyroid cells. *J Cell Physiol* 1994;160:75-88.
- 24 Claisse D, Martiny L, Chaqour B, *et al*. Influence of transforming growth factor  $\beta 1$  (TGF- $\beta 1$ ) on the behaviour of porcine thyroid epithelial cells in primary culture through thrombospondin-1 synthesis. *J Cell Sci* 1999;112:1405-16.
- 25 Clezardin P, Frappart L, Clerget M, *et al*. Expression of thrombospondin (TSP1) and its receptors (CD36 and CD51) in normal, hyperplastic and neoplastic human breast. *Cancer Res* 1993;53:1421-30.
- 26 Clark RAF, Tonnesen MG, Gailit J, *et al*. Transient functional expression on vascular cells during wound repair. *Am J Pathol* 1996;148:1407-21.
- 27 Brooks P, Clark R, Cheresh D. Requirement of vascular integrin  $\alpha v\beta 3$  for angiogenesis. *Science* 1994;264:569-71.
- 28 Bornstein P. Diversity of function is inherent in matricellular proteins an appraisal of thrombospondin-1. *J Cell Biol* 1995;130:503.
- 29 Good DJ, Polverini PJ, Rastinejad F, *et al*. A tumor suppressor-dependent inhibitor of angiogenesis is immunologically and functionally indistinguishable from a fragment of thrombospondin. *Proc Natl Acad Sci USA* 1990;87:6624-8.
- 30 Tolsma SA, Volpert OG, Good DJ, *et al*. Peptides derived from two separate domains of the matrix protein thrombospondin-1 have anti-angiogenic activity. *J Cell Biol* 1993;122:497-511.
- 31 Qian X, Nicosia RF, Bochenek KM, *et al*. The effect of thrombospondin on endothelial cell tube formation in vitro [abstract]. *Mol Biol Cell* 1994;5:179a.
- 32 Wong SY, Purdie AT, Han P. Thrombospondin and other possible related matrix proteins in malignant and benign breast disease: an immunohistochemical study. *Am J Pathol* 1992;140:1473-82.
- 33 Bertin N, Clezardin P, Kubiak R, *et al*. Thrombospondin 1 et 2 messenger RNA expression in normal, benign and neoplastic human breast tissues: correlation with prognosis.

- tic factors, tumor angiogenesis and fibroblastic desmoplasia. *Cancer Res* 1997;57:396-9.
- 34 Roberts DD. Regulation of tumor growth and metastasis by thrombospondin-1. *FASEB J* 1996;10:1183-91.
- 35 Dameron KM, Volpert OV, Toinsky MA, et al. Control of angiogenesis in fibroblasts by p53 regulation of thrombospondin-1. *Science* 1994;265:1582-4.
- 36 Mazzaferri EL, Jhiang SM. Long-term impact of initial surgical and medical therapy on papillary and follicular thyroid cancer. *Am J Med* 1994;97:418-28.
- 37 Delisle MJ, Schwartz C, Theobald S, et al. Les cancers de la thyroïde. Intérêt d'un registre régional de 627 patients diagnostiqués, traités et suivis par une équipe multidisciplinaire. *Ann Endocrinol (Paris)* 1996;57:41-9.
- 38 Brennan MD, Bergstralh EJ, Van Heerden JA, et al. Follicular thyroid cancer treated at the Mayo Clinic Proc. *Mayo Clin Proc* 1991;66:11-22.
- 39 Weinstat Saslow DL, Zabrenetzky VS, VanHoutte K, et al. Transfection of thrombospondin-1 complementary DNA into a human breast carcinoma cell line reduces primary tumor growth, metastatic potential and angiogenesis. *Cancer Res* 1994;54:6504-11.
- 40 Grossfeld GD, Ginsberg DA, Stein JP, et al. Thrombospondin-1 expression in bladder cancer: association with p53 alterations, tumor angiogenesis and tumor progression. *J Natl Cancer Inst* 1997;89:219-27.
- 41 Sandler MA, Zhang JN, Westerhausen DR, et al. A novel protein interacts with the major transforming growth factor  $\beta$  responsive element in the plasminogen activator inhibitor type 1 gene. *J Biol Chem* 1994;369:21500-4.
- 42 Ragno P, Montuori N, Covelli B, et al. Differential expression of a truncated form of the urokinase-type plasminogen-activator receptor in normal and tumor thyroid cells. *Cancer Res* 1998;58:1315-19.