

Immunohistochemical identification of erythroid precursors in paraffin embedded bone marrow sections: spectrin is a superior marker to glycophorin

Yoshito Sadahira, Akio Kanzaki, Hideho Wada, Yoshihito Yawata

Abstract

Aim—To investigate whether spectrin can be used as an immunohistochemical marker for erythroid precursors in routinely processed paraffin embedded bone marrow sections.

Methods—Bone marrow biopsies and clot sections were stained with rabbit anti-human erythrocyte spectrin antibodies, specific for erythroid cells as shown by western blotting and bone marrow smears, and compared to sections stained with antiglycophorin monoclonal antibodies (JC159 and Ret49f).

Results—Antispectrin antibodies resulted in diffuse cytoplasmic staining of early erythroblasts and membranous staining of late erythroblasts as well as erythrocytes. In haematopathological samples, immature erythroid cell clusters were clearly identified. In contrast, antiglycophorin monoclonal antibodies resulted in only membranous staining of late erythroblasts, and faint staining of early erythroblasts.

Conclusions—Spectrin may be a superior marker to glycophorin for the identification of erythroid precursors in paraffin embedded sections.

(J Clin Pathol 1999;52:919-921)

Keywords: spectrin, erythroblast, immunohistochemistry

In paraffin embedded tissue, immunohistochemistry is useful to identify erythroblasts, as erythroid precursors, proerythroblasts, and basophilic erythroblasts are not easily differentiated from other type of precursors. So far, antibodies against haemoglobin,¹ glycophorin A,² and glycophorin C³ have been used to identify erythroid cells in paraffin sections. However, the ability of these antibodies to identify erythroid precursors has not been determined.

The expression of erythroid membrane cytoskeleton components—spectrin, glycophorin, and band 3 protein—during mammalian and human erythroid cell differentiation has been extensively studied.⁴⁻⁶ While spectrin is a cytoskeleton component seen from early to terminal erythroid differentiation, the usefulness of this protein as a diagnostic marker has not been tested. In the present study, we used antihuman erythrocyte spectrin antibodies to assess routinely processed paraffin embedded sections.

Methods

CASE SELECTION

Bone marrow biopsies and clot samples were taken from the posterior iliac crest of patients including three cases of autoimmune haemolytic anemia, three of megaloblastic anaemia associated with vitamin B-12 deficiency, five of myelodysplastic syndromes (MDS) (refractory anaemia), two of erythroleukaemia, two of polycythaemia vera, and five of pure red cell aplasia associated with acute parvovirus B19 infection. As control, we used 10 cases of malignant lymphoma in which examination of bone marrow was shown to be within normal limits. Informed consent was obtained from all patients.

The samples were fixed with Bouin's solution for three hours, embedded in paraffin, and cut to a thickness of 4 µm without decalcification. Necropsy samples (bone marrows and spleens containing extramedullary haematopoiesis) were fixed in 10% buffered formalin, decalcified using Plank-Rychlo's method if necessary, embedded in paraffin, and cut to a thickness of 4 µm. A multi-tissue sausage block containing brain, liver, heart, lung, kidney, spleen, thymus, lymph node, pancreas, intestine, stomach, oesophagus, striated muscle, skin, and adrenal gland was prepared as described previously.⁷

ANTIBODIES

Rabbit antihuman erythrocyte spectrin antibodies were provided by the Division of Haematology, Department of Medicine, Kawasaki Medical School.⁸ Briefly, spectrin was purified from human erythrocytes as previously reported,⁹ and injected into a rabbit. Serum was recovered three months after the last immunisation. The antispectrin antibodies were affinity purified and used for western blotting and immunohistochemistry. Antihuman glycophorin A (JC159) and glycophorin C (Ret49f) monoclonal antibodies were purchased from Dako Japan, Kyoto, and used in 1:50 and 1:20 dilution, respectively.

IMMUNOHISTOCHEMISTRY

Sections were deparaffinised and treated in a microwave oven (600 W) in citrate buffered solution (pH 6.3) for 10 minutes and reacted with 5% H₂O₂ for 10 minutes to eliminate endogenous peroxidase activity. After incubation in 10% fetal bovine serum, sections were allowed to react with the first antibodies for 60 minutes at room temperature. They were then

Department of Pathology, Kawasaki Medical School, 577 Matsushima, Kurashiki 701-0192, Japan
Y Sadahira

Division of Haematology, Department of Medicine, Kawasaki Medical School
A Kanzaki
H Wada
Y Yawata

Correspondence to:
Dr Sadahira
email:
sadapath@med.kawasaki-m.ac.jp

Accepted for publication
2 August 1999

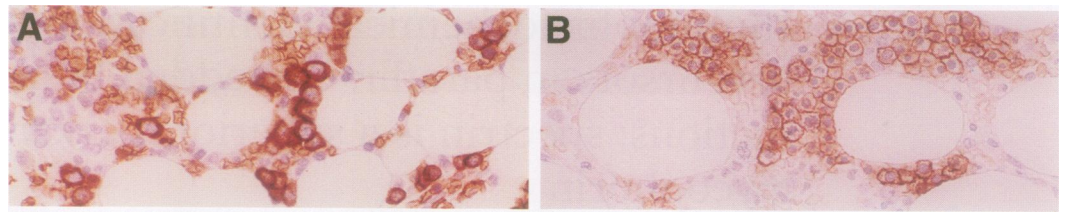


Figure 1 Immunoperoxidase staining with antispectrin in the bone marrow. A cluster of early erythroblasts (A) and a cluster of late erythroblasts (B). Spectrin is stained in the cytoplasm of early erythroblasts and on membranes of late erythroblasts.

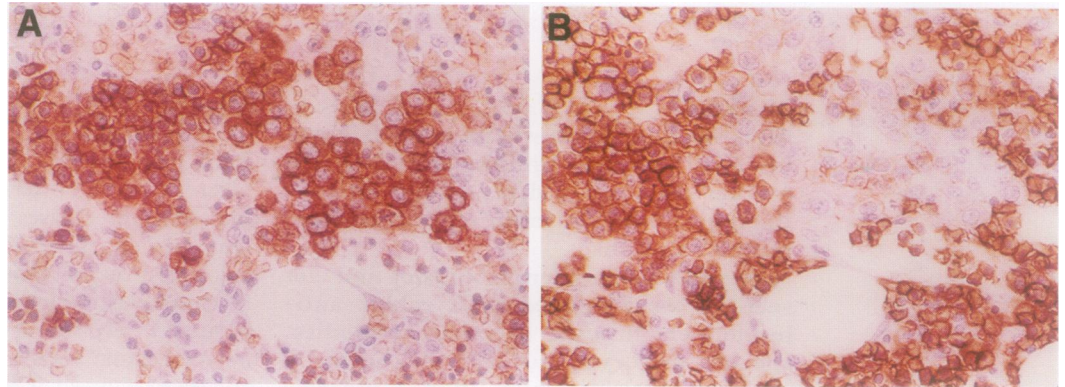


Figure 2 Immunoperoxidase staining of clusters of erythroid precursors with antispectrin antibodies (A) and JC159 (B) in serial sections from a patient with myelodysplastic syndrome. This sample shows erythroid hyperplasia. Spectrin staining is seen mainly in early erythroblasts. Late erythroblasts and erythrocytes are heavily stained with JC159, but early erythroblasts are faintly stained.

washed in phosphate buffered saline (PBS) and allowed to react with peroxidase-Envision (Dako) for 30 minutes. The sections were developed with diaminobenzidine and counterstained with haematoxylin. Negative controls were treated in the same manner, but without the primary antibodies.

Results

REACTIVITY OF THE ANTISPECTRIN AND ANTIGLYCOPHORIN ANTIBODIES WITH NORMAL ERYTHROID CELLS AT DIFFERENT MATURATION STAGE

In western blotting of bone marrow cell lysates, antihuman erythrocyte spectrin antibodies formed two bands, corresponding to α and β spectrin.⁸ In sections of adult tissues, the antibodies only reacted with erythroid cells at all stages of maturation in bone marrow, with extramedullary haematopoietic foci in spleen and liver, and with blood erythrocytes. Myeloid cells and megakaryocytes were not stained. Antigen retrieval with microwave treatment was essential to obtain good staining results. Immunohistochemical staining is influenced by decalcification procedures, with intensity markedly decreasing in decalcified bone marrow necropsy samples. In control cases, the antispectrin antibodies stained early erythroblasts, forming clusters and large isolated erythroblasts (fig 1A). Both these cell types had diffusely stained cytoplasm. Late erythroblasts, and erythrocytes, had stained membranes (fig 1B).

JC159 (antiglycophorin A) and Ret49f (antiglycophorin C) weakly stained membrane of early erythroblasts, forming clusters. The membranes of late erythroblasts, as well as erythrocytes, were all strongly labelled.

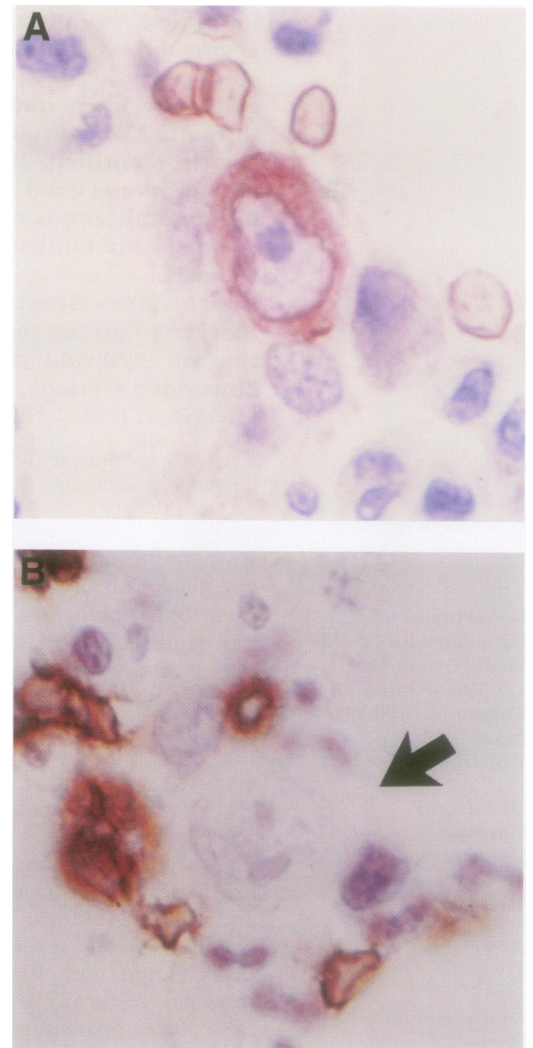


Figure 3 Cytoplasmic staining of spectrin in bone marrow giant proerythroblasts from a parvovirus B19 infection patient (A). JC159 failed to stain the giant proerythroblasts (B, arrow).

REACTIVITY OF THE ANTISPECTRIN AND ANTIGLYCOPHORIN A (JC159) WITH ERYTHROBLASTS IN HAEMATOLOGICAL DISORDERS

In the bone marrow of cases of myelodysplastic syndrome, there were cell clusters of early erythroid precursors which might easily be mistaken for clusters of myeloid precursors without immunohistochemical analysis. They had strong cytoplasmic staining by antispectrin antibodies and faint membranous staining by JC159 (fig 2, A and B). In erythroleukaemia cases, erythroblasts were clearly stained with antispectrin antibodies. However, blastic cells of undetermined lineage were not stained with either antibody. In the cases of haemolytic anaemia, megaloblastic anaemia associated with vitamin B-12 deficiency, and polycythaemia vera, colonies of early erythroid precursors were clearly stained with antispectrin antibodies. In the bone marrow of all five cases of acute parvovirus B19 infection, giant proerythroblasts were stained with antispectrin antibodies but not with JC159 (fig 3, A and B).

Discussion

In this study, we performed paraffin embedded immunohistochemistry using antispectrin antibodies. Intracellular haemoglobin has been reported to be a sensitive and specific marker for erythroid elements at all maturation stages of maturation in paraffin embedded sections.¹ However, the sensitivity of this marker for early erythroid precursors is questionable because haemoglobin can be detected during the late stage of erythroid cell differentiation. Nowadays, antiglycophorin A and antiglycophorin C monoclonal antibodies are widely used instead of antihemoglobin antibodies, and Erber *et al* showed that antiglycophorin A monoclonal antibody JC159 was superior to antiglycophorin C monoclonal antibody Ret49f for the staining of blast cells of erythroleukaemia in paraffin sections.²

We found that staining patterns and intensities of erythroblasts were different between antispectrin and antiglycophorin monoclonal antibodies. Consistent with previous reports on immunocytochemistry in bone marrow smear, antispectrin antibodies showed strong cytoplasmic staining, whereas antiglycophorin monoclonal antibody showed membranous staining.²⁻⁶ Although glycophorin has been found to be expressed by erythroid cells from the morphologically recognisable erythroblasts arising just after the erythroid colony forming unit (CFU-E) stage to mature erythrocytes,^{2,4} glycophorin expression was weak in early erythroblasts in routinely processed paraffin embedded sections. This may be because the detection sensitivity of paraffin section immunohistochemistry is lower than that of flow cytometry. Antispectrin antibody staining in smears of bone marrow cells was shown to be localised in the cytoplasm of late erythroid burst forming unit (BFU-E) in which band 3

could not yet be seen, suggesting that early erythroid progenitors can be identified with this stain.⁵

Abnormal localisation of immature precursors (ALIP) have been identified as non-paratrabeular clusters of myeloid precursors in paraffin sections.¹⁰ These seem to be an important prognostic factor of MDS cases. However, haematoxylin-eosin staining of paraffin sections cannot distinguish myeloid precursors from erythroid precursors. Staining with antispectrin antibodies would solve this problem because these antibodies specifically stain erythroid cells.

Interestingly, human parvovirus B19 infection associated giant cells were clearly stained with antispectrin, but not with JC159. A previous report showed that giant proerythroblasts, derived from human fetal liver culture in medium containing parvovirus B19 antigen positive serum, were stained with JC159 in cytocentrifuge preparations.¹¹ However, they were not stained with JC159 in the paraffin sections in this study. This discrepancy may be because of differences in the methods used in each study. Antispectrin antibody may be a valuable tool in the diagnosis of parvovirus B19 infection, because giant proerythroblasts are diagnostic of infection, yet difficult to find in histological sections.

In conclusion, antispectrin antibodies are more useful for detecting erythroid precursors in paraffin embedded immunostaining than antiglycophorin monoclonal antibodies (JC159 and Ret49f).

- 1 Pinkus GS, Said JW. Intercellular hemoglobin—a specific marker for erythroid cells in paraffin sections. An immunoperoxidase study of normal, megaloblastic, and dysplastic erythropoiesis, including erythroleukemia and other myeloproliferative disorders. *Am J Pathol* 1981;102:308-13.
- 2 Erber WN, McLachlan J, Cordell JL, *et al*. A new monoclonal antibody (JC159) that detects glycophorin A for the diagnosis of erythroleukemia. *Hematol Rev* 1991;5: 113-20.
- 3 Kurec A, Cruz VE, Barrett D, *et al*. Immunophenotyping of acute leukemias using paraffin-embedded tissue sections. *Am J Clin Pathol* 1990;93:502-9.
- 4 Loken MR, Shah VO, Dattilo KL, *et al*. Flow cytometric analysis of human bone marrow. I. Normal erythroid development. *Blood* 1987;69:255-63.
- 5 Nehls V, Zeitler-Zapf P, Drenckhahn D. Different sequences of expression of band 3, spectrin, and ankyrin during normal erythropoiesis and erythroleukemia. *Am J Pathol* 1993; 142:1565-73.
- 6 Wickrema A, Koury ST, Dai C, *et al*. Changes in cytoskeletal proteins and their mRNAs during maturation of human erythroid progenitor cells. *J Cell Physiol* 1994;160:417-26.
- 7 Battifora H. The multi-tumor (sausage) tissue block: Novel method for immunohistochemical antibody testing. *Lab Invest* 1986;55:244-8.
- 8 Wada H, Kanzaki A, Yawata A, *et al*. Late expression of red cell membrane protein 4.2 in normal human erythroid maturation with seven isoforms of the protein 4.2 gene. *Exp Hematol* 1999;27:54-62.
- 9 Morrow JS, Marchesi VT. Self assembly of spectrin oligomers in vitro: a basis for dynamic cytoskeleton. *J Cell Biol* 1981;88:463-8.
- 10 Tricot G, De Wolf-Peeters C, Vlietinck R, *et al*. Bone marrow histology in myelodysplastic syndromes. II. Prognostic value of abnormal localization of immature precursors in MDS. *Br J Haematol* 1984;58:217-25.
- 11 Morey AL, Fleming KA. Immunophenotyping of fetal haemopoietic cells permissive for human parvovirus B19 replication in vitro. *Br J Haematol* 1992;82:302-9.