

Letters

L26 (CD20) staining of Bouin fixed bone marrow biopsies

L26 (CD20) is one of the most useful markers in the diagnosis of lymphoid neoplasms, but when Gala *et al* tested a large panel of antibodies for use in Bouin fixed bone marrow, L26 was one of the few antibodies which failed to stain.¹ Vassallo and Pinto² now suggest that if Zenker solution is used instead of Bouin solution, satisfactory L26 staining may be obtained. However, Zenker has its own technical and safety disadvantages and we note that, in contrast to the findings of Gala *et al*, successful immunostaining of Bouin fixed material for L26 has previously been noted³ and we get consistent, strong immunostaining for L26. We have fixed marrow biopsies in Bouin fluid for many years because of its excellent morphology in haematoxylin and eosin (H&E) staining and for its ease of use. (Following three to six hours of fixation in Bouin, biopsies are decalcified overnight in 10% formic acid. A short daytime processing cycle allows H&E sections to be reviewed late on the day following biopsy.) For immunohistochemistry we use antigen retrieval in antigen unmasking solution (Vector Laboratories) with pressure cooking for two minutes before applying L26 (Dako) followed by the avidin-biotin complex (ABC) technique. In addition to staining B cells, we note that L26 may give weak to moderate staining of megakaryocytes, a finding we have also seen with B5 fixed material. Nucleolar staining, described in epithelial and other cells types⁴ and regarded as non-specific, may be seen in some marrow blast cells. Figure 1 shows L26 staining of an infiltrate of hairy cell leukaemia in a Bouin fixed marrow biopsy. Gala *et al* indicate that there is limited information on the range of antibodies which stain in Bouin fixed marrow¹ so we have reviewed all the immunostains on our bone marrow biopsies for the past year. In addition to the antibodies described by Gala we have found successful staining for L26, leucocyte common anti-

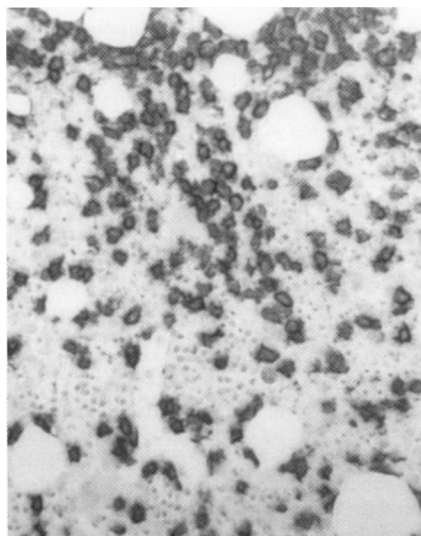


Figure 1 Immunoperoxidase staining of L26 (CD20) in Bouin fixed bone marrow infiltrated by hairy cell leukaemia. The hairy cells show strong membrane staining and contrast with the unstained marrow trilineage.

body, CD79a, CD34, CD68 (PGM1), epithelial membrane antigen, glycophorin A and C, S-100, and tryptase.

D S O'BRIAIN
C MURPHY

Histopathology Department, St James's Hospital and Trinity College Medical School, James's Street, Dublin 8, Republic of Ireland

- 1 Gala JL, Chenut F, Hong KB, *et al*. A panel of antibodies for the immunostaining of Bouin's fixed bone marrow trephine biopsies. *J Clin Pathol* 1997;50:521-4.
- 2 Vassallo J, Pinto GA. Antibody panel in diagnosis of lymphoid neoplasms. *J Clin Pathol* 1998; 51:638-9.
- 3 Labouyrie E, Marit G, Lacombe F, *et al*. Intrasinusoidal bone marrow involvement by splenic lymphoma with villous lymphocytes: a helpful immunohistologic feature. *Mod Pathol* 1997; 10:1015-20.
- 4 Chang KL, Arber DA, Weiss LM. CD20, a review. *Appl Immunohistochem* 1996;4:1-15.

Authors' reply:

In a previous issue of this journal,¹ we presented a list of antibodies suitable for immunostaining of Bouin's fixed, paraffin embedded bone marrow trephine biopsies. Very few data indeed report the reactivity of currently available antibodies on Bouin's fixed bone marrow. Some of the antibodies assessed were inconsistently reactive (4KB5/CD45RA, Ki-B3/CD45RA, DBA-44, VS38) or unreactive (CD 20/L26, LN-1/CDw75, Bcl-1/PRAD1, DO-7, rabbit-Ki-67). In a letter to the editor, Vassallo and Pinto commented on lack of reactivity of our L26 staining with Bouin's fixed material.² They pointed out the usefulness of L26 staining for differential diagnosis of reactive and neoplastic small cell lymphoid aggregates in bone marrow specimens, and stressed the satisfactory results that were obtained with their Zenker fixed marrow. As pinpointed in our reply,¹ it is of note that the major difference between their method and several previous discrepant reports of unsuccessful staining with L26 on Zenker's fixed material,^{4,7} was the use of a microwave retrieval procedure.

In this issue, O'Briain and Murphy also stress the value of L26 for diagnosis of lymphoid neoplasms, and point out that they, and another team, have consistent L26 (CD20) immunostaining on Bouin's fixed and decalcified material.⁸ O'Briain and Murphy used three to six hours of fixation, decalcification overnight in 10% formic acid, followed by antigen unmasking solution with pressure cooking for two minutes. The other team reported successful L26 staining on Bouin's fixed bone marrow with a very similar procedure, including Bouin's fixation for 12 hours, decalcification in EDTA for two hours, and retrieval step by pressure cooking. This is highly comparable with our procedure (less than 24 hours of fixation, decalcification for six hours in 7.5% in nitric acid). In agreement with others, however, we experienced a lack of reactivity of L26 on Bouin's fixed material.^{1,7,9} Here again, the major difference between successful and unsuccessful L26 staining appeared to be the use an adequate antigen retrieval procedure. While the reactivity of our panel of antibodies was compared with and without microwave heating on archival bone marrow biopsies, our evaluation with microwave retrieval was unfortunately hampered by the frequent unsticking and destruction of part or whole of the bone marrow core biopsy sample. Moreover, the length of fixation in several Bouin's fixed samples, delivered from outside institutions, was close to 24 hours and it is thought that

overfixation may damage the L26 epitope. Mounting processed bone marrow (fixation less than 12 hours) on coated slides now allows an adequate retrieval procedure. In such conditions and with microwave heating as prerequisite, our current L26 results are in full accordance with these of O'Briain and Murphy.

Regarding the statement of these investigators that L26 is one of the most useful lymphoid markers, we would like to emphasise that immunotyping of lymphoid cells on Bouin's fixed bone marrow may also be performed with surrogate B cell markers, such as LN-2/CD74 and MB2, but also by Ki-B5, a very effective antibody recognising normal and malignant B cells.¹⁰ The advantage of these antibodies, compared with L26, is that they do not require prior antigen retrieval. The use of this panel of B cell antibodies, together with bcl-2 antibody, allows easy identification and quantification of malignant B cells in bone marrow trephine biopsies.^{11,12}

The complementary list of other immunoreactive antibodies given by O'Briain and Murphy (LCA, CD79a, CD34, CD68, glycophorin A and C, S-100, and tryptase) is very useful for laboratories testing Bouin's fixed material, and we thank these workers for providing this valuable information. Like them, we previously reported and illustrated the strong reactivity of mast cells with antibody antitryptase (AA1).³ CD79a also appears immunoreactive in our hands after microwave heating. In the light of these new data, we would like to upgrade the current list of antibodies suitable for the immunostaining of Bouin's fixed bone marrow trephine biopsies; this includes antibodies for immunotyping haematological malignancies as well as solid tumors, as follows: CD4, CD8, CD15, prostate specific antigen (PSA, prediluted), carcinoembryonic antigen (CEA, prediluted), mouse antihuman oestrogen (MAE, prediluted), and cytokeratin (clone MNF116, prediluted), all from Dakopatts, Prospan, Belgium. Preliminary results with CD5 and CD1a also seem encouraging, but require confirmation on a larger series of clinical specimens. It should be borne in mind that prior microwave heating appears necessary for all these newly tested antibodies.

JEAN-LUC GALA

Laboratory of Molecular Biology, Department of Biochemistry, Université Catholique de Louvain, Brussels, and Hôpital Militaire Reine Astrid, Rue Bruyn, Brussels, Belgium

JEAN-MARIE SCHEIFF

Department of Haematology Cliniques, Université Catholique de Louvain, Brussels, Belgium

- 1 Gala JL, Chenut F, Hong KBT, *et al*. A panel of antibodies for the immunostaining of Bouin's fixed bone marrow trephine biopsies. *J Clin Pathol* 1997;50:521-24.
- 2 Vassallo J, Pinot GA. Antibody panel in diagnosis of lymphoid neoplasms. [Letter to the Editor.] *J Clin Pathol* 1998;51:638.
- 3 Gala JL, Horsmans Y. Antibody panel in diagnosis of lymphoid neoplasms. [Reply.] *J Clin Pathol* 1998;51:638-9.
- 4 Kubic VL, Brunning RD. Immunohistochemical evaluation of neoplasms in bone marrow biopsies using monoclonal antibodies reactive in paraffin-embedded tissue. *Mod Pathol* 1989;2:618-29.
- 5 Falini B, Pileri A, Flenghi L, *et al*. Selection of a panel of monoclonal antibodies for monitoring residual disease in peripheral blood and bone marrow of interferon-treated hairy cell leukaemia patients. *Br J Haematol* 1990;76:460-8.
- 6 Perkins SL, Kjeldberg CR. Immunophenotyping of lymphomas and leukemias in paraffin-embedded tissues. *Am J Clin Pathol* 1993;99:362-73.

- 7 Ellison DJ, Sharpe RW, Robbins BA, *et al.* Immunomorphologic analysis of bone marrow biopsies after treatment with 2-chlorodeoxyadenosine for hairy cell leukemia. *Blood* 1994;84:4310-15.
- 8 Labouyrie E, Marit G, Vial JP, *et al.* Intrasinusoidal bone marrow involvement by splenic lymphoma with villous lymphocytes: a helpful immunohistologic feature. *Mod Pathol* 1997;10: 1015-20.
- 9 Hakimian D, Tallman MS, Kiley C, *et al.* Detection of minimal residual disease by immunostaining of bone marrow biopsies after 2-chlorodeoxyadenosine for hairy cell leukemia. *Blood* 1993;6:1798-802.
- 10 Hansmann ML, Wacker HH, Gralla J, *et al.* Ki-B5: a monoclonal antibody unrelated to CD45 recognizes normal and neoplastic human B cells in routine paraffin sections. *Blood* 1991;77:809-17.
- 11 Gala JL, Delannoy A, Martiat P, *et al.* Detection of residual disease by immunostaining of bone marrow trephines after 2-chlorodeoxyadenosine in previously untreated chronic lymphocytic leukemia [abstract]. *Blood* 1995;86: 833a.
- 12 Gala JL, Guiot Y, Delannoy A, *et al.* Use of image analysis and immunostaining of bone marrow trephine biopsy specimens to quantify residual disease in patients with B-cell chronic lymphocytic leukemia. *Mod Pathol* 1999;12: 391-9.

Calcium oxalate (Weddellite) crystals within ductal carcinoma in situ

Following our short report of a rare example of calcium oxalate (Weddellite) crystals within papillary pattern ductal carcinoma in situ¹ we have encountered a further case. A 54 year old woman had microcalcifications detected in her right breast on routine breast screening. Core biopsies taken under x ray guidance showed ductal carcinoma in situ, but the only calcifications seen in the biopsies after examination of multiple tissue sections were of calcium oxalate (Weddellite) crystals in the lumen of a duct involved by high grade solid pattern ductal carcinoma in situ. A subsequent x ray guided wide excision of the microcalcifications revealed extensive high grade solid and comedo pattern ductal carcinoma, associated with (predominantly) ordinary-type microcalcifications, but also with luminal Weddellite crystals. This contrasted with our previously reported case in which the ductal carcinoma in situ was of papillary type.¹

As previously discussed,¹ Weddellite-type microcalcifications are usually associated with benign breast disease—particularly with apocrine microcysts.² Interestingly, the wide excision specimen in this case also contained apocrine microcysts with Weddellite crystals, which were immediately adjacent to the Weddellite containing ductal carcinoma in situ (fig 1).

Ductal carcinoma in situ associated with Weddellite-type microcalcifications remains a rare finding. The coexistence of Weddellite crystals in apocrine microcysts (not present within our previously reported case¹) and adjacent ductal carcinoma in situ in this case lends further support to the "bystander" theory for this phenomenon; that is, that ductal carcinoma in situ may involve a previously benign breast duct containing Weddellite crystals associated with pre-existing benign changes.

HILARY M MARTIN
ADRIAN C BATEMAN
JEFFREY M THEAKER

Department of Histopathology, Southampton General Hospital, Southampton SO16 6YD, UK

- 1 Singh N, Theaker JM. Calcium oxalate crystals (Weddellite) within the secretions of ductal carcinoma in situ—a rare phenomenon. *J Clin Pathol* 1999;52:145-6.

- 2 Frappart L, Boudeulle M, Boumendil J, *et al.* Structure and composition of microcalcifications in benign and malignant lesions of the breast. *Hum Pathol* 1984;15:880-9.

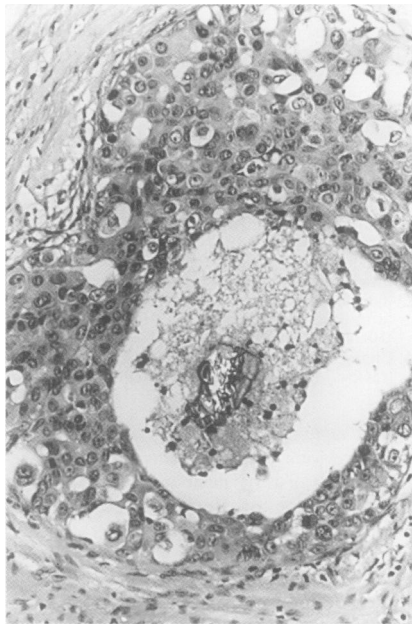


Figure 1 Weddellite crystals within high grade ductal carcinoma in situ, photographed under partially polarised light. Haematoxylin and eosin stain.

Book reviews

Color Atlas of Normal Cytology. By A J Herzberg, D S Raso, and J F Silverman. (£165.00.) Churchill Livingstone, 1999. ISBN: 0 443 07547 6.

In this book the authors aim to provide "a single source for describing and illustrating normal cytology that may be seen in day to day practice." Following introductory chapters covering the structure of the cell and cytological techniques, there are sections devoted to specific cell and tissue types and individual organs. There is a section on gynaecological cytology, although the majority of the book is devoted to fine needle aspiration and exfoliative cytology from other organs.

Each section is arranged in a similar fashion, covering anatomy, histology, normal cytology, and potential pitfalls. This results in a pleasing uniformity that is often missing in multi-author texts. The text, while brief, is clearly written and the sections in each chapter on potential pitfalls are particularly useful. The illustrations provide a good mix of Papanicolaou and Diff-quick stained material, together with relevant haematoxylin and eosin stained histological sections. They are of generally good quality, although some of the photomicrographs of Diff-quick stained material are a little dark, and in some sections there is quite marked variation in the photomicrograph background. These minor problems do not, however, detract from what is a high quality text.

This book would be of use to any practising cytopathologist and would also be of benefit to trainees. As such, it would be an important addition to any cytopathologist's library.

NEIL ANDERSON

Postgraduate Haematology (4th edn). Edited by A V Hoffbrand, S M Lewis, E G D Tuddenham. (£95.00.) Butterworth Heinemann, 1999. ISBN: 0 7506 0583 9.

Virginia Woolf wrote, "for the desire to read, like all the other desires which distract our unhappy souls, is capable of analysis." You may have noticed a few unhappy trainee souls around at the time of the MRCPath examination, so will the arrival of the fourth edition of *Postgraduate Haematology* bring a little light into their lives? The question of whether any book has a role for future trainees in the age of electronic publishing is certainly worthy of analysis. Remember when videos were going to sweep aside the cinema audience? The internet is unrivalled for current information but only the most hardened of computer nerds could suggest that the internet will ultimately replace the textbook. The local trainees who have had a look at *Postgraduate Haematology* agree with my assessment that it is an excellent overview and very clearly laid out. Some of the tables will be familiar to those who have attended the Hammersmith course, but all the 41 authors are to be complimented on their presentation of tables and diagrams. The morphology slides are also particularly good.

The layout is clear with the diagrams and photomicrographs organised in the appropriate section of the text so that they can be easily referred to. I recall reading a review of the second edition which criticised a didactic style which was necessary to keep the size of the book down. The fourth edition is a much more expansive text to take in the wealth of recent developments (such as new chapters on haemopoiesis and stem cell transplantation), but it does present most sides of the major issues and the bibliography is commendably concise. I particularly enjoyed the chapters on aplasia, genetic disorders of haemoglobin, and the myeloproliferative disorders.

Inevitably there are criticisms but they really are minor issues. A textbook will find that its description of current trials (for example, CML IV) will be out of date by the time it is published. You could quibble about the balance in some areas but there is a welcome overall balance between malignant and non-malignant haematology. Do you find it a challenge to remember CD numbers? I'm almost up to double figures but true enthusiasts can test themselves on seven pages of numbers, taking them up to CD166. The female trainees were not impressed that pregnancy is considered as a systemic disease, nor by the fact that the common haematological problems in pregnancy merit only one page, while the spleen has its own chapter. One could carp over other aspects but the essential point is that the fourth edition of this standard text book succeeds extremely well in providing a readable and visually attractive general overview of haematology. Clinical haematologists like myself attending the BSH or ASH meeting show a high incidence of narcolepsy during some of the presentations. This book will give us a good cutting edge introduction so that at least we can understand the titles of the presentations next time. It can be highly recommended to everyone who works in a haematology department and particularly its target audience of postgraduate students.

J A MURRAY