

# Antibody for detecting p53 protein by immunohistochemistry in normal tissues

F Pezzella, K Micklem, H Turley, K Pulford, M Jones, S Kocialkowski, D Delia, A Aiello, R Bicknell, K Smith, A L Harris, K C Gatter, D Y Mason

## Abstract

**Aims**—To establish whether PAb248 recognises human p53 as well as murine p53 and if so, to determine its distribution in normal tissues.

**Methods**—The ability of PAb248 to recognise human p53 was established by analysis of the human osteosarcoma derived Saos-2 cell line, which lacks the p53 gene, before and after transfection with p53 cDNA, using western blotting and immunoprecipitation. Immunostaining on normal tissues and cell lines was carried out using an immunoperoxidase technique. The two anti-p53 antibodies PAb 240 and DO-7 were used as controls.

**Results**—The anti-p53 PAb248 monoclonal antibody stained the Saos-2 cell line after, but not before, transfection with p53 cDNA. Both western blots and immunoprecipitations performed with this antibody revealed a 53 000 molecular weight band. With immunostaining, this antibody detects p53 protein in most lymphoid and human epithelial cells in a cytoplasmic-perinuclear localisation that has not been described before. In the same tissues nuclear staining could be seen in a few scattered cells using the PAb240 antibody. The topographical distribution of wild type p53 was not related to proliferating areas but, rather, to short-lived populations of cells.

**Conclusions**—Immunostaining of wild type p53 is demonstrable not only in its nuclear form using antibody PAb240 but also in its common cytoplasmic-perinuclear localisation in normal tissues using the PAb248 monoclonal antibody. This opens up new possibilities for its study in both physiological and pathological conditions.

(J Clin Pathol 1994;47:592-596)

It is widely believed that only the accumulation of abnormal p53 protein can be demonstrated by immunohistochemistry.<sup>1</sup> However, several reports, some more than 10 years old, suggest that this is not entirely true. In 1981 Dippold *et al* reported p53 nuclear staining in proliferating and cytoplasmic positivity in quiescent cells in non-neoplastic human cell lines.<sup>2</sup> In 1983 Rotter *et al* showed that p53 is expressed in the perinuclear areas of non-transformed murine cell lines but that this

becomes nuclear after chemically induced neoplastic transformation.<sup>3</sup> In 1984 Milner described two different forms of murine p53: one in resting and one in phytohaemagglutinin (PHA) stimulated splenic lymphocytes<sup>4</sup>; PAb421 antibody, which stains nuclei in tumours,<sup>5</sup> precipitated the protein from PHA blasts but not from resting lymphocytes; PAb248 precipitated p53 only from the splenic small lymphocytes.<sup>4</sup>

During the course of our investigation of p53 expression in several human tumours we noticed that the PAb248 antibody appeared to give results discordant with those obtained with other antibodies on neoplastic tissues (Pezzella *et al* unpublished data) and, furthermore, to produce staining on normal tissue present in the sections.

The PAb248 monoclonal antibody was believed to be specific for murine p53<sup>6</sup> but since it recognises an epitope highly preserved between mouse and man<sup>6</sup> we believed that it might also identify human p53, perhaps in a previously unrecognised form. This study was designed to establish whether PAb248 recognises human p53 and if so, its distribution in normal human tissues.

## Methods

Fresh frozen human tissues were obtained from the histopathology department at the John Radcliffe Hospital, Oxford. Frozen samples were stored at  $-70^{\circ}\text{C}$  until use. The following anti-p53 monoclonal antibodies were used: PAb248<sup>6</sup>; PAb240<sup>7,8</sup>; and DO-7.<sup>9</sup> The anti-vimentin V9 (Dako) antibody was used as a positive control for immunostaining of the Saos-2 cell line and as a negative control in the immunoprecipitation-immunoblot experiments.

Five cell lines established from human tumours were used. The two lines in which p53 protein is not expressed, because of large deletions in the gene, were the osteosarcoma derived Saos-2 cell line,<sup>10</sup> obtained from the American Tissue Culture Collection (ATCC) (Rockville, Maryland, USA) and the promyelocytic leukaemia cell line HL-60.<sup>11</sup> The other three were cell lines expressing p53 protein: the breast carcinoma cell line MCF-7, in which the protein is normal<sup>12</sup>; the colorectal carcinoma cell line HT-29 expressing only mutated p53 protein<sup>13</sup>; and the cell line K 422, for which the gene sequence is as yet unpublished.<sup>14</sup>

Immunoblotting was performed under reducing conditions according to the method

Leukaemia Research Fund  
Immunodiagnostic Unit, Department of Cellular Science, John Radcliffe Hospital, Oxford

F Pezzella  
K Micklem  
K Pulford  
M Jones  
S Kocialkowski  
K C Gatter  
D Y Mason

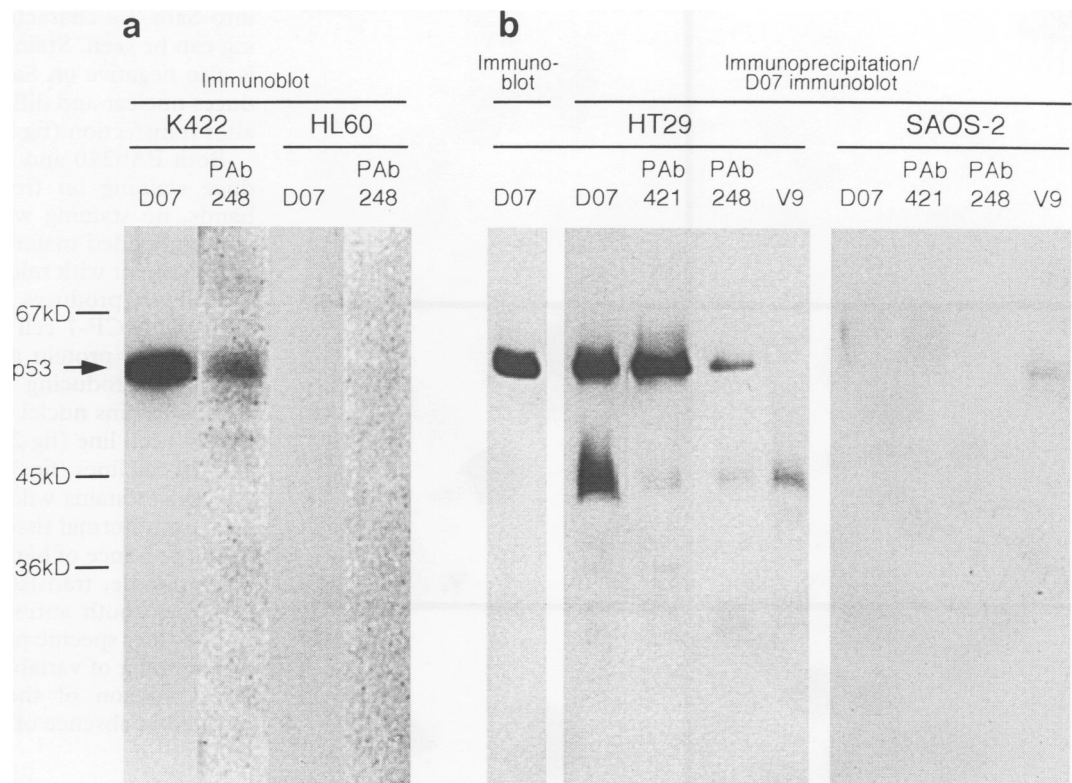
ICRF Molecular Oncology Laboratory, John Radcliffe Hospital, Oxford

H Turley  
R Bicknell  
K Smith  
A L Harris

Oncologia Sperimentale A, Istituto Nazionale dei Tumori, Milan, Italy  
D Delia  
A Aiello

Correspondence to:  
Dr Francesco Pezzella,  
Department of Pathology,  
European Institute of  
Oncology, Via Ripamonti  
435, 20141 Milano, Italy

Accepted for publication  
14 December 1993



**Figure 1** Characterisation of PAb248 by immunoblotting and combined immunoprecipitation and immunoblotting. (A) Immunoblot: lane 1, D0-7 used as positive control; lane 2, PAb248 shows a unique band of 53 000 molecular weight from a p53 positive line (K 422); but not from the HL-60 cell line (lanes 3 and 4); in which the protein is not expressed because of large deletions in the gene. (B) Immunoprecipitation and immunoblot analysis of HT-29 cell line expressing mutated p53 and SAOS-2 cell line not expressing the protein, because of a biallelic gene deletion, with anti-p53 antibodies. Lane 1, immunoblot of HT-29 cells using D0-7 antibody; lanes 2 and 6, immunoprecipitation using D0-7 antibody from HT-29 (lane 2) and SAOS-2 (lane 6) cells; lanes 3 and 7, immunoprecipitation using antibody PAb421 from HT-29 (lane 3) and SAOS-2 (lane 7) cells; lanes 4 and 8, immunoprecipitation using PAb248 antibody from HT-29 (lane 4) and SAOS-2 (lane 8) cells; lanes 5 and 9, negative control immunoprecipitation using anti-vimentin antibody V9 (Dako) from HT-29 (lane 5) and SAOS-2 (lane 9) cells. p53 in the unlabelled immunoprecipitates was detected by immunoblotting with D0-7. The positions of molecular weight markers and the p53 band are indicated.

described by Delia *et al.*<sup>15</sup> and modified by C Schneider *et al.* (National Laboratory CIB, Padriciano, Trieste, Italy, manuscript in preparation) to enhance the antibody binding.

Cells ( $10^7$ /track) were solubilised in non-ionic detergent and buffer containing protease inhibitor. Immunoprecipitation was performed using the antibodies adsorbed to Protein G-Sepharose. Immunoprecipitates were analysed by sodium dodecyl sulphate polyacrylamide gel electrophoresis (SDS-PAGE) under reducing conditions and transferred to Immobilon membranes. For the immunoblot, whole cells ( $10^7$ ) were solubilised and applied to the gel. The membrane was incubated with D0-7 antibody and bound antibody visualised using enhanced chemiluminescence reagents (Amersham UK).

Saos-2 cells obtained from the ATCC (Rockville, Maryland) were transfected with pCMV-neo-Bam plasmid carrying either the wild type pC53-SN3 or the mutated pC53-SCX3 p53 cDNA<sup>16</sup> by electroporation, using a Bio-Rad instrument under the following conditions. Cells ( $10^6$ ) in 400  $\mu$ l RPMI culture medium containing 5% fetal calf serum were incubated directly in the electroporation cell (10 minutes on ice) with 10  $\mu$ g of plasmid previously electroporated. Cells were trans-

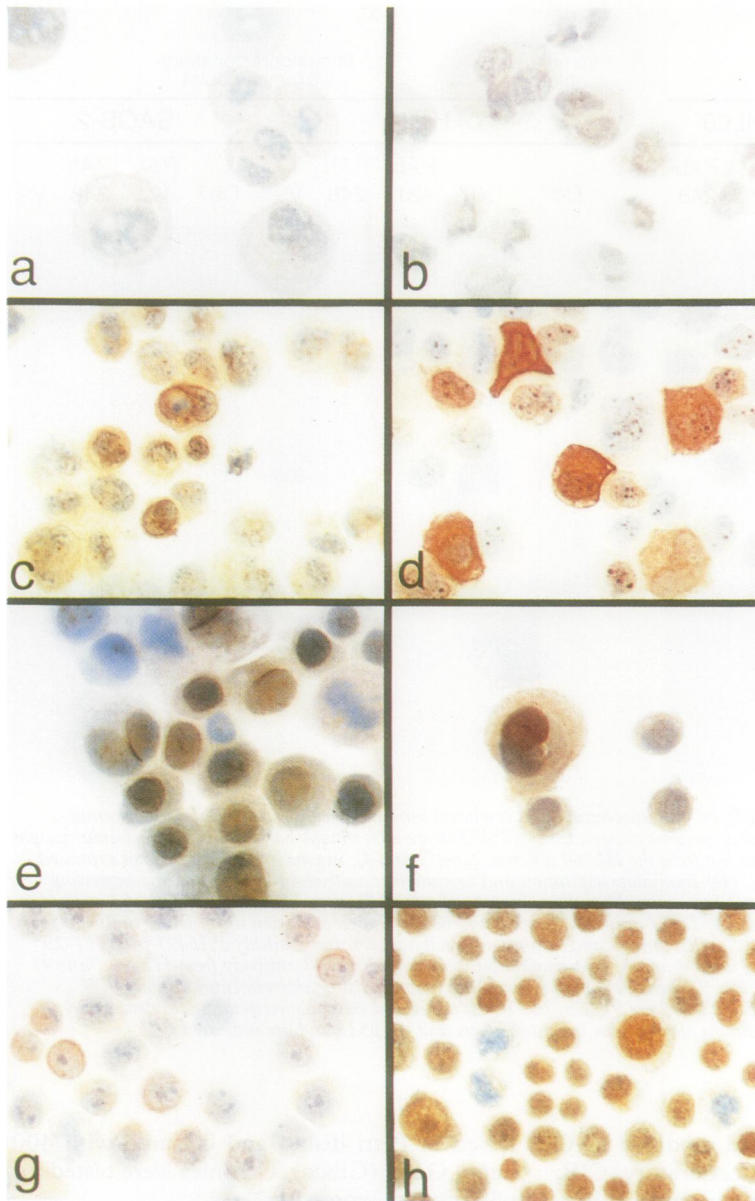
ferred in Petri dishes and cultured with 400 ng/ml G418 (Gibco). Colonies were tested for p53 protein expression.

Immunostaining was performed by the immunoperoxidase technique, as described before.<sup>17</sup>

PAb240 and PAb248 antibodies were tested on paraffin wax embedded sections after microwave pretreatment according to the method of Cattoretti *et al.*<sup>18</sup> Briefly, sections were dewaxed in the usual way, then placed in a glass container containing a 0.01M solution of sodium citrate. The slide container was placed in a microwave oven and heated at 700W (equivalent) twice for five minutes before being transferred to TRIS-buffered saline (TBS) and continuing the immunocytochemistry as usual.

## Results

PAb248 recognises human p53 by immunoblotting (fig 1A) and by immunoprecipitation-immunoblotting (fig 1B). Its ability to recognise specifically human p53 is further demonstrated by its failure to stain the human osteosarcoma Saos-2 cell line (which lacks p53 coding exons<sup>10</sup>) (figs 2A and B). However, after transfection with either the wild type or the mutant gene (figs 2C and D)



**Figure 2** Characterisation of PAb 248 by immunostaining and demonstration of two different forms of p53. Human osteosarcoma Saos-2 cell line, in which on both alleles of the p53 gene the coding exons are deleted (Masuda, et al, 1987), is not stained with (A) PAb248 and (B) PAb240. After transfection with mutated p53 gene, PAb 248 produces pronounced cytoplasmic perinuclear staining (C), characteristic of this antibody; PAb240 stains nuclei and, diffusely, the cytoplasm (D). Immunostaining of the cell lines MCF-7, expressing wild type p53 (Casey et al 1991) (E-F) and HT-29, expressing mutated p53 (G-H) produces the same pattern seen in the transfected cells with PAb248, revealing perinuclear p53 (E-G) and PAb240, producing nuclear staining (F-H).

#### Wild type p53 expression in normal human tissues

|  | PAb248:<br>Perinuclear<br>staining | PAb240:<br>Nuclear staining |
|--|------------------------------------|-----------------------------|
| <i>Peripheral blood and lymphoid tissues</i> |                                    |                             |
| Peripheral blood lymphocytes                 | Negative                           | Negative                    |
| Neutrophils                                  | Positive (all)                     | Positive (a few)            |
| <i>Lymph node, tonsil, and spleen:</i>       |                                    |                             |
| Paracortical area                            | Positive                           | Positive (a few)            |
| Mantle zone                                  | Positive                           | Negative                    |
| Germinal centres                             | Positive                           | Positive (a few)            |
| Endothelia                                   | Negative                           | Negative                    |
| <i>Thymus</i>                                |                                    |                             |
| Cortex                                       | Positive                           | Positive (a few)            |
| Medulla                                      | Positive                           | Negative                    |
| <i>Other tissues</i>                         |                                    |                             |
| Liver (hepatocytes)                          | Negative                           | Negative                    |
| Stomach                                      | Positive (a few)                   | Negative                    |
| Duodenum                                     | Positive                           | Negative                    |
| Colon  | Positive                           | Negative                    |
| Respiratory epithelium                       | Positive                           | Negative                    |
| Kidney                                       | Negative                           | Negative                    |
| Prostate                                     | Positive                           | Negative                    |

into Saos-2 a characteristic perinuclear staining can be seen. Staining with PAb240, which is also negative on Saos-2 cells (fig 2B), produces nuclear and diffuse cytoplasmic staining after transfection (fig 2D).

Both PAb240 and PAb248 antibodies produce staining on frozen tissue but, in our hands, no staining was obtained on paraffin wax-embedded material either before or after pretreatment with microwaves.

PAb248 produces perinuclear staining of both the MCF-7 cell line (fig 2E) expressing normal p53 protein and the HT-29 cell line (fig 2G) producing only mutated protein. PAb240 stains nuclei of only a few cells in the MCF-7 cell line (fig 2F) and of almost all the HT-29 cell lines (fig 3).

PAb248 stains wild type p53 in numerous cells from normal tissues (table, figs 3 and 4). In the presence of high protein concentrations (for example, transfected Saos-2 or HT-29<sup>13</sup> cell lines) both antibodies produce, in addition to their specific patterns, diffuse cytoplasmic staining of variable intensity (figs 2C and D). Omission of the first antibody always resulted in absence of staining.

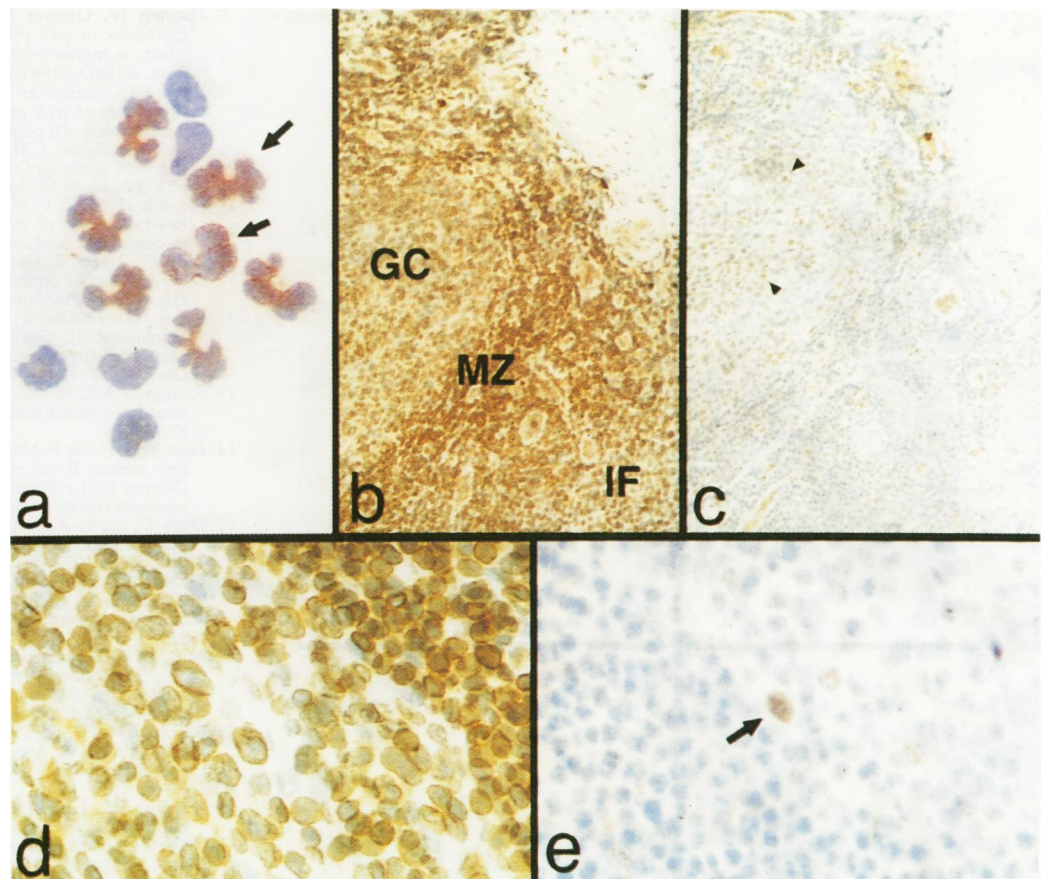
#### Discussion

In this study we have shown that p53 is detectable in many cells from normal human tissues by immunostaining, and that the protein in these cells is present in two forms: cytoplasmic-perinuclear, as stained by PAb248; and nuclear, this pattern being only occasionally detectable, with PAb240.

This cytoplasmic-perinuclear localisation has not been described before in normal human tissues. However, it is not a total surprise because of its description in an embryonic murine cell line<sup>3</sup> and the evidence for a putative cytoplasmic protein able to link with p53.<sup>19</sup> Furthermore, perinuclear staining was described in the human breast cancer cell line MDA 157 by Bartek *et al*<sup>20</sup> by immunostaining with PAb240. The authors comment that although this pattern of staining could have been due to the presence of a protein cross-reacting with PAb240, this is unlikely, and that it might instead be caused by the presence of perinuclear p53. They support this conclusion on the grounds that perinuclear location is characteristic of centrosomes and that it has been reported that, "p53 can bind to murine p34cdc2 and that p34 cdc2 is present in the centrosome."<sup>20</sup> They also point out that on the same cell line staining with two other anti-p53 antibodies (PAb421 and PAb1801) was negative and consequently if the protein in question is p53, it is "a p53 molecule which has lost both the PAb421 and PAb1801 epitopes".<sup>20</sup> Our findings strongly support their view that the p53 protein molecule exists in different conformations, and show that one of these has a high affinity for PAb248.

Nuclear staining for p53 in occasional normal cells has been reported both in proliferating germinal centre cells<sup>21</sup> and quiescent cells, such as epithelial parabasal cells of the





**Figure 3** P53 expression in normal human peripheral blood and reactive tonsil. (A) PAb248 does not stain peripheral blood small lymphocytes, but neutrophils show the characteristic perinuclear positivity (arrows). Staining of a reactive tonsil shows diffuse positivity with PAb248 (B) in germinal centre (GC), mantle zone (MZ), and interfollicular areas (IF), and a few cells positive with PAb240 (C) (arrows). Higher magnification shows that PAb248 gives strong cytoplasmic perinuclear staining (D) whereas PAb240 stains nuclei (E) (arrows).

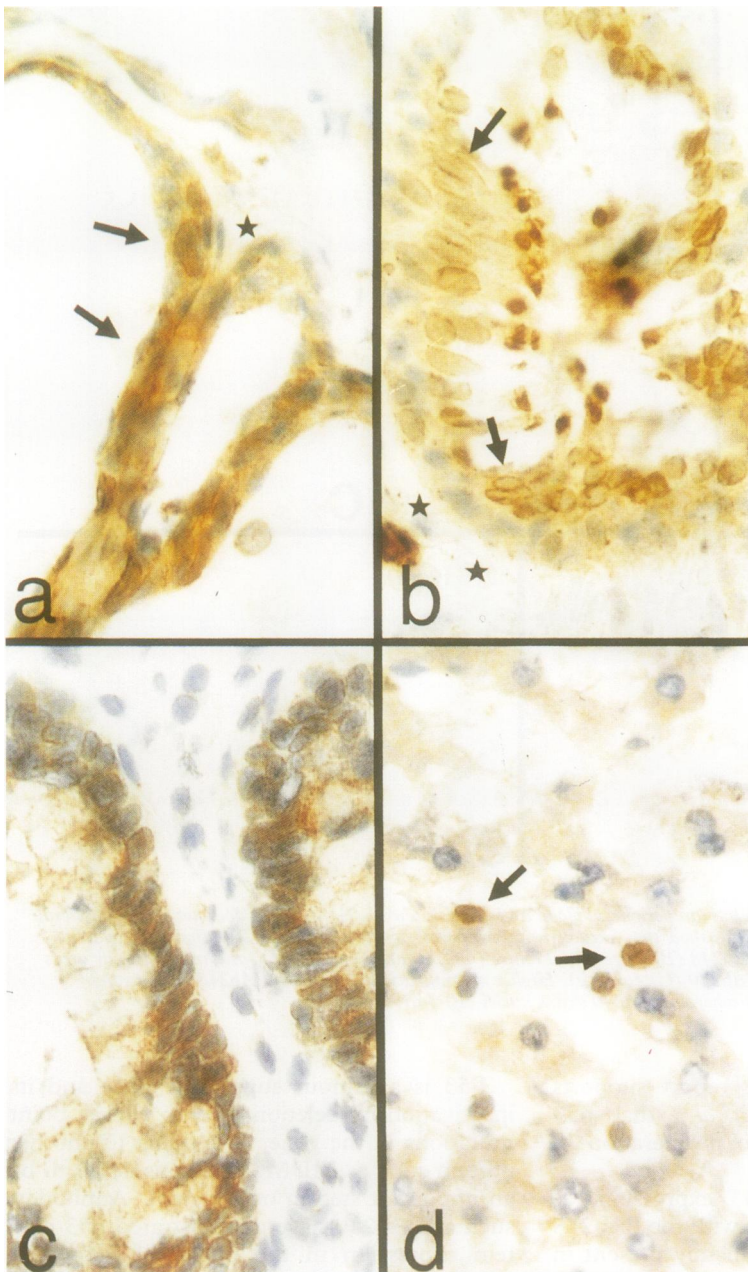
oesophageal mucosa.<sup>22</sup> Our report supports the evidence by Sasano *et al*<sup>22</sup> that p53 expression is not related to proliferation in normal tissues.

Our data show that p53 expression, as detected by immunostaining with the PAb248 and PAb240 antibodies, is mainly present in tissues characterised by occurrence of cell death by apoptosis. Indeed, its expression in lymphoid, myeloid, and epithelial cells is complementary to that of *bcl-2* protein, which protects cells from death by apoptosis.<sup>23</sup> Peripheral blood lymphocytes are *bcl-2* positive<sup>24</sup> but p53 negative (fig 3A). Small lymphocytes in tissues are *bcl-2*<sup>24</sup> and perinuclear p53 positive (fig 3D) but *bcl-2* negative germinal centre cells,<sup>24</sup> most of which are going to die by apoptosis, retain cytoplasmic p53, and occasionally express nuclear p53 (figs 3B-E). Circulating granulocytes are *bcl-2* negative,<sup>23</sup> but p53 positive (fig 3A). In organs such as prostate and lung, basal proliferating cells are p53 negative (figs 4A and B) and *bcl-2* positive.<sup>25,26</sup> The upper layers of well differentiated cells show cytoplasmic-perinuclear p53 (figs 3A and B) but *bcl-2* is absent.<sup>25,26</sup> The data are consistent with the hypothesis that these two proteins belong to two different pathways: one, which includes *bcl-2*, prevents cells from apoptosis<sup>23</sup> while the other, to which p53 belongs, is likely to arrest cellular growth and perhaps to induce cell death.<sup>27-30</sup>

P53 is a tumour suppressor gene and its inactivation by deletion of both alleles, point mutations in the gene, or binding to another protein such as MDM2,<sup>31</sup> is considered to be an important step in oncogenesis. Antibodies such as PAb240 have demonstrated p53 protein expression in the nuclei of neoplastic cells, which in some cases, is due to an underlying point mutation of the gene. PAb248 antibody will permit a full evaluation of p53 expression by immunohistochemistry, making it possible to identify tumours truly lacking detectable protein, or those with a normal pattern of p53 expression. Furthermore, the use of PAb248 now gives researchers the possibility of investigating the expression of human p53 "in vivo" and "in vitro" to reach an understanding of its normal function.

We thank Professor David Lane for kindly providing all the anti-p53 antibodies used in this study and Mr Enrico Fontanella for his excellent technical assistance.

- 1 Iggo R, Gatter K, Bartek J, Lane D, Harris AL. Increased expression of mutant forms of p53 oncogene in primary lung cancer. *Lancet* 1990;335:675-9.
- 2 Dippold WG, Jay G, DeLeo AB, Khoury G, Old LJ. p53 transformation-related protein: detection by monoclonal antibody in mouse and human cells. *Proc Natl Acad Sci USA* 1981;78:1695-9.
- 3 Rotter V, Abutbul H, Ben-Ze'ev AA. P53 transformation-related protein accumulates in the nucleus of transformed fibroblasts in association with the chromatin and is found in the cytoplasm of non-transformed fibroblasts. *EMBO J* 1983;2:1041-7.



**Figure 4** P53 expression in normal human tissues. With PAb248 prostatic (A) and respiratory (B) epithelium show positive cytoplasmic-perinuclear staining in the upper layer of non-proliferating well differentiated cells (arrows). Basal cells (\*) are mostly negative. Colonic mucosa (C) is mostly positive with PAb248. In liver (D) hepatocytes are PAb248 negative whereas sporadic lymphoid cells are positive (arrows) showing that p53 is not expressed in all tissues.

- 4 Milner J. Different forms of p53 detected by monoclonal antibodies in non-dividing lymphocytes. *Nature* 1984; 310:143-5.
- 5 Van Den Berg FM, Tigges AJ, Scipper MEI, Den Hartog-Jager, Kroes WGM, Walboomers JMM. Expression of the nuclear oncogene p53 in colon tumours. *J Pathol* 1989;157:193-9.
- 6 Yewdell JW, Gannon JV, Lane DP. Monoclonal antibody analysis of p53 expression in normal and transformed cells. *J Virol* 1986;59:444-52.

- 7 Gannon JV, Greaves R, Iggo R, Lane DP. Activating mutations in p53 produce a common conformational effect. A monoclonal antibody specific for the mutant form. *EMBO J* 1991;9:1595-602.
- 8 Rivas CI, Wisniewski D, Strife AB, et al. Constitutive expression of p53 protein in enriched normal human marrow blast cell populations. *Blood* 1992;78:1982-6.
- 9 Vojtesek B, Bartek J, Midgley CA, Lane DP. An immunohistochemical analysis of the human nuclear phosphoprotein p53. *J Immunol Methods* 1992;151:237-44.
- 10 Masuda H, Miller C, Koeffler HP, Battifora H, Cline MJ. Rearrangement of the p53 gene in human osteogenic sarcoma. *Proc Natl Acad Sci USA* 1987;84:7716-9.
- 11 Wolf D, Rotter V. Major deletions in the gene encoding the p53 tumor antigen cause lack of p53 expression in HL-60 cells. *Proc Natl Acad Sci USA* 1985;82:790-4.
- 12 Casey G, Lo-Hsueh M, Lopez ME, Vogelstein B, Stanbridge EJ. Growth suppression of human breast cancer cells by the introduction of a wild-type p53 gene. *Oncogene* 1991;6:1791-7.
- 13 Rodriguez NR, Rowan A, Smith MFE, et al. P53 mutations in colorectal cancer. *Proc Natl Acad Sci USA* 1990; 87:7555-9.
- 14 Dyer MJS, Fisher P, Nacheva E, Labastide W, Karpas A. A new human B-cell non-Hodgkin's lymphoma cell line (Karpas 422) exhibiting both t(14;18) and t(4;11) chromosomal translocations. *Blood* 1990;75:709-14.
- 15 Delia D, Aiello A, Soligo D, et al. bcl-2 proto-oncogene expression in normal and neoplastic human myeloid cells. *Blood* 1992;79:1291-8.
- 16 Backer SJ, Markowitz S, Fearon ER, Willson JK, Vogelstein B. Suppression of human colorectal carcinoma cell growth by wild type p53. *Science* 1990;249: 912-5.
- 17 Mason DY, Abdulaziz ZA, Falini B, Stein H. Single and double immunoenzymatic techniques for labelling tissue sections with monoclonal antibodies. *Ann N Y Acad Sci* 1984;420:127-33.
- 18 Cattoretti G, Pileri S, Parravicini C, Becker MHG, Poggi S, Bifulco C, et al. Antigen unmasking on formalin-fixed, paraffin-embedded tissue sections. *J Pathol* 1993;171: 83-98.
- 19 Gannon JV, Lane DP. Protein synthesis required to anchor a mutant p53 protein which is temperature-sensitive for nuclear transport. *Nature* 1991;349:802-6.
- 20 Bartek J, Iggo R, Gannon J, Lane DP. Genetic and immunohistochemical analysis of mutant p53 in human breast cancer cell lines. *Oncogene* 1990;5:893-9.
- 21 Villuendas R, Piris MA, Orradre JL, et al. P53 protein expression in lymphomas and reactive lymphoid tissue. *J Pathol* 1992;166:235-41.
- 22 Sasano H, Miyazaki S, Gotoh Y, Nishihira T, Sawai T, Nagura H. Expression of p53 in human esophageal carcinoma. An immunohistochemical study with correlation to proliferating cell nuclear antigen expression. *Hum Pathol* 1992;23:1238-43.
- 23 Hockenberry D, Nunez G, Milliman C, Scriver RD, Korsmeyer SJ. Bcl-2 is an inner mitochondrial membrane protein that blocks programmed cell death. *Nature* 1990;348:334-6.
- 24 Pezzella F, Tse A, Cordell JL, Pulford KAF, Gatter KC, Mason DY. Expression of the bcl-2 protein is not specific for the 14;18 chromosomal translocation. *Am J Pathol* 1990;137:225-32.
- 25 Hockenberry DM, Zutter M, Hickey W, Nahm M, Korsmeyer SJ. BCL2 protein is topographically restricted in tissues characterized by apoptotic cell death. *Proc Natl Acad Sci USA* 1991;88:6961-5.
- 26 Pezzella F, Turley H, Kuzu I, et al. Bcl-2 protein in non-small-cell lung carcinoma. Immunohistochemical evidence for abnormal expression and correlation with survival. *N Engl J Med* 1993;329:690-4.
- 27 Yonis-Rouach E, Resnitzky D, Lotem J, Sachs L, Kimchi A, Oren M. Wild type p53 induces apoptosis of myeloid leukaemic cells that is inhibited by interleukin-6. *Nature* 1991;352:345-7.
- 28 Shaw P, Bovey R, Tardy S, Sahali R, Sordat B, Costa J. Induction of apoptosis by wild-type p53 in a human colon tumor-derived cell line. *Proc Natl Acad Sci USA* 1992;89:4495-9.
- 29 Lowe SW, Schmitt EM, Smith SW, Osborne BA, Jacks T. p53 is required for radiation-induced apoptosis in mouse thymocytes. *Nature* 1993;362:847-9.
- 30 Clarke AR, Purdie CA, Harrison DJ, et al. Thymocytes apoptosis induced by p53-dependent and independent pathways. *Nature* 1993;362:849-52.
- 31 Oliner JD, Kinzler KW, Meltzer PS, George DL, Vogelstein B. Amplification of a gene encoding a p53-associated protein in human sarcomas. *Nature* 1992;358: 80-3.