

# Ultrastructural study of two patterns in the interaction of *Helicobacter pylori* with neutrophils

H Rautelin, C-H von Bonsdorff, B Blomberg, D Danielsson

## Abstract

**As evidenced by electron microscopy, unopsonised bacteria of some *Helicobacter pylori* strains were readily taken into cytoplasmic vacuoles of human neutrophils; those of other strains were only rarely absorbed. The strains engulfed like this also induced strong oxidative burst reactions in neutrophils, as measured by chemiluminescence. This has been associated with peptic ulcer disease, in the past. The ultrastructural interaction patterns agreed with the reaction patterns shown by chemiluminescence.**

(J Clin Pathol 1994;47:667-669)

The causal association between *Helicobacter pylori* infection and active chronic gastritis,<sup>1,2</sup> and its association with peptic ulcer disease<sup>3</sup> have been confirmed. The exact pathogenetic mechanisms are still not known. In the attendant gastric inflammation is almost invariably an infiltration of the mucosal wall by polymorphonuclear leucocytes, lymphocytes, and monocytes. We have recently shown that unopsonised organisms of some strains of *H pylori* rapidly adhere to human neutrophils in vitro, resulting in visible agglutination. These also induced a rapid and strong oxidative burst in polymorphonuclear leucocytes, as measured by chemiluminescence.<sup>4</sup> Such strains occurred significantly more often in patients with peptic ulcers than in patients with gastritis alone. The aim of this study was to discover whether unopsonised *H pylori* organisms could be phagocytosed by polymorphonuclear leucocytes and, if so, whether this was concordant with the reaction pattern in chemiluminescence.

## Methods

Four *H pylori* strains were used in the experiments: reference strain NCTC 11637, which, unopsonised, adheres rapidly to neutrophils and induces a rapid and strong oxidative burst in chemiluminescence; a Canadian strain designated C 7050 with low adherence and oxidative burst rates; and two additional strains isolated from gastric biopsy specimens of patients at our hospital. One of the clinical isolates (O 30/90) induced a strong oxidative burst in polymorphonuclear leucocytes, as measured by chemiluminescence, and the other strain (O 1/90) gave a slow and weak chemiluminescence pattern. The reactions of the two types of strains were studied in parallel

and always with the same set of polymorphonuclear leucocytes.

The strains were stored at -70°C before use and for experiments were grown on GC agar plates (GC agar base, BBL, Cockeysville, Maryland, USA, supplemented with 1% bovine haemoglobin (BBL), 10% horse serum, and 1% IsoVitalex) without antibiotics.

Blood anticoagulated with heparin was obtained from four members of staff who did not have raised *H pylori* antibody titres by enzyme immunoassay.<sup>5</sup> Blood from a single donor was used for each series of experiments on a particular day. To obtain polymorphonuclear leucocytes the method of Böyum was used with minor modifications.<sup>6</sup>

Live bacteria ( $10^8$ /ml) and polymorphonuclear leucocytes ( $2 \times 10^6$ /ml) in phosphate buffered saline (same proportions as in chemiluminescence) were incubated on a roller at 37°C and aliquots for electron microscopy were removed at different time intervals. Samples were fixed by adding an equal volume of 5% glutaraldehyde (EMS, Fort Washington, Pennsylvania, USA) in 0.1 N sodium cacodylate and the fixation was allowed to continue for at least one hour. The fixative was then exchanged to cacodylate buffer with 0.2 M sucrose until further processing. Postfixation was performed with 1% osmium tetroxide in cacodylate buffer for one hour at room temperature, and stained en bloc in 1% uranyl acetate over night. Dehydration was done through ethanol series and the pellets were embedded in LX-112 (Ladd Research Ind, Burlington, Vermont, USA) after propylene oxide incubations. Thin sections were cut with a diamond knife and the sections were poststained with lead hydroxide. Electron micrographs were taken with a Jeol 100 CX II microscope.

## Results

Mixing bacteria of the strains NCTC 11637 or O 30/90 with polymorphonuclear leucocytes resulted in an immediate attachment of the bacteria to the cells. After one minute of incubation, typically, many bacteria adhered to the plasma membrane (fig 1). The attachment to the plasma membrane is characterised by a very regular apposition about 5 nm away from the two membranes (fig 2A), but the cytoplasm underneath the attachment site does not show any morphological changes in contrast to the findings with some invasive bacteria.<sup>7</sup> Intracellular bacteria were found in

Department of  
Clinical Microbiology  
and Immunology  
H Rautelin  
D Danielsson

Department of  
Medicine,  
Division of  
Gastroenterology,  
B Blomberg

Örebro Medical  
Centre, Örebro,  
Sweden

Department of  
Bacteriology and  
Immunology,  
H Rautelin

Department of  
Virology  
C-H von Bonsdorff

University of Helsinki,  
Finland

Correspondence to:  
Dr Hilpi Rautelin,  
Department of Bacteriology  
and Immunology, PO Box  
21, Haartmaninkatu 3,  
SF-00014, University of  
Helsinki, Finland

Accepted for publication  
9 February 1994

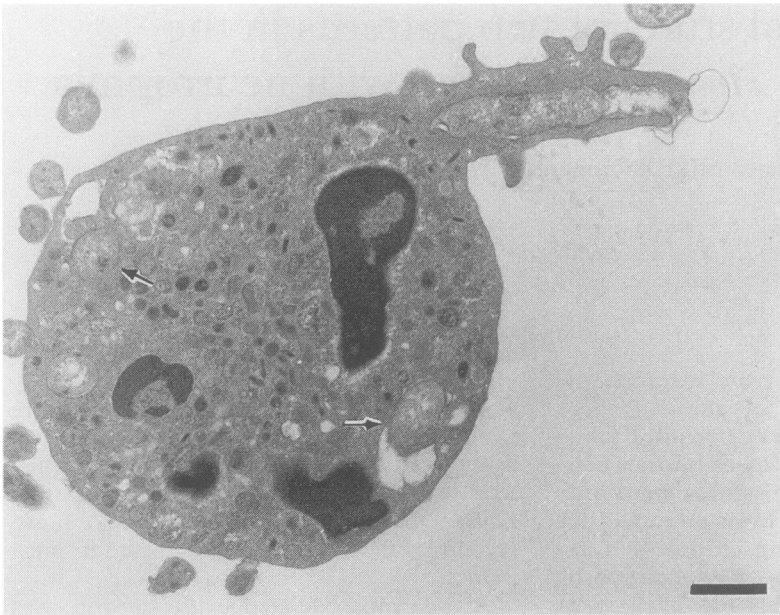


Figure 1 Electron micrograph of a polymorphonuclear cell after one minute of incubation with the NCTC 11637 strain of *H. pylori*. In addition to the one bacterium in the process of being engulfed, there are a few bacteria already located in apparent cytoplasmic vacuoles (arrows). Bar = 1.0  $\mu$ m.

vacuoles rather tightly surrounding the bacterium. In successive samples an increasing number of internalised bacteria were seen (fig 2B). In some instances the vacuoles became larger, lysosome-like, and seemed to contain not only remnants of bacteria but also mor-

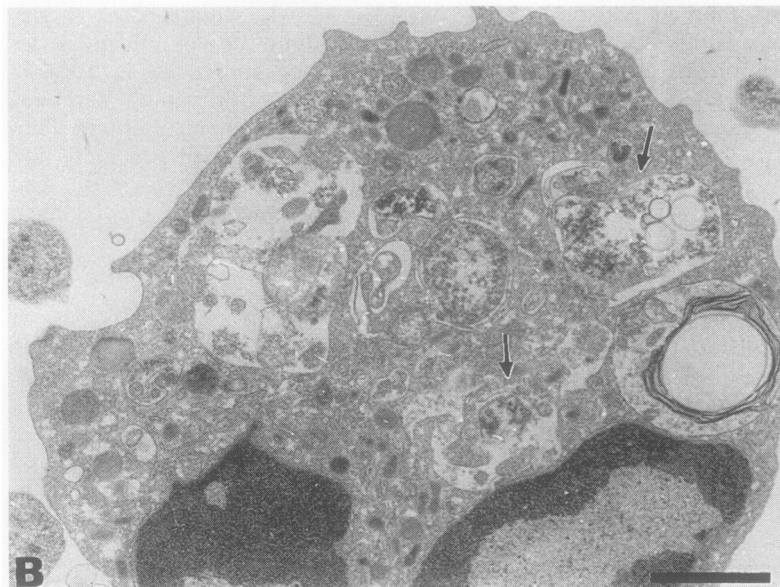
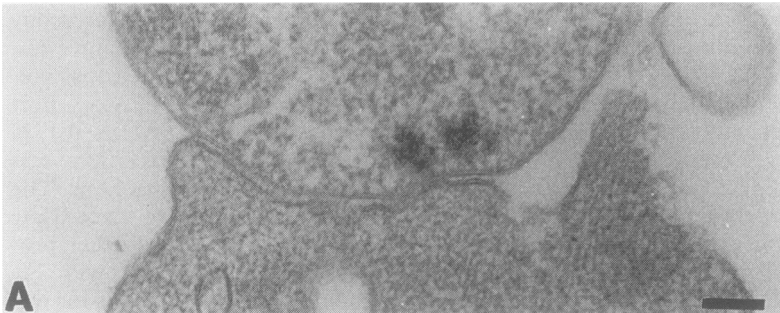


Figure 2 Interaction of the clinical isolate O 30/90 of *H. pylori* with human polymorphonuclear leucocytes. Incubation was for five minutes. (A). Detail of the contact between the bacterium (above) and the plasma membrane. Note the uniform distance between the two membranes. No discernible changes in the cytoplasmic structures at the attachment site are observed. Bar = 100 nm. (B). Numerous intracellular bacteria, some of which seem to be disintegrating in lysosome-like structures (arrows). Bar = 1.0  $\mu$ m.

phologically intact bacteria. In samples incubated for up to one hour there were still many intact-looking bacteria inside cellular vacuoles. In no instance were organisms found in the free cytoplasm—that is, without a surrounding cellular membrane.

In contrast, the strains C 7050 and O 1/90 did not show any particular tendency to attach to the cells, not even after prolonged incubation for up to one hour. Only occasionally were bacteria seen attached to the cells, and intracellular organisms were only rarely found.

## Discussion

Bernatowska *et al*<sup>8</sup> have shown *H. pylori* within phagocytic vacuoles of neutrophils in the presence of complement. Recently Andersen *et al*<sup>9</sup> reported that *H. pylori* was also phagocytosed without the presence of opsonins, but those experiments were mainly performed with a single strain. In the present study two different patterns in the interaction of *H. pylori* with polymorphonuclear leucocytes have been shown. The rapid ingestion of the organisms of the strains NCTC 11637 and O 30/90 reflected our previous findings of the ability of these strains to induce a rapid oxidative burst in polymorphonuclear leucocytes, as measured by luminol-enhanced chemiluminescence.<sup>4</sup> The peak values in chemiluminescence were obtained within five to 15 minutes,<sup>4</sup> thus coinciding with the phagocytosis verified by electron microscopy in this study.

Some of the bacteria of the NCTC 11637 and O 30/90 strains found in the phagocytic vacuoles after 60 minutes of incubation were coccoidal in form, and in some instances obviously destroyed. Our recent study<sup>4</sup> did not show any phagocytic killing of *H. pylori* in polymorphonuclear leucocytes unless complement was added. However, further studies are needed to clarify if the ingested NCTC 11637 type of bacteria can survive in polymorphonuclear leucocytes. The ingested bacteria in this study were never found free in cytoplasm and thus the internalisation observed here does not resemble the one described for invasive bacteria, such as *Listeria* or some *Shigella* strains.<sup>7</sup>

A typical feature for *H. pylori* infection in the gastric mucosa is an abundant infiltrate of polymorphonuclear leucocytes. We have described a novel heat-labile activity, present in those *H. pylori* strains like NCTC 11637 and O 30/90, which shows rapid and strong oxidative burst reactions in neutrophils, as measured by chemiluminescence. Reactive oxygen metabolites, such as superoxide radicals ( $O_2^{\cdot-}$ ), hydrogen peroxide ( $H_2O_2$ ), and hydroxyl radicals ( $\cdot OH$ ) can depolymerise gastric mucin,<sup>10</sup> and moreover, such radicals are strongly toxic to various types of tissue cells. When *H. pylori* organisms penetrate the mucus layer they may meet and challenge neutrophils and *H. pylori* cells of the NCTC 11637 type might then induce oxidative bursts in the neutrophils. It is tempting to speculate that the rapid liberation of reactive

metabolites might act both by changing viscoelastic properties of the mucin (thus facilitating penetration?) and by causing tissue injuries, and thus paving the way for peptic ulcer disease.

This work was partly supported by the Research Committee of Örebro County Council and the Örebro Medical Center Research Foundation. We thank M Jurstrand and A Mörtinen for their excellent technical help.

This work was presented in part at the VI European Workshop on Gastrointestinal Pathology and *Helicobacter pylori* (*Acta Gastroenterologica Belgica* 1993;56 (Suppl):119 (Abstract)).

- 1 Marshall BJ, Armstrong JA, McGeachie DB, Glancy RJ. Attempt to fulfill Koch's postulates for pyloric campylobacter. *Med J Aust* 1985;142:436-43.
- 2 Morris A, Nicholson G. Ingestion of Campylobacter pyloridis causes gastritis and raised fasting gastric pH. *Am J Gastroenterol* 1987;82:192-9.
- 3 Rauws EAJ, Tytgat GNJ. Cure of duodenal ulcer associ-

- ated with eradication of *Helicobacter pylori*. *Lancet* 1990;335:1233-5.
- 4 Rautelin H, Blomberg B, Fredlund H, Järnerot G, Danielsson D. Incidence of *Helicobacter pylori* strains activating neutrophils in patients with peptic ulcer disease. *Gut* 1993;34:599-603.
- 5 Kosunen TU, Höök J, Rautelin HI, Myllylä G. Age-dependent increase of Campylobacter pylori antibodies in blood donors. *Scand J Gastroenterol* 1989;24:110-4.
- 6 Fredlund H, Olcen P, Danielsson D. A reference procedure to study chemiluminescence induced in polymorphonuclear leukocytes by *Neisseria meningitidis*. *APMIS* 1988;96:941-9.
- 7 High N, Mounier J, Prevost MC, Sansonetti PJ. IpaB of *Shigella flexneri* causes entry into epithelial cells and escape from the phagocytic vacuole. *EMBO J* 1992;11:1991-9.
- 8 Bernatowska E, Jose P, Davies H, Stephenson M, Webster D. Interaction of Campylobacter species with antibody, complement and phagocytes. *Gut* 1989;30:906-11.
- 9 Andersen LP, Blom J, Nielsen H. Survival and ultrastructural changes of *Helicobacter pylori* after phagocytosis by human polymorphonuclear leukocytes and monocytes. *APMIS* 1993;101:61-72.
- 10 Grisham MB, von Ritter C, Smith BF, Lamont JT, Granger DN. Interaction between oxygen radicals and gastrin mucin. *Am J Physiol* 1987;253:G93-6.

*J Clin Pathol* 1994;47:669-671

## IgD multiple myeloma with thoracic spine compression due to epidural extra-osseous tumour spread

Y I Lolin, C W Lam, W H Lo, K L Au, J R L Masarei

### Abstract

**On initial presentation of a patient with IgD multiple myeloma there were no features to suggest an unusual variant. Two months later she developed spinal cord compression due to an IgD plasmacytoma. This complication of IgD myeloma has rarely been reported. During the course of the disease and using the routine laboratory protocol for investigating and identifying paraproteins, including IgD, the patient's results became indistinguishable from those in Bence-Jones proteinuria myeloma.**

(*J Clin Pathol* 1994;47:669-671)

IgD myeloma is rare.<sup>1-4</sup> It generally follows a shorter course than other forms of myeloma, with more frequent extra-osseous spread, renal insufficiency, Bence-Jones proteinuria and atypical presentations and complications.<sup>1-3</sup> The paraprotein band is also often either not visible or faint and diffuse.<sup>1,4,5</sup> This, in conjunction with the usual large excess of Bence-Jones protein in the urine, can lead to a misdiagnosis of a Bence-Jones proteinuria myeloma.<sup>6</sup>

We report, as far as we are aware, the first documented case of IgD multiple myeloma in a Hong Kong Chinese patient. Although initially there were no distinctive features to suggest a rarer myeloma, she later developed thoracic spinal cord compression due to a soft

tissue plasmacytoma. This particular complication is rare with IgD myelomas: our case seems to be only the second one described in the English language.<sup>7</sup>

### Case report

A 55 year old Chinese woman presented with spontaneous low back pain. She had also had an episode of back pain one month earlier after a fall. Physical examination showed that she was pale, with muscle spasm over the lower back and local tenderness over the L5 vertebra, but was otherwise unremarkable. Investigations showed a haemoglobin of 103 g/l, normochromic normocytic anaemia, an erythrocyte sedimentation rate of 60 mm/first hour, white cells of  $5 \times 10^9/l$  (with a normal differential count) and a platelet count of  $171 \times 10^9/l$ . The serum renal and liver function tests all yielded normal results. Serum total protein was 75 g/l, albumin 52 g/l, and the albumin adjusted calcium 2.33 mmol/l. X-ray pictures of the lumbar spine showed a collapsed L5 vertebra. Skull x ray pictures showed multiple osteolytic lesions and a trephine bone marrow biopsy specimen of the iliac crest showed 95% plasma cells. The serum IgA was 0.5 g/l (range 1.25-4.26), IgG 7.18 g/l (range 7.90-17.90), and IgM 0.27 g/l (range 0.63-3.07 g/l). Serum protein electrophoresis (agarose gels; Beckman Paragon SPE kit) showed a small, discrete paraprotein band of 4 g/l in the mid  $\beta/\gamma$  region (figure). Urine contained 0.9 g/l of protein and a faint

Department of  
Chemical Pathology,  
Prince of Wales  
Hospital, Chinese  
University of Hong  
Kong, Shatin, NT,  
Hong Kong  
Y I Lolin  
J R L Masarei

Department of  
Pathology, Princess  
Margaret Hospital,  
Princess Margaret  
Road, Lai Chi Kok,  
Hong Kong  
C W Lam  
W H Lo  
K L Au

Correspondence to:  
Dr Y I Lolin

Accepted for publication  
11 January 1994