

Contents lists available at [ScienceDirect](http://www.sciencedirect.com)

## International Journal of Surgery Case Reports

journal homepage: [www.casereports.com](http://www.casereports.com)

## Traumatic brain injury with a machete penetrating the dura and brain: Case report from southeast Mexico



Juan D. Del Castillo-Calcano<sup>a,b,\*</sup>, Ulises Bravo-Angel<sup>c,f</sup>, Raúl Mendez-Olan<sup>c</sup>,  
Francisco Rodriguez-Valencia<sup>d</sup>, Javier Valdés-García<sup>e</sup>, Ulises García-González<sup>a,b,d</sup>,  
Guy G. Broc-Haro<sup>a,d,e</sup>

<sup>a</sup> Neurosurgery, National Autonomous University of Mexico (UNAM), Mexico City, Mexico

<sup>b</sup> Neurosurgery Department, Mexican Oil Company (Pemex) High Specialty Hospital, Mexico City, Mexico

<sup>c</sup> Neurosurgery Department, Mexican Oil Company (Pemex) Regional Hospital, Villahermosa, Tabasco, Mexico

<sup>d</sup> Neurosurgery Department, The American British Cowdray Hospital, Mexico City, Mexico

<sup>e</sup> Neurosurgery Department, Social Security Institute for State Workers (ISSSTE) López Mateos Regional Hospital, Mexico City, Mexico

<sup>f</sup> Neurosurgery Department, Social Security Institute of Tabasco (ISSET) Medical Specialty Center "Julian A Manzur Ocaña", Villahermosa, Tabasco, Mexico

### ARTICLE INFO

#### Article history:

Received 8 April 2016

Received in revised form 20 April 2016

Accepted 24 April 2016

Available online 28 April 2016

#### Keywords:

Machete

Traumatic brain injury

Decompressive craniectomy

Case report

### ABSTRACT

**INTRODUCTION:** Traumatic Brain Injury (TBI) is a major cause of death and disability in our society, we present the first case report of non-missile penetrating (NMP) cranial trauma with a machete in Mexico, and our objective by presenting this case is to prove the usefulness of recently proposed algorithms in the treatment of NMP

**PRESENTATION OF CASE:** We present the case of a 47 year old woman who received a machete hit to the right side of her head during an assault, she arrived fully conscious to the emergency department (ED), computed tomography was performed and based on the findings of this study and in accordance to recently proposed algorithms for managing NMP cranial trauma a craniotomy was performed, at follow-up the patient presented with minor neurological disability in the form of left hemiparesis.

**DISCUSSION:** Non-missile penetrating (NMP) lesions are defined as having an impact velocity of less than 100 m/s, causing injury by laceration and maceration, An algorithm for treating NMP cranial trauma has been recently published in the Journal World Neurosurgery by De Holanda et al., in this case we followed the algorithm in order to provide best care available for our patient with good results.

**CONCLUSION:** The use of current algorithms for managing NMP cranial trauma has proved to be very useful when applied on this particular case. GCS on admission is an important prognostic factor in NMP cranial trauma.

© 2016 The Author(s). Published by Elsevier Ltd on behalf of IJS Publishing Group Ltd. This is an open access article under the CC BY-NC-ND license (<http://creativecommons.org/licenses/by-nc-nd/4.0/>).

## 1. Introduction

Traumatic Brain Injury (TBI) is a major cause of death and disability in our society, in Mexico, it is considered the third cause of death with a mortality index of 38.8 per 100,000 habitants and its peak incidence is in males with an age range from 15 to 45 years [1].

Case reports and case series of cranial injuries caused by machetes have been reported in the literature, mainly in African countries, there is to date no case report or case series of a pen-

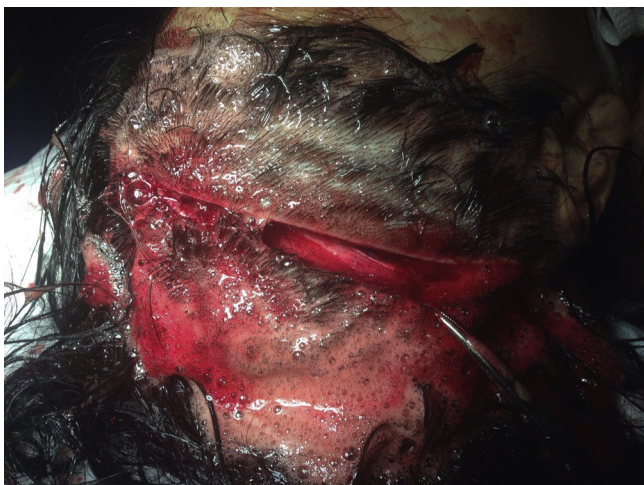
etrating cranial injury inflicted with a machete in Mexico or in Latin America to our knowledge [2–4].

The machete is a common and popular tool that is used for agriculture purposes in many tropical countries, including southeast Mexico and most of Central America as well as parts of South America, it is often the weapon of choice for uprisings. For example, the Boricua Popular Army are unofficially called *macheteros* because of the machete-wielding laborers of sugar cane fields of past Puerto Rico [5].

Our objective by presenting this case report is to provide a clear example of how managing unusual types of head trauma using current algorithms presented in the literature for the management of non-missile penetrating (NMP) cranial injuries provide an excellent point of care [6] and that GCS at admission is an important prognostic factor.

\* Corresponding author at: Mexican Oil Company High Specialty Hospital, Av. Periférico Sur 4091, 4th Floor, Col. Fuentes del Pedregal, 14140, CDMX, Mexico.

E-mail addresses: [dr.calcano@gmail.com](mailto:dr.calcano@gmail.com), [jdcacach@gmail.com](mailto:jdcacach@gmail.com)  
(J.D. Del Castillo-Calcano).



**Fig. 1.** Machete inflicted wound to the right side of the head, penetrating up to the cranium.

Presentation of this case report is in compliance with the CARE (Case Report) Guidelines [7].

## 2. Case report

### 2.1. History

We present the case of a 47 year old woman who presented to the emergency department (ED) of our hospital in southeast Mexico, family members revealed no relevant prior medical history, they reported a subject attacked her in her home premises

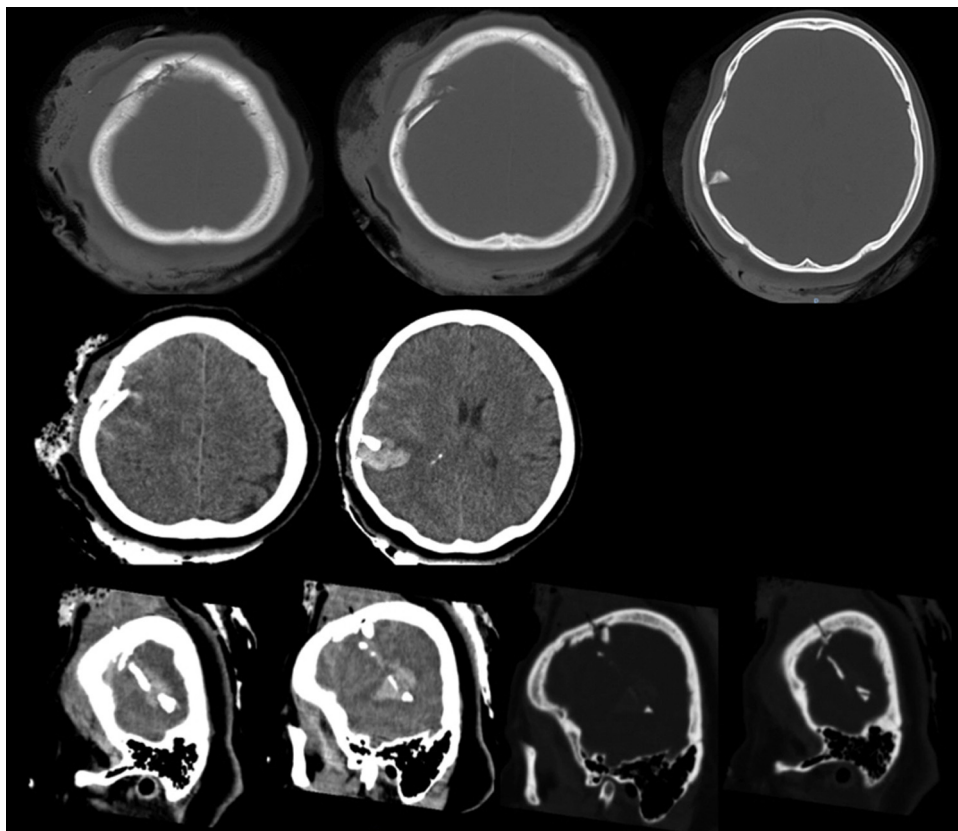
30 min before presenting to the hospital in a suburban area of a 2 million habitant city, allegedly the attacker pushed the victim to the floor and while she was on her knees performed a direct hit using a machete to the right side of her head. A family member who witnessed the assault reported immediate loss of consciousness after the hit, with full recovery 3–4 min later.

### 2.2. Examination

On initial examination the patient was fully conscious with a Glasgow Coma Scale (GCS) of 14 points, disoriented, and with no other neurological focal deficit, a 15 cm long cutting wound was observed on the right side of the head (Fig. 1) which extended all the way through the skull, no depressed fractures were evident at palpation, a computed axial tomography (CT) of the skull (Fig. 2) was ordered immediately in which a depressed fracture in the frontal and parietal bone, as well as a linear direct hit to the parenchyma and an intracerebral hematoma in the parietal lobe were evident, decision to perform a craniotomy was taken, during his stay at the ED the patient presented with deviation of the sight to the right and deterioration of consciousness to GCS of 10.

### 2.3. Operation

After neurological status deterioration was observed in the ED, we decided to rush the patient into the operating room (OR) for exploration and craniotomy, the incision was performed by extending the machete cut through the scalp to allow better visualization for craniotomy, a linear skull fracture in concordance with direction of the machete cut was observed, craniotomy was performed, observing bone shrapnel fragments penetrating the dura as well as a linear incision that went through the dura and



**Fig. 2.** Skull CT images in bone and brain windows showing a depressed fracture in the frontal and parietal bone, as well as a linear direct hit to the parenchyma and an intracerebral haematoma in the parietal lobe.

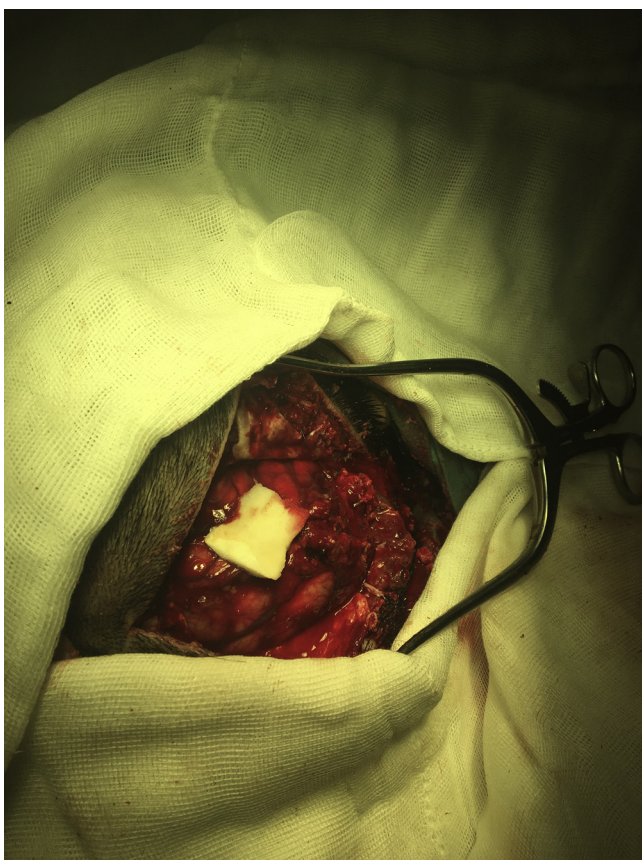

Fig. 3. Intraoperative photograph showing the craniectomy window using the same incision the machete did in the scalp.

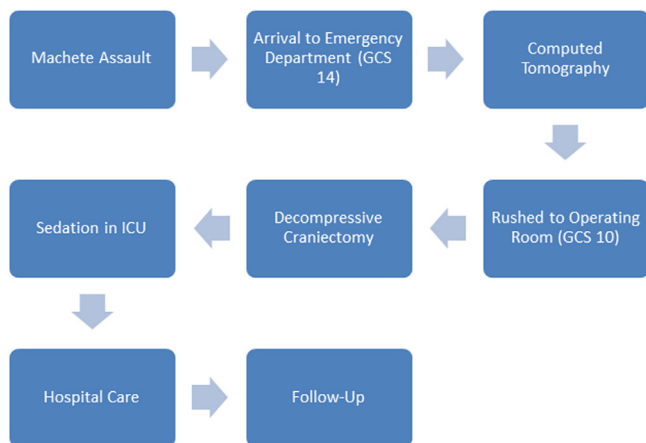


Fig. 4. Timeline of the most relevant data events of the case report.

into the parenchyma aligned with the machete cut, bone shrapnel fragments were removed and a U shaped dural incision performed, cerebral edema was evident after dural opening (Fig. 3), a debridement of bone fragments and pulped encephalic tissue was performed, and decompressive craniectomy was decided extending the bone flap limits to the base of the skull. Scalp closure was done in two steps with continuous vicryl suture in the subaponeurotic tissue and nylon suture in the skin.

2.4. Postoperative outcome

Patient was maintained under propofol sedation during 24 h in the intensive care unit (ICU), sedation was removed and neuro-

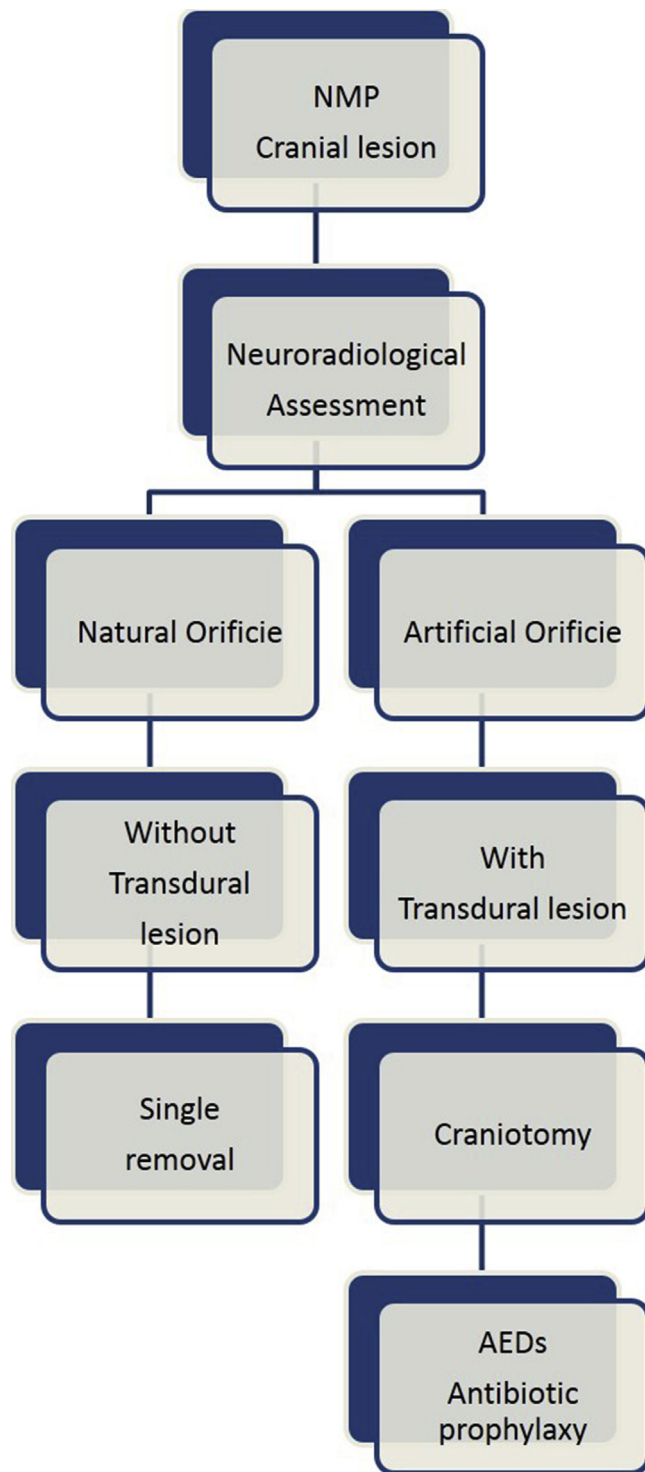


Fig. 5. Algorithm of neurosurgical management of nonmissile penetrating cranial lesions. AED, antiepileptic drug; NMP, nonmissile penetrating. "Reprinted from de Holanda LF, Pereira BJA, Holanda RR, Neto JT, de Holanda CVM, Giudicissi Filho M, de Oliveira NRC, de Oliveira JG, Neurosurgical Management of Nonmissile Penetrating Cranial Lesions, World Neurosurgery (2016), doi: 10.1016/j.wneu.2016.03.015, with permission from Elsevier.

logical examination revealed a left side hemiparesis with 4/5 force using the Medical Research Council (MRC) Scale, patient was taken out of ventilator support successfully and spent 2 more days under supervision by the attending neurosurgeons, the patient received antibiotics covering gram positive, gram negative and anaerobic bacteria, as well as phenytoin as antiepileptic drug. At 1 week follow



up the patient persisted with left hemiparesis. The patient is currently receiving physical therapy and is awaiting for cranioplasty. Timeline of the most relevant events is depicted on Fig. 4.

### 3. Discussion

In southeast Mexico, the main economic activities are oil extraction and agriculture, machetes are a useful tool utilized in both activities. However it is very strange that it is utilized as a weapon directly to the head, since the amount of force necessary to inflict significant damage must be a lot more than in other parts of the body due to the presence of the skull, we performed a survey among 4 operating room nurses with a combined 83 year experience and none recalled a similar case in which the machete penetrated the skull and damaged the parenchyma directly. Non-missile penetrating (NMP) lesions are defined as having an impact velocity of less than 100 m/s, causing injury by laceration and maceration [8], which is what our patient presented with the laceration from the machete hit extending all the way down to the parenchyma.

An algorithm for treating NMP cranial trauma has been recently published in the Journal World Neurosurgery by De Holanda et al., in this case we followed the algorithm in order to provide best care available for our patient, proving that in this particular case the algorithm was useful and provided an invaluable tool to manage an uncommon type of TBI. (Fig. 5) [6].

One of the most important prognostic factor in NMPs as well as in other types of TBIs is the GCS at admission. This was observed in one of the largest case series of NMP in which those patients with GCS 15 at admission, showed satisfactory developments, whereas among those with GCS < 15 two died [6]. In our case this was accurate since the deterioration of GCS happened in the ER and that allowed the multidisciplinary team to take quick actions in order to ensure patient survival with minimal neurological consequences.

### 4. Conclusions

Penetrating traumatic brain injury with melee weapons is not as common in our country as it is in other countries such as Nigeria or Jamaica, since according to our search, this is the first report of such type of trauma in Mexico, the use of current proposed workflows for managing NMP cranial trauma have proved to be very useful when applied on this particular case. GCS on admission proves again its importance as a prognostic factor in NMP cranial trauma.

### Conflict of interest

All authors report no conflict of interest.

### Funding

No funding was received for the purpose of this case report.

### Ethical approval

The internal review board of the Regional Mexican Oil Company does not require ethical approval for case reports when

informed consent was taken, if required by the journal it could be granted.

### Consent

Informed consent was taken and signed by the spouse of the patient in this case report, in which it was clearly stated that if considered relevant to medical education the case could be reported in a medical journal removing all identifiers.

### Author contribution

Juan D. Del Castillo-Calcaño—writing the paper, study concept, data analysis & interpretation Ulises Bravo-Angel—study concept Raúl Mendez-Olan—study concept Ulises García- González—data analysis Francisco Rodríguez-Valencia—data analysis Javier Valdés-García—data interpretation Guy G. Broc-Haro—data interpretation.

### Guarantor

Juan D. Del Castillo-Calcaño, Ulises Bravo-Ángel, Raúl Mendez-Olan.

### Acknowledgements

All authors report no conflict of interest; realization of this case report was registered on April 4th 2016 in <http://www.researchregistry.com> with the number researchregistry1114.

Fig. 5 is a reprint from de Holanda LF, Pereira BJA, Holanda RR, Neto JT, de Holanda CVM, Giudicissi Filho M, de Oliveira NRC, de Oliveira JG, Neurosurgical Management of Nonmissile Penetrating Cranial Lesions, World Neurosurgery (2016), doi: [10.1016/j.wneu.2016.03.015](https://doi.org/10.1016/j.wneu.2016.03.015), with permission from Elsevier.

### References

- [1] Aspectos clínicos y epidemiológicos del trauma craneoencefálico en México, México: Secretaría de Salud, 2008. (available online at: <http://www.epidemiologia.salud.gob.mx/doctos/boletin/2008/sem26.pdf>).
- [2] B. Enicker, T.E. Madiba, Cranial injuries secondary to assault with a machete, Injury 45 (9) (2014) 1355–1358, <http://dx.doi.org/10.1016/j.injury.2014.04.036>.
- [3] A.A. Adoga, K.N. Ozoilo, The epidemiology and type of injuries seen at the accident and emergency unit of a Nigerian referral center, J. Emerg. Trauma Shock 7 (2) (2014) 77–82, <http://dx.doi.org/10.4103/0974-2700.130875>.
- [4] I.W. Crandon, H.E. Harding, S.O. Cawich, D. Webster, Complicated head trauma from machete wounds: the experience from a tertiary referral hospital in Jamaica, Int. J. Inj. Control Saf. Promot. 18 (4) (2011) 293–297, <http://dx.doi.org/10.1080/17457300.2011.569890>.
- [5] Martin Gus, The SAGE Encyclopedia of Terrorism, 2nd edition, SAGE Publications, 2011, ISBN 978-1-4129-8016-6, pp. 490, 15 June 2011.
- [6] L.F. de Holanda, B.J.A. Pereira, R.R. Holanda, J.T. Neto, C.V.M. de Holanda, M. Giudicissi Filho, N.R.C. de Oliveira, J.G. de Oliveira, Neurosurgical management of nonmissile penetrating cranial lesions, World Neurosurg. (2016), <http://dx.doi.org/10.1016/j.wneu.2016.03.015>.
- [7] J. Gagnier, G. Kienle, D.G. Altman, D. Moher, H. Sox, D.S. Riley, CARE Group, The CARE guidelines: consensus-based clinical case report guideline development, J. Clin. Epidemiol., 67, 1, 46–51.
- [8] S. Chibbaro, L. Tacconi, Orbito-cranial injuries caused by penetrating non-missile foreign bodies. Experience with eighteen patients, Acta Neurochir. (Wien) 148 (2006) 932–941, discussion 941–932.

### Open Access

This article is published Open Access at [sciedirect.com](http://sciedirect.com). It is distributed under the [IJSCR Supplemental terms and conditions](#), which permits unrestricted non commercial use, distribution, and reproduction in any medium, provided the original authors and source are credited.