

LETTERS TO THE EDITOR

Distribution of *Campylobacter pylori* in the upper and lower gastrointestinal tract: a microbiological and histological study

The presence of *Campylobacter pylori* in the stomach and in gastric metaplasia in the duodenum and its association with gastro-duodenal disease is well established. The mode of spread and the form of the bacteria in transmission, however, is unknown. To ascertain whether *C pylori* could be detected by routine microbiological and histological methods we decided to map retrieval sites in the gastrointestinal tract from the mouth to the rectum.

Twenty two consecutive, unselected patients (13 men, nine women, median age 50 years) undergoing endoscopy for upper gastrointestinal tract symptoms were studied. At endoscopy (Olympus 91F-KXQ or XQ10 instrument, disinfected between use), macroscopic appearances were noted and any abnormality biopsied. Two adjacent biopsy specimens were also taken from the oesophagus at 35 cm, gastric body, antral, first and second parts of duodenal mucosa. At sigmoidoscopy two biopsy specimens of rectal mucosa were taken 10 cm from the anus. A buccal scrape was obtained using a tongue depressor. From each site or scrape one biopsy specimen was cultured by highly selective microbiological methods¹ for the presence of *C pylori*, and one biopsy specimen examined by routine histological methods for identification of *Campylobacter*-like organisms (CLO). *C pylori* or CLO were not identified in specimens from buccal scrapes, squamous type oesophageal mucosa, second part of duodenum or rectal mucosa by either microbiological or histological methods. In four patients *C pylori* was not identified at any site. Gastric and duodenal results in 18 patients positive for *C pylori* are shown in the table.

The aim of this study was simply to establish if *C pylori* could be recovered in a recognisable form from sites not previously described. This was not achieved and thus raises the question of how *C pylori* reach the stomach and are established in numbers sufficient to be identified by biopsy and culture?

Three possibilities are considered. First, for infection to be established only a small loading dose might be required, and this is so transient that it could be impossible to recover sufficient organisms to identify by recognised techniques. To test this theory a reliable animal model must be developed. Human volunteer studies would be more

Sites of retrieval of C pylori in 22 consecutive endoscopies

Site	Number (%) of patients in whom <i>C pylori</i> positively identified
Gastric body mucosa	18 (82) (one patient body site only positive)
Gastric antral mucosa	18 (82) (one patient antral site only positive)
Gastric antral and body mucosa	17 (77)
First part of duodenum	3 (14) (all three patients also had gastric <i>C pylori</i>)

appropriate if a completely effective treatment was guaranteed. Marshall, in attempting to fulfil Koch's postulates, ingested 10⁹ colony forming units in peptone water, but other studies repeating this experiment led to chronic atrophic gastritis in one volunteer.²

Secondly, transmission could occur in a form not identifiable by current methods. Dimorphism of *C pylori* is described³ in the coccoid and spiralic/vibrio-like forms, which can be separated by means of a sucrose concentration gradient. The coccoid forms prevail in old cultures; regrowth could be achieved but the infectivity and transmissibility have not been confirmed.

Thirdly, colonisation of the stomach could occur at a very early age and the organism might remain in the stomach in either dimorphic forms or very small numbers, with recrudescence when conditions are favourable. Gastritis in children is described in association with *C pylori*.⁴ Studies on eradication and subsequent relapse of *C pylori* investigated by restriction endonuclease DNA analysis showed that relapse was attributable to recrudescence rather than reinfection by a different strain,⁵ which would support the theory of infection for life.

In conclusion, our inability to show recognisable morphological forms of *C pylori* at any site other than gastric type mucosa has stimulated us to explore further avenues of transmission, and microbiological and epidemiological studies are in progress.

MM WALKER*

QN KARIM†

A PAYNE†

JH BARON‡

Departments of *Histopathology, †Microbiology, and ‡Gastroenterology, St Mary's and St Charles' Hospitals, London

- Karim QN, Rao GG, Taylor M, Baron JH. Routine cleaning and elimination of *Campylobacter pylori* from endoscopic biopsy forceps. *J Hosp Infect* 1989;13:87-90.
- Morris A, Rafiq Ali, Blaser M, Guillermo PP. Human ingestion of *Campylobacter pylori*—long term follow up. In: Megraud F, Lamouliatte H, eds. Proceedings of the first workshop of the European *Campylobacter pylori* study group. Amsterdam: Elsevier (in press).
- Mia U, Geis G, Leying H, Ruhl G, Opferkuch W. Dimorphism of *Campylobacter pylori*. In: Megraud F, Lamouliatte H, eds. Proceedings of the first workshop of the European *Campylobacter pylori* study group. Amsterdam: Elsevier (in press).
- Drumm B, Sherman P, Cutz E, Karmali M. Association of *Campylobacter pylori* on the gastric mucosa with antral gastritis in children. *Eng Med J* 1987;316:1558-61.
- Rauws EAJ, Langenberg W, Widjojokusumo A, Oudbier JH. Molecular epidemiology of *Campylobacter pylori*. *Gastroenterology* 1988;94:A369.

Primary malignant melanoma of the oesophagus

Malignant melanoma of the oesophagus is an extremely rare condition with only 110 cases reported in the world by 1985.¹ Indeed, melanoma of the oesophagus was always regarded as metastatic at this site until the demonstration of melanoblasts in oesophageal squamous epithelium by de la Pava.² We report a case of a malignant melanoma clearly arising from atypical melanoblasts.

A 61 year old woman had a six month history of retrosternal pain exacerbated by swallowing, and weight loss of one stone; she had no dysphagia.

Endoscopy showed a pale, polypoid tumour in the mid oesophagus, 25 cm from the incisor teeth. Several biopsy specimens were submitted for histological examination and showed a small cell anaplastic tumour with no evidence of squamous or glandular differentiation. Mucin stains were negative and an immunoperoxidase stain for leucocyte common antigen was also negative. The appearances were interpreted as representing primary or secondary anaplastic carcinoma as no mucosal origin was demonstrable.

Barium, ultrasound, and computed tomography studies indicated no evidence of metastases and therefore an Ivor-Lewis oesophagectomy was performed. Initial post-operative course was satisfactory with no leak on radiological studies but she subsequently developed acute respiratory disease syndrome and died.

Pathology

The resected oesophagus measured 20 cm after formalin fixation and contained a 3 × 2 cm smooth polypoidal tumour projecting into the lumen 5 cm from the upper limit of resection. Immediately below and adjacent to the main tumour mass were two discrete satellite tumour polyps, 1 cm in diameter. On sectioning, the tumour had a soft pale consistency with focal areas of haemorrhage but no brown pigmentation.

The histological picture was dominated by interweaving fascicles of plump spindle cells with vesicular nuclei and frequent mitotic figures. Other areas, however, had epithelioid characteristics with the cells tending to cluster in nests. Only a few cells in the deeper parts of the tumour displayed faint melanin stippling of the cytoplasm. The squamous epithelium immediately adjacent to the tumour masses contained numerous junctional nests of atypical melanocytes with pleomorphic nuclei, establishing the primary origin of the melanoma from the oesophageal epithelium. The tumour cells had spread peripherally beneath the intact squamous epithelium, distending submucosal lymphatic channels. All the tumour cells showed strong positivity with immunoperoxidase S-100 staining. Electron microscopic examination showed numerous premelanosomes together with numerous vesicles and vacuoles. Junctional attachment complexes between adjacent tumour cells were a common feature.

Most cases of primary oesophageal melanoma are found to be polypoidal intraluminal masses with contrast radiology at endoscopy, and arise in the distal oesophagus.^{1,2} Problems can be encountered in establishing a pathological diagnosis, particularly on small endoscopy specimens. The melanoma cells may contain little or no melanin pigment. The differential diagnosis embraces the spindle cell variant of squamous carcinoma, sarcomas, small cell carcinoma, carcinosarcoma and metastatic melanoma to the oesophagus.³ In this case a diagnosis of primary malignant melanoma became established with the demonstration of atypical junctional activity affecting the oesophageal squamous epithelium at the margin of the neoplastic mass. Further confirmation came from S-100 protein positivity and the demonstration of premelanosomes on electron microscopic examination.

The tumours are highly malignant. At presentation, 30-40% of cases have metastases. Chemotherapy is ineffective, although the use of radiotherapy alone, or as an adjunct

to surgery, is controversial^{4,5} and may merit reappraisal.

The disease has a dismal prognosis, with an average survival of 13.4 months after treatment, and a five year survival of 4.2%.¹ When metastases are present, survival averages only one to five months.

- 1 Chalkiadakis G, Wihlm JM, Morand G, Weill-Bousson M, Witz JP. Primary malignant melanoma of the oesophagus. *Ann Thorac Surg* 1985;39:472-5.
- 2 Mills SE, Cooper PH. Malignant melanoma of the digestive system. *Pathol Annu* 1983;18:1-26.
- 3 DiCostanzo DP, Urmacher C. Primary malignant melanoma of the oesophagus. *Am J Surg Pathol* 1987;11:46-52.
- 4 Boulafendis D, Damiani M, Sie E, Bastounis E, Samaan HA. Primary malignant melanoma of the oesophagus in a young adult. *Am J Gastroenterol* 1985;80:417-20.
- 5 Ludwig ME, Shaw R, De Suto-Nagy G. Primary malignant melanoma of the oesophagus. *Cancer* 1981;48:2528-34.

NS SIMPSON
RAJ SPENCE
JD BIGGART

Department of Surgery and Pathology,
Belfast City Hospital

CHS CAMERON
Department of Pathology,
Royal Victoria Hospital
Belfast

Secondary tumour deposits in needle biopsy tracks: an underestimated risk?

We report a case of adenocarcinoma metastatic to a computed tomography guided needle biopsy tract. The actual incidence of such events is higher than is often claimed.¹⁻⁴

There has been a remarkable increase in various forms of needle biopsy in recent years. This has been partly due to the development of very accurate systems for guiding the procedure, and partly due to cost effectiveness. The result is that radiologists and pathologists frequently cooperate closely in the performance and interpretation of these procedures. The incidence of needle track metastases is fortunately rare, but rather more common than is sometimes stated.

The commonsense view is that although there is a real risk from large needle biopsies,

fine needle aspiration biopsy is much safer. Kline, writing about fine needle aspiration in the introduction to a text on aspiration cytology, states: "Seeding of tumour cells . . . is almost a myth."⁵ The commonest well established tumour that regularly seeds in needle tracks is malignant mesothelioma, but the reports on the seeding of other tumours is not inconsiderable.¹⁻⁵ We report here a further case of metastasis to a computed tomography guided needle biopsy track from an abdominal mass.

A 67 year old woman presented with vague abdominal symptoms; examination showed a large mass in the right iliac fossa. Computed tomography and ultrasound examinations were unhelpful in establishing the nature of the mass and computed tomography guided biopsy was therefore performed (figure). Two passes were made with a Tru-cut needle and at subsequent microscopy the cores of tissue contained poorly differentiated adenocarcinoma.

Six weeks later the patient returned with a skin lesion which was thought clinically to be a pyogenic granuloma. It was 7 mm in diameter and was located at the site of the biopsy. This was removed under local anaesthetic and subsequent histology showed poorly differentiated adenocarcinoma identical with that in the original Tru-cut biopsy specimen.

As the clinical and economic arguments for percutaneous biopsy, as opposed to open biopsy, seem to be irresistible, progressively more of these samples must be expected in the laboratory. Consequently the risks of such procedures must be constantly assessed. The assumption that there is less risk from fine needle aspiration than from larger needles has been challenged, at least in the case of prostatic cancer.⁵ Consequently one cannot automatically assume that there is no risk from fine needle aspiration or that such risks should be neglected. There are numerous examples, such as the one reported here of metastases to large needle tracks from renal² and prostatic carcinomas,⁵ and from fine needle aspiration of pancreatic,⁴ lung, and pleural primaries.³ Clearly the risk, though small, is real and continued recording of such cases is needed if we are to establish the true

incidence for an event which may have clinical and legal implications.

KJ DENTON
DWK COTTON
RA NAKIELNY*
JR GOEPEL

Departments of Pathology and Radiodiagnosis,
University of Sheffield Medical School,
and Royal Hallamshire Hospital,
Sheffield

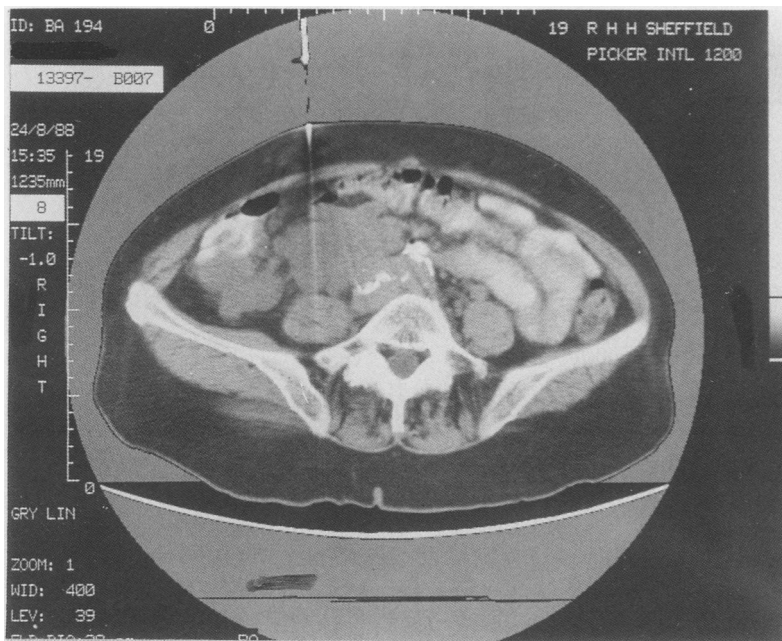
- 1 Kiser GC, Totonchy M, Barry JM. Needle track seeding after percutaneous renal adenocarcinoma aspiration. *J Urol* 1986;136:1292-3.
- 2 Muller NL, Bergin CJ, Miller RE, Ostrow DN. Seeding of malignant cells into the needle track after lung and pleural biopsy. *J Can Assoc Radiol* 1986;37:192-4.
- 3 Rashleigh-Belcher HJC, Russell RCG, Lees WR. Cutaneous seeding of pancreatic carcinoma by fine needle aspiration biopsy. *Br J Radiol* 1986;59:182-3.
- 4 Haddad FS, Somsin AA. Seeding and perineal implantation of prostatic cancer in the track of the biopsy needle: three case reports and a review of the literature. *J Surg Oncol* 1984;35:184-91.
- 5 Kline TS. *Handbook of fine needle aspiration biopsy cytology*. 2nd Ed. London: Churchill Livingstone, 1988.

Simplified method of preparing neutrophil slides to examine antibodies to cytoplasmic antigens

Several authors have described the specificity of indirect immunofluorescence tests for detecting antibodies to neutrophil cytoplasmic antigens (ANCA, ACPA) in diagnosing and managing patients with active Wegener's granulomatosis, microscopic polyarteritis, systemic vasculitis and necrotising glomerulonephritis.^{1,3} We found the following method of slide preparation simple and less time-consuming than dextran or methylcellulose sedimentation with Ficoll-Hypaque neutrophil separation.³ We also did not observe neutrophil clumping, sometimes associated with exposure to density sedimentation with the Ficoll-Hypaque technique. This method is adapted from that used to affix neutrophils to glass slides for the nitro-blue tetrazolium (NBT) reduction assay.⁴

One to two drops of fresh whole human blood without anticoagulant are allowed to clot for 30 minutes on warm glass slides coated with 4% bovine serum albumin in a 37°C humidified chamber. The clot is gently removed and the area briefly rinsed indirectly with phosphate buffered saline. The wet slide is immediately cytocentrifuged at 500 rpm for five minutes, air dried, and fixed with 99% ethanol for five minutes at 4°C (or acetone/formalin), as previously described.^{1,3} The prepared slides are stable at -20°C for at least one month. We have found the cellular morphology to be excellent in addition to which there is low background fluorescence and reproducibility. This method can be adapted for phorbol myristate acetate neutrophil activation and subsequent immunofluorescence staining.

In view of rapidly increasing interest in ANCA/ACPA testing, and the necessity for preservation of neutrophil morphology, we feel that this technique may prove more time saving and cost effective than previously described methods.^{3,6} Other methods which do not use indirect immunofluorescence are currently under evaluation^{7,8} and seem to



Computed tomography guided Tru-Cut needle biopsy specimen of intra-abdominal mass in the right iliac fossa.