

## Correspondence

### Necrobiotic granulomas of the urogenital system

Recently, Akosa and Boret<sup>1</sup> described the condition of four patients who complained of menorrhagia which was treated by laser ablation of the endometrium. Treatment failed in these patients and hysterectomy was performed. Necrotising histiocytic granulomas were found in the endometria of all the four cases.

We have recently investigated nine similar hysterectomy specimens which were subjected to laser ablation of the endometrium (unpublished data, 1994, Aqel *et al*). We found scattered histiocytes and/or multinucleated giant cells in the endometria of eight of the nine cases. Some of the histiocytes formed necrotising granulomas. In all cases histiocytes showed intracytoplasmic black and golden-brown pigment; in addition, residual endometria contained variable quantities of haemosiderin (Perl's positive) which suggested past injury and haemorrhage in the basal layer of the endometrium.

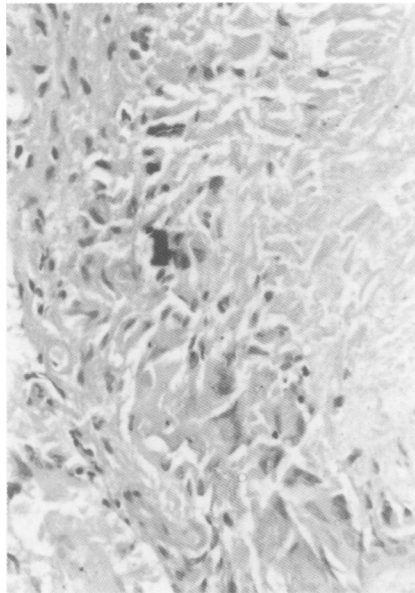
We have also recently examined a urinary bladder biopsy specimen which was removed three months after diathermy resection of a transitional cell carcinoma. This biopsy specimen showed necrotising granulomas with deposition of intracytoplasmic black pigment (figure). The pigment in the hysterectomy specimens and in the bladder biopsy specimen was not birefringent and did not stain with haematoxylin, Perl's (iron), Masson-Fontana (melanin), Gram (bacteria), or Ziehl-Neelsen (acid-alcohol fast bacilli). It seemed to be composed of non-degradable products of carbonised tissue, resulting from injury by laser or cautery.

Similar black or golden-brown "diathermy pigment"<sup>2</sup> was reported following laser ablation or diathermy resection of endometrium and ovary.<sup>3-5</sup> As histiocytic and granulomatous inflammation of the urogenital system can be a component of a wide range of pathological conditions including infections, infestations, and systemic diseases, such as sarcoidosis,<sup>6</sup> it is important to recognise the presence of "diathermy pigment" and haemosiderin in these lesions. Such observations should prompt the histopathologist to consider the possibility of previous cautery or laser treatment, and so enquire further about the past surgical history. This will save unnecessary histological and clinical investigations to rule out infectious or systemic diseases.<sup>7</sup>

NM AQEL

Department of Histopathology,  
Charing Cross and Westminster Medical School,  
Fulham Palace Road,  
London W6 8RF

- 1 Akosa AB, Boret F. Necrotising granulomas of the uterine corpus. *J Clin Pathol* 1993;46:953-5.
- 2 Clarke TJ, Simpson RHW. Necrotising granulomas of peritoneum following diathermy ablation of endometriosis. *Histopathology* 1990; 16:400-2.
- 3 Thurrell W, Reid P, Kennedy A, Smith JHF. Necrotising granulomas of the peritoneum. *Histopathology* 1991;18:190.
- 4 Ashworth MT, Moss CI, Kenyon WE. Granulomatous endometritis following hysteroscopic resection of the endometrium. *Histopathology* 1991;18:185-7.
- 5 Ferryman SR, Stephens M, Gough D. Necrotising granulomatous endometritis following



Section of bladder showing an area of the lamina propria with necrosis (right) surrounded by mononuclear histiocytes and multinucleated giant cells; some of these cells contain black pigment.

- endometrial ablation therapy. *Br J Obstet Gynaecol* 1992;99:928-30.
- 6 Buckley CH, Fox H. *Biopsy pathology of the endometrium*. London: Chapman and Hall, 1989.
- 7 Wilson GE, Haboubi NY, McWilliam LJ, Hirsch PJ. Postoperative necrotising granulomata in the cervix and ovary. *J Clin Pathol* 1990;43: 1037-8.

### Occult papillary microcarcinoma of the thyroid: a potential pitfall of fine needle aspiration cytology? Is it possible to avoid it?

Harach *et al*<sup>1</sup> reported two cases of papillary microcarcinoma of the thyroid incidentally diagnosed by fine needle aspiration cytology of nodular goitres. Based on the cytological diagnoses, subtotal thyroidectomies were performed. In both cases histological diagnosis of nodular goitre with one focus of papillary microcarcinoma was established. The authors regarded the cytodiagnoses as so-called false positive results because the cytological reports led to unnecessary surgery.

Recently, a 51 year old woman was sent to our Cytology Laboratory for fine needle aspiration cytology of the thyroid because two small nodules were detected in the upper and middle part of the right thyroid lobe on a radioisotope scan. Several blind fine needle aspirates were taken from both thyroid lobes and papillary carcinoma of the right thyroid lobe was diagnosed on cytology. The cytological diagnosis was an indication for thyroidectomy which was performed 14 days later. During surgery, two small nodules were detected in the right thyroid lobe, which were diagnosed as benign on examination of frozen tissue sections. Two additional small nodules were detected in the left lobe and subtotal thyroidectomy was performed.

Before paraffin wax sections were prepared, the smears taken from the right thyroid lobe were reviewed by a second experienced cytopathologist. The smears contained numerous benign follicular cells arranged in

honeycomb sheets. Some of these cells had well defined eosinophilic cytoplasm (Hurthle cells). Amongst these benign follicular cells, there were a few groups of epithelial cells with overlapping round and oval, occasionally slightly irregular nuclei displaying chromatin grooves, prominent intranuclear vacuoles and small nucleoli; these cytological features are characteristic of papillary carcinoma and the diagnosis established by the first cytopathologist was confirmed.

Numerous samples were taken from both thyroid lobes for sectioning in paraffin wax, revealing two small adenomatoid nodules in the right thyroid lobe and two papillary microcarcinomas about 0.3 cm in diameter were discovered in both thyroid lobes.

Had the papillary microcarcinoma not been incidentally detected by fine needle aspiration cytology the patient would have been treated by suppressive hormonal therapy and most likely would have avoided unnecessary surgery. Can such a false positive cytodiagnosis be avoided?

When fine needle aspiration cytology is performed on palpable solid papillary carcinoma of the thyroid, smears are usually cellular and all or most of the cells display the morphological features of papillary carcinoma. We propose that false positive results may be avoided if repeat aspirates taken from the palpable nodule are negative for cancer cells.

Based on our observations in the future it may be possible to avoid such so-called false positive cytodiagnoses in some cases as suggested by Harach *et al*.<sup>1</sup> Unfortunately, in their article Harach *et al* did not mention whether the papillary microcarcinoma smears they evaluated contained only cancer cells or whether the cancer cells were admixed with numerous benign follicular cells as mentioned above.

S WOYKE

AK AL-JASSAR

Departments of Cytology and Histopathology,  
Kuwait Cancer Control Centre, Kuwait

UK LUTHRA

ZA SHEIKH

Department of Cytology,

Mubarak Hospital, Kuwait

- 1 Harach HR, Day ES, Zusman SB. Occult papillary microcarcinoma of the thyroid—a potential pitfall of fine needle aspiration cytology? *J Clin Pathol* 1991;44:205-7.

#### Dr Harach comments:

Dr Woyke and colleagues raise the interesting point that it may be possible to separate needle biopsy specimens of papillary microcarcinomas from those of clinically significant carcinomas by the admixture of benign follicular cells in the specimen. In our own report of needle biopsy specimens diagnosed as papillary carcinoma, found on operation to be papillary microcarcinomas, both cases contained non-neoplastic follicular cells as well as the typical cells of papillary carcinoma. However, I have also seen numerous examples where needle biopsy specimens contained both non-neoplastic and neoplastic follicular cells, and at surgery a clinically significant papillary carcinoma was found. The proposal to use repeat aspirations is also difficult, unless there is proof that the aspirate is restricted to the nodule. A possible strategy would be to carry out a second biopsy with ultrasound, when the first biopsy of a palpable nodule produces abundant non-neoplastic follicles and a minor papillary carcinoma component.