

a pathological diagnosis and most material has been already fixed and processed. The technique's main disadvantages are that it is labour intensive and the large number of cells examined by a flow cytometer cannot be examined with this method. A near diploid aneuploid peak might not be resolved with this technique either. It will be interesting to examine further cases of AIS to determine if any show definite aneuploidy.

R C JAWORSKI  
Department of Anatomical Pathology,  
Institute of Clinical Pathology  
and Medical Research,  
Westmead Hospital,  
Westmead,  
New South Wales, 2145  
Australia.  
A JONES  
Department of Cytology,  
Royal Prince Alfred Hospital,  
Camperdown, New South Wales,  
Australia.

- 1 Fu YS, Hall TL, Berek JS, Hacker NF, Reagan JW. Prognostic significance of DNA ploidy and morphometric analyses of adenocarcinoma of the uterine cervix. *Anal Quant Cytol Histol* 1987;9:17-24.
- 2 Hedley DW, Friedlander ML, Taylor IW, Rugg CA, Musgrove EA. Method for the analysis of cellular DNA content of paraffin-embedded pathological material using flow cytometry. *J Histochem Cytochem* 1983;31:1333-5.
- 3 Schulte E. Haematoxylin and the Feulgen reagent in nuclear staining. In: Boon ME, Kok LP, eds. *Standardization and quantitation of diagnostic staining of cytology*. Leiden, The Netherlands: Coulomb, 1986:15-26.
- 4 Fu YS, Reagan JW. Benign and malignant epithelial lesions of the uterine cervix. In: Bennington JL, ed. *Pathology of the uterine cervix, vagina and vulva*. Philadelphia: WB Saunders Company, 1989:248.
- 5 Jaworski RC, Pacey NF, Greenberg ML, Osborn RA. The histological diagnosis of adenocarcinoma in situ and related lesions of the cervix uteri. *Adenocarcinoma in situ*. *Cancer* 1988;61:1171-81.

### Lymphocytic gastritis and coeliac disease

Lymphocytic gastritis is a recently described histopathological form of gastritis that is characterised by a distinct increase in lymphocytes in the surface and foveolar epithelium.<sup>1</sup> It is commonly associated with a characteristic endoscopic picture featuring erosions and prominent folds (varioliiform gastritis).<sup>1</sup> The incidence of lymphocytic gastritis in gastric biopsy material is about 4%.<sup>2</sup> A similar increased density of intraepithelial lymphocytes in the small intestinal mucosa is also a typical feature of coeliac disease. The pathogenesis of lymphocytic gastritis is unknown, but it has been suggested that it may represent an immunological response to some local antigen. Dixon *et al* found serological evidence of *Helicobacter pylori* infection, even in cases where bacterium was not detectable in biopsy specimens, and suggested that *H pylori* might be the antigen.<sup>2</sup> We evaluated the numbers of intraepithelial lymphocytes in biopsy specimens from the gastric mucosa of patients with adult coeliac disease and from controls with no evidence of coeliac disease and studied the presence of *H pylori* in these specimens.

The series comprised all adult patients with coeliac disease diagnosed between January 1 1986 and June 30 1987. There were 30 such patients, from 27 of whom—mean (SD) age 46 (14)—gastric biopsy specimens were taken simultaneously with duodenal biopsy specimens before any treatment. Both the antrum and the corpus were biopsied in 25 cases, while in the remaining two the specimen represented only the antral mucosa.

### Intraepithelial lymphocytes/100 epithelial cells in entire groups of coeliac patients and controls and according to *H pylori* state (median; range within parentheses)

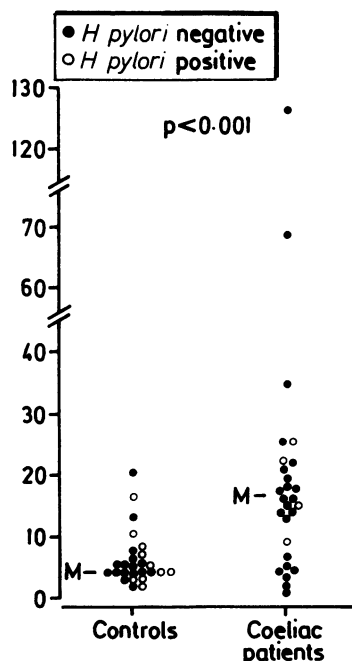
	Patients (n = 27)	Controls (n = 27)	Significance
Antral mucosa:			
All	16.3 (1.6-127.3)	4.3 (2.0-20.6)	p < 0.001
Positive	18.8 (9.1-25.3)	4.3 (2.1-17.3)	
Negative	16.3 (1.6-127.3)	4.7 (2.0-20.6)	
Body mucosa:			
All	12.4 (3.1-53.9)	4.8 (2.0-66.1)	p < 0.001
Positive	16.5 (16.3-17.9)	5.9 (2.0-66.1)	
Negative	9.9 (3.1-53.9)	4.2 (2.0-13.6)	

The groups were compared using the Mann-Whitney U test. There were no significant differences in lymphocyte counts between the *H pylori* positive and negative patients among the coeliac patients and controls.

The control material consisted of 27 consecutive age and sex matched patients without any peptic ulcer, gastric resection, or malignancy and with histologically normal duodenal mucosa, who were examined for upper abdominal complaints. All but one of control patients had had an antral biopsy performed and all but one a corpus biopsy.

Sections stained with haematoxylin and eosin were coded and studied blind in the absence of any information on the state of the duodenal mucosa or the clinical diagnosis. The numbers of lymphocytes and epithelial cells were counted over an uninterrupted length of the surface and foveolar epithelium. One hundred to 200 cells were counted and the results expressed as lymphocytes per 100 epithelial cells.<sup>2</sup> Modified Giemsa stain<sup>2</sup> was used to show the presence of *H pylori* in 46 cases and haematoxylin and eosin stain in eight.

The count of intraepithelial lymphocytes was significantly higher in the coeliac patients than in the controls in both the antral and the body mucosa (table, figure). There were four *H pylori* positive patients among the coeliac cases and 10 among the controls, a non-significant difference ( $\chi^2$  test). There were no significant differences in the counts of intraepithelial lymphocytes between the *H pylori* positive and negative coeliac patients or the *H pylori* positive and negative controls (table, figure).



Numbers of intraepithelial lymphocytes (IEL)/100 epithelial cells in the antral mucosa of coeliac patients and controls. M = median.

The findings suggest that increased amounts of intraepithelial lymphocytes are present in the gastric mucosa of coeliac patients. It has been suggested that 30 intraepithelial lymphocytes/100 epithelial cells is the minimum figure for the diagnosis of lymphocytic gastritis,<sup>1</sup> and there were four (14.8%) such cases among the coeliac patients and one (3.7%) among the controls. Endoscopic examination showed nodular erosions at the antrum-corporum border in the control patient with a high number of intraepithelial lymphocytes, while none of the cases with coeliac disease showed any evidence of varioliiform gastritis.

No instances of an increase in intraepithelial lymphocytes in the gastric mucosa in association with coeliac disease have been reported previously, except by Wolber *et al*,<sup>3</sup> who found high numbers in five out of 10 patients with coeliac disease.

Because the counts of intraepithelial lymphocytes between the coeliac patients and controls overlapped, this increase cannot be regarded as a specific diagnostic feature. On the other hand, it might be used as an indication for a small intestinal biopsy, at least when typical varioliiform gastritis is not present at endoscopy.

An abnormal immunological reaction to gluten is considered to be important in the pathogenesis of coeliac disease, and this may be reflected in the abnormal density and subtype distribution of intraepithelial lymphocytes in the small intestinal mucosa. The change in the stomach may represent the same process. Our results do not support the possibility that *H pylori* may have some role in the pathogenesis of coeliac disease or lymphocytic gastritis, but due to the retrospective nature of this survey, no *H pylori* serology could be performed and we are not able to disprove the suggestion of Dixon *et al*<sup>2</sup> that lymphocytic gastritis is an abnormal immune response to *H pylori*. An increased incidence of achlorhydria has been reported to occur in coeliac disease<sup>4</sup> and dermatitis herpetiformis,<sup>5</sup> but it is unknown whether the present increase in intraepithelial lymphocytes in coeliac disease is associated with any functional abnormality in the gastric mucosa.

TUOMO KARTTUNEN  
SEPPO NIEMELÄ  
Department of Pathology,  
University of Oulu,  
Kajaanintie 52 D,  
SF-90220 Oulu,  
Finland

- 1 Haot J, Hamichi L, Wallez L, Mainguet P. Lymphocytic gastritis: a newly described entity: a retrospective/endoscopic and histological study. *Gut* 1988;29:1258-64.
- 2 Dixon MF, Wyatt JI, Burke DA, Rathbone BJ. Lymphocytic gastritis - relationship to *Campylobacter pylori* infection. *J Pathol* 1988;154:125-32.
- 3 Wolber R, Owen MB, DeBuono L, Appelman H. Lymphocytic gastritis in patients with

celiac sprue or sprue like disease. *Lab Invest* 1989;60:106A.

- 4 Hansky J, Shiner M. Gastric studies in idiopathic steatorrhea. *Gastroenterology* 1985; 45:49-56.
- 5 Gillberg R, Kastrop W, Mobacken H, Stockbrügger R. Gastric morphology and function in dermatitis herpetiformis and in coeliac disease. *Scand J Gastroenterol* 1985;20: 133-40.

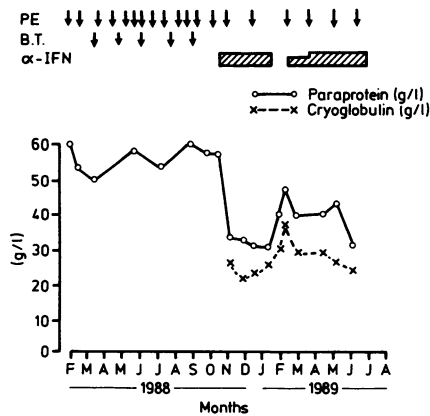
### Treatment of Waldenström's macroglobulinaemia with $\alpha$ interferon

Alpha interferon has been shown to have some activity against B cell non-Hodgkin's lymphomas, primarily the low grade histological types.<sup>1</sup> It has also been used in Waldenström's macroglobulinaemia, but its activity in this disorder is not very well documented.<sup>2</sup> We report a patient with Waldenström's macroglobulinaemia and cryoglobulinaemia, who derived considerable benefit from treatment with  $\alpha$  interferon.

A 68 year old Caucasian woman presented in November 1985 with a six month history of recurrent epistaxis, night sweats, and severe Raynaud's disease. She also complained of blurring of vision. On examination the fingers were blue, there was no lymphadenopathy, and the spleen was just palpable. Fundal examination showed typical changes of hyperviscosity. A full blood count showed: haemoglobin concentration of 10.7 g/dl, white cell count of  $8.7 \times 10^9/l$  with a normal differential, and a platelet count of  $360 \times 10^9/l$ . Urea and electrolytes and liver function tests were normal, but the total protein was raised at 126 g/l, with the presence of an IgM  $\lambda$  paraprotein band. There was minimal immune suppression and Bence-Jones protein was absent. The paraprotein band was quantitated at 55 g/l, of which 40 g was a cryoglobulin. The bone marrow findings were consistent with a diagnosis of Waldenström's macroglobulinaemia.

She had urgent plasmapheresis with good resolution of her symptoms, but as Bence-Jones protein became detectable within the next few months, she was started on a course of chlorambucil, 10 mg daily for seven days, repeated every four weeks. As there was no change in the paraprotein concentration, this was discontinued. She continued to have plasma exchanges every four to six weeks and remained quite well. In early 1988, however, her condition began to deteriorate and she was given cyclophosphamide, 1 g intravenously, at monthly intervals. This was discontinued after six months as the paraprotein concentration had not changed. Moreover, she was requiring regular blood transfusions.

By October 1988, despite three weekly plasma exchanges, her general condition continued to deteriorate. She had excessive gum bleeding, her visual disturbance worsened, and she had several episodes of loss of consciousness. She was therefore given  $\alpha$  interferon (Intron A), 3 megaunits three times weekly. The figure shows the striking response of the paraprotein and cryoglobulin concentrations to treatment with  $\alpha$  interferon. In particular, she required no further blood transfusion and needed only one plasma exchange in the ensuing three months. She experienced severe side effects from  $\alpha$  interferon, however, and it was temporarily discontinued. The paraprotein concentration increased, with reappearance of her symp-



Response of paraprotein and cryoglobulin concentrations to treatment with  $\alpha$  interferon. PE = plasma exchange; BT = blood transfusion.

toms, necessitating an urgent plasma exchange. She was given another preparation of  $\alpha$  interferon (Roferon A) at a lower dose (3 megaunits twice weekly), without much improvement in her symptoms. When the interferon was increased to 3 megaunits three times weekly, the cryoglobulin concentration fell to around 25 g/l and her symptoms disappeared. She remains well and has not required any further plasma exchange since June 1989.

This case shows that  $\alpha$  interferon may be useful in the treatment of refractory Waldenström's macroglobulinaemia, especially in association with cryoglobulinaemia. It may also be worth exploring its use in cases of cryoglobulinaemia from other causes.

M BHAVNANI

Department of Haematology,  
J MARPLES

Department of Chemical Pathology,  
Royal Albert Edward Infirmary,  
Wigan Lane, Wigan WN1 23NN  
J A LIU YIN

Department of Haematology,  
Manchester Royal Infirmary.

- 1 Wagstaff J, Loynds P, Crowther D. A phase II study of human and rDNA alpha-2 interferon in patients with low grade non-Hodgkin's lymphoma. *Cancer Chemother Pharmacol* 1986;18:54-8.
- 2 Ozer H, Ratanatharathorn V, Leavitt R, et al. *Proceedings of the American Society of Clinical Oncology*, 1985;4:214.

### Apoptotic cell death during renal transplant rejection

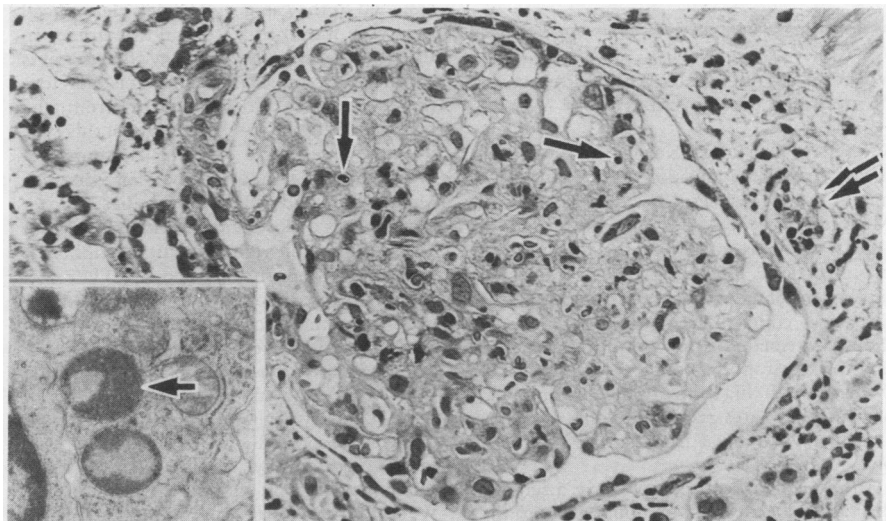
Apoptosis is a form of intrinsically programmed cell death described in a wide range of physiological and pathological states.<sup>1</sup> Its occurrence has been documented in several renal disorders.<sup>2</sup> Acute rejection of renal transplants produces widespread damage, principally in tubules and vasculature, but glomerular abnormalities have been reported.<sup>3</sup> Although well described, the pathogenesis of much of this damage is unclear. We describe a case of acute renal transplant rejection in which cell death by apoptosis was striking within the glomeruli and tubules.

A 45 year old woman who had had a functioning renal transplant for nine months presented with a pronounced decline in renal function. Rejection was clinically confirmed by biopsy and the patient responded slowly to increased doses of immunosuppressive drugs. A second biopsy specimen two and a half weeks later showed diminished but continuing active rejection which eventually responded to immunosuppression. Four and a half months after that, however, a further decline in renal function occurred with a third biopsy specimen showing chronic rejection.

The first biopsy specimen showed acute rejection with a prominent interstitial lymphocytic infiltrate and a "tubulitis" with tubular necrosis. Endothelial swelling, foam cells, lymphocytic infiltration and oedema were present in the intima of medium and large sized arteries. A variable expansion in mesangial matrix was seen, but striking cell death by apoptosis was identified, principally in endothelial cells but also in the mesangium (figure). Review of the tubular damage showed, focally, a similar mode of cell death. Electron microscopic examination showed characteristic apoptotic nuclear fragments with condensed, featureless chromatin. Some had been phagocytosed by other cells (figure; inset).

The second biopsy specimen was similar but the rejection process was milder. Apoptotic cell death persisted in the glomeruli. Arterial narrowing, tubular atrophy, and interstitial fibrosis typical of chronic vascular rejection were seen in the third biopsy specimen.

As far as we know, this is the first description of apoptosis during acute renal trans-



Glomerulus with prominent apoptotic bodies in characteristic scattered distribution (single arrow). Interstitial inflammation and tubulitis are also seen (double arrow) (Haematoxylin and eosin). Inset: apoptotic body in tubular epithelial cell.