

Editorial

Houston, GEMINI has landed: Spinal cord fusion achieved

Sergio Canavero, Xiaoping Ren

HEAVEN/GEMINI International Collaborative Group, Turin, Italy

E-mail: *Sergio Canavero - sercan@inwind.it; Xiaoping Ren - xren2@luc.edu
 *Corresponding author

Received: 01 September 16 Accepted: 01 September 16 Published: 13 September 16

Key Words: Gemini, head transplantation, heaven, peg, spinal cord fusion

In June 2013, the world was taken by storm by the announcement that a full head (or body) transplant was possible.^[1] This key achievement would have been made possible by the GEMINI spinal cord fusion protocol.

Despite several publications delineating the rationale of the GEMINI protocol over the past 3 years,^[2-5,13] it soon became clear that the spinal cord community worldwide was completely unaware of the underlying, pressing anatomical rationale and of the technology involved. The response was a hysterical reaction.

Today, it is most gratifying to announce a series of proof-of-principle papers that will dispel that hysteria once and for all.

One of the keys to a successful spinal cord fusion is a very sharp cut that minimizes damage of the cord, both at the white matter and the gray matter level. This allows the two interfaces of a severed cord to regrow neurites out of the gray matter core, the vital component of the sensorimotor machinery that makes us move and feel (the so-called cortico-trunco-reticulo-proprio-spinal pathway, CTRPS) – unlike the previous misbegotten dogma that the white matter (including the pyramidal corticospinal fibers) with its 20 million fibers was solely or to a large extent in charge of these functions (for in-depth anatomical discussion, see references 2–3 and 6). Work done since Cajal’s time, but then forgotten or ignored, made it clear that a sharp cut was not irreversibly associated with permanent paralysis; in fact, animals reacquired sensorimotor function.^[2-4]

A sharp cut has been equated to standard spinal cord injury, which is to a large extent unrecoverable because of the widespread mechanical disruption of the cord’s cell bodies and extensions, along with the formation of cysts

and scars. This is a major conceptual error. The degree of mechanical disruption is fractional in sharp sections. It is true that a scar, however limited, forms after a sharp severance, but we know that a scar is no obstacle to regrowing neuritic extensions from the spinal propriospinal neurons. This fact was shown by US neurosurgeon W. Freeman more than half a century ago, and rediscovered in 2016!^[12] (see full discussion in^[5] and Figure 1).

On the other hand, this recovery process takes time and a patient receiving a new body must be able to move and feel as fast as possible, ideally within days or a few weeks at most.

Enter the second pillar of the GEMINI spinal cord fusion protocol; fusogens, and in particular polyethylene glycol (PEG).^[1] PEG has the uncanny

This is an open access article distributed under the terms of the Creative Commons Attribution-NonCommercial-ShareAlike 3.0 License, which allows others to remix, tweak, and build upon the work non-commercially, as long as the author is credited and the new creations are licensed under the identical terms.

For reprints contact: reprints@medknow.com

Access this article online	
Quick Response Code:	Website: www.surgicalneurologyint.com
	DOI: 10.4103/2152-7806.190473

How to cite this article: Canavero S, Ren X. Houston, GEMINI has landed: Spinal cord fusion achieved. *Surg Neurol Int* 2016;7:S626-8.
<http://surgicalneurologyint.com/Houston,-GEMINI-has-landed:-Spinal-cord-fusion-achieved/>

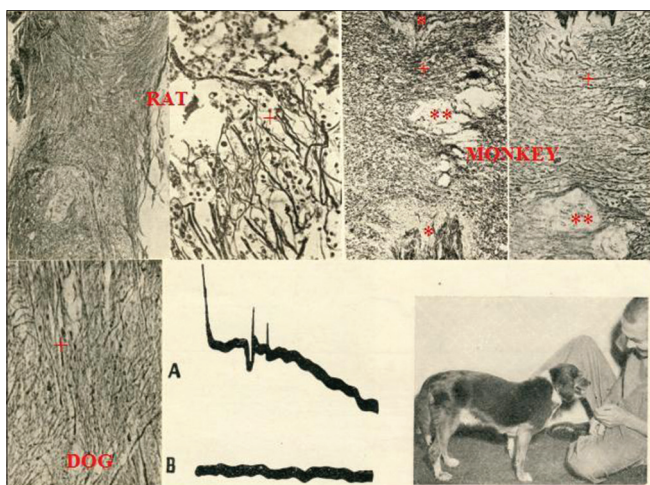


Figure 1: Original histological frames from Freeman 1963: Notice profuse regrowth across the point of full severance of fibers piercing the scar (rat, dog, and primate) (silver staining). In addition, notice recovery of impulse conduction and Freeman with a close-to-normal dog at 7 months (see references 2–5) (*: point of sharp section; **: scar; +: Regrowing fibers)

capacity to literally refuse neuronal cell membranes submitted to mechanical disruption, a fact reported in 1986 by Prof. Bittner at the single axonal level. Unfortunately, no one caught on until 13 years later Prof. Borgens started testing PEG in spinal cord injury models.^[13] However, nothing came out of their solitary efforts and neither understood the potential of PEG in accelerating the process of fusion of a severed spinal cord with functional restoration in the clinical setting. In fact, Borgens even denied to *New Scientist* (February 28 2015) that such a feat was even possible, while Bittner finally caught on in 2015 after 2 years of media coverage of GEMINI.^[13]

Ever since 2013, one of us (Canavero) has collaborated with Prof. Kim in Seoul, Korea, a veterinarian scientist who first offered to investigate GEMINI in animal models. That effort paid nice dividends now displayed in full in this journal. Kim first showed that PEG applied to a sharply severed cervical spinal cord accelerated the initial recovery of motor evoked potentials (MEPs) in mice within the first hour, with occasional voluntary movements at 1 week.^[8] In the first new paper, the follow-up at 4 weeks shows that mice can move, although not normally, and feed themselves.^[9] This by itself is a spectacular achievement. Freeman reported on rodents recovering ambulation within several months (!) after simply apposing the two interfaces of a sharply severed dorsal cord,^[4] In Kim *et al.*, this happened in a much shorter time-frame (4 weeks vs. months). The group of one of us (Ren) applied standard PEG to severed dorsal cords in rodents and observed recovery of motor function within 4 weeks (BBB score 14 out of 22) (Ye *et al.* 2016). These experiments have been covered in the September 2016 issue of *The Atlantic* and the

journalist was astonished at seeing a rat re-walk within 2 days versus paralyzed control rodents. He referred to the near-miraculous properties of PEG.

Early this year, one of us (Canavero) was approached by Prof. J. Tour's PhD student William Sikkema at Rice University's Faculty of Chemistry and Nano Center in Houston, Texas, offering to test a "nano-enhanced" form of PEG (Texas PEG). Prof. Kim with his team immediately tested it. The initial results are indeed nothing short of miraculous.^[10] Somatosensory evoked potentials recovered to a good extent within 24 hours! Unfortunately, an accidental mishap led to the death of four of the five study animals. However, the sole survivor re-acquired almost normal motor behaviors. To put these results into perspective, rats treated with normal PEG recovered to a BBB score of 8 within 4 weeks, versus a BBB score of 19–20 within 2 weeks with TexasPEG!

While of course these results are in need of duplication, there can be no doubt that this new batch of data confirm that a spinal cord, once severed, can be refused with useful behavioral recovery. Certainly, it will be necessary to confirm the absence of toxicity of TexasPEG in further studies, although, given the small amount used topically, it is very difficult that any significant toxicity is observed in the long term. Last but not least, the astute reader of these papers will have noticed that these animals developed no pain-related behaviors nor signs of possible "full body phantoms."

How PEG accelerates the GEMINI fusion process is discussed elsewhere.^[1,5] Here, we want to stress how GEMINI can be leveraged in the clinical context of spinal cord injury, outside the immediate application of a full head transplant.

Kim brilliantly chose for a model of a stab wound a sharp severance to the cervical cord in a dog where more than 90% of the cord was cut.^[11] As is well known, what remains of a thus severed cord is occasionally capable of aiding in partial recovery of motor and sensory function, but over extended periods (even years). By applying standard PEG, the dog recovered almost full motor function within 2 weeks!

It is up to neurosurgeons to find now a way to apply this in patients. While stab wounds are rare, traumatic spinal cord injury is not. Freeman already suggested a way to cure spinal cord injury: Remove the injured segment, perform a vertebrectomy, bring in contact the two stumps and wait [Figure 2]; walking animals resulted from this procedure. A vertebrectomy is major surgery, but is a path that must be explored. Another would be to remove the injured segment and fill the void with gelled PEG as done by Mueller's team,^[7] with or without a scaffold. Electrical stimulation, the third pillar of GEMINI, can be applied to speed up the recovery.^[6] TexasPEG, that contains

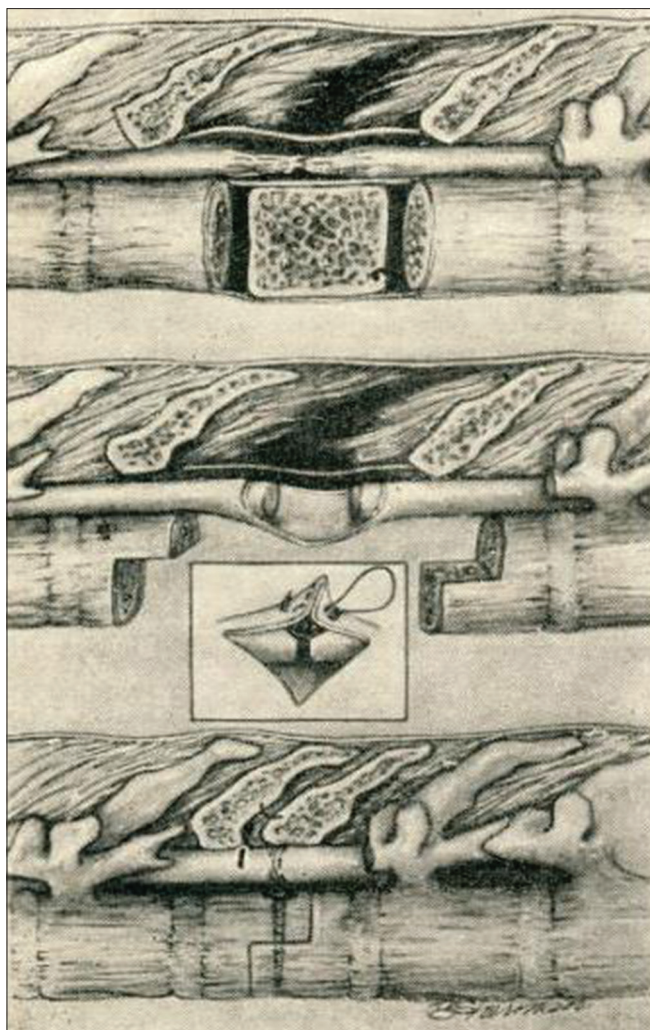


Figure 2: Original image depicting a possible surgical scenario for the cure of paralysis: Removal of the injured segment and vertebrectomy, apposition of healthy stumps, and vertebral fixation (see reference 4)

nanoribbons, can also act as a scaffold and conduct electricity, making it an ideal agent for clinical trials.

What comes next on the path to the first HEAVEN surgery?

Despite these exciting animal experiments, the proof of the pudding rests in human studies. The only

ethical – and expeditious – way is to test GEMINI in brain dead organ donors before explantation during a 6-hour window during which the cord is severed, PEG applied, and motor conduction assessed distally. The same rationale applies to peripheral nerves (phrenics, vagi).

Once the first impulses are recorded crossing the fusion interface, we will know that a human head transplant can materialize. At that point, the final testing of the HEAVEN hypothermia protocol will be necessary. In the meantime, extensive cadaveric rehearsals will train the surgical crews for the defining event of the 21st century.

REFERENCES

1. Canavero S. HEAVEN: The head anastomosis venture project outline for the first human head transplantation with spinal linkage (GEMINI). *Surg Neurol Int* 2013;4(Suppl 1):S335-42.
2. Canavero S. Head transplantation and the quest for immortality. Amazon CreateSpace IP; 2014.
3. Canavero S. The “Gemini” spinal cord fusion protocol: Reloaded. *Surg Neurol Int* 2015;6:18.
4. Canavero S. Commentary. *Surg Neurol Int* 2015;6:103.
5. Canavero S, Ren XP, Kim CY, Rosati E. Neurologic foundations of spinal cord fusion (GEMINI). *Surgery* 2016;160:11-9.
6. Canavero S, Ren XP. The Spark of Life: Engaging the Cortico-Truncoreticulo-Propriospinal Pathway by Electrical Stimulation. *CNS Neurosci Ther* 2016;22:260-1.
7. Estrada V, Brazda N, Schmitz C, Heller S, Blazyca H, Martini R, et al. Long-lasting significant functional improvement in chronic severe spinal cord injury following scar resection and polyethylene glycol implantation. *Neurobiol Dis* 2014;67:165-79.
8. Kim CY. PEG-assisted reconstruction of the cervical spinal cord in rat: Effects on motor conduction at 1 hour. *Spinal Cord* 2016 [Epub ahead of print].
9. Kim CY, Oh H, Hwang IK, Hong KS. GEMINI: Initial behavioral results after full severance of the cervical spinal cord in mice. *Surg Neurol Int* 2016 [Epub ahead of print].
10. Kim CY, Sikkema WK, Hwang IK, Oh H, Kim UJ, Lee BH, et al. Spinal cord fusion with PEG-GNRs (Texas PEG): Neurophysiological recovery at 24 hours in rats. Preliminary results. *Surg Neurol Int* 2016.
11. Kim CY, Hwang IK, Jang SW, Kim HS. Accelerated recovery of sensorimotor function in a dog submitted to quasi-total transection of the cervical spinal cord and treated with PEG. *Surg Neurol Int* 2016.
12. Liddelow SA, Barres BA. Regeneration: Not everything is scary about a glial scar. *Nature* 2016;532:182-3.
13. Ye YJ, Kim CY, Miao Q, Ren XP. Fusogen-assisted rapid reconstitution of anatomophysiological continuity of the transected spinal cord. *Surgery* 2016;160:20-5.