



Published in final edited form as:

*Histopathology*. 2015 September ; 67(3): 313–324. doi:10.1111/his.12657.

## Handling and Reporting of Orchidectomy Specimens with Testicular Cancer: Areas of Consensus and Variation among 25 Experts and 225 European Pathologists

Daniel M Berney<sup>1,\*</sup>, Ferran Algaba<sup>2</sup>, Mahul Amin<sup>3</sup>, Brett Delahunt<sup>4</sup>, Eva Compérat<sup>5</sup>, Jonathan I Epstein<sup>6</sup>, Peter Humphrey<sup>7</sup>, Mohammed Idrees<sup>8</sup>, Antonio Lopez-Beltran<sup>9</sup>, Cristina Magi-Galluzzi<sup>10</sup>, Gregor Mikuz<sup>11</sup>, Rodolfo Montironi<sup>12</sup>, Esther Oliva<sup>13</sup>, John Srigley<sup>14</sup>, Victor E Reuter<sup>15</sup>, Kiril Trpkov<sup>16</sup>, Thomas M Ulbright<sup>8</sup>, Murali Varma<sup>17</sup>, Clare Verrill<sup>18</sup>, Robert H Young<sup>13</sup>, Ming Zhou<sup>19</sup>, and Lars Egevad<sup>20</sup>

<sup>1</sup>Barts Cancer Centre, Queen Mary University of London, London, UK <sup>2</sup>Fundacio Puigvert-University Autonomous, Barcelona, Spain <sup>3</sup>Department of Pathology and Laboratory Medicine, Cedars-Sinai Medical Center, Los Angeles, CA <sup>4</sup>Department of Pathology, Wellington School of Medicine and Health Sciences and University of Otago, Wellington, New Zealand <sup>5</sup>Hopital La Pitié-Salpêtrière, Paris, France <sup>6</sup>Johns Hopkins Hospital, Baltimore, USA <sup>7</sup>Yale School of Medicine, Yale-New Haven Hospital New Haven, CT 06510 <sup>8</sup>Department of Pathology and Laboratory Medicine, Indiana University School of Medicine and Indiana Pathology Institute, Indianapolis, Indiana <sup>9</sup>Cordoba University Medical School, Cordoba, Spain <sup>10</sup>Robert J. Tomsich Pathology and Laboratory Medicine Institute, Cleveland Clinic, Cleveland, OH, USA <sup>11</sup>Institute of Pathology, Medical University of Innsbruck, Muellerstrasse 44, 6020, Innsbruck, Austria <sup>12</sup>Polytechnic University of the Marche Region, Ancona, Italy <sup>13</sup>Massachusetts General Hospital †Department of Pathology, Harvard Medical School, Boston, MA <sup>14</sup>Department Pathology and Molecular Medicine, McMaster University, Hamilton, ON, Canada <sup>15</sup>Department of Pathology, Memorial Sloan-Kettering Cancer Center, USA <sup>16</sup>Department of Pathology and Laboratory Medicine, University of Calgary and Calgary Laboratory Services, Calgary, AB <sup>17</sup>University Hospital of Wales, Cardiff, UK <sup>18</sup>Department of Cellular Pathology, John Radcliffe Hospital, Oxford, UK <sup>19</sup>Department of Pathology, New York University Langone Medical Center, New York, NY, USA <sup>20</sup>Department of Oncology-Pathology, Karolinska Institutet, Stockholm, Sweden

### Abstract

**Background**—The handling and reporting of testicular tumours is difficult due to their rarity.

**Design**—A survey developed by the European Network of Uro-Pathology (ENUP) and sent to its members and experts to assess the evaluation of testicular germ cell tumours

**Results**—25 experts (E) and 225 ENUP members replied. Areas of disagreement included immaturity in teratomas, reported by 32% (E) but 68% (ENUP). Although the presence of rete

\*Corresponding Author: Prof DM Berney, Centre for Molecular Oncology, Barts Cancer Centre, John Vane Science Centre, Charterhouse Square, LONDON EC1M 6BQ, Tel: +44 (0)20 7882, Fax: +44 (0)20 7882 3884, D.Berney@bartshealth.nhs.uk.  
Conflict of Interest Statement. No conflicts of interest are declared.

testis invasion was widely reported, the distinction between pagetoid and stromal invasion was made by 96% (E) but only 63% (ENUP). Immunohistochemistry was used in more than 50% of cases by 68% (ENUP) and 12% (E). Staging revealed the greatest areas of disagreement. Invasion of the tunica vaginalis without vascular invasion was interpreted as T1 by 52% (E) and 67% (ENUP), but T2 by the remainder. Tumour invading the hilar adipose tissue adjacent to the epididymis without vascular invasion was interpreted as T1: 40% (E), 43% (ENUP), T2: 36% (E), 30% (ENUP) and T3: 24% (E), 27% (ENUP).

**Conclusions**—There is remarkable consensus in many areas of testicular pathology. Significant areas of disagreement included staging and reporting of histologic types, both of which have the potential to impact on therapy.

### Keywords

testis; germ cell tumour; consensus; rete testis; staging; classification

---

### Introduction

Testicular pathology creates many challenges for both expert and general histopathologists<sup>1, 2</sup>. Orchidectomies are relatively simple surgical procedures and therefore often performed by general or junior urologists in local hospitals where there is a lack of specialist genitourinary (GU) pathologists. For practicing pathologists, orchidectomy specimens pose two main problems. Firstly, these tumours are generally rare and only a handful may be encountered in a year, thus limiting the experience of the pathologist. The second problem is the huge range of testicular pathology. Within merely the germ cell tumours, the most commonly encountered testicular tumours, there is a protean range of morphology with many mimics and confounding patterns. This problem is magnified by the vast range of non-germ cell malignancies in the testicular parenchyma and spermatic cord. Some testicular tumour subtypes may be encountered only once in a career, if at all. Some are associated with rare clinical syndromes.

The handling and staging of testicular tumours, particularly germ cell tumours, may also be problematic. Both staging and typing may be affected by macroscopic examination. Although most germ cell tumours are now treated by surveillance<sup>3</sup>, the decision to give adjuvant therapy may be dependent on a number of clinic-pathological factors<sup>4</sup>. These include tumour stage, but there are a number of other predictive factors that have been suggested over the past 10 years not included in the current TNM terminology.

In some countries testicular pathology has been centralised, so that within the GU community there are certain designated experts who see a large volume of testicular tumours and therefore are more able to recognise the rarer variants. It has been shown that this subspecialisation may affect both typing and staging of tumours<sup>5, 6</sup>. There are numerous prospective and retrospective studies where pathology interpretation may be variable and greatly affect the results. There is a necessity of uniform pathology, not only to address the problems of correct diagnosis and treatment but also to address the consequences of pathology variability in clinical trials and avoid contamination of the literature with inaccurate prognostic factors. We therefore wished to examine the variability and conformity

in practice among both experts and general GU pathologists. This would hopefully highlight areas of agreement, and also areas where practice is variable and consensus needed.

## Materials and Methods

A survey was developed by the steering group of the European Network of Uro-Pathology (ENUP). This focused on macroscopy, microscopy and especially known controversies in staging. The survey was sent to all 661 ENUP members as well as selected international experts. Experts were invited because of their known publication record or volume of their testicular pathology practice. The expert survey was analysed separately from the ENUP survey. The survey questions are listed in Table 1.

## Results

Replies were received from 25 experts (E) and 225 ENUP members. Both groups had remarkably similar responses for many questions.

### Demographics

The experts worked in 10 different countries: 13 in North America, 11 in Europe and one in New Zealand. ENUP members came from 22 European countries, the largest representation coming from the UK with 17% (38), Spain 14% (31), Italy 9% (21) and Germany 7% (16). This may at least partly reflect that most surveys are conducted in English.

Of the experts, 24 received more than 20 testis cases in consult or routine practice per year and 6 (24%) received more than 100 cases. 48% of the experts had more than half their cases as consults. Among ENUP members, 39% (87) saw fewer than 20 and 50% (113) saw between 20 and 50. 2% (4) of ENUP members saw more than half their cases as consults. For clarity, only percentages of each cohort will be reported for the remaining results.

### Macroscopy

A summary of the results are displayed in Table 2. Notable differences of opinion in technique were noted. Ink was not used by 62% (ENUP) and 52% (E). Of those using ink, experts all used one colour. While 93% of ENUP members did the same, 6% used two colours and one member used 3 colours. Other significant differences were in methods of tumour measurement where some measured the tumour only in 1 dimension, while others used two or three measurements. Tumour blocks were taken by a variety of methods. A subjective method was used, correlating to tumour size, in 65% (ENUP) and 56% (E). The classical method of a fixed number of blocks per cm was used by 24% (ENUP) and 22% (E). Others used no fixed protocol and commented on their specific method. Some experts said they would take more blocks from a suspected seminoma than from a non-seminoma.

### Classification and microscopy

A summary of the results is displayed in Table 3. Nearly all respondents from both groups classified by WHO 2004. Significant differences included recording of immaturity in teratoma which was reported by 68% (ENUP) but only 32% of experts. Respondents were asked whether they made any assessment of 'differentiation' in seminomas. Some authors

have previously reported mitotic rates or so called ‘anaplastic’ seminomas and we wished to investigate whether pathologists reported these features.<sup>7–9</sup> This was done by 12% (ENUP) and 28% (E) though methods were very variable including mitotic counts, and nuclear morphology. Reporting the type of tumour involved in vascular invasion was reported by 54% (ENUP) and 56% (E). Also, there were differences on whether blood vessel invasion should be distinguished from lymphatic invasion. This was reported by 41% (ENUP) and 28% (E). Invasion of the rete testis was reported by 94% (ENUP) and 96% (E), though when asked whether any distinction was made between pagetoid and stromal invasion of the rete (Figures 1a and b), this was done by 63% (ENUP) and 96% (E).

### TNM staging

The detailed usage of TNM classification is presented in Table 3 and the expert differences in Figure 2. Major differences included the staging of tumour invading the inner serosal lining of the testis but not the outer layer with no vascular invasion. This would be staged as T1 by 67% (ENUP) and 52% (E) and T2 by the remainder. Tumour invading the hilar fatty tissue adjacent to the epididymis with no vascular invasion would be staged T1 by 43% (ENUP) and 40% (E), T2 by 30% (ENUP) and 36% (E) and T3 by 27% (ENUP) and 24% (E). A tumour deposit in the upper cord with a separate tumour in the testis associated with vascular invasion would be staged as T2 with a soft tissue deposit by 23% (ENUP) and 28% (E) and T3 by 75% (ENUP) and 68% (E). The remainder made comments that they would stage as a metastasis.

### Immunohistochemistry and genetics

Use of immunohistochemistry is presented in Table 4 and specific antibodies used presented in Figure 3. Isochromosome 12p assessment was requested on challenging cases by 7% (ENUP) and 48% (E).

### Discussion

This survey highlights a surprising degree of concordance between urological pathologists whether or not they have a specialist interest in testicular pathology. Although some protocols are evidence based, others appear to have evolved with very little evidence base, however logic has dictated certain approaches which are widely adopted. Pathologists are also guided by expert opinion and by cancer guidelines which have been published by national pathological associations<sup>10</sup>.

Macroscopic protocols are broadly similar. However opinion was split on the use of ink. While only one colour is used as a maximum by all the expert groups, two or more colours are used by some ENUP members. This routine appears to be unnecessary for total orchidectomy specimens. The use of ink is necessary on partial orchidectomy specimens where it is the only way that margin positivity can be demonstrated due to the lack of an anatomic boundary. The taking of a cord block before incising the testis was widespread. However some pathologists receive their testes already incised by the surgeon. The logic of this is to ensure formalin fixation, as suboptimal fixation can compromise tissue typing. The taking of the cord block prior to excision derives from a sole paper and serves to avoid

contamination of the margin, and a false positive report of vascular invasion<sup>11</sup>. It should be noted, however, that it is not possible to protect testicular parenchyma from contamination of vessels by free floating tumour cells in a similar way.

A majority of pathologists take tumour blocks in a subjective manner, but claim that the number of blocks correlates with tumour size. It was commented by some experts that they sample probable seminomas more widely to look for non-seminomatous transformation. Tumour size is most commonly measured in three diameters, but by a minority in two dimensions. The maximal tumour dimension has been shown in many studies to be prognostically significant, particularly in seminoma. One pooled analysis of data from 4 cohort studies of 638 patients showed that if tumours were greater than 4cm in maximum diameter there was a two-fold risk of recurrence and the importance of tumour size is strongly supported by more recent studies.<sup>4, 12-14</sup>. It would appear logical that it is important to give as a minimum the maximal diameter. Blocking of the rete testis, normal parenchyma and examination of the tunics appears now to be very widely accepted. Rete testis invasion has been shown in some studies to be an important prognostic factor<sup>4, 15</sup>, though this may be a surrogate for tumour size and has been disputed by other studies<sup>16</sup> Including recent large series which did not however include pathological review<sup>12</sup>.

While nearly all respondents report on rete testis invasion, 37% of ENUP members did not distinguish between pagetoid invasion, which is probably a phenomenon related to spread of intratubular germ cell neoplasia into the rete, and true interstitial invasion. This shows the possible dangers of relying on extraction of pooled pathological data from multiple centres without central review, which is often done in clinical studies.

Reporting vascular invasion was virtually universal in the survey and has an excellent evidence base, particularly for non seminomas<sup>17-22</sup>. The evidence that vascular invasion is an important prognostic factor in seminoma is much however less certain<sup>4, 12, 23</sup>. There were general disagreements in whether lymphatics should be reliably distinguished from small venules. One trial has suggested that this is an important distinction<sup>24</sup>, but older and more recent work suggests that such distinctions are not possible on H and E<sup>25, 26</sup>. There was also disagreement on whether the type of tumour present within vessels should be reported. There is no evidence to support this. In pure seminomas this should be self apparent, and the vast majority of non seminoma cases show vascular invasion by the embryonal carcinoma component.

Classification by the WHO 2004 now appears widespread. The British Testicular Panel (BTTP) devised a classification in the 1960s<sup>27</sup> and is still used by a few UK based pathologists though is not recommended in the latest Royal College of Pathologists dataset<sup>10</sup>.

77% of ENUP and 92% of the experts reported the percentages of all elements of a germ cell tumour. There is considerable work supporting that the percentage of embryonal carcinoma is prognostically significant. A surveillance study of 373 men with stage 1 non seminomatous germ cell tumours showed that the percentage of embryonal carcinoma

predicted relapse<sup>28</sup>. This has been supported by numerous other smaller studies<sup>18, 29, 30</sup>. More recent cohort studies, one on 1,226 patients<sup>22</sup>, have supported this.

The degree of immaturity in a teratoma has been shown to have little impact on disease natural history. Interestingly 68% of ENUP still reported on this while only 32% of experts would do so: an example of a practice where less is done by the experts because of insight that it has little prognostic importance.

The most important differences were in tumour staging by TNM, and here there was a lack of consistency despite over 95% of respondents using it. This is reflected in a very poor evidence base, where apart from vascular invasion in non-seminomas, the TNM staging appears to be largely unhelpful. Tunica vaginalis invasion is staged as T2 in the current TNM classification, though in fact there is no evidence for this in the literature, despite being an anatomical boundary. The experts and ENUP members were broadly split on how to interpret tumour involvement of the inner serosal lining part of the tunica vaginalis. Although anatomically both serosal linings represent the tunica vaginalis, there is a reluctance of pathologists to upstage to T2 in these circumstances, possibly because some believe that the inner serosal lining represents the tunica albiginea.

There was even further disagreement on the staging of hilar fat involvement, without vascular invasion: split fairly evenly between T1, T2 and T3. Recent papers have suggested that this is a poor prognostic factor, but many are reluctant to stage as T3<sup>31</sup>.

The variation seen in this survey suggests a number of consequences. Firstly, the variation in reporting TNM stage and rete testis invasion will affect any analysis of prognostic factors in germ cell tumours especially in pooled data. Any reliance on extracting the data from pathology reports should be treated with extreme caution as it may be unreliable.

Immunohistochemistry was used in far fewer cases among the expert group, reflecting the familiarity of those pathologists with these tumours. However there were significant differences in the markers that were utilised between both groups (Figure 3). Notably, OCT3/4<sup>32</sup> was used far more among experts than amongst ENUP members. It has been shown to be both sensitive and specific for embryonal carcinoma and seminoma, and widely promulgated in many articles<sup>2, 33</sup>. A recent expert opinion paper from ISUP may promote changes in some practices<sup>34</sup>. The lack of its use in many departments may reflect budget restraints or caution in developing new tests. The same holds true for SALL-4<sup>35, 36</sup> and Glipican-3<sup>37, 38</sup>.

Finally, molecular testing for isochromosome 12p may be helpful in rare and challenging cases, for instance to distinguish dermoid cysts from mature teratomas.<sup>39</sup> It was used by half the expert group, it only 7% of the ENUP group, again probably reflecting a lack of local availability and molecular expertise.

In conclusion we have shown that while some areas of testicular pathology show remarkable degrees of consensus, others show great variability which may lead to differences in the power of prognostic information provided and even effect treatment decisions. International agreement and consensus statements may lessen the variability in these areas.

## Acknowledgments

DB, EC, ALB, FA, MV and LE devised the survey. DB wrote the manuscript. All authors participated in the survey and commented and refined the survey results and commented on the conclusions. We gratefully acknowledge the other experts who took part in the survey: Phillippe Camparo, Jeffrey Theaker, Isabell Sesterhenn and Grete Krag Jacobsen.

DB gratefully acknowledges the support of Orchid.

## References

1. Ulbright TM. The most common, clinically significant misdiagnoses in testicular tumor pathology, and how to avoid them. *Adv Anat Pathol.* 2008; 15:18–27. [PubMed: 18156809]
2. Rajab R, Berney DM. Ten testicular trapdoors. *Histopathology.* 2008; 53:728–39. [PubMed: 18336561]
3. Powles T. Stage I nonseminomatous germ cell tumor of the testis: more questions than answers? *Hematol Oncol Clin North Am.* 25:517–27. viii. [PubMed: 21570606]
4. Warde P, Specht L, Horwich A, et al. Prognostic factors for relapse in stage I seminoma managed by surveillance: a pooled analysis. *J Clin Oncol.* 2002; 20:4448–52. [PubMed: 12431967]
5. Lee AH, Mead GM, Theaker JM. The value of central histopathological review of testicular tumours before treatment. *BJU Int.* 1999; 84:75–8. [PubMed: 10444128]
6. Delaney RJ, Sayers CD, Walker MA, Mead GM, Theaker JM. The continued value of central histopathological review of testicular tumours. *Histopathology.* 2005; 47:166–9. [PubMed: 16045777]
7. Tickoo SK, Hutchinson B, Bacik J, et al. Testicular seminoma: a clinicopathologic and immunohistochemical study of 105 cases with special reference to seminomas with atypical features. *Int J Surg Pathol.* 2002; 10:23–32. [PubMed: 11927966]
8. von Hochstetter AR. Mitotic count in seminomas--an unreliable criterion for distinguishing between classical and anaplastic types. *Virchows Arch A Pathol Anat Histol.* 1981; 390:63–9. [PubMed: 7281474]
9. Stein ME, Zidan J, Charas T, Drumea K, Ben-Yosef R. Anaplastic variant of classical seminoma of the testis: northern Israel oncology center experience and brief review of literature. *Rambam Maimonides medical journal.* 2014; 5:e0006. [PubMed: 24498513]
10. Berney, DT.; Verril, JC. RC Pathologists, editor. Dataset for the histological reporting of testicular neoplasms. 32014. [http://www.rcpath.org/Resources/RCPath/Migrated%20Resources/Documents/G/G046\\_TestisDatasetMay14.pdf](http://www.rcpath.org/Resources/RCPath/Migrated%20Resources/Documents/G/G046_TestisDatasetMay14.pdf)
11. Nazeer T, Ro JY, Kee KH, Ayala AG. Spermatic cord contamination in testicular cancer. *Mod Pathol.* 1996; 9:762–6. [PubMed: 8832559]
12. Chung P, Daugaard G, Tyldesley S, et al. Evaluation of a prognostic model for risk of relapse in stage I seminoma surveillance. *Cancer medicine.* 2014
13. Aparicio J, Maroto P, Garcia Del Muro X, Sanchez-Munoz A, Guma J, Margeli M, et al. Prognostic factors for relapse in stage I seminoma: a new nomogram derived from three consecutive, risk-adapted studies from the Spanish Germ Cell Cancer Group (SGCCG). *Ann Oncol.* 2014; 25:2173–8. [PubMed: 25210015]
14. Mortensen MS, Lauritsen J, Gundgaard MG, et al. A Nationwide Cohort Study of Stage I Seminoma Patients Followed on a Surveillance Program. *Eur Urol.* 2014
15. Kamba T, Kamoto T, Okubo K, et al. Outcome of different post-orchietomy management for stage I seminoma: Japanese multi-institutional study including 425 patients. *Int J Urol.* 17:980–7. [PubMed: 20955354]
16. Vogt AP, Chen Z, Osunkoya AO. Rete testis invasion by malignant germ cell tumor and/or intratubular germ cell neoplasia: what is the significance of this finding? *Hum Pathol.* 41:1339–44. [PubMed: 20573373]
17. Fossa SD, Jacobsen AB, Aass N, et al. How safe is surveillance in patients with histologically low-risk non-seminomatous testicular cancer in a geographically extended country with limited computerised tomographic resources? *Br J Cancer.* 1994; 70:1156–60. [PubMed: 7981068]

18. Dunphy CH, Ayala AG, Swanson DA, Ro JY, Logothetis C. Clinical stage I nonseminomatous and mixed germ cell tumors of the testis. A clinicopathologic study of 93 patients on a surveillance protocol after orchiectomy alone. *Cancer*. 1988; 62:1202–6. [PubMed: 2842034]
19. Colls BM, Harvey VJ, Skelton L, et al. Late results of surveillance of clinical stage I nonseminoma germ cell testicular tumours: 17 years' experience in a national study in New Zealand. *BJU Int*. 1999; 83:76–82. [PubMed: 10233456]
20. Alexandre J, Fizazi K, Mahe C, et al. Stage I non-seminomatous germ-cell tumours of the testis: identification of a subgroup of patients with a very low risk of relapse. *Eur J Cancer*. 2001; 37:576–82. [PubMed: 11290432]
21. Wishnow KI, Johnson DE, Swanson DA, et al. Identifying patients with low-risk clinical stage I nonseminomatous testicular tumors who should be treated by surveillance. *Urology*. 1989; 34:339–43. [PubMed: 2480680]
22. Daugaard G, Gundgaard MG, Mortensen MS, et al. Surveillance for Stage I Nonseminoma Testicular Cancer: Outcomes and Long-Term Follow-Up in a Population-Based Cohort. *J Clin Oncol*. 2014
23. Kamba T, Kamoto T, Okubo K, et al. Outcome of different post-orchiectomy management for stage I seminoma: Japanese multi-institutional study including 425 patients. *Int J Urol*. 2010; 17:980–7. [PubMed: 20955354]
24. Freedman LS, Parkinson MC, Jones WG, et al. Histopathology in the prediction of relapse of patients with stage I testicular teratoma treated by orchidectomy alone. *Lancet*. 1987; 2:294–8. [PubMed: 2886764]
25. Barsky SH, Baker A, Siegal GP, Togo S, Liotta LA. Use of anti-basement membrane antibodies to distinguish blood vessel capillaries from lymphatic capillaries. *Am J Surg Pathol*. 1983; 7:667–77. [PubMed: 6356945]
26. Van den Eynden GG, Van der Auwera I, Van Laere SJ, et al. Distinguishing blood and lymph vessel invasion in breast cancer: a prospective immunohistochemical study. *Br J Cancer*. 2006; 94:1643–9. [PubMed: 16670715]
27. Lyubimov N. The Pathology of Testicular Tumours. Studies from the Testicular Tumour Panel and Registry of the Pathological Society of Great Britain and Ireland in Association with the British Empire Cancer Campaign for Research. *Br J Urol*. 1964; 36:1–112. [PubMed: 14184703]
28. Read G, Stenning SP, Cullen MH, et al. Medical Research Council prospective study of surveillance for stage I testicular teratoma. Medical Research Council Testicular Tumors Working Party. *J Clin Oncol*. 1992; 10:1762–8. [PubMed: 1403057]
29. Atsu N, Eskicorapci S, Uner A, et al. A novel surveillance protocol for stage I nonseminomatous germ cell testicular tumours. *BJU Int*. 2003; 92:32–5. [PubMed: 12823379]
30. Nicolai N, Pizzocaro G. A surveillance study of clinical stage I nonseminomatous germ cell tumors of the testis: 10-year followup. *J Urol*. 1995; 154:1045–9. [PubMed: 7637051]
31. Yilmaz A, Cheng T, Zhang J, Trpkov K. Testicular hilum and vascular invasion predict advanced clinical stage in nonseminomatous germ cell tumors. *Mod Pathol*. 26:579–86. [PubMed: 23238629]
32. Looijenga LH, Stoop H, de Leeuw HP, et al. POU5F1 (OCT3/4) identifies cells with pluripotent potential in human germ cell tumors. *Cancer Res*. 2003; 63:2244–50. [PubMed: 12727846]
33. Emerson RE, Ulbright TM. The use of immunohistochemistry in the differential diagnosis of tumors of the testis and paratestis. *Semin Diagn Pathol*. 2005; 22:33–50. [PubMed: 16512598]
34. Ulbright TM, Tickoo SK, Berney DM, Srigley JR. Members of the IliDUPG. Best Practices Recommendations in the Application of Immunohistochemistry in Testicular Tumors: Report From the International Society of Urological Pathology Consensus Conference. *Am J Surg Pathol*. 2014
35. Cao D, Humphrey PA, Allan RW. SALL4 is a novel sensitive and specific marker for metastatic germ cell tumors, with particular utility in detection of metastatic yolk sac tumors. *Cancer*. 2009; 115:2640–51. [PubMed: 19365862]
36. Cao D, Li J, Guo CC, Allan RW, Humphrey PA. SALL4 is a novel diagnostic marker for testicular germ cell tumors. *Am J Surg Pathol*. 2009; 33:1065–77. [PubMed: 19390421]



37. Zynger DL, Dimov ND, Luan C, Teh BT, Yang XJ. Glypican 3: a novel marker in testicular germ cell tumors. *Am J Surg Pathol.* 2006; 30:1570–5. [PubMed: 17122513]
38. Zynger DL, McCallum JC, Luan C, Chou PM, Yang XJ. Glypican 3 has a higher sensitivity than alpha-fetoprotein for testicular and ovarian yolk sac tumour: immunohistochemical investigation with analysis of histological growth patterns. *Histopathology.* 56:750–7. [PubMed: 20546340]
39. Cheng L, Zhang S, MacLennan GT, et al. Interphase fluorescence in situ hybridization analysis of chromosome 12p abnormalities is useful for distinguishing epidermoid cysts of the testis from pure mature teratoma. *Clin Cancer Res.* 2006; 12:5668–72. [PubMed: 17020968]

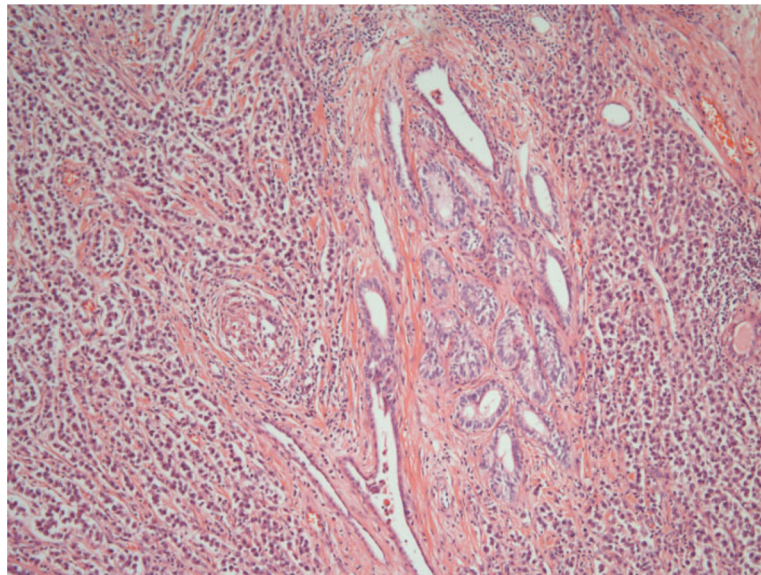
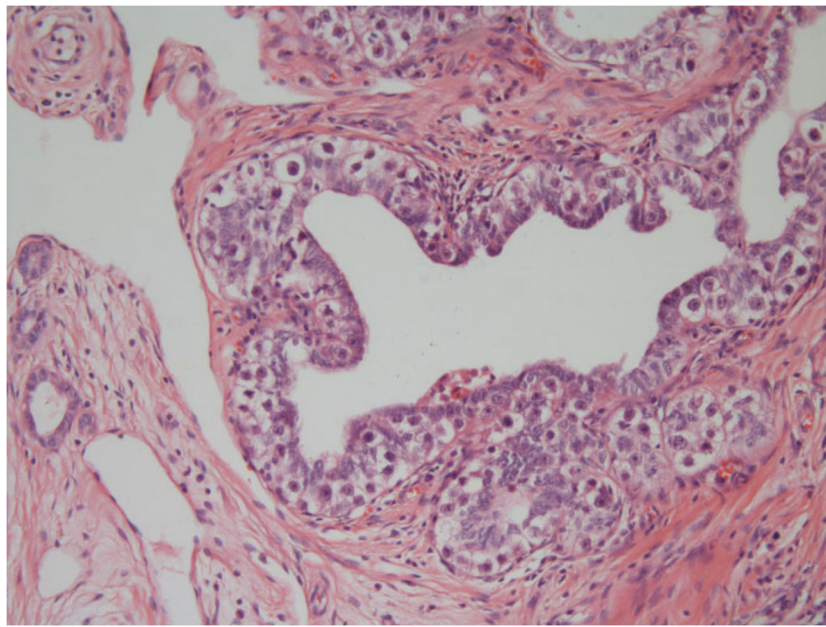
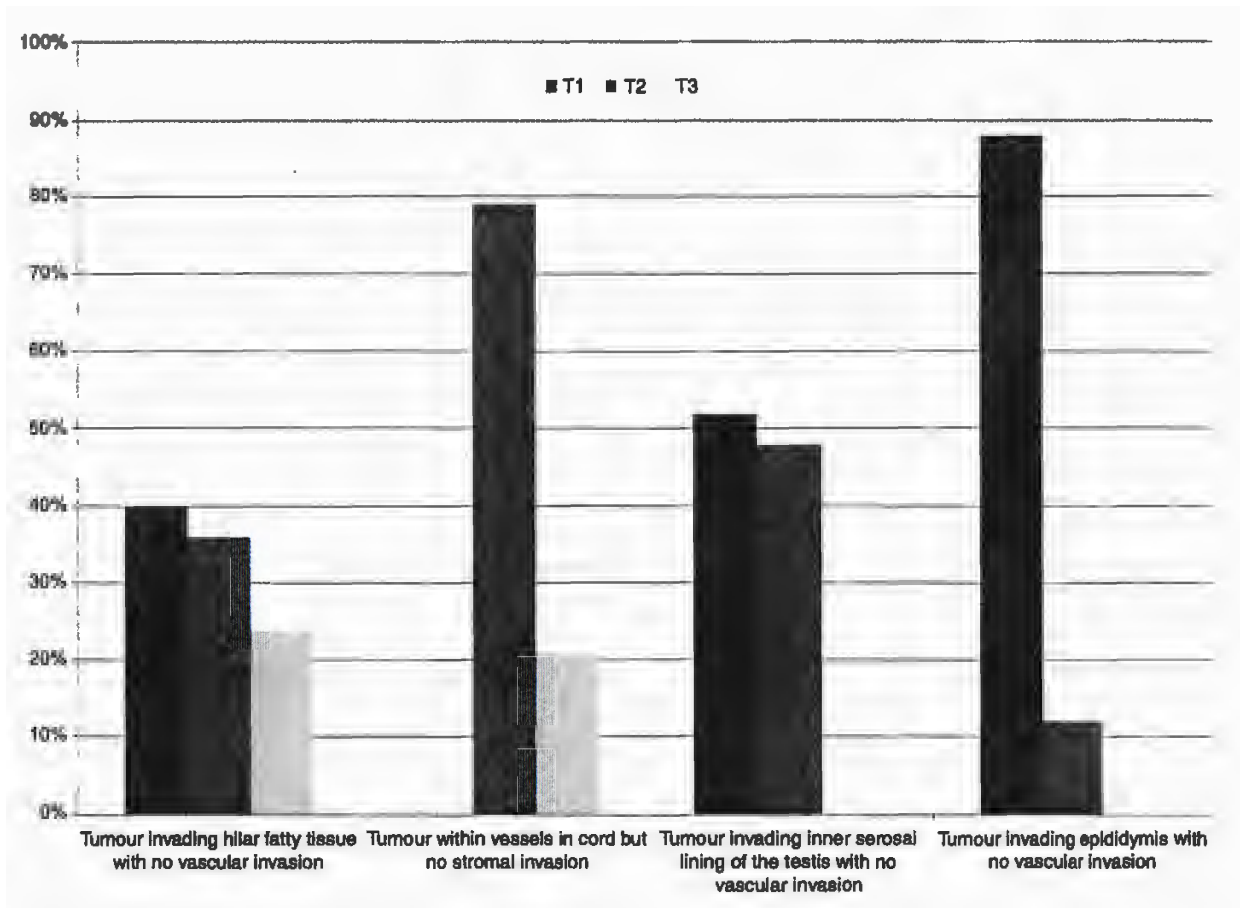
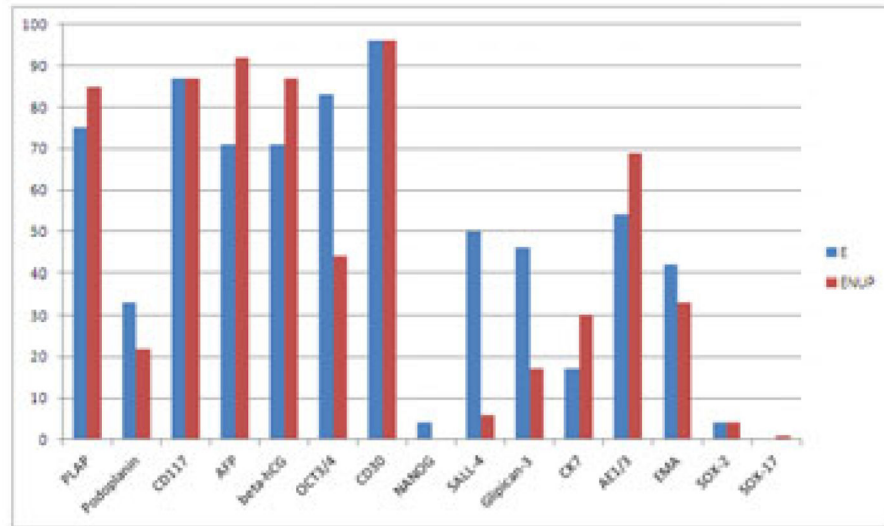
**Figure 1.**

Figure 1a. Rete testis showing pagetoid invasion by intra tubular germ cell neoplasia, unclassified

Figure 1b. Rete testis, showing widespread invasion of the interstitium by seminoma.



**Figure 2.** Variation in tumour-node-metastasis (TNM) staging in particular scenarios by the expert panel.



**Figure 3.** Frequency of use of different immunochemical antibodies by ENUP members and experts. E=Experts ENUP=European network of Uro-Pathology.

Author Manuscript

Author Manuscript

Author Manuscript

Author Manuscript

**Table 1**

## Testis Questionnaire.

1	Please state your name
2	In which country do you practice?
3	Approximately how many radical orchidectomy specimens or consultation testis cases do you receive per year? 1–20 20–50 50–100 Greater than 100
4	Of these, what percentage is in consultation for second opinion/referred from a nonspecialist centre? 0% 0–25% 25%–50% Greater than 50%
5	How do you receive the specimen? Fresh Formalin fixed Bouin's fixed
6	Do you perform frozen section diagnosis of testicular tumours? Yes, for all cases For selected cases only when considering partial orchidectomy Never
7	Do you ever take fresh tissue for biobanking? Y/N
8	If you receive fixed specimens do the surgeons incise them before receipt? Yes No Sometimes
9	Do you routinely take the cord margin? Y/N
10	How many other cord blocks do you routinely take? None 1 2 or more Only if there is a macroscopic abnormality
11	Do you routinely take cord blocks before incising the testis? Y/N
12	Do you use any ink on any part of the specimen? Y/N

- 13 If yes, how many colours?  
1  
2  
3
- 14 What methods do you use to decide number of tumour blocks?  
Fixed number regardless of size  
Subjective decision, correlating o size  
Fixed number of blocks per cm  
tumour diameter  
No set protocol  
Other method
- 15 Do you measure the cord length?  
Y/N
- 16 Do you measure the testis size (including the tumour)?  
Y/N
- 17 Do you measure the tumour size?  
Y/N
- 18 If yes, how do you measure the tumour?  
Ruler, maximum diameter on cut section  
Ruler, 2 diameters on cut section  
Ruler, 3 diameters  
Estimation, maximum diameter on cut section  
Estimation, 2 diameters on cut section  
Estimation, 3 diameters  
Comparisons to objects such as golf balls, bird eggs, nuts (specify)  
Subjective description
- 19 Do you routinely take a block(s) to examine the rete testis and hilum to examine its involvement by tumour?  
Y/N
- 20 Do you comment on the outer layer of the tunica vaginalis and whether it is stuck down to the testis or not?  
Y/N
- 21 Do you always take a block of grossly normal testicular parenchyma if present?  
Y/N
- 22 Any other comments on special macro techniques?
- 23 What system do you use to classify GCTs?  
WHO 2004  
British Testicular Tumour Panel  
Classification  
Earlier WHO  
Both BTTP and WHO
- 24 Do you always report the percentages of different tumour types of a germ cell tumor?  
Yes  
No  
Only percentage of embryonal carcinoma  
Other

- 25 For teratoma do you report the degree of immaturity?  
Y/N
- 26 Do you report the presence of primitive neuroectodermal elements?  
Y/N
- 27 Do you always report whether vascular invasion is present or absent?  
Y/N
- 28 Do you report the type of tumour involved in vascular invasion?  
Y/N
- 29 Do you distinguish between lymphatic and blood vessel invasion?  
Y/N
- 30 If you see blood vessel invasion but no stromal invasion in the cord (distant from the tumour) do you stage as T2 or T3?  
T2  
T3
- 31 Do you always report rete testis invasion?  
Y/N
- 32 Do you distinguish between pagetoid invasion of the rete epithelium and invasion of the rete stroma?  
Y/N
- 33 For seminoma, do you make any assessment of 'differentiation'?  
Y/N  
(Please comment on method)
- 34 Do you routinely report the presence of IGCNU?  
Y/N
- 35 Do you always use the TNM staging classification?  
Y/N
- 36 How would you stage the following scenario: Tumour invading the tunica albiginea and the inner serosal lining of the testis but not the outer layer, no vascular invasion?  
T1  
T2  
T3
- 37 How would you stage the following scenario: Tumour invading the epididymis, no vascular invasion?  
T1  
T2  
T3
- 38 How would you stage the following scenario: Tumour invading the hilar fatty tissue adjacent to the epididymis, no vascular invasion?  
T1  
T2  
T3
- 39 How would you stage the following scenario: Tumour deposit in the upper cord with separate tumour confined to testis, vascular invasion present?  
T2  
T3
- 40 How often do you use immunochemistry in the diagnosis of testicular tumours?  
Every case

- 50–100% of cases
- 10–50% of cases
- Less than 10% of cases
- Never

41 Which immunochemical antibodies do you use in your routine diagnosis of germ cell malignancies? Please tick if used

- PLAP
- Podoplanin
- CD117
- Alpha feto-protein
- Beta hCG
- OCT3/4
- CD30
- NANOG
- SALL-4
- Glipican-3
- Cytokeratin-7
- Cytokeratin AE1/3
- EMA
- SOX-2
- SOX-17

42 Do you ever ask for i12p assessment on challenging cases?

Y/N

43 If you have any further comments on important controversies in testicular pathology then please outline them below.

---

Author Manuscript

Author Manuscript

Author Manuscript

Author Manuscript



**Table 2**

Macroscopic methods for testis examination of Experts (E) and ENUP members. Where the total number of respondents does not add up to 25 (Expert) or 225 (ENUP), the remainder chose not to supply an answer to the question.

	Experts %(N)		ENUP Members %(N)	
	Yes	No	Yes	No
Tissue received Fresh?	36% (9)	64% (16)	37% (82)	63% (141)
Frozen section performed?	All cases 8% (2)	Selected cases Never 24% (6)	All cases 8% (17)	Selected cases Never 35% (79)
Surgeons incise specimen?	Yes 4% (1)	Sometimes No 54% (13)	Yes 14% (31)	Sometimes No 53% (115)
Fresh tissue biobanked?	Yes 56% (14)	No 44% (11)	Yes 30% (68)	No 70% (155)
Cord margin Sampled?	Yes 96% (24)	No 4% (1)	Yes 98% (219)	No 2% (5)
Cord margin sampled before incision?	Yes 84% (21)	No 16% (4)	Yes 70% (154)	No 30% (66)
Do you measure cord length?	Yes 100% (25)	No 0% (0)	Yes 96% (211)	No 4% (8)
Do you measure testis size?	Yes 100% (25)	No 0% (0)	Yes 99% (220)	No 1% (1)
No of other cord blocks taken?	None 0% (0)	1 36% (9)	None 1% (2)	1 37% (82)
Do you use ink?	Yes 48% (12)	2 or more 48% (12)	Yes 38% (85)	Only if abnormal 2 or more 7% (15)
If yes, how many colours	1 100% (12)	16% (4)	1 93% (80)	More than 1 7% (6)
Do you measure tumour size?	Yes 100% (25)	No 0% (0)	Yes 99% (221)	No 1% (1)
How tumour Measured?	1 dimension 20% (5)	2 dimensions 24% (6)	1 dimension 30% (51)	2 dimension 29% (65)
		3 dimensions 56% (14)		3 dimension 47% (104)

	Experts %(N)			ENUP Members %(N)		
	Fixed number	Subjective decision	Fixed no per cm tumour	Fixed number	Subjective decision	Fixed no per cm tumour
No of blocks taken?	0%(0)	56% (13)	22%(5)	2%(5)	65% (143)	24%(53)
Block from the rete taken?	Yes	No	No	Yes	No	No
	100%(25)		0%(0)	98%(220)		2%(4)
Block taken of normal?	Yes	No	No	Yes	No	No
	100%(25)		0%(0)	98%(218)		2%(4)
Comment on tunica vaginalis?	Yes	No	No	Yes	No	No
	78%(18)		22%(5)	82%(184)		17%(39)

**TABLE 3**

Differences in microscopic assessments of testicular tumours between experts and ENUP members. Where the total number of respondents does not add up to 25 (Expert) or 225 (ENUP), the remainder chose not to supply an answer to the question.

	Experts % (N)				ENUP % (N)			
	WHO2004	BTTP	Earlier WHO	Both BTTP and WHO	WHO2004	BTTP	Earlier WHO	Both BTTP and WHO
Classification system used								
% of tumour types reported?	96% (24) Yes	0% (0) No	0% (0) Only EC	4% (1)	86% (192) Yes	1% (1) No	2% (5) Only EC	11% (25) 2% (5)
Immaturity reported in teratoma?	92% (23) Yes	4% (1)	4% (1)		77% (173) Yes	20% (45)		2% (5)
PNET reported?	32% (8) Yes		68% (17) No		68% (150) Yes		32% (71) No	
TNM stage always reported	88% (22) Yes		12% (3) No		84% (186) Yes		16% (35) No	
Vascular invasion(VI) reported?	96% (24) Yes		4% (1) No		95% (207) Yes		5% (10) No	
Tumour type in VI reported?	100% (25) Yes		0% (0) No		99% (221) Yes		1% (2) No	
Lymphatics and blood vessels distinguished?	56% (14) Yes		44% (11) No		54% (120) Yes		46% (102) No	
Stage of blood vessel invasion in cord but no stromal invasion	28% (7) T2		72% (18) T3		41% (93) T2		59% (131) T3	
Rete invasion reported?	79% (19) Yes		21% (5) No		78% (169) Yes		22% (47) No	
Distinction between pagetoid/stromal rete invasion?	96% (24) Yes		4% (1) No		94% (208) Yes		6% (14) No	
Assessments of differentiation made in seminoma?	96% (24) Yes		4% (1) No		63% (139) Yes		37% (83) No	
IGCNU reported?	28% (7) Yes		72% (18) No		12% (26) Yes		88% (195) No	

	Experts % (N)		ENUP %(N)	
	92% (23)	8% (2)	95% (207)	5% (10)
Stage of tumour invading inner serosal lining of testis with no vascular invasion	T1	T2	T1	T2
	52% (13)	48% (12)	67% (146)	33% (72)
Stage of tumour invading epididymis with no vascular invasion?	T1	T2	T1	T2
	88% (22)	12% (3)	91% (195)	7% (15)
Stage of tumour invading hilar fatty tissue with no vascular invasion	T1	T2	T1	T2
	40% (10)	36% (9)	43% (90)	30% (63)
Stage of tumour deposit in upper cord with separate tumour in testis?	T2 with soft tissue deposit	T3	T2 with soft tissue deposit	T3
	28% (7)	68% (17)	23% (50)	75% (162)

**Table 4**

Frequency of use of Immunochemistry for testicular tumours.

Use of immunochemistry in the testis	ENUP N (%)	Experts N (%)
Every case	78 (35%)	0 (0%)
50–100% of cases	75 (33%)	3 (12%)
10–50% of cases	54 (24%)	9 (36%)
Less than 10% of cases	17 (8%)	13 (52%)
Never	0 (0%)	0 (0%)

Author Manuscript

Author Manuscript

Author Manuscript

Author Manuscript