

## Expression of HLA-ABC, HLA-DR and intercellular adhesion molecule-1 in oesophageal carcinoma

J C Rockett, S J Darnton, J Crocker, H R Matthews, A G Morris

### Abstract

**Aim**—To examine the expression of HLA-ABC and HLA-DR major histocompatibility (MHC) antigens and intercellular adhesion molecule (ICAM)-1 in normal, inflamed, metaplastic, and neoplastic oesophageal tissue and in freshly disaggregated tumours.

**Methods**—Sequential sections of frozen tissue and cytopspins of freshly disaggregated tumour were stained using the ABC peroxidase system and monoclonal antibodies specific for HLA-ABC, HLA-DR and ICAM-1.

**Results**—Normal oesophageal tissue showed positive staining for HLA-ABC in the basal layers of the oesophageal squamous epithelium and on the epithelial cells of the submucosal oesophageal glands. HLA-DR and ICAM-1 were not detected in either of these cell types. In 20 of 37 (54%) carcinomas HLA-ABC was expressed weakly, with heterogeneous expression in nine (24%). Two tumours showed strong expression of HLA-ABC, but 15 of 37 (41%) were negative. HLA-DR and ICAM-1 were expressed weakly in six of 37 (16%) carcinomas without correlation with each other or with the expression of HLA-ABC.

**Conclusions**—HLA-ABC is absent from a high proportion of oesophageal carcinomas (41%) and is otherwise variably and weakly expressed with strong expression in only a small fraction (3%). In other carcinomas there is a higher level of HLA-ABC expression. This discrepancy may partly explain the aggressive nature of oesophageal carcinomas. HLA-DR and ICAM-1 are not normally expressed on those cells from which oesophageal carcinomas are thought to arise. The limited expression found here could suggest a partial or inhibited immune response against oesophageal carcinoma. **In vivo repressive factors may be involved.**

(*J Clin Pathol* 1995;48:539-544)

**Keywords:** HLA antigens, intercellular adhesion molecule-1, oesophageal carcinoma.

An important factor which may affect the capacity of a tumour to elicit a cellular immune response is its expression of human leucocyte antigens (HLA) and intercellular adhesion molecule (ICAM)-1. These molecules may play an important role in regulating the progression of malignant growth. This is related to their central function in modulating the cellular immune

response. Abnormal antigen expression by target cells is recognised by T cells in the context of HLA,<sup>1</sup> whilst ICAM-1 serves to modulate leucocyte adhesion and enhances immune recognition and target-effector interaction.<sup>2</sup>

HLA-ABC, also called major histocompatibility complex (MHC) class I, antigens are expressed constitutively by most normal nucleated cells<sup>3</sup> but may be lost in transformation to the neoplastic state.<sup>4-6</sup> There is evidence that such a loss of expression can correlate significantly with a decreased degree of tumour differentiation—for example, in larynx,<sup>7</sup> breast,<sup>8</sup> lung,<sup>9</sup> and basal cell carcinomas,<sup>10</sup> and also with a worse prognosis, at least in the case of laryngeal and breast carcinomas.

HLA-DR (MHC class II) and ICAM-1 are not normally expressed on most epithelia<sup>11,12</sup> but may appear in various inflammatory conditions, presumably after induction by cytokines secreted by infiltrates of activated T cells and other leucocytes—for example, in ulcerative colitis,<sup>13</sup> rejecting allografts<sup>14,15</sup> and autoimmune disorders.<sup>16,17</sup> The expression of both of these molecules by premalignant and malignant lesions is complex, although neither are commonly expressed on most tumours. This seems to be the case even where there are infiltrates of activated leucocytes which might be expected to produce the cytokines that would induce them.<sup>18,19</sup>

A recent report placed oesophageal carcinoma as the ninth most common cancer worldwide, accounting for some 4% of total cases.<sup>20</sup> As oesophageal carcinoma is relatively uncommon in the United Kingdom (less than 2% of total cancer cases<sup>21</sup>), few studies of the immunological nature of the disease have been carried out here. Its cause also remains largely unknown. The disease is increasing in incidence—between 1956 and 1960 and 1981 and 1985 there was a rise of 25% in men and 32% in women in the number of reported cases in England and Wales.<sup>21</sup> Furthermore, oesophageal carcinoma is a very aggressive malignancy which progresses quickly and has a high mortality. The five year survival rate can be less than 4%.<sup>22</sup>

In this study we examined for the first time the expression of MHC and ICAM-1 in tumours of 37 patients with oesophageal carcinoma and seven with adenocarcinomas of the gastric cardia. Three resected benign oesophagoi and five samples of Barrett's epithelium from tumour bearing oesophagoi were also investigated. Where possible the expression in tumour cells was compared with that of normal cells derived from the same resected specimen.

Clinical Sciences  
Laboratory,  
Department of  
Biological Sciences,  
University of Warwick,  
Coventry CV4 7AL  
J C Rockett  
A G Morris

Department of  
Thoracic Surgery,  
Birmingham  
Heartlands  
Hospital,  
Birmingham B9 5SS  
S J Darnton  
H R Matthews

Department of  
Histopathology  
J Crocker

Correspondence to:  
Dr A G Morris.

Accepted for publication  
13 October 1994

## Methods

### TISSUE SPECIMENS

Thirty seven resected oesophageal and seven gastric carcinomas were studied for phenotypic expression of HLA and ICAM-1 antigens. There were 13 oesophageal adenocarcinomas, 10 oesophageal adenocarcinomas arising in an obvious Barrett's oesophagus, 10 oesophageal squamous cell carcinomas, four adenocarcinomas of the oesophagus, and seven adenocarcinomas of the gastric cardia. Non-neoplastic squamous and glandular epithelia away from the tumour were examined where possible. Three benign oesophagoi resected for stricture were also examined. Patients ranged in age from 42 to 83 years, with a mean of 65.8 years.

Biopsy specimens (approximately 3 mm<sup>3</sup>) were selected from the opened oesophageal specimens immediately after resection. The rolled edge of the tumour was sampled in order to obtain a good yield of viable tumour cells. No epithelium adjacent to the tumour was

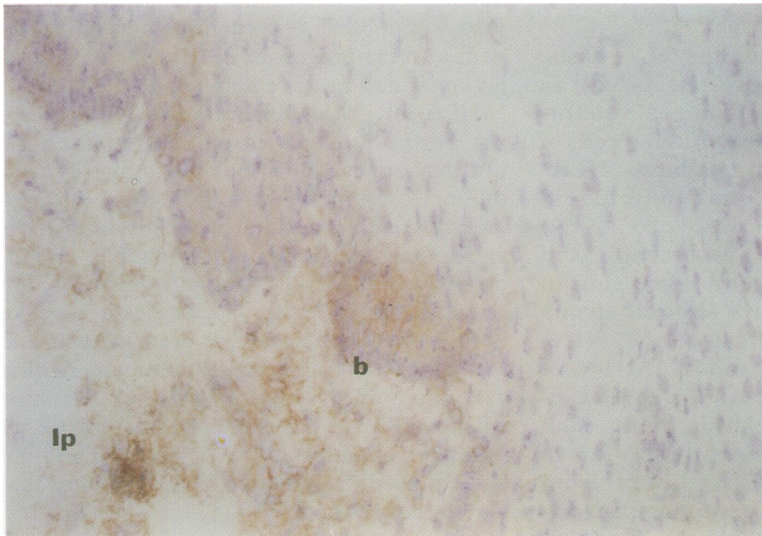


Figure 1 Case with squamous carcinoma. Normal stratified squamous epithelium distant from tumour in which lowest layers are positive for HLA-ABC (b=basal layer, lp=lamina propria). (Original magnification  $\times 100$ .)

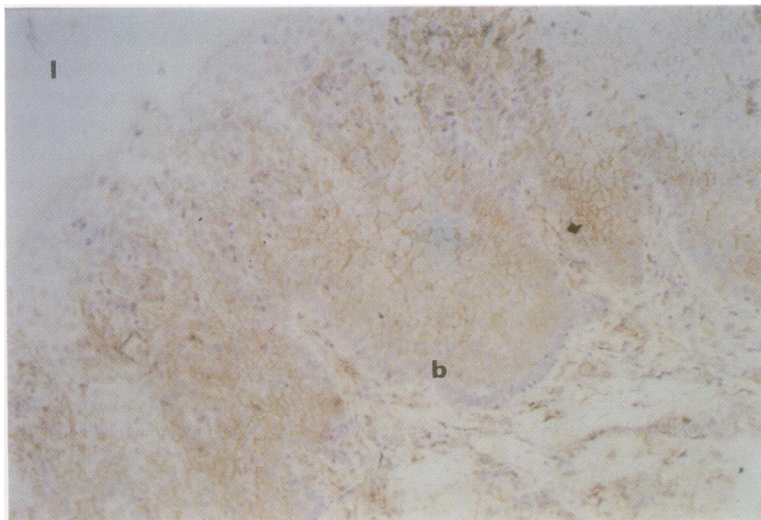


Figure 2 Case with benign stricture. Inflamed stratified squamous epithelium is positive for HLA-ABC throughout all layers, except in the superficial squames (b=basal layer, l=lumen). (Original magnification  $\times 100$ .)

taken. Similarly sized pieces of normal tissue were obtained from an area at least 5 cm away from any gross tumour. Samples were washed in medium before mincing. A single cell suspension was obtained by digesting overnight in 10 ml medium containing the enzymes collagenase (Boehringer Mannheim, Lewes, UK; 1 mg/ml), hyaluronidase (Boehringer Mannheim; 0.01 mg/ml) and DNase I (Boehringer Mannheim; 0.01 mg/ml). Any undigested clumps of tissue were removed and the remaining cell suspension washed twice in medium before being counted and assessed for viability using trypan blue exclusion staining. If the cells were sufficient in number and their viability exceeded 50%, they were used in further experiments. Duplicate samples of tumour and normal tissue were taken, snap frozen and stored in liquid nitrogen for immunohistochemical examination.

### TISSUE AND CYTOSPIN PREPARATION

Consecutive 7  $\mu$ m cryostat sections were fixed for 20 minutes in acetone at  $-20^{\circ}\text{C}$  and then stored at  $-80^{\circ}\text{C}$  until staining. Immediately after digestion of each tumour, cytospin preparations were made (using a Shandon Cytospin 3, Shandon Scientific, Runcorn, UK) with 5000 cells per slide. These were fixed in acetone for 20 minutes at  $-20^{\circ}\text{C}$  and then stored at  $-80^{\circ}\text{C}$  until staining.

### IMMUNOHISTOCHEMICAL STAINING OF TISSUE SECTIONS AND CYTOSPINS

Endogenous peroxidase was inhibited in methanol containing 0.6% hydrogen peroxide for 12 minutes. The staining procedure accompanying the Vectastain "Elite" ABC kit (Vector Laboratories, Peterborough, UK) was followed. All of the primary antibodies were monoclonal mouse antihuman. The HLA-ABC (clone W6/32, isotype IgG2a), HLA-DR (clone CR3/43, isotype IgG1) and IgG1/IgG2a negative control antibodies were obtained from Dako (High Wycombe, UK). The ICAM-1 (clone 84H10, isotype IgG1) antibody was obtained from Serotec (Oxford, UK). 3,3'-Diaminobenzidine (DAB; Sigma, Poole, Dorset, UK) was used as chromogen. Parallel negative controls were performed using non-specific antibodies of IgG1/IgG2a isotypes. Parallel positive controls were performed using sections of tonsil. Sections were counterstained with Mayer's haematoxylin and mounted in DPX.

In reporting, cases were considered to be negative (less than 5% of cells stained), positive (more than 95% of cells stained), or heterogeneously positive (5–95% stained). The intensity of staining relative to internal stromal and inflammatory cells was also noted.

### ROUTINE HISTOPATHOLOGICAL EXAMINATION

The tumours were classified for T, N and G according to the UICC system.<sup>23</sup> Grade was reported according to the most poorly differentiated area seen.

Table 1 Immunohistochemical staining of tumour sections

Sample type	HLA-ABC			HLA-DR			ICAM-1		
	0	+	++	0	+	++	0	+	++
Oesophageal									
squamous cell carcinoma	4	2	4	10	0	0	8	1	1
adenosquamous carcinoma	1	2	0	3	0	0	2	1	0
adenosquamous carcinoma in Barrett's oesophagus	1	0	0	1	0	0	1	0	0
adenocarcinoma	5	4	4	11	1	1	12	1	0
adenocarcinoma in Barrett's oesophagus	4	1	5	6	1	3	8	1	1
Total	15	9	13	31	2	4	31	4	2
benign oesophagus (squamous cell epithelium)*	0	0	3	2	0	1	1	0	2
Barrett's oesophagus	1	0	4	4	0	1	4	0	1
Gastric									
adenocarcinoma	1	1	5	6	1	0	5	1	1
Total (tumours only)	16	10	18	37	3	4	36	5	3

0=no staining; +=5-95% positive; ++=100% positive.

\* See text for further explanation.

## Results

### EXPRESSION OF HLA ANTIGENS AND ICAM-1 IN TUMOUR SECTIONS

#### Normal oesophagus

Normal oesophageal and gastric mucosa obtained from distant areas of the resected specimen, not macroscopically involved by the

tumour or local inflammation, were stained with each antibody. Submucosal oesophageal glands were positive for HLA-ABC but negative for HLA-DR and ICAM-1. Oesophageal squamous cell epithelium was also negative for HLA-DR and ICAM-1 through all layers. However, the first one to six basal layers of the epithelium were positive for HLA-ABC (fig 1).

Gastric mucosa was positive for all three antigens. The staining was confined to the upper regions (pits) of the gastric glands.

#### Benign and Barrett's oesophagus

All three resected benign strictures of the oesophagus had hyperplastic squamous epithelium and were highly inflamed. In one, with an intense lymphocytic and eosinophilic infiltrate of the lamina propria, the entire depth of the squamous epithelium (with the exception of the superficial squames) was strongly positive for HLA-ABC (fig 2). The first three basal layers were positive for HLA-DR and the first basal layer was positive for ICAM-1. Another was also positive for HLA-ABC, although only through about half the depth of the epithelium. This sample was negative for HLA-DR but focally positive in the basal two layers for ICAM-1. The third case showed squamous staining identical with that seen in normal tissue.

Five specimens of adenocarcinoma included Barrett's oesophagus with intestinal metaplasia. In one of these there was carcinoma in situ whilst another showed moderate dysplasia. The remaining three were non-dysplastic, non-neoplastic. Both the carcinoma in situ and dysplastic cases were positive for HLA-ABC but negative for HLA-DR and ICAM-1. Two out of three non-dysplastic, non-neoplastic cases were positive for HLA class I. One of these was also positive for HLA-DR and one for ICAM-1. The third sample was negative for all three antigens.

#### Oesophageal carcinoma

**HLA-ABC**—Staining showed extensive heterogeneity of expression by the neoplastic cells both within and between tumours (table 1). In all, 24 of 37 (65%) oesophageal carcinomas, but only two of seven (29%) gastric cardia tumours, showed some or total loss of HLA-ABC expression on the malignant cells. There

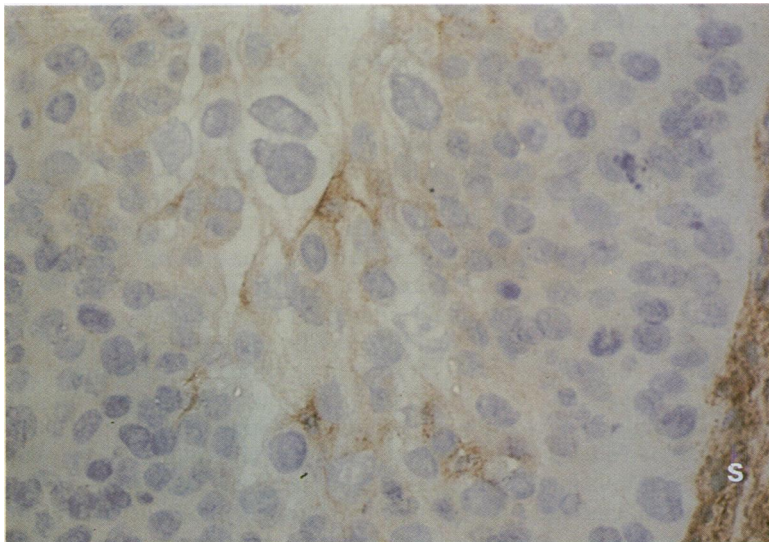


Figure 3 Case with squamous carcinoma. Neoplastic cells show a positive cytoplasmic bluish with focal membranous staining for HLA-ABC. Cells within the adjacent stroma(s) are strongly positive. (Original magnification  $\times 250$ .)

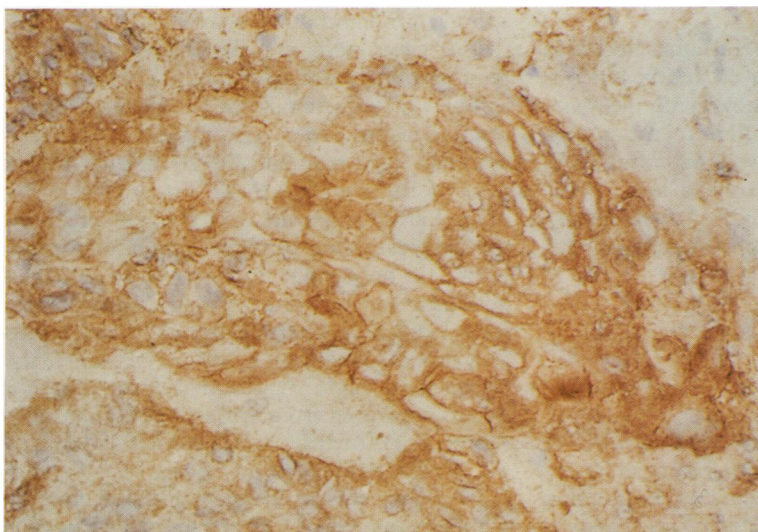


Figure 4 Case with adenocarcinoma in Barrett's oesophagus. Neoplastic cells show cytoplasmic and strong membranous positivity for HLA-ABC, the latter giving a "chicken-wire" effect. (Original magnification  $\times 250$ .)

Table 2 Tumour staging

Tumour type	Stage (pTpN)				Grade		
	I	IIa	IIb	III	1	2	3
Squamous cell carcinoma		7	1	2		5	5
Adenosquamous carcinoma				2			2
Adenosquamous carcinoma in Barrett's oesophagus		1		1			2
Adenocarcinoma		5	1	7	1	5	7
Adenocarcinoma in Barrett's oesophagus	1	5	1	3		4	6
Gastric adenocarcinoma		1		6		3	4

was a total absence of expression in 15 of 37 (41%) oesophageal specimens, but in only one of seven (14%) gastric specimens. No obvious distinction between the different tumour types was apparent, with oesophageal adenocarcinomas and squamous carcinomas showing the same heterogeneity. Positive staining of tumour cells was consistently weaker than that of the infiltrating leucocytes and the vascular endothelial and stromal cells. Positive staining on all malignant cells was observed as a pale brown blush across the cytoplasm (fig 3). Five specimens with different histologies also showed sparse membranous positivity, whilst two more tumours (both adenocarcinomas in Barrett's oesophagus) showed a homogeneous intense membranous positivity giving rise to a "chicken-wire" effect (fig 4). Staging of the tumours is shown in table 2. The degree of tumour differentiation and staging did not correlate with HLA-ABC expression.

**HLA-DR**—This antigen was absent in the majority of both oesophageal and gastric cardia tumours (84% and 86% of samples, respectively). Squamous carcinomas were all negative. Two adenocarcinomas, one in Barrett's oesophagus, showed some heterogeneous staining although this was weak and largely only cytoplasmic. Three of 10 (30%) adenocarcinomas arising in Barrett's oesophagus showed homogeneous staining, including patchy membranous positivity, compared with only one of 13 (8%) of those arising in the absence of Barrett's epithelium. Again, there was no correlation between HLA-DR expression and tissue differentiation or tumour staging.

**ICAM-1**—The majority of tumours were negative. Four, however, showed heterogeneous and two homogeneous staining, with positivity always cytoplasmic and often membranous. The expression was again weak in comparison with that of stromal and endothelial cells. There was no apparent pattern in ICAM-1 expression relating to the different types of tumour, nor was there any correlation with the degree of differentiation or staging.

#### HLA AND ICAM-1 STAINING IN CYTOSPINS OF DISAGGREGATED TUMOURS

Cytospins from 25 tumours were stained in order to confirm, by a different method, staining of tumour cells in the sections. Expression by tumour cells in the majority of cytospins reflected that seen in stained sections of the original tumours. However, 11 of 25 (44%) samples showed changes in expression of one

or more of the antigens. Most were alterations in the expression of a single antigen only: in three cases there was a higher percentage of malignant cells stained for HLA-ABC in the cytospins than in the original tumour section. Three cytospins stained for ICAM-1 also showed this pattern. In one sample there was reduction in the level of HLA-ABC expression. Four tumours showed changes in more than one antigen in cytospins compared with the original tumour sections. One of these showed an increase in HLA-ABC and -DR, one an increase in HLA-ABC and ICAM-1, and one an increase in HLA-DR but a decrease in ICAM-1 expression. The fourth sample showed increased expression of all three antigens.

#### Discussion

Much has been published about the HLA status of carcinomas such as lung, breast, larynx, colon, and cervix.<sup>24</sup> However, similar studies in oesophageal carcinoma have not been carried out before. In this study we also stained normal stratified squamous oesophageal mucosa for HLA and ICAM-1 to compare the expression with that seen in oesophageal carcinoma.

Only four of 14 (29%) malignant tumours with a squamous component were homogeneously positive for HLA-ABC. This is surprising as squamous malignancies presumably arise from the dividing suprabasal layer of the epithelium, and this was found to be positive in normal tissue. Furthermore, two of three inflamed (benign) oesophagoi were shown to have enhanced expression of HLA-ABC. This indicates that squamous cells are able to respond to inflammatory cytokines.

Ten cases with non-neoplastic tissue containing submucosal oesophageal glands and five samples of Barrett's epithelium, the perceived premalignancy of oesophageal adenocarcinoma, were studied. All 10 normal glands were positive for HLA-ABC. Four of five (80%) of the Barrett's samples were positive, including the dysplastic and carcinoma in situ samples. However, only nine of 23 (39%) oesophageal adenocarcinomas were homogeneously positive for HLA-ABC. A further five (22%) were heterogeneous. Although numbers are small, this observation might suggest that development of adenocarcinoma from either type of glandular tissue is frequently accompanied by loss of HLA-ABC expression.

In other cases aberrant expression may accompany neoplasia. The majority of positive adenocarcinomas in this study had pale staining across the cytoplasm and seemed to have little membrane positivity. This could point

to a malfunction in transportation of the molecules<sup>25</sup> to the cell surface, as has been reported in colorectal carcinoma.<sup>26</sup>

There are several possible implications from these observations of HLA-ABC in oesophageal carcinoma. The first is that the tumour clone(s) may have acquired a mutation which causes downregulation of HLA-ABC antigens. In vivo this would lead to fewer immune recognition molecules to stimulate a cytotoxic (CD8+) T cell response. Alternatively, or additionally, the tumour cells may have become refractory to the effects of cytokines, such as interferon- $\gamma$ , which are produced by leucocytes in an immune response and which normally upregulate HLA antigens. It is also possible that the tumour infiltrating lymphocytes (TIL) are not actually secreting such cytokines because there is repression of TIL activation in the local tumour environment. We are currently investigating this last possibility.

The low expression of HLA-DR and ICAM-1 (only 16% of samples expressed one or both to some degree) by these tumours is perhaps not surprising if one considers that the cells of origin are normally negative for these antigens. There is evidence that some premalignant and benign lesions of epithelial tumours (breast, colon, cervix, larynx) acquire de novo expression of HLA-DR.<sup>24</sup> We did not find this in our limited study of Barrett's oesophagus, with only one of five (20%) samples proving positive. However, the limited expression of these molecules in oesophageal carcinoma is suggestive of cytokine induction from a partial immune response. The biological significance of the limited induction of these molecules is not yet known, but again could be related to suppression of infiltrating lymphocytes. Certainly, in other inflammatory conditions, such as graft versus host disease,<sup>14,15</sup> Crohn's disease,<sup>13</sup> ulcerative colitis,<sup>13</sup> and coeliac disease,<sup>27</sup> there is a pronounced induction of HLA-DR compared with the normal tissue. Indeed, two of three of the benign oesophagoi in this study stained positively for HLA-DR in the squamous epithelium, the only time this was observed. This is probably caused by chronic inflammation in such benign lesions where there are high concentrations of cytokine secreting lymphocytes and eosinophils.

ICAM-1 is expressed in malignant melanoma<sup>28-30</sup> and squamous cell carcinomas,<sup>31</sup> but only in a minority of samples from adenocarcinomas of various organs.<sup>28</sup> Our study also found little expression in adenocarcinomas, but we did not observe expression in the majority of squamous cell carcinomas of the oesophagus. Further characterisation of ICAM-1 expression in different malignancies is required.

The staining of cytopspins (11/25 cases) often showed a discrepancy with staining in sections. There was usually an increase in the percentage of cells expressing one or more of the three antigens examined. This could suggest release from an inhibitory factor(s) in the local tumour environment, which then permitted antigen expression in the disaggregated cells. It is possible that cytokines produced by TILs had instigated upregulation signals for the HLA and ICAM-1

antigens in vivo, but that the assembly and transportation of these antigens to the cell surface had been blocked by some suppressive agent. The presence of such a suppressive factor could perhaps explain the cytoplasmic staining but lack of membranous staining in the majority of positive sections.

We are currently investigating the relation between inflammatory cell infiltrate and HLA/ICAM-1 expression. Although this work is incomplete at this time, the results obtained to date suggest that there is no correlation between absolute numbers of total inflammatory, CD3 positive or interleukin-2 receptor positive cells and HLA/ICAM-1 status.

In conclusion, we have shown that a high proportion of oesophageal tumours show loss of HLA-ABC expression compared with the normal tissue from which they are derived and with most other carcinomas. We suggest that this may be important in the progression of this aggressive malignancy. We have also shown that there is limited expression of HLA-DR and ICAM-1 in this tumour and suggest that this represents a restricted immune response. In vivo local suppressive factors may lead to the inhibition of antigen expression.

JCR and SJD are supported by the Oesophageal Cancer Research Appeal (OCRA), Birmingham, UK.

- Zinkernagel R, Doherty P. MHC-restricted cytotoxic T-cells: studies on the biological role of polymorphic major transplantation antigens determining T-cell restriction-specificity, function and responsiveness. *Adv Immunol* 1979;27:51-177.
- Johnson JP. The role of ICAM-1 in tumour development [review]. *Chem Immunol* 1991;50:143-63.
- Darr AS, Fuggle SV, Fabre JW, Ting A, Morris PJ. The detailed distribution of HLA-ABC antigens in normal human organs. *Transplantation* 1984;38:287-92.
- Fleming KA, McMichael A, Morton JA, Woods J, McGee JO'D. Distribution of class I antigens in normal and in mammary cancer. *J Clin Pathol* 1981;34:779-84.
- Lopez-Nevot MA, Esteban F, Ferron A, Gutierrez J, Oliva MR, Romero C, et al. HLA class I gene expression on human primary tumours and autologous metastases: demonstration of selective losses of HLA antigens in colorectal, gastric and laryngeal carcinomas. *Br J Cancer* 1989;59:221-6.
- Connor ME, Stern PL. Loss of MHC class I expression in cervical carcinomas. *Int J Cancer* 1990;46:1029-34.
- Esteban F, Concha A, Delgado M, Perez-Ayala M, Ruiz-Cabello F, Garrido F. MHC class I antigens and tumour aggressiveness of the squamous cell carcinoma of the larynx. *Br J Cancer* 1990;62:1047-51.
- Concha A, Cabrera T, Ruiz-Cabello F, Garrido F. Can the HLA phenotype be used as a prognostic factor in breast carcinomas. *Int J Cancer* 1991;Suppl 6:146-54.
- Redondo M, Concha A, Oldiviera R, Cueto A, Gonzalez F, Garrido F, et al. Expression of HLA class I and II antigens in bronchogenic carcinomas: Its relationship to cellular DNA content and clinical-pathological parameters. *Cancer Res* 1991;51:4948-54.
- Cabrera T, Garrido V, Concha A, Martin J, Esquivias J, Oliva MR, et al. HLA molecules in basal-cell carcinoma of the skin. *Immunobiology* 1992;185:440-52.
- Daar AS, Fuggle SV, Fabre JW, Ting A, Morris PJ. The detailed distribution of class II antigens in normal human organs. *Transplantation* 1984;38:293-8.
- Klareskog L, Forsum U. Tissue distribution of class II transplantation antigens: presence on normal cells. *Scand J Immunol* 1984;21:389-96.
- Selby WS, Janossy G, Mason DY, Jewell DP. Expression of HLA-DR antigens by colonic epithelium in inflammatory bowel disease. *Clin Exp Immunol* 1983;53:614-18.
- Tufvesson G, Forsum U, Claesson K, Klareskog L, Larsson E, Karlsson-Parra A, et al. T-lymphocyte subsets and HLA expressing cells in rejected human kidney grafts. *Scand J Immunol* 1983;18:37-40.
- Lampert IA, Janossy G, Sutters AJ, Bofill MB, Palmer S, Gordon-Smith E, et al. Immunological analysis of the skin on graft versus host disease. *Clin Exp Immunol* 1982;50:123-31.
- Janossy G, Panai G, Duke U, Bofill M, Poulter LW, Goldstein G. Rheumatoid arthritis: a disease of T lymphocyte and macrophage immunoregulation. *Lancet* 1981;ii:839-43.
- Klareskog L, Forsum U, Malmnas Tjernlund U, Kabelitz D, Wigren A. Appearance of anti-HLA-DR reactive cells

- in normal and rheumatoid synovium. *Scand J Immunol* 1981;14:183-92.
- 18 Glew SS, Duggan Keen M, Cabrera T, Stern PL. HLA class II antigen expression in human papillomavirus-associated cervical cancer. *Cancer Res* 1992;52:4009-16.
  - 19 Csiba A, Whitwell HL, Moore M. Distribution of histocompatibility and leukocyte differentiation antigens in normal human colon and in benign and malignant colonic neoplasms. *Br J Cancer* 1984;50:699-709.
  - 20 Parkin DM, Pisani P, Ferlay J. Estimates of the worldwide incidence of eighteen major cancers in 1985. *Int J Cancer* 1993;54:594-606.
  - 21 Cheng KK, Day NE, Davies TW. Oesophageal mortality in Europe: paradoxical time trend in relation to smoking and drinking. *Br J Cancer* 1992;65:613-17.
  - 22 Matthews HR, Waterhouse JAH, Powell J, McConkey CC, Robertson JE (eds). Cancer of the oesophagus. In: *Clinical cancer monographs*. Vol 1. London: Macmillan, 1993:114-65.
  - 23 Hermanek P, Sobin LH (eds). *UICC TNM classification of malignant tumours*. 4th edn, 2nd revision. Berlin: Springer-Verlag, 1992:42-4.
  - 24 Garrido F, Cabrera T, Concha A, Glew S, Ruiz-Cabello F, Stern PL. Natural history of HLA expression during tumour development. *Immunol Today* 1993;14:491-9.
  - 25 Braciale TJ, Braciale VL. Antigen presentation: structural themes and functional variations. *Immunol Today* 1991;12:124-9.
  - 26 Cabrera T, Concha A, Ruiz-Cabello F, Garrido F. Loss of HLA heavy chain and beta-2-microglobulin in HLA negative tumours. *Scand J Immunol* 1991;34:147-52.
  - 27 Scott H, Brandtzaeg P, Solheim BG, Thorsby E. Relationship between HLA-DR-like antigens and secretory component (SC) in jejunal epithelium of patients with coeliac disease or dermatitis herpetiformis. *Clin Exp Immunol* 1981;44:233-8.
  - 28 Johnson JP, Stade BG, Holzmann B, Schwable W, Reithmuller G. De novo expression of intercellular adhesion molecule in melanoma correlated with increased risk of metastasis. *Proc Natl Acad Sci USA* 1989;86:641-4.
  - 29 Maio M, Gulwani B, Langer A, Kerbel RS, Duigou GJ, Fisher PB, et al. Modulation by interferons of HLA antigen, high molecular weight melanoma-associated antigens and intercellular adhesion molecule 1 expression by cultured melanoma cells with different metastatic potential. *Cancer Res* 1990;49:2980-7.
  - 30 Natali P, Nicotra MR, Caviere R, Biotti A, Romano G, Temponi M, et al. Differential expression of intercellular adhesion molecule-1 in primary and metastatic melanoma lesions. *Cancer Res* 1990;50:1271-8.
  - 31 Vogetseder W, Feichtinger H, Schulz TF, Schwaeble W, Tabaczewski P, Mitterer M, et al. Expression of 7F7-antigen, a human adhesion molecule identical to intercellular adhesion molecule 1 (ICAM-1) in human carcinomas and their stromal fibroblasts. *Int J Cancer* 1989;43:768-73.