

## Entrapment neuropathies in diabetes mellitus

Eugenia Rota, Nicola Morelli

Eugenia Rota, Nicola Morelli, Department of Neurology, Ospedale G. da Saliceto, 29121 Piacenza, Italy

**Author contributions:** Rota E performed the majority of the writing; Morelli N made a substantive intellectual contribution, performing a critical revision of the content of the review and preparing the figure and table.

**Conflict-of-interest statement:** There is no conflict of interest associated with the author or the coauthor.

**Open-Access:** This article is an open-access article which was selected by an in-house editor and fully peer-reviewed by external reviewers. It is distributed in accordance with the Creative Commons Attribution Non Commercial (CC BY-NC 4.0) license, which permits others to distribute, remix, adapt, build upon this work non-commercially, and license their derivative works on different terms, provided the original work is properly cited and the use is non-commercial. See: <http://creativecommons.org/licenses/by-nc/4.0/>

**Manuscript source:** Invited manuscript

**Correspondence to:** Eugenia Rota, MD, Department of Neurology, Ospedale G. da Saliceto, Via Taverna 49, 29121 Piacenza, Italy. [eugenia.rota.md@gmail.com](mailto:eugenia.rota.md@gmail.com)  
Telephone: +39-0523-303310  
Fax: +39-0523-303322

Received: March 25, 2016

Peer-review started: March 26, 2016

First decision: May 13, 2016

Revised: July 9, 2016

Accepted: July 20, 2016

Article in press: July 22, 2016

Published online: September 15, 2016

### Abstract

Neuropathy is a common complication of diabetes mellitus (DM) with a wide clinical spectrum that encompasses generalized to focal and multifocal forms. Entrapment neuropathies (EN), which are focal forms, are so frequent at any stage of the diabetic disease, that they may be considered a neurophysiological hallmark

of peripheral nerve involvement in DM. Indeed, EN may be the earliest neurophysiological abnormalities in DM, particularly in the upper limbs, even in the absence of a generalized polyneuropathy, or it may be superimposed on a generalized diabetic neuropathy. This remarkable frequency of EN in diabetes is underlain by a peculiar pathophysiological background. Due to the metabolic alterations consequent to abnormal glucose metabolism, the peripheral nerves show both functional impairment and structural changes, even in the preclinical stage, making them more prone to entrapment in anatomically constrained channels. This review discusses the most common and relevant EN encountered in diabetic patient in their epidemiological, pathophysiological and diagnostic features.

**Key words:** Diabetes mellitus; Neuropathy; Diabetic neuropathy; Median entrapment neuropathy at the wrist; Ulnar entrapment neuropathy at the elbow; Ulnar entrapment neuropathy at the wrist; Carpal tunnel syndrome; Electrodiagnosis; Tarsal tunnel syndrome

© **The Author(s) 2016.** Published by Baishideng Publishing Group Inc. All rights reserved.

**Core tip:** Diabetic neuropathy syndromes include both generalized and focal/multifocal forms. Entrapment neuropathies (EN) are remarkably frequent in the focal forms and may be the earliest neurophysiological abnormalities in diabetes, even in the absence of a generalized polyneuropathy. Based on a pathophysiological hypothesis, diabetic patients' peripheral nerves, damaged by the altered glucose metabolism, show both functional impairment and structural changes. This makes them more susceptible to chronic compression in anatomically constrained channels. Therefore, EN may be considered a neurophysiological hallmark of peripheral nerve involvement in diabetes mellitus.

Rota E, Morelli N. Entrapment neuropathies in diabetes mellitus. *World J Diabetes* 2016; 7(17): 342-353 Available from: URL:

http://www.wjgnet.com/1948-9358/full/v7/i17/342.htm DOI:  
http://dx.doi.org/10.4239/wjd.v7.i17.342

## INTRODUCTION

Neuropathy is a major complication of diabetes mellitus (DM) and is as common as protean. Moreover, it not only leads to an impaired quality of life, but also to an increased morbidity and mortality<sup>[1]</sup>. Diabetic neuropathy (DN) is the most common form of neuropathy in Western countries, with a wide prevalence in literature, ranging from 5% to 90%<sup>[2,3]</sup>. Such a large discrepancy is mainly due to the different methods, *i.e.*, sets of electrophysiological and clinical criteria and demographic data adopted<sup>[4]</sup>. The EURODIAB IDDM Complication Study reports a 28% prevalence of DN across Europe<sup>[4]</sup>. Considering that DM affects about 246 million people worldwide, it can be estimated that 20-30 million people have a DN<sup>[5]</sup>.

There are numerous and heterogeneous neuropathic syndromes associated with DM. Indeed, the Toronto Diabetic Neuropathy Expert Group<sup>[1,6]</sup> updated the classification of DNs, providing definitions, minimal criteria for diagnoses and severity estimations. The Toronto Consensus Panels on DN<sup>[1,6]</sup> accepted Thomas<sup>[7]</sup> and Boulton *et al.*<sup>[8]</sup>'s separation of DNs into generalized and focal/multifocal neuropathies (Table 1).

Generalized DNs can be further classified into at least two major subgroups, *i.e.*, typical and atypical<sup>[1,6]</sup>. The most common generalized DN is the typical symmetric sensorimotor polyneuropathy, which is known to be length-dependent<sup>[9]</sup>. The atypical forms of generalized DN are usually intercurrent, painful varieties and can develop acutely at any time during the course of a patient's disease<sup>[10]</sup>.

### **Focal and multifocal neuropathies in DM: Entrapment syndromes vs mononeurites/multiple mononeuropathies**

The focal and multifocal neuropathies associated with DM can be broadly subdivided into two categories<sup>[6]</sup>, which are characterized by different clinical features and underpinned by various pathophysiological backgrounds. Entrapment of the nerve, favoured by chronic compression, is the pivotal causative factor in the first group: This includes median neuropathy at the wrist (MNW), ulnar neuropathy at the elbow (UNE) and peroneal neuropathy at the knee<sup>[6]</sup>. The second group encompasses cranial mononeuropathies or mononeurites, multiple mononeuropathies and thoracic, cervical and, most frequently, lumbosacral radiculoplexus neuropathies. The latter is also known as diabetic amyotrophy or Bruns Garland syndrome, where the pathophysiology involves inflammatory factors, microvasculitis and ischemia<sup>[11-13]</sup>. The 3<sup>rd</sup> and 6<sup>th</sup> are the most commonly affected cranial nerves, whilst the 7<sup>th</sup> is more rarely involved. Some pathological studies have demonstrated a centro-fascicular lesion in the

**Table 1 Diabetic neuropathies classification (according to Dyck *et al.*<sup>[6]</sup>, on behalf of the Toronto Expert Panel on Diabetic Neuropathy, 2011)**

Diabetic neuropathies	
Generalized	Typical (symmetrical, length-dependent, sensorimotor neuropathy) Atypical (painful varieties)
Focal/multifocal	Multiple mononeuropathy Entrapment neuropathy Lumbosacral/thoracic/cervical radiculoplexus neuropathy

intracavernous portion of the 3<sup>rd</sup> cranial nerve, sparing the peripheral fibres (and, consequently, the pupillary reaction), attributable to ischemic damage<sup>[5,14]</sup>.

The two groups, *i.e.*, entrapment neuropathies (EN) and mononeuropathies/multiple mononeuropathies, have different clinical characteristics<sup>[15]</sup>. Indeed, mononeurites or multiple mononeuropathies usually have an acute onset, where pain is a common feature, and a self-limiting clinical course within a 6-mo period, even if forms like diabetic amyotrophy may be highly disabling. On the other hand, EN have a gradual onset, a slow progression and persist without intervention<sup>[15]</sup>.

### **EN: General epidemiological remarks**

EN are remarkably common in DM<sup>[15,16]</sup> at any stage and may be asymptomatic. Therefore, patients with signs and symptoms suggestive of an entrapment should be thoroughly investigated, as surgery may be indicated<sup>[15]</sup>.

A study by Stamboulis *et al.*<sup>[17]</sup> aimed at establishing whether symptomatic mononeuropathies are more frequent in diabetic patients without symptoms of polyneuropathy than in the general population. A large cohort of 642 consecutive outpatients with various acute symptomatic mononeuropathies (radial, ulnar or peroneal neuropathy, Bell's palsy or median neuropathy at the carpal tunnel) were screened for the presence of DM. The results showed that in 522/642 patients with symptomatic carpal tunnel syndrome (CTS) and in 38/522 with Bell's palsy, DM frequency (7.7% and 10.5%, respectively) did not differ significantly from that expected in the general population<sup>[17]</sup>. Conversely, the respective DM rates (27.8%, 12.2% and 30.4%) were significantly higher than in the general population in 18 patients with radial neuropathy at (or distally to) the spiral groove<sup>[17]</sup>. The same finding was observed in 41 patients with ulnar neuropathy and in 23 patients with peroneal neuropathy at the fibular head<sup>[17]</sup>. This suggests that diabetic patients are more prone to focal limb neuropathies caused by acute external compression. However, this study focused on acute symptomatic mononeuropathies, whilst the majority of EN in DM are chronic and often asymptomatic.

Some cross-sectional and population studies reported a high prevalence of both symptomatic and asymptomatic MNW and ulnar nerve entrapments, with an increased lifetime risk for CTS, compared to the general

population. Herein, we should only like to emphasize that the presence of MNW was detected in 28% of DM patients at diagnosis<sup>[18]</sup> and that this proportion rose to 62.5% in patients with an average disease duration of 14.5 years<sup>[19]</sup>. This finding seems to confirm an association between EN, previously reported as not being age-dependent<sup>[20]</sup>, and longer disease duration. Furthermore, subclinical UNE was electro-diagnosed in a remarkably high percentage, *i.e.*, 34%, of DM patients<sup>[19]</sup>, suggesting that the ulnar nerve is very susceptible to focal entrapment in DM, as is the median nerve. These findings and others (see CTS and ulnar entrapments), suggest that EN in DM, mostly at the upper limbs, are not late complications, but rather early neurophysiological abnormalities, where the frequency increases with the disease duration and/or in the presence of generalized DN.

## THE PATHOPHYSIOLOGY OF EN: OLD AND NEW EVIDENCE

Epidemiological findings suggest that peripheral nerves are strikingly susceptible to focal entrapment in the presence of DM. Such a liability to chronic compression in DM may be attributable to metabolic factors and endoneurial ischemia, which damage the nerves already in the long preclinical stage<sup>[21]</sup>, as was first proven in animal models<sup>[22]</sup>. Therefore, a focal EN may be the first and, at times, only manifestation of a peripheral nerve involvement not only in DM, but also in prediabetes.

Growing evidence has shown that, on the one hand, impaired glucose tolerance may cause peripheral neuropathy itself and, on the other, abnormal glucose metabolism underlies a relevant proportion of apparently "idiopathic" sensory neuropathies<sup>[23-25]</sup>. The effects of sustained impaired glucose tolerance and progressive insulinopenia, also in the absence of hyperglycemia, were studied in an animal model (Goto-Kakizaki rat), which showed a functional and structural neuropathy associated with impaired NGF support and neuropeptide synthesis<sup>[26]</sup>. Indeed, insulin deficiency has been proven to be a pivotal pathogenetic factor in DN, owing to its unique trophic properties that act on sensory neuron and axon receptors<sup>[27]</sup>. Not only has it been shown that abnormal direct neuronal insulin signaling contributes to neuro-degeneration, but studies are ongoing on other important molecular factors that influence neuronal and axon growth, such as PTEN (phosphatase and tensin homolog deleted on chromosome 10)<sup>[28]</sup>.

On the other hand, observational studies have reported an increased prevalence of impaired glucose tolerance (up to 34%) in subjects with painful sensory neuropathy<sup>[23,24]</sup>. In another study, where patients with peripheral neuropathy of unknown origin were administered Oral Glucose Tolerance Test, 56% had abnormal results. Moreover, patients with impaired glucose tolerance had predominantly small fibre neuropathy, compared to those with overt DM, who

showed more prominent involvement of large fibres<sup>[25]</sup>. Hence, some kind of a "continuum" of peripheral nerve damage, associated with glucose dysmetabolism, may be hypothesized. A subtle impairment of nerve function, which begins in the preclinical stage of DM and progresses into the more advanced stages of the disease, is involved in this dysmetabolism, where sustained hyperglycemia alters biochemical pathways in the neurons, making the nerves more susceptible to entrapment.

There is clear evidence of the pathogenetic role the activated polyol pathway plays in diabetic nerves. Both the neurons and Schwann cells of patients with chronic hyperglycemia undergo a shift from the physiologic conversion of glucose into glucose-6-phosphate by hexokinase into an alternative pathway, where excess glucose is transformed into sorbitol by the aldose-reductase. Sorbitol, due to its low plasma membrane permeability, may act as an osmotic driver and, consequently, promote axonal and nerve trunk swelling in DM<sup>[29]</sup>. Moreover, the activated polyol pathway may induce a decrease in Na/K ATPase activity, leading to intra-axonal Na accumulation and a reduced Na gradient across the plasmatic membrane<sup>[30]</sup>.

Prolonged hyperglycemia may also enhance oxidative stress as radical scavengers are recharged too slowly to counterbalance the higher activity of the electron transport chain induced by the glucose overload<sup>[29]</sup>. The nerve axons, which are rich in mitochondria, are particularly vulnerable to oxidative damage in DM. Such a "double cellular crisis" of energy failure and oxidative damage has also been proven in Schwann cells<sup>[31]</sup>.

Furthermore, neurodegeneration may also be promoted by advanced glycation end products, which accumulate due to the non-enzymatic glycosylation of proteins and may even damage the function of pericytes and impair the nerve vascular supply<sup>[29]</sup>. A study on an animal model also led to the hypothesis that endoneurium and perineurium metabolic and phenotypic abnormalities may be underlying causal factors in the high sensitivity of diabetic nerves to entrapment<sup>[32]</sup>.

### **The "double crush" hypothesis revisited**

All these metabolic alterations lead to both functional impairment and structural changes, mainly swelling, in the nerves, making them more prone to entrapment in anatomically constrained channels<sup>[33]</sup>. In other words, there is a sort of "two hit" model. The glucose derangement hits the peripheral nerve first, which then becomes more susceptible to a second "hit", by the local factors related to entrapment, such as increased pressure, strain and/or elongation in the anatomically narrow sites. This may well be in agreement with Upton's "double crush hypothesis". In 1973, Drs. Upton and McComas<sup>[34]</sup> hypothesized in the journal *Lancet* that, if non-symptomatic impairment of axoplasmic flow occurs at more than one site along a nerve, it might well sum-up to cause a symptomatic neuropathy<sup>[33,35]</sup>. This

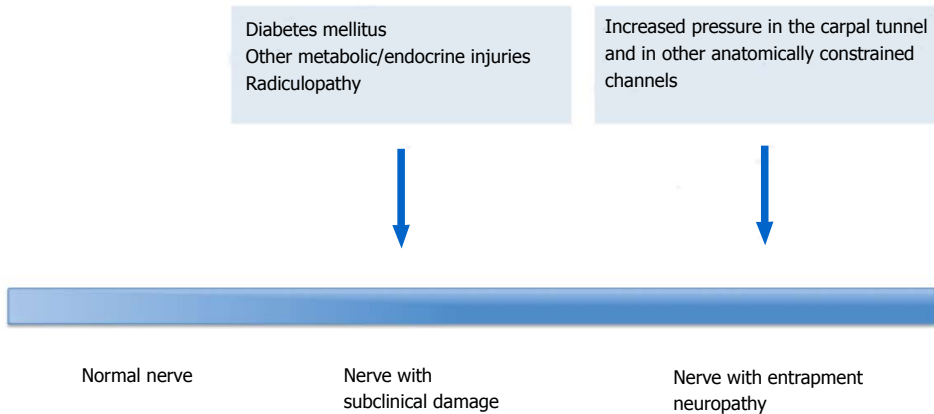


Figure 1 The “Double Crush” hypothesis revisited.

hypothesis relied on the clinical observation that most patients observed by the authors had an MNW, which was often bilateral, or an ulnar neuropathy, associated with cervical radiculopathy. Drs. Upton and McComas<sup>[34]</sup> supposed that axoplasmic flow could also be impaired by the metabolic damage, based on the frequent association between DM and CTS. Hence, in a revisited and extended “double crush hypothesis” (Figure 1), not only proximal nerve impingement, but also metabolic dysfunction and nerve swelling subsequent to DN, may be involved in the “first crush”. This predisposes nerves to chronic compression, *i.e.*, the “second crush”, in anatomically constrained sites, like carpal and/or tarsal tunnels<sup>[15]</sup>.

This mechanism seems to be consistent with the frequent association of both generalized and focal DN, where an EN is superimposed on a generalized form of DN. Indeed, the metabolic derangement and the microvessel alterations, subsequent to chronic hyperglycemia, lead to exhaustion of the ATP supply and an earlier fibre dissolution in the distal nerve compartment<sup>[36]</sup>. This may be in line with the well-known dying-back pathophysiological mechanisms that underlie generalized typical, symmetrical, length-dependent diabetic neuropathy. However, the same subclinical damage to distal nerve segments and the early demyelination of small sensory fibres may be taken into account when interpreting a slow conduction velocity and/or conduction blocks across the carpal tunnel, in the distal median nerve in MNW, which is often the earliest EN.

#### **Diabetic neuropathy: Axonal or demyelinating?**

The question thus arises whether the nature of DN is axonal or demyelinating. The results of a study aimed at answering this question<sup>[37]</sup> suggested that both mechanisms are involved. Demyelination seems to appear earlier in diabetic patients with or without symptoms of polyneuropathy, whilst axonal loss seems prevalent in more advanced DN, where it may be responsible for most of the symptoms. Moreover, the abnormal conduction velocity in the distal segment of the

sural nerve, observed by Cappellari *et al.*<sup>[38]</sup> in impaired glucose tolerance subjects without clinical neuropathy, also suggests that the myelin dysfunction of the distal sensory fibres represents the earliest detectable nerve response to hyperglycemia. Furthermore, a peculiar pattern of “abnormal median or ulnar/normal sural”, *i.e.*, reduced sensory action potential of median or ulnar nerve in the presence of normal sensory action potential of sural nerve, was detected in 82% and 80% respectively of newly diagnosed diabetic patients<sup>[18]</sup>. Such a peculiar pattern was found in a high proportion of patients with acute inflammatory polyneuropathy and was thus considered suggestive of an early distal nerve involvement<sup>[39]</sup>. Hence, if the small myelinated nerve fibres may be assumed to be the most susceptible to entrapment, this may explain the finding of median neuropathy in a very distal segment of the nerve across the carpal tunnel, as the earliest neurophysiological alteration in patients with abnormal glucose metabolism (impaired glucose tolerance and DM). This is observed even in the absence of an overt DN. On the other hand, demyelination has been described as the first human nerve response to chronic compression in the pioneering studies carried out by Dellon *et al.*<sup>[22]</sup> and Mackinnon *et al.*<sup>[40]</sup>, who detected markedly thinner myelin after compressive injuries. A Schwann cell proliferation, accompanied by increased apoptosis, has also been observed in animal models some weeks after compression<sup>[41]</sup>. These and other experimental findings reviewed by Tapadia *et al.*<sup>[41]</sup>, suggest that myelinated neurons may be particularly susceptible to mechanical stress, a pivotal factor in EN. Therefore, in the presence of a DN the peripheral nerves, that are already suffering from endoneurial ischemia and altered axonal excitability, are made more vulnerable to pressure.

This may lead, on the one hand, to an induction of demyelination and, on the other, cause local vascular impairment and superimposed axonal damage in anatomical tunnels<sup>[42]</sup>. This seems to imply that, in EN, once an entrapment has occurred, the chronic compression may enhance the pre-existing nerve metabolic damage within a sort of vicious circle, leading to

worsening, unless surgery is performed. Furthermore, regeneration is impaired in DM patients. Indeed, the microangiopathic changes in small vessels, the metabolic derangement of neurons and Schwann cells, defects in the inflammatory cells within the injury milieu and lack of trophic factors, may contribute to the failure of regenerative programmes<sup>[43]</sup>.

### **EN: Often asymptomatic**

Another peculiar finding of EN in DM deserves mention. It is well known that DN are often asymptomatic. Indeed EN, mainly MNE and UNE, may frequently occur as subclinical neurophysiological alterations, in the absence of clinical symptoms, as demonstrated by some studies<sup>[18,19,44,45]</sup>. MNW was asymptomatic in 36% of the patients in a cohort of some newly diagnosed DM patients<sup>[18]</sup>, similar to that obtained by Celiker *et al.*<sup>[44]</sup>. This suggests that the presence of lesions in the proximal nerve segment and/or an alteration of the threshold of the sensory nerve fibres may render patients with DN less prone to develop a clinically evident CTS than normal controls<sup>[18,20,44,45]</sup>.

---

## **EN DIAGNOSIS: GENERAL**

### **METHODOLOGICAL ASPECTS**

Electro-diagnostic studies are the mainstay in the diagnostic work-up of EN. Sensory and motor conduction studies provide an array of documentation on neuropathy. They distinguish the generalized forms from focal forms and show focal neurophysiologic abnormalities in anatomically constrained channels along the suspected nerve. Moreover, electrodiagnostic studies allow for the demonstration of the axonal or demyelinating features of the neuropathy, the staging of its severity and, last but not least, the exclusion of other concomitant diseases. One remarkable characteristic of electromyography is that it is able to detect a superimposed radiculopathy (such as a cervical C7-C8 radiculopathy concomitant with CTS) in the aforementioned "double crush" syndrome<sup>[34]</sup>.

There is growing evidence in favour of the use of imaging techniques as ancillary or complementary methods in the diagnostic process of neuropathies, above all for EN. Ultrasonography has been proven to offer several advantages in assessing peripheral nerves, including its cost-effectiveness, time-efficient evaluation of long nerve segments, ability to perform dynamic maneuvers, lack of contraindications, portability and non-invasiveness<sup>[46]</sup>. The last decade has witnessed an extensive use of neuromuscular ultrasonography, particularly in the assessment of EN, where the most common and reproducible sonographic finding is nerve enlargement, just proximal to the site of entrapment<sup>[47]</sup>. This enlargement is typically fusiform, rather than discretely focal, and is usually measured by the nerve cross-sectional area. Although the cause of nerve enlargement has not yet been completely clarified, it

has been hypothesized to be the result of axoplasmic damming, as observed in entrapment and chronic nerve compression models<sup>[47]</sup>. Moreover, inflammatory and/or vascular components may contribute to nerve enlargement. Along with nerve enlargement, just proximal to the site of entrapment, other less common findings have been reported and include hypoechoic nerve echo-texture, nerve flattening and pinching at the entrapment site, enlargement of single or multiple fascicles and/or increased vascularity within the nerve<sup>[47]</sup>. A recent study<sup>[48]</sup> was carried out to identify ultrasound findings in type II DM patients complaining of neuropathic symptoms and signs. Nerve ultrasound revealed an increased cross-sectional area in the peripheral nerves both at compression sites, even in the absence of clinical symptoms, and at non-compression sites. The authors hypothesize that cross-sectional area enlargement at compression sites indicates subclinical nerve damage and probably susceptibility to entrapment. Whilst cross-sectional area increase at non-compression sites suggests early morphological abnormalities, even when nerve conduction studies are unremarkable<sup>[48]</sup>. However, further studies should be carried out to confirm these results and to identify any correlations between ultrasonographic and electrodiagnostic findings.

The current role of magnetic resonance imaging (MRI) neurography in diabetic neuropathy is mainly that of excluding the presence of a lesion as the cause of nerve entrapment in cases of focal or regionally distributed multifocal neuropathy, mostly when clinical and electrodiagnostic findings are inconclusive. Furthermore, MRI neurography can diagnose those extra-neural affections that mimic neuropathic symptoms, such as Charcot arthropathy, osteomyelitis, plantar fasciitis, *etc.*<sup>[49]</sup>.

---

## **MEDIAN ENTRAPMENT NEUROPATHY AT THE WRIST AND CARPAL TUNNEL SYNDROME**

Median nerve entrapment neuropathy at the wrist (MNW) is the prototype of EN and is caused by the compression and traction of the median nerve within the carpal tunnel, an osteofibrous outlet located between the transverse carpal ligament and the carpal bones. It may be asymptomatic or accompanied by sensory complaints (pain, numbness, paraesthesias) or motor symptoms (weakness, clumsiness) in the section of the hand supplied by the median nerve. CTS is the commonest median neuropathy, with a 10% lifetime risk in the general population<sup>[50]</sup>. Prevalence rates vary widely across studies, depending on various factors, such as the geographic area, age, anthropometric data, exposure to risk factors for CTS and the diagnostic criteria used. Recently, a CTS prevalence of 2.3% to 4.3% has been reported in two large cohorts of French workers<sup>[51]</sup>. Some studies<sup>[18-20,42,52]</sup> report the prevalence

of both MNW and CTS to be several-fold higher in DM patients than in the general population, above all in DM patients with polyneuropathy and/or long disease duration. CTS has been detected in 14% of diabetic subjects without polyneuropathy and in 30% of subjects with polyneuropathy<sup>[42]</sup>. Moreover, an MNW was found in 28% of newly diagnosed DM patients, compared to 62.5% of patients with an average disease duration of 14.5 years<sup>[18,19]</sup>. Similar results were reported in another study carried out on 146 DM patients, where CTS was diagnosed in 39% of the sample, 28% of males and 46% of females<sup>[53]</sup>. The risk of hand syndromes, including CTS, stenosing flexor tenosynovitis and Dupuytren disease, was evaluated in a population-based cohort study (606152 diabetic patients and 609970 matched for age and gender)<sup>[54]</sup>, where the hazard ratio for CTS was: 1.31 (95%CI: 1.28-1.34) in DM patients. In the longitudinal Fremantle Diabetes Study, aimed at determining the incidence and predictors of carpal tunnel decompression in 1284 DM patients, the incidence of CTS was 5.5 cases per 1000 patient-year, at least 4.2-fold that of the general population<sup>[52]</sup>. In a previous review, aimed at evidencing any increase in the prevalence of specific conditions in CTS patients, a two-fold increased risk (OR = 2.2; 95%CI: 1.5-3.1) for DM was detected<sup>[55]</sup>. Therefore, DM is an independent risk factor for CTS<sup>[55]</sup>. A surprisingly high lifetime risk of CTS has been reported in type 1 DM patients, where it may rise to 85% after 54 disease years<sup>[56]</sup>.

A case-control Italian study<sup>[57]</sup> reported that, not only overt DM, but also abnormal glucose metabolism was present in a high percentage of the subjects with idiopathic CTS. This finding led the authors to propose insulin resistance screening for all patients with CTS, as they found insulin resistance in 80% of patients: 45% had impaired glucose tolerance, 14% newly diagnosed DM and 20% insulin resistance only<sup>[57]</sup>.

The dominant hand is the most commonly affected in CTS, with a prevalence for females, where the tunnel tends to be smaller, and in obese DM patients<sup>[53,58]</sup>.

Such a strong association between MNW/CTS and DM is underpinned by the fact that DM nerves are very prone to compression due to metabolic and vascular factors occurring in a DM already in the prediabetic stage. Indeed, increased pressure in the carpal tunnel, which rises up to 8-10-fold in the flexion/extension movements of the wrist, and nerve traction may reduce the intra-neural microcirculation, damage the myelin sheath and the axonal function, as well as the connective structures, in a vicious circle where the nerve swelling, due to oedema and hypoxia, are a pivotal aggravating factor in the pathophysiology of CTS<sup>[59]</sup> (Figure 2).

Median nerve entrapment in the carpal tunnel with neural mobilization during anatomical stress may lead to conduction failure also in the non-diabetic population. This has recently been demonstrated by a study where recruitment properties of the median nerve were studied by the stimulus-response curve before and after intermittent-repetitive neural mobilization,

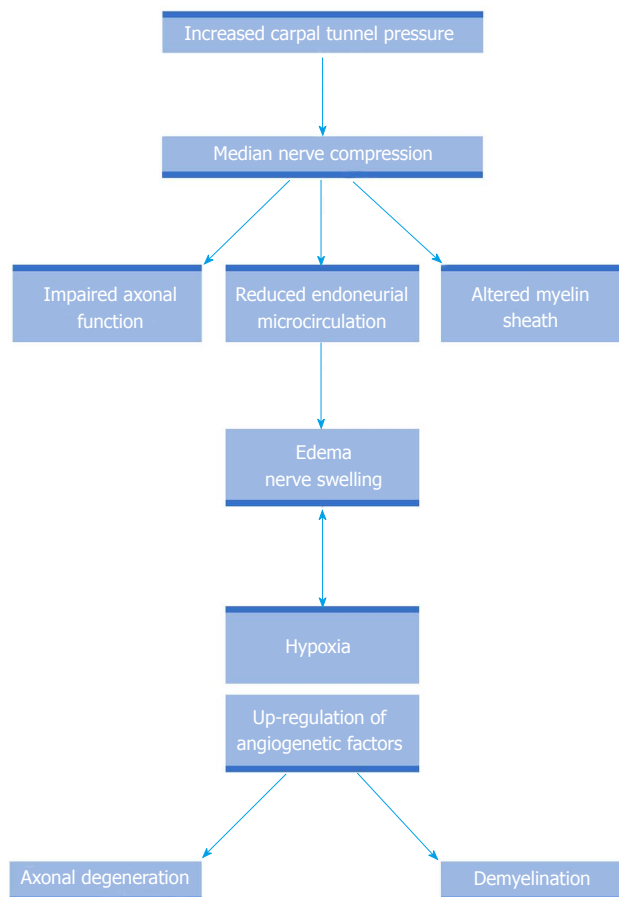


Figure 2 Carpal tunnel pathophysiology (modified from Aboonq<sup>[59]</sup>, 2015).

in subjects with and without CTS<sup>[60]</sup>. Only subjects with CTS exhibited a strikingly abnormal stimulus-response curve. This finding suggests that compressive forces may alter energy-dependent processes during anatomical stress in elongation, leading to conduction block in axons<sup>[60]</sup>. Taken as a whole, these findings do seem to imply that once an entrapment has occurred in MNW/CTS, anatomical stress may enhance the pre-existing metabolic and ischemic nerve damage within a sort of vicious circle, leading to axonal degeneration and to a worsening of the entrapment, unless surgery is performed.

When the severity of an electrophysiologically confirmed CTS was compared between patients with DM (and no concomitant metabolic syndrome) and patients with metabolic syndrome, it was observed to be more severe in those with a metabolic syndrome<sup>[61]</sup>. This finding suggests the presence of other disease modifying factors related to the metabolic syndrome.

Nerve conduction studies are the mainstay in the diagnostic approach to the MNW and CTS. Although quantitative sensory testing for the different modalities (temperature, pain, vibration perception threshold, perception testing) may be more sensitive than standard clinical tests<sup>[62]</sup>, it has considerable subjective components making it unreliable for diagnosis<sup>[15,63]</sup>.

Electrophysiological studies, that measure median nerve sensory and motor conduction parameters, not

only allow for a diagnosis of MNW, but also the staging of its severity, as they may detect focal abnormalities within the carpal tunnel itself. The techniques for an electrodiagnosis of CTS were described and assessed by Werner *et al.*<sup>[64]</sup>, in an American Association of Neuromuscular and Electrodiagnostic Medicine monograph. The sensory response is particularly useful to diagnose CTS, as sensory fibres have a larger proportion of large myelinated fibres, with a higher energy requirement, that are more susceptible to ischemic and metabolic damage. Comparison of the median nerve sensory latency with ulnar or radial latency has been demonstrated to be more effective than the use of absolute median nerve latency in documenting the median nerve entrapment within the carpal tunnel<sup>[64]</sup>.

An electrodiagnosis of CTS may be particularly challenging in DM patients with a polyneuropathy, where the comparative tests between the ulnar and radial nerve may necessitate that the values be adjusted from those used in the general population to more conservative cut-off values<sup>[64]</sup>. Moreover, segmental and comparative median nerve conduction tests (the disto-proximal latency ratio) showed a high sensitivity of 90% in DM patients affected by polyneuropathy, which is similar to that of the median-ulnar sensory latency to digit 4 comparison<sup>[65]</sup>.

The measures needed to achieve a minimum standard of care for the use of electrodiagnostic testing in the suspicion of a CTS have been defined according to the guidelines developed by the American Association of Neuromuscular and Electrodiagnostic Medicine<sup>[66]</sup>.

MNW is the entrapment neuropathy most frequently studied with ultrasonography. Enlargement of the median nerve cross-sectional area at the distal wrist crease is an accurate parameter for the diagnosis of CTS, with a sensitivity and specificity of > 85% in several studies<sup>[47]</sup>. The median nerve has a lower mobility in patients affected by CTS than healthy controls and this decreased range of movement can be quantified in both lateral and distal-proximal planes, according to set grading scales<sup>[47]</sup>. A recent study<sup>[67]</sup> suggests that ultrasonography be used to make a differential diagnosis between EN and diabetic neuropathy in DM patients. There was a wider median nerve cross-sectional area in DM patients with polyneuropathy than in controls, in particular in the CTS subgroup, where there was a larger cross-sectional area at the wrist and wrist-to-forearm<sup>[67]</sup>.

The treatment of CTS is mainly surgical, aimed at decompression of the median nerve by sectioning the carpal transverse ligament. Surgical nerve release can be done either by an open approach (OCTR) or endoscopically (ECTR). Although the two approaches differ only slightly as to pain relief and improvement of functional status, there may be a functionally significant benefit of ECTR over OCTR in improving grip strength<sup>[68]</sup>. Several non-surgical approaches, including oral steroids, splinting, ultrasound, yoga and carpal bone mobilization, have been suggested for patients with mild-moderate symptoms, with significant short-term benefit, although

long-term efficacy remains to be ascertained<sup>[69]</sup>. In the DM population, where the metabolic derangement may impair nerve regeneration<sup>[43]</sup>, the question arises whether the treatment, above all surgery, would maintain the same long-term efficacy as it does in the general population. Such a question has been addressed by some studies. The outcome of CTS surgical release was evaluated at one month and one year in DM patients and was observed to be inferior and slower than in non-diabetic controls<sup>[70]</sup>. Such a difference was attributed to metabolic factors and impaired nerve regeneration, which are likely to be responsible for the slower recovery in DM patients<sup>[70]</sup>. A worse surgical outcome was reported at 10 post-surgical years for DM patients with CTS, compared to idiopathic CTS patients<sup>[71]</sup>. However, another recent study was carried out on 35 patients and 31 normal controls with a 5-year follow-up. It reported that after surgical release of CTS, DM subjects had a long-term improvement in sensory, motor function and cold intolerance, comparable to that of non-diabetic controls<sup>[72]</sup>. Interestingly, the improvement in cold intolerance would be consistent with a potential for long-term regeneration of small fibers<sup>[72]</sup>. Thomsen *et al.*<sup>[73]</sup> also assessed the neurophysiologic recovery after carpal tunnel release in the same sample of DM patients, who had significantly impaired nerve conduction parameters, both before and after surgical carpal tunnel release, compared to non-diabetic patients. Nevertheless, neurophysiologic recovery after carpal tunnel surgery did not differ between the two patient groups or between diabetic patients, with or without peripheral neuropathy. Thus, relevant neurophysiologic impairment of the median nerve, or signs of peripheral neuropathy, is not likely to preclude significant recovery after carpal tunnel release in DM patients<sup>[73]</sup>. Even the quality of life, evaluated with generic and disease-specific questionnaires (SF-36 and Boston Carpal Tunnel Questionnaire, respectively), that was more impaired in DM CTS patients than in non-diabetic CTS subjects and the general population, had the same post-surgical scores for both DM and non-diabetic patients<sup>[74]</sup>. Therefore, the authors stated that DM patients should be given the same surgical option for CTS treatment as non-diabetic patients<sup>[73,74]</sup>.

---

## UNE AND ULNAR ENTRAPMENT NEUROPATHY AT THE WRIST (UNW)

---

The second most frequent entrapment neuropathy involves the UNE, in the retroepicondylar groove or under the humeroulnar aponeurotic arcade, *i.e.*, the cubital tunnel. A study by Mondelli *et al.*<sup>[75]</sup> investigated the UNE incidence in the general population, where there was a crude incidence of 24.7 per 100000 person-years and a standardized incidence of 20.9 per 100000 person-years. A prospective study<sup>[76]</sup> was carried out on a group of subjects with suspected UNE given electrodiagnostic and ultrasonographic examination.

It reported that the entrapment was localized in the retroepicondylar groove in 76% of the cases, where it was mainly demyelinating and at the humeroulnar aponeurotic arcade in 17%, where it was mostly axonal. UNE may occur without symptoms or be accompanied by painful paraesthesias in the fourth and/or fifth digit or by hypothenar or interosseus muscle weakness and wasting.

Clinical and neurophysiologic findings of a severe ulnar neuropathy were previously reported in a group of patients affected by DM with severe systemic complications<sup>[77]</sup>. Another four patients with type I DM and clinical findings suggestive of severe ulnar neuropathy have been described, where nerve conduction studies detected a partial conduction block or abnormal temporal dispersion within the forearm segment of the ulnar nerve, along with a mild underlying polyneuropathy<sup>[78]</sup>. The authors raised the question whether the UNE was due to an increased propensity to focal compression of the ulnar nerve within the humeroulnar arcade, or whether it represented a localized manifestation of the generalized polyneuropathy<sup>[78]</sup>. According to the advances made in DN pathophysiology, this seems to be only an apparent contradiction, in as much as, in reality, the metabolic derangement of diabetic nerves may underpin their remarkable liability to compression.

A more recent study<sup>[19]</sup> assessed the prevalence and electrophysiological features of ulnar entrapment neuropathy, according to the American Association of Electrodiagnostic Medicine protocol<sup>[79]</sup>. A cohort of 64 consecutive DM patients were studied and UNE was electrodiagnosed in 34% (18% were not polyneuropathic); UNW was detected in 11% of this sample<sup>[19]</sup>. On the basis of such a high proportion of patients (45%) with neurophysiological alterations consistent with ulnar EN at both sites (elbow and wrist), the authors concluded that the ulnar nerve, similarly to the median nerve, is very susceptible to focal entrapment in DM. Moreover, they suggested that upper limb sensory and motor NCS, including motor conduction velocity across the elbow, be routinely evaluated in the staging of DM patients<sup>[19]</sup>.

Furthermore, the frequent neurophysiological abnormalities detected on the ulnar nerve by this electrodiagnostic study<sup>[19]</sup> were mostly asymptomatic and only a small proportion of patients with a diagnosis of UNE showed the clinical signs of EN. This finding that UNE was mainly subclinical is in agreement with previous evidence related to MNW, which was asymptomatic in one third of DM patients<sup>[18,20,44,45]</sup>. It is also in line with the hypothesis that there is an alteration of the threshold of the sensory nerve fibres in DM and this may well explain the lower propensity for DN patients to develop a clinical symptomatology<sup>[18,20,44,45]</sup>.

Furthermore, in the same study<sup>[19]</sup>, UNW was concomitant with MNW in all but one case. Indeed, the question arises as to the association between UNW and MNW, where the discrepancy in literature is most likely to be due to the different methods adopted<sup>[80]</sup>.

Indeed, in DM patients, where the frequency of MNW is high, concomitant involvement of Guyon's canal (UNW) has been shown to reduce the sensitivity of the median-ulnar comparative studies<sup>[81]</sup>. Therefore, the neurophysiological diagnosis of concomitant CTS and UNW may present a challenge, above all in DN patients. A retrospective case-control study<sup>[82]</sup>, carried out on an electrodiagnostic database, included 1924 patients evaluated for CTS and 1024 DM patients investigated for CTS and/or polyneuropathy. A logistic regression analysis showed that the presence of CTS was associated with a two-fold risk of UNW in both idiopathic CTS and DM CTS groups. These findings suggest that the presence of concomitant UNW and CTS should be carefully pursued in nerve conduction studies, above all in DM patients.

A study by Mondelli *et al.*<sup>[75]</sup> compared the prevalence of DM in two consecutive samples of patients with UNE and CTS and reported that it was remarkably similar, *i.e.*, 6.0% and 6.6% respectively. Indeed, patients with UNE and DM were clinically and neurophysiologically indistinguishable from other UNE patients (both idiopathic and post-traumatic). The only difference was a smaller amplitude of the sensory response in the DM patients, which may well be attributable to the underlying axonal polyneuropathy<sup>[75]</sup>. These findings strengthen the similarities between median and ulnar EN in DM, which obviously act in the same way on peripheral nerves at both the upper and lower limbs, predisposing them to compression in anatomically narrow sites, where the nerves are exposed to increased pressure and repetitive strain.

## EN AT THE LOWER LIMBS

It seems that entrapments of the ulnar and median nerve are not only a typical electrophysiological feature of polyneuropathy in DM, but also the early subclinical sign of peripheral nerve damage, even when a generalized diabetic neuropathy is not yet evident. Whilst EN at the lower limbs seem to be less frequent feature of DM. Indeed, the evidence of an increased frequency of common peroneal nerve entrapment in DM at the level of the fibular head and of the tarsal tunnel syndrome is less overwhelming, compared to upper limb focal neuropathies.

In the past it was reported that DM was the underlying cause of peroneal neuropathy in only 5%-12% of patients<sup>[83]</sup>. However, a more recent study was carried out to determine whether peripheral neuropathy could explain the apparent association between DM and disability in ageing subjects. It reported that reduced peroneal motor response amplitude at multiple sites and weakness of foot dorsiflexion were found in two thirds of the sample of DN patients over 65<sup>[15,84]</sup>.

A similar impairment of peroneal nerve conduction parameters was observed in subjects 65 years or older in a study<sup>[85]</sup>, carried out to determine whether DM was associated with objective measures of physical and



peripheral function. It concluded that DM patients had a decreased conduction velocity and motor response amplitude at the lower limbs, along with a reduced walking speed, compared to the non-diabetic subjects<sup>[85]</sup>. However, if direct neurophysiological signs of entrapment, *e.g.*, conduction block or reduced motor conduction velocity across the fibular head, are not carefully searched for and detected, peroneal axonal damage may be consequent to DN itself or to an L5 radiculopathy or a lumbar spinal stenosis. These conditions may even be superimposed on DN, making for a complex differential diagnosis.

The diagnosis of tarsal tunnel syndrome is even more challenging, as it is characterized by entrapment of the tibialis nerve as it curves behind the medial malleolus underneath the flexor retinaculum. There may be a selective or prevailing entrapment of the medial or lateral plantar nerves, two of the terminal branches of tibial nerve, in a tarsal tunnel syndrome. Indeed, this is more difficult to demonstrate without the adoption of a complex electrodiagnostic protocol with segmental analysis of the motor conduction velocity in the distal tracts of the tibial nerve<sup>[86]</sup>. Such shortcomings in neurophysiological investigation protocols seem to be common to several studies on neuropathy at the lower limbs in DM, making them unreliable when investigating entrapment. Therefore, these methodological limits could be considered a plausible explanation for the less detailed evidence on entrapment in the lower limbs, than what is available for the upper extremities in the general population and even more so in DM patients. Indeed, similarities between CTS and tarsal tunnel syndrome might be expected as they have a common pathophysiological background that predisposes the nerves to external compression.

Surgical nerve release seems to find a rationale in the "revisited" Upton and McComas's "double crush" hypothesis (Figure 1)<sup>[15,34]</sup>, where DN (with nerve swelling) represents the "first crush" and nerve compression at the tarsal tunnel or peroneal head the "second crush"<sup>[87]</sup>, despite the often limited electrodiagnostic evidence for entrapment superimposed to the length-dependent DN. This hypothesis has received recent support by nerve ultrasonography that demonstrated an increased cross-sectional area in nerves affected by neuropathy<sup>[47]</sup>. Moreover, ultrasound imaging was used to quantify the magnitude and timing of tibial nerve excursion during ankle dorsiflexion in patients with DM and was compared to matched healthy controls<sup>[88]</sup>. The results showed that the nerve cross-sectional area was increased at the ankle in the DM group, where the tibial nerve longitudinal excursion at the ankle and knee was reduced proportionally to the severity of neuropathy. Moreover, on the basis that a larger tibial nerve size within the tarsal tunnel in patients with DM may restrict longitudinal excursion, it has been hypothesized that such altered tibial nerve biomechanics may be related to painful symptoms during functional activities<sup>[88]</sup>.

### **Surgical decompression of nerves at the lower limbs**

Several studies have been based on the "double crush" hypothesis (Figure 1), from the pioneering work by Dellon<sup>[89]</sup> to more recent studies<sup>[90,91]</sup>, which evaluated the efficacy of surgical decompression in DN patients. Considering Valdivia Valdivia *et al.*<sup>[90]</sup>'s retrospective review, the results of neurolysis on multiple sites of chronic nerve compression in the lower extremity were analyzed in 158 consecutive patients, 96 with DM and 62 with idiopathic neuropathy. A significant post-operative improvement was reported in sensation and balance at a minimum follow-up of 1 year; even pain improved, as demonstrated by a decrease in the Visual Analogic Scale score. There was no statically significant difference in outcomes between patients with DM vs idiopathic neuropathy in response to nerve decompression<sup>[90]</sup>. Another study by Liao *et al.*<sup>[91]</sup> investigated into the effect surgical decompression had on painful DN as to the pain distribution, where a total of 306 patients, with painful diabetic lower-extremity neuropathy were treated with Dellon surgical nerve decompression. Patients had pre- and post-surgical (were appropriate) clinical evaluation and high-resolution ultrasonography (cross-sectional area), as well as nerve conduction studies (tibial and common peroneal nerve conduction velocity). Surgical patients were retrospectively assigned into two subgroups, *i.e.*, focal and diffuse pain, according to the distribution of the diabetic neuropathic pain. The control group included 92 non-surgical patients with painful DN. After surgical decompression, the surgical group had a higher reduction in pain (measured as Visual Analogic Scale score) and an improvement in nerve conduction and cross-sectional area than did the control group. As was expected, based on the rationale on the surgical decompression approach, a greater improvement in Visual Analogic Scale and cross-sectional area was observed in the focal pain group than in the diffuse pain group. The authors concluded that decompression of multiple lower-extremity peripheral nerves was effective in patients with painful DN to a greater extent in patients with focal symptoms<sup>[91]</sup>.

However, unfortunately, these two studies show relevant methodological shortcomings. Firstly, there was no demonstration of a precise site of entrapment by direct electrodiagnostic signs along nerves, which showed only axonal damage subsequent to DN. Furthermore, serial measurements of nerve motor conduction velocities may show a variability<sup>[92]</sup> which was not taken into account in the post-surgical evaluation of the improved conduction velocity along tibial and common peroneal nerves. In addition, most of the outcome measures evaluated by these studies are subjective, making the definition of focal pain in the study of Liao *et al.*<sup>[91]</sup>, 2014 questionable. Therefore, we are of the opinion that further neurophysiological studies should be carried out in an effort to better characterize EN superimposed on DN at the lower limbs. Moreover, further prospective studies, based on detailed

electrodiagnostic and ultrasonographic protocols aimed at localizing the sites of nerve compression are welcome to better assess the efficacy of surgical nerve decompression in patients suffering from painful DN.

## CONCLUSION

EN are so common in DM, at any stage, that they may be considered a neurophysiological hallmark of peripheral nerve involvement in DM. Indeed, EN, particularly in the upper limbs, may represent the earliest neurophysiological abnormalities, which are often asymptomatic, even in the absence of a generalized polyneuropathy or, usually later in the natural history of DM, they may be superimposed on a generalized DN.

The remarkable frequency of EN in DM is underpinned by a peculiar pathophysiological background. The peripheral nerves, due to the metabolic alterations consequent to altered glucose metabolism, even in the preclinical stage, show both functional impairment and structural changes, mainly swelling, which makes them more prone to entrapment in anatomically constrained channels. The diagnosis of EN relies mainly on nerve conduction studies and may sometimes be challenging, mostly in DM patients with a generalized polyneuropathy. Despite this, we believe that an EN diagnosis is a must, not only for the staging of DM, but also due to the fact that the treatment of choice for numerous EN cases may have to be surgical.

## ACKNOWLEDGMENTS

The authors thank Barbara Wade for her linguistic advice.

## REFERENCES

- 1 **Tesfaye S**, Boulton AJ, Dyck PJ, Freeman R, Horowitz M, Kempler P, Lauria G, Malik RA, Spallone V, Vinik A, Bernardi L, Valensi P. Diabetic neuropathies: update on definitions, diagnostic criteria, estimation of severity, and treatments. *Diabetes Care* 2010; **33**: 2285-2293 [PMID: 20876709 DOI: 10.2337/dc10-1303]
- 2 **Dyck PJ**. Detection, characterization, and staging of polyneuropathy: assessed in diabetics. *Muscle Nerve* 1988; **11**: 21-32 [PMID: 3277049 DOI: 10.1002/mus.880110106]
- 3 **Vinik AI**, Park TS, Stansberry KB, Pittenger GL. Diabetic neuropathies. *Diabetologia* 2000; **43**: 957-973 [PMID: 10990072 DOI: 10.1007/s001250051477]
- 4 **Tesfaye S**, Stevens LK, Stephenson JM, Fuller JH, Plater M, Ionescu-Tirgoviste C, Nuber A, Pozza G, Ward JD. Prevalence of diabetic peripheral neuropathy and its relation to glycaemic control and potential risk factors: the EURODIAB IDDM Complications Study. *Diabetologia* 1996; **39**: 1377-1384 [PMID: 8933008 DOI: 10.1007/s001250050586]
- 5 **Said G**. Focal and multifocal diabetic neuropathies. *Arq Neuropsiquiatr* 2007; **65**: 1272-1278 [PMID: 18345446 DOI: 10.1590/S0004-282X2007000700037]
- 6 **Dyck PJ**, Albers JW, Andersen H, Arezzo JC, Biessels GJ, Bril V, Feldman EL, Litchy WJ, O'Brien PC, Russell JW; Toronto Expert Panel on Diabetic Neuropathy. Diabetic polyneuropathies: update on research definition, diagnostic criteria and estimation of severity. *Diabetes Metab Res Rev* 2011; **27**: 620-628 [PMID: 21695763 DOI: 10.1002/dmrr.1226]
- 7 **Thomas PK**. Classification, differential diagnosis, and staging of diabetic peripheral neuropathy. *Diabetes* 1997; **46** Suppl 2: S54-S57 [PMID: 9285500 DOI: 10.2337/diab.46.2.S54]
- 8 **Boulton AJ**, Vinik AI, Arezzo JC, Bril V, Feldman EL, Freeman R, Malik RA, Maser RE, Sosenko JM, Ziegler D. Diabetic neuropathies: a statement by the American Diabetes Association. *Diabetes Care* 2005; **28**: 956-962 [PMID: 15793206 DOI: 10.2337/diacare.28.4.956]
- 9 **Dyck PJ**, Karnes JL, O'Brien PC, Litchy WJ, Low PA, Melton LJ. The Rochester Diabetic Neuropathy Study: reassessment of tests and criteria for diagnosis and staged severity. *Neurology* 1992; **42**: 1164-1170 [PMID: 1603343 DOI: 10.1212/WNL.42.6.1164]
- 10 **Archer AG**, Watkins PJ, Thomas PK, Sharma AK, Payan J. The natural history of acute painful neuropathy in diabetes mellitus. *J Neurol Neurosurg Psychiatry* 1983; **46**: 491-499 [PMID: 6875582 DOI: 10.1136/jnnp.46.6.491]
- 11 **Raff MC**, Asbury AK. Ischemic mononeuropathy and mononeuropathy multiplex in diabetes mellitus. *N Engl J Med* 1968; **279**: 17-21 [PMID: 4297979 DOI: 10.1056/NEJM196807042790104]
- 12 **Chokroverty S**, Reyes MG, Rubino FA, Tonaki H. The syndrome of diabetic amyotrophy. *Ann Neurol* 1977; **2**: 181-194 [PMID: 215072 DOI: 10.1002/ana.410020303]
- 13 **Llewelyn JG**, Thomas PK, King RH. Epineurial microvasculitis in proximal diabetic neuropathy. *J Neurol* 1998; **245**: 159-165 [PMID: 9553846 DOI: 10.1007/s004150050197]
- 14 **Asbury AK**, Aldredge H, Hershberg R, Fisher CM. Oculomotor palsy in diabetes mellitus: a clinico-pathological study. *Brain* 1970; **93**: 555-566 [PMID: 5507015 DOI: 10.1093/brain/93.3.555]
- 15 **Vinik A**, Mehrabyan A, Colen L, Boulton A. Focal entrapment neuropathies in diabetes. *Diabetes Care* 2004; **27**: 1783-1788 [PMID: 15220266 DOI: 10.2337/diacare.27.7.1783]
- 16 **Knopp M**, Rajabally YA. Common and less common peripheral nerve disorders associated with diabetes. *Curr Diabetes Rev* 2012; **8**: 229-236 [PMID: 22283678 DOI: 10.2174/157339912800564034]
- 17 **Stamboulis E**, Vassilopoulos D, Kalfakis N. Symptomatic focal mononeuropathies in diabetic patients: increased or not? *J Neurol* 2005; **252**: 448-452 [PMID: 15726259 DOI: 10.1007/s00415-005-0672-8]
- 18 **Rota E**, Quadri R, Fanti E, Isoardo G, Poglio F, Tavella A, Paolasso I, Ciaramitaro P, Bergamasco B, Cocito D. Electrophysiological findings of peripheral neuropathy in newly diagnosed type II diabetes mellitus. *J Peripher Nerv Syst* 2005; **10**: 348-353 [PMID: 16279983 DOI: 10.1111/j.1085-9489.2005.00046.x]
- 19 **Rota E**, Zavaroni D, Parietti L, Iafelice I, De Mitri P, Terlizzi E, Morelli N, Immovilli P, Guidetti D. Ulnar entrapment neuropathy in patients with type 2 diabetes mellitus: an electrodiagnostic study. *Diabetes Res Clin Pract* 2014; **104**: 73-78 [PMID: 24565211 DOI: 10.1016/j.diabres.2014.01.024]
- 20 **Albers JW**, Brown MB, Sima AA, Greene DA. Frequency of median mononeuropathy in patients with mild diabetic neuropathy in the early diabetes intervention trial (EDIT). Tolrestat Study Group For Edit (Early Diabetes Intervention Trial) *Muscle Nerve* 1996; **19**: 140-146 [PMID: 8559161]
- 21 **Perkins BA**, Bril V. Diabetic neuropathy: a review emphasizing diagnostic methods. *Clin Neurophysiol* 2003; **114**: 1167-1175 [PMID: 12842711 DOI: 10.1016/S1388-2457(03)00025-7]
- 22 **Dellon AL**, Mackinnon SE, Seiler WA. Susceptibility of the diabetic nerve to chronic compression. *Ann Plast Surg* 1988; **20**: 117-119 [PMID: 3355055 DOI: 10.1097/0000637-198802000-00004]
- 23 **Novella SP**, Inzucchi SE, Goldstein JM. The frequency of undiagnosed diabetes and impaired glucose tolerance in patients with idiopathic sensory neuropathy. *Muscle Nerve* 2001; **24**: 1229-1231 [PMID: 11494278 DOI: 10.1002/mus.1137]
- 24 **Singleton JR**, Smith AG, Bromberg MB. Increased prevalence of impaired glucose tolerance in patients with painful sensory neuropathy. *Diabetes Care* 2001; **24**: 1448-1453 [PMID: 11473085 DOI: 10.2337/diacare.24.8.1448]
- 25 **Sumner CJ**, Sheth S, Griffin JW, Cornblath DR, Polydefkis M. The spectrum of neuropathy in diabetes and impaired glucose tolerance. *Neurology* 2003; **60**: 108-111 [PMID: 12525727 DOI: 10.1212/WNL.60.1.108]

- 26 **Murakawa Y**, Zhang W, Pierson CR, Brismar T, Ostenson CG, Efendic S, Sima AA. Impaired glucose tolerance and insulinopenia in the GK-rat causes peripheral neuropathy. *Diabetes Metab Res Rev* 2002; **18**: 473-483 [PMID: 12469361 DOI: 10.1002/dmrr.326]
- 27 **Guo G**, Kan M, Martinez JA, Zochodne DW. Local insulin and the rapid regrowth of diabetic epidermal axons. *Neurobiol Dis* 2011; **43**: 414-421 [PMID: 21530660 DOI: 10.1016/j.nbd.2011.04.012]
- 28 **Zochodne DW**. Diabetes and the plasticity of sensory neurons. *Neurosci Lett* 2015; **596**: 60-65 [PMID: 25445357 DOI: 10.1016/j.neulet.2014.11.017]
- 29 **Sessions J**, Nickerson DS. Biologic Basis of Nerve Decompression Surgery for Focal Entrapments in Diabetic Peripheral Neuropathy. *J Diabetes Sci Technol* 2014; **8**: 412-418 [PMID: 24876595 DOI: 10.1177/1932296814525030]
- 30 **Misawa S**, Kuwabara S, Ogawara K, Kitano Y, Yagui K, Hattori T. Hyperglycemia alters refractory periods in human diabetic neuropathy. *Clin Neurophysiol* 2004; **115**: 2525-2529 [PMID: 15465442 DOI: 10.1016/j.clinph.2004.06.008]
- 31 **Song Z**, Fu DT, Chan YS, Leung S, Chung SS, Chung SK. Transgenic mice overexpressing aldose reductase in Schwann cells show more severe nerve conduction velocity deficit and oxidative stress under hyperglycemic stress. *Mol Cell Neurosci* 2003; **23**: 638-647 [PMID: 12932443 DOI: 10.1016/S1044-7431(03)00096-4]
- 32 **Nishimura T**, Hirata H, Tsujii M, Iida R, Hoki Y, Iino T, Ogawa S, Uchida A. Pathomechanism of entrapment neuropathy in diabetic and nondiabetic rats reared in wire cages. *Histol Histopathol* 2008; **23**: 157-166 [PMID: 17999372]
- 33 **Nemoto K**, Matsumoto N, Tazaki K, Horiuchi Y, Uchinishi K, Mori Y. An experimental study on the "double crush" hypothesis. *J Hand Surg Am* 1987; **12**: 552-559 [PMID: 3611653 DOI: 10.1016/S0363-5023(87)80207-1]
- 34 **Upton AR**, McComas AJ. The double crush in nerve entrapment syndromes. *Lancet* 1973; **2**: 359-362 [PMID: 4124532 DOI: 10.1016/S0140-6736(73)93196-6]
- 35 **Zahir KS**, Zahir FS, Thomas JG, Dudrick SJ. The double-crush phenomenon--an unusual presentation and literature review. *Conn Med* 1999; **63**: 535-538 [PMID: 10531704]
- 36 **Chowdhury SK**, Smith DR, Fernyhough P. The role of aberrant mitochondrial bioenergetics in diabetic neuropathy. *Neurobiol Dis* 2013; **51**: 56-65 [PMID: 22446165 DOI: 10.1016/j.nbd.2012.03.016]
- 37 **Valls-Canals J**, Povedano M, Montero J, Pradas J. Diabetic polyneuropathy. Axonal or demyelinating? *Electromyogr Clin Neurophysiol* 2002; **42**: 3-6 [PMID: 11851006]
- 38 **Cappellari A**, Airaghi L, Capra R, Ciammola A, Branchi A, Levi Minzi G, Bresolin N. Early peripheral nerve abnormalities in impaired glucose tolerance. *Electromyogr Clin Neurophysiol* 2005; **45**: 241-244 [PMID: 16083148]
- 39 **Bromberg MB**, Albers JW. Patterns of sensory nerve conduction abnormalities in demyelinating and axonal peripheral nerve disorders. *Muscle Nerve* 1993; **16**: 262-266 [PMID: 8383290 DOI: 10.1002/mus.880160304]
- 40 **Mackinnon SE**, Dellon AL, Hudson AR, Hunter DA. Chronic human nerve compression--a histological assessment. *Neuropathol Appl Neurobiol* 1986; **12**: 547-565 [PMID: 3561691]
- 41 **Tapadia M**, Mozaffar T, Gupta R. Compressive neuropathies of the upper extremity: update on pathophysiology, classification, and electrodiagnostic findings. *J Hand Surg Am* 2010; **35**: 668-677 [PMID: 20223605 DOI: 10.1016/j.jhsa.2010.01.007]
- 42 **Perkins BA**, Olalaye D, Bril V. Carpal tunnel syndrome in patients with diabetic polyneuropathy. *Diabetes Care* 2002; **25**: 565-569 [PMID: 11874948]
- 43 **Kennedy JM**, Zochodne DW. Impaired peripheral nerve regeneration in diabetes mellitus. *J Peripher Nerv Syst* 2005; **10**: 144-157 [PMID: 15958126 DOI: 10.1111/j.1085-9489.2005.0010205.x]
- 44 **Celiker R**, Basgöze O, Bayraktar M. Early detection of neurological involvement in diabetes mellitus. *Electromyogr Clin Neurophysiol* 1996; **36**: 29-35 [PMID: 8654318]
- 45 **Kim WK**, Kwon SH, Lee SH, Sunwoo IN. Asymptomatic electrophysiologic carpal tunnel syndrome in diabetics: entrapment or polyneuropathy. *Yonsei Med J* 2000; **41**: 123-127 [PMID: 10731930 DOI: 10.3349/ymj.2000.41.1.123]
- 46 **Ali ZS**, Pisapia JM, Ma TS, Zager EL, Heuer GG, Khoury V. Ultrasonographic Evaluation of Peripheral Nerves. *World Neurosurg* 2016; **85**: 333-339 [PMID: 26463397 DOI: 10.1016/j.wneu.2015.10.005]
- 47 **Cartwright MS**, Walker FO. Neuromuscular ultrasound in common entrapment neuropathies. *Muscle Nerve* 2013; **48**: 696-704 [PMID: 23681885 DOI: 10.1002/mus.23900]
- 48 **Pitarokoli K**, Kerasnoudis A, Behrendt V, Labedi A, Ayzenberg I, Gold R, Yoon MS. Facing the diagnostic challenge: Nerve ultrasound in diabetic patients with neuropathic symptoms. *Muscle Nerve* 2016; **54**: 18-24 [PMID: 26575030 DOI: 10.1002/mus.24981]
- 49 **Thakkar RS**, Del Grande F, Thawait GK, Andreisek G, Carrino JA, Chhabra A. Spectrum of high-resolution MRI findings in diabetic neuropathy. *AJR Am J Roentgenol* 2012; **199**: 407-412 [PMID: 22826404 DOI: 10.2214/AJR.11.7893]
- 50 **Padua L**, Padua R, Lo Monaco M, Aprile I, Tonali P. Multiperspective assessment of carpal tunnel syndrome: a multicenter study. Italian CTS Study Group. *Neurology* 1999; **53**: 1654-1659 [PMID: 10563608]
- 51 **Mediouni Z**, Bodin J, Dale AM, Herquelot E, Carton M, Leclerc A, Fouquet N, Dumontier C, Roquelaure Y, Evanoff BA, Descatha A. Carpal tunnel syndrome and computer exposure at work in two large complementary cohorts. *BMJ Open* 2015; **5**: e008156 [PMID: 26353869 DOI: 10.1136/bmjopen-2015-008156]
- 52 **Makepeace A**, Davis WA, Bruce DG, Davis TM. Incidence and determinants of carpal tunnel decompression surgery in type 2 diabetes: the Fremantle Diabetes Study. *Diabetes Care* 2008; **31**: 498-500 [PMID: 18070996 DOI: 10.2337/dc07-2058]
- 53 **Awada AA**, Bashi SA, Aljumah MA, Heffernan LP. Carpal Tunnel Syndrome in type 2 diabetic patients. *Neurosciences (Riyadh)* 2000; **5**: 219-222 [PMID: 24276599]
- 54 **Chen LH**, Li CY, Kuo LC, Wang LY, Kuo KN, Jou IM, Hou WH. Risk of Hand Syndromes in Patients With Diabetes Mellitus: A Population-Based Cohort Study in Taiwan. *Medicine (Baltimore)* 2015; **94**: e1575 [PMID: 26469895 DOI: 10.1097/MD.0000000000001575]
- 55 **van Dijk MA**, Reitsma JB, Fischer JC, Sanders GT. Indications for requesting laboratory tests for concurrent diseases in patients with carpal tunnel syndrome: a systematic review. *Clin Chem* 2003; **49**: 1437-1444 [PMID: 12928223]
- 56 **Singh R**, Gamble G, Cundy T. Lifetime risk of symptomatic carpal tunnel syndrome in Type 1 diabetes. *Diabet Med* 2005; **22**: 625-630 [PMID: 15842519 DOI: 10.1111/j.1464-5491.2005.01487.x]
- 57 **Plastino M**, Fava A, Carmela C, De Bartolo M, Ermio C, Cristiano D, Ettore M, Abenavoli L, Bosco D. Insulin resistance increases risk of carpal tunnel syndrome: a case-control study. *J Peripher Nerv Syst* 2011; **16**: 186-190 [PMID: 22003933 DOI: 10.1111/j.1529-8027.2011.00344.x]
- 58 **Becker J**, Nora DB, Gomes I, Stringari FF, Seitensu R, Panosso JS, Ehlers JC. An evaluation of gender, obesity, age and diabetes mellitus as risk factors for carpal tunnel syndrome. *Clin Neurophysiol* 2002; **113**: 1429-1434 [PMID: 12169324 DOI: 10.1016/S1388-2457(02)00201-8]
- 59 **Aboonq MS**. Pathophysiology of carpal tunnel syndrome. *Neurosciences (Riyadh)* 2015; **20**: 4-9 [PMID: 25630774]
- 60 **Ginanneschi F**, Cioncoloni D, Bigliazzi J, Bonifazi M, Lorè C, Rossi A. Sensory axons excitability changes in carpal tunnel syndrome after neural mobilization. *Neurol Sci* 2015; **36**: 1611-1615 [PMID: 25896622 DOI: 10.1007/s10072-015-2218-x]
- 61 **Gül Yurdakul F**, Bodur H, Öztop Çakmak Ö, Ateş C, Sivas F, Eser F, Yılmaz Taşdelen Ö. On the Severity of Carpal Tunnel Syndrome: Diabetes or Metabolic Syndrome. *J Clin Neurol* 2015; **11**: 234-240 [PMID: 26174786 DOI: 10.3988/jcn.2015.11.3.234]
- 62 **Siemionow M**, Zielinski M, Sari A. Comparison of clinical evaluation and neurosensory testing in the early diagnosis of superimposed entrapment neuropathy in diabetic patients. *Ann Plast Surg* 2006; **57**: 41-49 [PMID: 16799307 DOI: 10.1097/01.sap.0000210634.98344.47]
- 63 **Werner RA**, Andary M. Carpal tunnel syndrome: pathophysiology and clinical neurophysiology. *Clin Neurophysiol* 2002; **113**: 1373-1381 [PMID: 12169318]

- 64 **Werner RA**, Andary M. Electrodiagnostic evaluation of carpal tunnel syndrome. *Muscle Nerve* 2011; **44**: 597-607 [PMID: 21922474 DOI: 10.1002/mus.22208]
- 65 **Gazioglu S**, Boz C, Cakmak VA. Electrodiagnosis of carpal tunnel syndrome in patients with diabetic polyneuropathy. *Clin Neurophysiol* 2011; **122**: 1463-1469 [PMID: 21330198 DOI: 10.1016/j.clinph.2010.11.021]
- 66 **Sandin KJ**, Asch SM, Jablecki CK, Kilmer DD, Nuckols TK. Clinical quality measures for electrodiagnosis in suspected carpal tunnel syndrome. *Muscle Nerve* 2010; **41**: 444-452 [PMID: 20336661 DOI: 10.1002/mus.21617]
- 67 **Moon HI**, Kwon HK, Kim L, Lee HJ, Lee HJ. Ultrasonography of palm to elbow segment of median nerve in different degrees of diabetic polyneuropathy. *Clin Neurophysiol* 2014; **125**: 844-848 [PMID: 24269093 DOI: 10.1016/j.clinph.2013.10.041]
- 68 **Vasiliadis HS**, Georgoulas P, Shrier I, Salanti G, Scholten RJ. Endoscopic release for carpal tunnel syndrome. *Cochrane Database Syst Rev* 2014; **(1)**: CD008265 [PMID: 24482073 DOI: 10.1002/14651858.CD008265.pub2]
- 69 **O'Connor D**, Marshall S, Massy-Westropp N. Non-surgical treatment (other than steroid injection) for carpal tunnel syndrome. *Cochrane Database Syst Rev* 2003; **(1)**: CD003219 [PMID: 12535461 DOI: 10.1002/14651858.CD003219]
- 70 **Ozkul Y**, Sabuncu T, Kocabay Y, Nazligul Y. Outcomes of carpal tunnel release in diabetic and non-diabetic patients. *Acta Neurol Scand* 2002; **106**: 168-172 [PMID: 12174177]
- 71 **Gulabi D**, Cecen G, Guclu B, Cecen A. Carpal tunnel release in patients with diabetes result in poorer outcome in long-term study. *Eur J Orthop Surg Traumatol* 2014; **24**: 1181-1184 [PMID: 24442385 DOI: 10.1007/s00590-014-1418-z]
- 72 **Thomsen NO**, Cederlund RI, Andersson GS, Rosén I, Björk J, Dahlin LB. Carpal tunnel release in patients with diabetes: a 5-year follow-up with matched controls. *J Hand Surg Am* 2014; **39**: 713-720 [PMID: 24582843 DOI: 10.1016/j.jhssa.2014.01.012]
- 73 **Thomsen NO**, Rosén I, Dahlin LB. Neurophysiologic recovery after carpal tunnel release in diabetic patients. *Clin Neurophysiol* 2010; **121**: 1569-1573 [PMID: 20413347 DOI: 10.1016/j.clinph.2010.03.014]
- 74 **Thomsen NO**, Cederlund R, Björk J, Dahlin LB. Health-related quality of life in diabetic patients with carpal tunnel syndrome. *Diabet Med* 2010; **27**: 466-472 [PMID: 20536520 DOI: 10.1111/j.1464-5491.2010.02970.x]
- 75 **Mondelli M**, Giannini F, Ballerini M, Ginanneschi F, Martorelli E. Incidence of ulnar neuropathy at the elbow in the province of Siena (Italy). *J Neurol Sci* 2005; **234**: 5-10 [PMID: 15993135 DOI: 10.1016/j.jns.2005.02.010]
- 76 **Omejec G**, Podnar S. Precise localization of ulnar neuropathy at the elbow. *Clin Neurophysiol* 2015; **126**: 2390-2396 [PMID: 25743266 DOI: 10.1016/j.clinph.2015.01.023]
- 77 **Schady W**, Abuaisa B, Boulton AJ. Observations on severe ulnar neuropathy in diabetes. *J Diabetes Complications* 1998; **12**: 128-132 [PMID: 9618067]
- 78 **Acosta JA**, Hoffman SN, Raynor EM, Nardin RA, Rutkove SB. Ulnar neuropathy in the forearm: A possible complication of diabetes mellitus. *Muscle Nerve* 2003; **28**: 40-45 [PMID: 12811771 DOI: 10.1002/mus.10387]
- 79 **Campbell WW**. Guidelines in electrodiagnostic medicine. Practice parameter for electrodiagnostic studies in ulnar neuropathy at the elbow. *Muscle Nerve Suppl* 1999; **8**: S171-S205 [PMID: 16921634]
- 80 **Moghtaderi A**, Ghafarpour M. The dilemma of ulnar nerve entrapment at wrist in carpal tunnel syndrome. *Clin Neurol Neurosurg* 2009; **111**: 151-155 [PMID: 19084328 DOI: 10.1016/j.clineuro.2008.09.012]
- 81 **Imada M**, Misawa S, Sawai S, Tamura N, Kanai K, Sakurai K, Sakamoto S, Nomura F, Hattori T, Kuwabara S. Median-radial sensory nerve comparative studies in the detection of median neuropathy at the wrist in diabetic patients. *Clin Neurophysiol* 2007; **118**: 1405-1409 [PMID: 17452013 DOI: 10.1016/j.clinph.2007.03.003]
- 82 **Kiylioglu N**, Akyildiz UO, Ozkul A, Akyol A. Carpal tunnel syndrome and ulnar neuropathy at the wrist: comorbid disease or not? *J Clin Neurophysiol* 2011; **28**: 520-523 [PMID: 21946366 DOI: 10.1097/WNP.0b013e318231c2cc]
- 83 **Garland H**, Moorhouse D. Compressive lesions of the external popliteal (common peroneal) nerve. *Br Med J* 1952; **2**: 1373-1378 [PMID: 12997789]
- 84 **Resnick HE**, Stansberry KB, Harris TB, Tirivedi M, Smith K, Morgan P, Vinik AI. Diabetes, peripheral neuropathy, and old age disability. *Muscle Nerve* 2002; **25**: 43-50 [PMID: 11754184]
- 85 **Chiles NS**, Phillips CL, Volpato S, Bandinelli S, Ferrucci L, Guralnik JM, Patel KV. Diabetes, peripheral neuropathy, and lower-extremity function. *J Diabetes Complications* 2014; **28**: 91-95 [PMID: 24120281 DOI: 10.1016/j.jdiacomp.2013.08.007]
- 86 **Troni W**, Parino E, Pisani PC, Pisani G. Segmental analysis of motor conduction velocity in distal tracts of tibial nerve: a coaxial needle electrode study. *Clin Neurophysiol* 2010; **121**: 221-227 [PMID: 19948425 DOI: 10.1016/j.clinph.2009.10.005]
- 87 **Dellon AL**. Diabetic neuropathy: review of a surgical approach to restore sensation, relieve pain, and prevent ulceration and amputation. *Foot Ankle Int* 2004; **25**: 749-755 [PMID: 15566708]
- 88 **Boyd BS**, Dilley A. Altered tibial nerve biomechanics in patients with diabetes mellitus. *Muscle Nerve* 2014; **50**: 216-223 [PMID: 24375463 DOI: 10.1002/mus.24155]
- 89 **Dellon AL**. Treatment of symptomatic diabetic neuropathy by surgical decompression of multiple peripheral nerves. *Plast Reconstr Surg* 1992; **89**: 689-697; discussion 698-699 [PMID: 1546082]
- 90 **Valdivia Valdivia JM**, Weinand M, Maloney CT, Blount AL, Dellon AL. Surgical treatment of superimposed, lower extremity, peripheral nerve entrapments with diabetic and idiopathic neuropathy. *Ann Plast Surg* 2013; **70**: 675-679 [PMID: 23673565 DOI: 10.1097/SAP.0b013e3182764fb0]
- 91 **Liao C**, Zhang W, Yang M, Ma Q, Li G, Zhong W. Surgical decompression of painful diabetic peripheral neuropathy: the role of pain distribution. *PLoS One* 2014; **9**: e109827 [PMID: 25290338 DOI: 10.1371/journal.pone.0109827]
- 92 **Bleasel AF**, Tuck RR. Variability of repeated nerve conduction studies. *Electroencephalogr Clin Neurophysiol* 1991; **81**: 417-420 [PMID: 1721581 DOI: 10.1016/0168-5597(91)90049-4]

**P- Reviewer:** Gómez-Sáez JM, Mansour AA, Raghov RS, Zanoni JN

**S- Editor:** Gong XM **L- Editor:** A **E- Editor:** Wu HL





Published by **Baishideng Publishing Group Inc**

8226 Regency Drive, Pleasanton, CA 94588, USA

Telephone: +1-925-223-8242

Fax: +1-925-223-8243

E-mail: [bpgoffice@wjgnet.com](mailto:bpgoffice@wjgnet.com)

Help Desk: <http://www.wjgnet.com/esps/helpdesk.aspx>

<http://www.wjgnet.com>

